

## Review Article

# Prognostic Value and Therapeutic Perspectives of Coronary CT Angiography: A Literature Review

Patrizia Carità <sup>1</sup>, Andrea Igoen Guaricci <sup>2</sup>, Giuseppe Muscogiuri,<sup>3</sup>  
Nazario Carrabba <sup>4</sup> and Gianluca Pontone <sup>3</sup>

<sup>1</sup>Department of Cardiology, Santissima Trinita' Hospital, Borgomanero, Novara, Italy

<sup>2</sup>Cardiology Institute, Department of Emergency and Organ Transplantation, University Hospital Policlinico Consorziale of Bari, Bari, Italy

<sup>3</sup>Centro Cardiologico Monzino, IRCCS, Milan, Italy

<sup>4</sup>Division of Cardiology, Careggi Hospital, Florence, Italy

Correspondence should be addressed to Andrea Igoen Guaricci; [andrea.guaricci@gmail.com](mailto:andrea.guaricci@gmail.com)

Received 11 May 2018; Accepted 1 August 2018; Published 16 September 2018

Academic Editor: Pablo Avanzas

Copyright © 2018 Patrizia Carità et al. This is an open access article distributed under the Creative Commons Attribution License, which permits unrestricted use, distribution, and reproduction in any medium, provided the original work is properly cited.

Coronary stenosis severity is both a powerful and a still debated predictor of prognosis in coronary artery disease. Coronary computed tomographic angiography (CCTA) has emerged as a noninvasive technique that enables anatomic visualization of coronary artery disease (CAD). CCTA with newer applications, plaque characterization and physiologic/functional evaluation, allows a comprehensive diagnostic and prognostic assessment of otherwise low-intermediate subjects for primary prevention. CCTA measures the overall plaque burden, differentiates plaque subtypes, and identifies high-risk plaque with good reproducibility. Research in this field may also advance towards an era of personalized risk prediction and individualized medical therapy. It has been demonstrated that statins may delay plaque progression and change some plaque features. The potential effects on plaque modifications induced by other medical therapies have also been investigated. Although it is not currently possible to recommend routinely serial scans to monitor the therapeutic efficacy of medical interventions, the plaque modulation, as a part of risk modification, appears a feasible strategy. In this review we summarize the current evidence regarding vulnerable plaque and effects of lipid lowering therapy on morphological features of CAD. We also discuss the potential ability of CCTA to characterize coronary atherosclerosis, stratify prognosis of asymptomatic subjects, and guide medical therapy.

## 1. Introduction

The diagnostic approach to cardiac and coronary diseases is rapidly changing with the advent and implementation of radiologic techniques [1–14]. Coronary computed tomographic angiography (CCTA) is increasingly emerging as a noninvasive technique that enables direct anatomic visualization of atherosclerotic stenosis in the epicardial coronary arteries, with low radiation exposure [15–18]. Although such factors (i.e., high heart rate, arrhythmia, obesity, and high coronary calcium burden) may limit overall evaluability [19–21], the significant improvement in technologies during the last past decades has opened new perspectives in cardiac imaging permitting the acquisition within few seconds and with a higher spatial resolution [22–24]. CCTA has proven to

have a high diagnostic accuracy compared with the invasive coronary angiography (ICA), which represents until now the standard of reference for evaluating coronary artery disease [25–33]. Using at least a 64-slice multidetector row, a sensitivity and specificity of 98% and 90%, respectively, have been reported on a per patient level. The elevated sensitivity turns out into a negative predictive value (NPV) ranging from 95 to 100% to rule out obstructive coronary artery disease (CAD) [23]. This high negative predictive value for CAD translates into an excellent negative predictive value for future events. In a recent study analyzing more than six hundred patients, normal CCTA findings were associated with an event-free survival rate of 100% in both diabetic and nondiabetic patients with suspected CAD [34].

In 2013, the European Society of Cardiology proposed CCTA as an alternative to stress imaging techniques for the assessment of patients with suspected stable CAD and low-to-intermediate pretest probability of CAD [35]. Recently, the update of the NICE-UK guidelines on the management of patients with new onset chest pain proposed CCTA as first-line diagnostic tool for people in whom stable angina cannot be excluded by clinical assessment alone [36].

In this context, coronary stenosis severity is considered a powerful although debated prognostic index of CAD prognosis. Both invasive and noninvasive angiographic studies have demonstrated the correlation between stenosis degree and clinical events. However, in a recent study Min et al. evaluated a large consecutive cohort of patients without history of CAD and showed a similar incidence of all-cause mortality in nonobstructive and 1-vessel obstructive CAD as assessed by CCTA (HR: 1.62 vs. 1.75) [37]. Moreover, it has been reported that more than two-thirds of acute myocardial infarction (MI) may be due to nonobstructing lesions [38]. Beyond the degree of stenosis, other features are pivotal determinants of events. Numerous clinical biomarkers and imaging modalities have been investigated during the past few decades in order to identify patients harboring plaques at high risk of rupturing (vulnerable plaque), hoping to be able to prognosticate events. While ICA is focused only on the evaluation of the degree of coronary stenosis (luminography), CCTA looking at both the wall and the lumen of coronary artery reliably measures the overall plaque burden, differentiates plaque subtypes, and identifies adverse features of coronary high-risk plaques [39, 40]. In addition, CCTA may help us to avoid a PCI in case of obstructive CAD in a small vessel and may help us to start an early and aggressive optimal medical therapy in case of nonobstructive extensive CAD. Currently, there are increasing interest and continuing debate on the potential role of CCTA as a noninvasive method for mapping CAD, identifying nonobstructive lesions with features of vulnerability, defining prognosis of otherwise low-to-moderate risk subjects, and guiding therapeutic interventions. Research in this area may advance us towards an era of personalized risk prediction and individualized medical therapy. Indeed, since various medications—principally acting on lipid profile and inflammation—may prevent plaque progression or even induce regression, the search for simple techniques makes us able to assess these changes could provide physician a valuable tool for patients management. The present paper, moving beyond coronary stenosis, reviews the features of coronary vulnerable plaques and the ability of CCTA to noninvasive plaque characterization with practical prognostic implication in patient risk stratification. Moreover, current and future therapeutically perspectives are elucidated.

## 2. Definition of Vulnerable Plaque and Features by CCTA

Histologic studies suggest that plaque composition plays a central role in the pathogenesis and clinical consequences of epicardial lesions [41]. Expert consensus points that the morphology, composition, and degree of inflammation of

coronary atherosclerotic plaques are more important than the degree of luminal stenosis [42].

If advances in acute coronary syndromes (ACS) are to occur, it is important to recognize their precursor lesions [43]. Most of the ACS are thought to be the result of sudden luminal “thrombosis” that begins from three different pathologies. The most common cause of thrombosis is plaque rupture, followed by plaque erosion. Less commonly dense calcified nodules can penetrate the fibrous cap and cause thrombosis [44–46]. Plaque rupture is the most common cause of coronary thrombosis in both genders: approximately 76% of all fatal coronary thrombi are precipitated by plaque rupture [47, 48]. Consequently, although the term “vulnerable plaque” should be globally reserved for plaques that resemble all three causes of luminal thrombosis, it is usually strictly referred to a rupture-prone plaque. The nonthrombosed lesion that most nearly resembles the acute plaque rupture and then represents its precursor is the thin-cap-fibroatheroma (TCFA) [43].

It has been widely accepted that atherosclerosis is usually a generalized—rather than a focal— process, characterized by a dynamic nature with plaques undergoing biological remodeling and compositional alterations [49]. Autoptic findings from various stages of atherosclerosis have provided a putative sequence of events where lesion progression is not necessarily a process of slow, steady, and indolent accretion [50].

Intimal thickening is observed early in the disease process. The early lesion is composed of smooth muscle cells and is affected by increased macrophage and lipid influx. The next phase is represented by the formation of a necrotic core and the development of a fibrous cap atheroma. The necrotic core contains a certain lipid amount and apoptotic macrophages. Intraplaque hemorrhages are also frequently seen in this entity and lead to further enlargement of the lipid core. A stable fibrous cap may prevent rupture of the lesion. If the fibrous cap loses matrix proteins and smooth muscle cells, a thin cap atheroma can result [51, 52]. The positive remodeling is considered a compensatory outward enlargement of coronary artery accumulating atherosclerosis in its walls [53]. Fibrocalcific plaques might represent an end stage of the atherosclerosis process and can contain extensive calcifications. Because of a stable fibrous cap and lower lipid content, these lesions rarely cause thrombosis but can cause chronic ischemic symptoms because of lumen narrowing [51, 52].

Differently, TCFA are characterized by a large necrotic core, with an overlying thin fibrous cap containing rare smooth muscle cells but numerous infiltrating macrophages [43, 54, 55]. Vessels demonstrating TCFA do not usually show severe lumen narrowing but a positive (expansive) remodeling. Understandably, clinicians aim to detect these plaques before they rupture in order to be able to undertake measures and obtain prevention goals. The search for “vulnerable plaque” is then subject of an intense scientific investigation. Identifying coronary artery lesions prone to future cardiac events and high-risk patients may direct more potent local and systemic approaches for preventive treatments.

Invasive coronary angiography evaluation delineates the vessel lumen with high quality. The additional step of

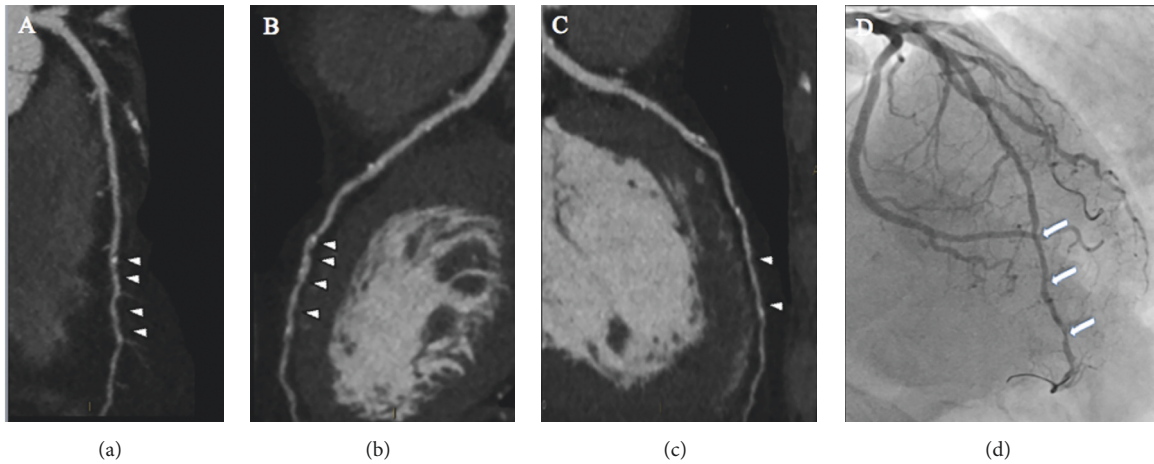


FIGURE 1: A fifty-two-year-old male patient with familial history of coronary artery disease and inconclusive ECG stress test underwent cardiac computed tomography angiography. Multiplanar reconstruction shows in panels (a), (b), and (c) the presence of severe coronary artery disease at the level of distal left anterior descending artery (arrowhead). Invasive coronary angiography confirmed the diagnosis (panel (c), arrows) and the patient underwent successfully coronary revascularization.

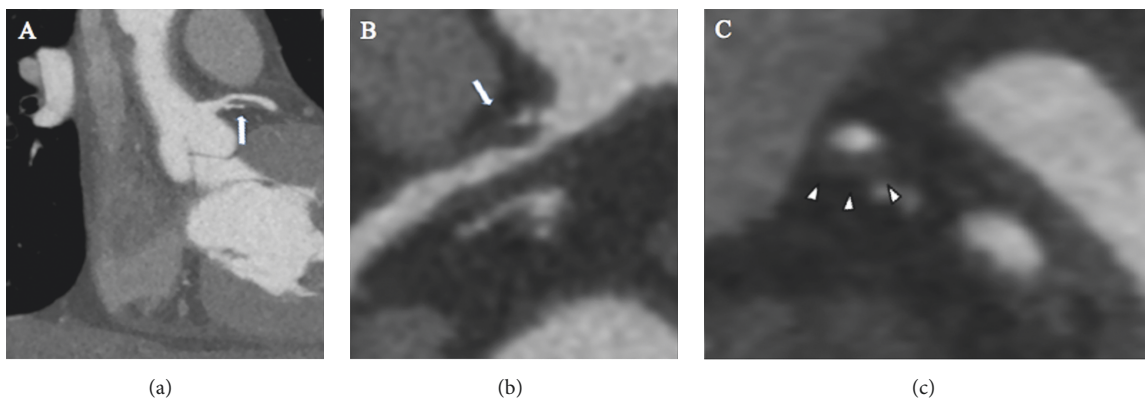


FIGURE 2: A fifty-three-year old-male patient with history of arterial hypertension and dyslipidemia was admitted at the emergency department for atypical chest pain. Cardiac computed tomography acquired during hospitalization showed in multiplanar reconstruction a soft plaque determining stenosis of 70% in proximal left anterior descending artery ((a) (b) arrow). Cross sectional images showed positive remodeling of a soft plaque ((c) arrowhead).

intravascular ultrasound (IVUS), also known as virtual histology, constitutes the current gold standard for plaque evaluation and quantification [56]. Moreover, optical coherence tomography (OCT) provides a higher magnitude of resolution (10  $\mu\text{m}$ ) when compared with IVUS (permitting direct visualization of thin cap fibroatheroma) but lacks delineation of the outer vessel boundary due to weaker penetration [57]. Although providing high-resolution images, these techniques are highly expensive and invasive, being used only in conjunction with coronary artery catheterization.

Recently, CCTA has emerged as a promising tool that enables direct visualization of the vascular lumen (with assessment of presence and extent of angiographic stenosis) together with the arterial wall characterization (Figure 1). CCTA focalizes attention on validated measures of plaque vulnerability. There is increasing interest and continuing debate on its potential role as a “noninvasive” method for (1)

mapping coronary atherosclerosis, (2) better understanding the adverse features of coronary plaques, and (3) achieving potential benefits in guiding therapeutic interventions [58].

CCTA imaging has been extensively compared with IVUS and became really after the demonstration of the existence of a good correlation with virtual histology [59]. Identification of noncalcified plaques (NCP), particularly low-attenuation plaques (LAP) with spotty calcifications (SCPs), positive vessel remodeling (PR), and napkin-ring-like NRS has been considered as important landmarks of plaque vulnerability and instability [60]. Using CCTA, in comparison with grayscale IVUS, calcified versus noncalcified plaque can be quantified on the basis of density cutoff values [61]. Low attenuation suggests high lipid content and has defined for attenuations below 30 Hounsfield Units (HU) [58, 62] (Figure 2). Different HU cut-off limits used in different laboratories presumably have weakened the estimated risk

of ACS associated with LAP. Positive remodeling is usually assessed using vessel area (PRI = lesion plaque area/reference area). SCs are scattered calcified nodules within the context of a plaque with a diameter <3 mm. Usually, SCs are well represented on the shoulder of the plaque and are associated to enzyme activity. Finally, the NRS is a thin ring of high attenuation around the plaque along the outer contour of the vessel. This is typically due to the presence of a hypodense deposit of necrotic material in the center of the plaque itself [58, 62]. Importantly, despite *ex vivo* comparison to histology showed the ability of CCTA to differentiate noncalcified, mixed, and calcified plaques [63]. A limitation of commonly used computed tomography (CT) scanners is the relatively poor soft tissue contrast which means difficulty in further subclassification (with possible misclassification) of noncalcified subcomponents (i.e., fibrous versus fatty components) on the only basis of HU attenuation [64, 65]. It has been indeed reported a tendency to overlapping the HU between lipid-rich and fibrous noncalcified plaques. CT technology is, however, rapidly evolving and several solutions are available. In the latest generations of CT devices, faster acquisition speeds have been achieved by faster rotation, larger detectors, and dual source systems. Dual-energy CT can reduce blooming effects that occur near to calcium and iodine and leads to more valid density measurements [66, 67]. The two sources of energy are particularly apt at achieving material decomposition (i.e., differentiation of different tissues), with improved plaque characterization [68, 69]. Moreover, complex image (iterative) reconstructions, recently introduced in commercial systems, seem to be able to improve image quality with regard to noise, resolution, artifacts, and finally diagnostic accuracy [29].

### 3. Prognosis Beyond Degree of Stenosis

Despite advances in preventive approaches and therapies, CAD is one of the main causes of morbidity and mortality in both industrialized and low income to middle-income countries. Sudden cardiac death has been reported to occur in 50% of men and 64% of women without previous cardiovascular symptoms [70]. Coronary stenosis severity is both a powerful but a still now debated predictor of prognosis. A large number of studies have confirmed the long-term prognostic power of CCTA in attributing excellent prognosis to patients (including diabetics) without coronary plaques and intermediate prognosis in patients with nonobstructive lesions. In a long term follow-up, event-free survival rates of symptomatic patients with CT diagnosed CAD decreased proportionally from normal coronary arteries (98.3%) to nonobstructive (95.2%) to obstructive CAD (87.5%) [71]. Similarly, in the very low risk cohort of patients of the CONFIRM registry, followed for a mean of 5 years, Cheruvu et al. reported that the incidence of major adverse cardiovascular events (MACE; all-cause death, nonfatal MI, unstable angina, or late coronary revascularization) increased from 5.6% in those without CAD to 13.24% in those with nonobstructive disease and to 36.28% in those with obstructive CAD ( $p < 0.001$ ) [72].

The novel Coronary Artery Disease-Reporting and Data System (CAD-RADS) scores used to standardize CCTA

reporting ranked CAD stenosis severity as 0 (0%), 1 (1% to 24%), 2 (25% to 49%), 3 (50% to 69%), 4A (70% to 99% in 1 to 2 vessels), 4B (70% to 99% in 3 vessels or  $\geq 50\%$  left main), or 5 (100%). It is not surprising that CAD-RADS effectively identify patients at risk for adverse events. Cumulative 5-year event-free survival ranges from 95.2% to 69.3% for CAD-RADS 0 to 5 ( $p < 0.0001$ ). Higher scores are associated with elevations in event risk (hazard ratio: 2.46 to 6.09;  $p < 0.0001$ ). Its incorporation into coronary CTA reports may provide a novel opportunity to promote evidence-based care [73]; however, this system, as well as the segment involvement score (SIS), is flawed for several reasons, being probably the main that it oversimplifies prognosis of CAD strictly relating it to the degree of stenosis.

Notably, in a recent substudy of the above mentioned CONFIRM registry, even the presence of a single nonobstructive (1%-49% stenosis) left main plaque in elective CCTA for suspected CAD increased in a 5-year follow-up the risk for composite outcome in women (adjusted hazard ratio, 1.48;  $p = 0.005$ ) but not in men (adjusted hazard ratio, 0.98,  $p = 0.806$ ). This turns out into a nearly 80% higher risk for events than men. This sex-specific prognostic significance, not observed across other patterns (e.g., location or extent) of preclinical coronary plaque, had to be considered since may increase risk stratification efforts [74].

These and similar findings highlight the prognostic importance of both angiographically significant (potentially flow-limiting) and nonobstructive coronary stenosis, as well as the excellent prognosis for patients without evident plaque on CCTA. This means that absence of coronary atherosclerosis on high-resolution CCTA images identifies a patient with an exceptionally low risk of long-term cardiovascular events [75].

Of note, more than two-thirds of acute MI may be due to mild to moderate plaques that did not significantly compromise the coronary lumen before the event [36]. As a consequence, beyond the effective degree of stenosis, other lesion features—reflecting plaque composition—are pivotal determinants of untoward outcomes. The ability of CCTA to assess the entire coronary tree for the presence (present/absent), extent (proximal and/or distal), distribution (per vessel and per segment) of CAD, degree of vessel stenosis (<50% or >50%), and plaque morphology (i.e., calcified, mixed, and no calcified), with further subclassification of plaque subcomponents, makes it a unique non-invasive modality. Starting the first evidence reporting the role of CCTA in improving the prognostic stratification of patients with suspected CAD, there is a growing interest in testing the correlation between the coronary plaque features and the occurrence of MACE [76–78].

In a multicenter study, the presence of a large plaque burden, TCFA, and a small lumen area were independent predictors of future events [56]. Tian et al. demonstrated in 643 patients enrolled in an OCT, IVUS, and angiography study that severe coronary stenosis has a twofold probability to show the features of vulnerable lesions suggesting a potential overlapping between degree of stenosis and plaque characteristics to influence outcome of patients [79]. Undoubtedly, the prevalence of severe coronary stenosis is

however significantly lower than that of mild-to-moderate atherosclerotic lesions. Moreover, many of these lesions despite a clinical relevant high plaque burden may be not severely stenotic at ICA.

Ahmadi et al. have showed that survival rate of subjects with nonobstructive CAD decreases significantly with the number of diseased coronary arteries (from single to triple vessels disease,  $p < 0.001$ ) and is significantly affected from the plaque morphology. Death rate increases incrementally from calcified plaque (1.4%) to mixed plaque (3.3%) to no calcified plaque (9.6%). The risk-adjusted hazard ratios of all-cause mortality were 3.2 (95% confidence interval 1.3 to 8.0,  $p = 0.001$ ) for mixed plaques and 7.4 (95% confidence interval 2.7 to 20.1,  $p = 0.0001$ ) for noncalcified plaques compared with calcified plaques. In subjects with mixed or calcified plaques, the death rate also increased with the severity of coronary artery calcium from 1 to 9 to  $> 400$  [30].

High-risk plaque (HRP) features have been also shown to be associated with an increased risk of events even in patients with nonobstructive CAD. In a recently published study it has been shown that the use of an integrated score easily obtained with CCTA (based on the presence of mixed and remodeled atherosclerotic plaques) may improve MACE prediction in symptomatic patients without previous cardiovascular history but at intermediate pretest likelihood of CAD, beyond standard clinical (Diamond & Forrester) and coronary (based on presence and degree of stenosis) scores used in clinical practice [78]. This finding underlines the importance of a comprehensive coronary evaluation even taking into consideration the low prevalence of some high-risk plaque characteristics.

The prognostic value of risk assessment determined on the basis of plaque anatomy alone, however, has been partially disappointing, because of a low positive predictive value [56]. It is indeed worth mentioning that, despite the ability to identify potentially vulnerable plaques with CCTA, there is no clear indication of which and how many plaques with high-risk features will actually rupture and cause events. In the Providing Regional Observations to Study Predictors of Events in the Coronary Tree (PROSPECT) study only 5% of TCFA plaques identified by IVUS caused coronary events [56]. Therefore, the presence of high-risk plaques is probably just a factor in the more complex framework of ACS pathophysiology [80]. The consequences of a plaque disruption depend not only on the composition of the atheroma itself but also on local rheological and hemodynamic phenomena [81]. How plaque composition and local phenomena interact is an important question and several investigators have tried to address it. Moreover, the morphology and underlying activity of individual coronary plaques are heterogeneous and dynamic. Probably, taking into consideration other important pathophysiological principles applied to CCTA imaging, such as plaque inflammation-induced ischemia and the CT-derived fractional flow reserve, it will be conceivable in the next future to further improve the prognostic power of noninvasive coronary evaluation [82].

#### 4. CCTA in Asymptomatic Patient

Still evaluating with certainty the role of CCTA in asymptomatic subjects now is not possible and further data are needed to be collected on this topic. Notably, with the technological advance the accuracy of CCTA has constantly improving and, at the same time, possible adverse effects, costs, and radiation exposure reduction are enlarging the indication of the CCTA. Recent recommendations give a criterium of “uncertainty” to the indication of CCTA in asymptomatic patients [Andreini *jcm* 2016].

The evaluation of asymptomatic patients may sometimes imply a wider evaluation looking for different signs of atherosclerotic involvement of multiple vascular districts. In a cohort of nondiabetic ambulatory subjects, prevalently referred by their physicians for risk-stratification screening, it has been demonstrated that the number of coronary arteries with any amount of disease on CCTA was significantly correlated with increased intima media thickness (IMT) and carotid plaque on vascular ultrasound. CAD was present in most patients with carotid plaque or increased IMT and absent in most patients without carotid plaque or with lower IMT values [83]. Being IMT a well-established marker of subclinical systemic atherosclerotic process and increased global cardiovascular risk beyond traditional system for risk scoring, this relationship supports the concept that an integrated noninvasive approach should be needed [84–86].

Among asymptomatic patients, diabetics represent a particular category in which CCTA could be very useful for prognostic purpose. Two aspects need to be considered. At first, although diabetes mellitus is an important risk factor for future cardiovascular events, some studies suggest that it should not be considered a “coronary risk equivalent” [87]. This consideration is confirmed by studies employing CCTA. Indeed, the absence of coronary atherosclerosis was associated with 100% disease-free survival at follow-up [88]. Second, since the diabetic patient carries a condition of high coronary risk per se [89–91], it is conceivable to postulate that standard risk stratification does not add any additional prognostic information. A recent study supporting this concept has enrolled 517 consecutive asymptomatic patients (63% male, 17.6% diabetics) who underwent CCTA and were evaluated for the prediction of MACE. Over a median follow-up of 4.4 [3.4–5.1] years there were 53 MACE (10%). The authors found that the presence of obstructive CAD and plaque positive remodeling increased MACE prediction as compared to a model based on 10-year-FRS, carotid disease, and coronary calcium scoring in the subgroup of nondiabetic patients. Importantly, the percentage of segments with remodeled plaque was the only predictor of MACE in the subgroup of diabetic subjects [92]. Therefore, CCTA may represent a tool able to make a certain diagnosis of CAD with significant prognostic impact in diabetics. Anyway, since a wide stratification with the use of CCTA of all diabetic patients is not possible for economic reasons, screening patients whit more than 10-year-old diabetes mellitus could be a suitable strategy [93].

## 5. Future Perspectives for Prognosis Improvement

It has been demonstrated that an ischemia-guided revascularization yields improved clinical outcomes in a cost-effective fashion compared with anatomy-guided revascularization alone [38]. As a consequence, in patients with suspected or known disease, noninvasive functional testing should be used as gatekeeper to catheterization. At the time of ICA, the evaluation of fractional flow reserve (FFR) may be instead considered for assessment of the hemodynamic significance of coronary lesion with moderate stenosis (50%-90%). Indeed, the identification of obstructive coronary lesions is only one aspect of the complex relationship between stenosis and ischemia, since there is an increasing awareness on the unreliable relationship between stenosis severity and functional relevance [94].

Even if most CCTA-detected obstructive lesions are confirmed by ICA, lesser than half of those studied with invasive FFR effectively causes ischemia. On the other hand, nonobstructive lesions can be associated with inducible ischemia [95]. Also in this context plaque characterization may help for clinical purpose. Park et al. showed that plaque remodeling, when adjusted for stenosis severity, remained a predictor of ischemia for all degrees of stenosis [96]. Similarly, it has been reported that in moderately stenotic vessels perfusing ischemic territories the prevalence of PR, LAP, and SCs was three to fivefold higher than in vessels without ischemia [97].

The pathogenetic mechanism linking HRP features and inducible ischemia in moderate anatomic stenosis is still not completely clear. It has been postulated that the necrotic core could be responsible for oxidative stress. The resulting local inflammation may compromise the production and bioavailability of the vasodilator nitric oxide and increase the levels of vasoconstrictors such as isoprostanes. The latter along with local endothelial dysfunction could cause a focal “functional stenosis” with inability of the vessel segment containing high-risk plaques to vasodilate adequately during stress [98]. For example, the ongoing presence of endothelial shear stress, which is considered a potent proatherogenic and proinflammatory stimulus, has been associated with a more inflamed and unstable coronary plaque phenotype [56]. Revascularization procedures could be reserved for patients with lower FFR in the presence of obstructive disease on invasive angiography, while high-intensity statin therapy should be prescribed for patients with abnormal FFR in the setting of nonobstructive but high-risk plaques with the aim to obtain plaque stabilization [94].

In this new optic, CCTA with newer applications—due to combination of both plaques characterization and functional evaluation of flow-limiting stenosis in the same examination—seems to represent the Holy Grail for a comprehensive coronary disease assessment [99]. Recently, two methods for the evaluation of the functional relevance of stenosis by cardiac CT have been introduced in the clinical field, stress myocardial computed tomography perfusion (CTP), and fractional flow reserve computed tomography (FFRCT) [24, 82, 100]. Stress CTP demonstrated similar

performance to nuclear imaging and additional diagnostic value to CCTA alone as compared to invasive FFR [22]. Software to determine FFR from CCT dataset (FFR-CT) using computational fluid dynamics laws has been recently developed. FFR-CT is derived from routinely anatomic images (acquired at rest only) and subsequent mathematically simulated hyperemia without the need of vasodilator administration.

Gaur et al. showed that plaque tissue characterization and FFR-CT improve the ability to predict inducibility of ischemia in a myocardial territory dependent on a specific coronary lesion compared to mere luminal stenosis assessment [98]. Specific studies have already been designed to investigate whether plaque characterization is a better approach to predict and detect myocardial ischemia compared to current standard of care. Preliminary results from CREDENCE trial are hopefully waited [101].

Moreover, to improve the prognostic power of CCTA, a better clarification of the relationship between plaque burden and cardiac inflammation biomarkers would be very useful [102, 103]. Molecular imaging of plaque activity is also gaining ground and is poised to provide prognostically significant information if the current exciting results are expanded.

## 6. Therapeutic Perspectives

Before CCTA wide spreading, patients without obstructive plaques were often overlooked and, in the absence of inducible ischemia, were included without distinctions in the same group of those without CAD. In fact, among patients with nonobstructive lesions, those with low-risk plaque morphology may be differentiated from those in whom plaque characteristics are associated with an increased risk of future events. Randomized trials have shown that patients undergoing CCTA have significantly reductions in the risk for mortality, revascularizations, and incident MI, probably related to the increased utilization of preventive therapies (i.e., aspirin and statin) among patients with stable chest pain and nonobstructive CAD, as compared to patients who underwent functional provocative test [104, 105].

It is well known that hypocholesterolemic and antiplatelet therapies are considered as some of the most important preventive strategies for coronary artery disease decreasing relative risk of MACE by 20-45% [106, 107].

Reduction in circulating levels of atherogenic lipoproteins has been postulated as one mechanism by which statins exert favorable benefits. However, other pathways beyond cholesterol contribute to CV risk through pleiotropic mechanisms. The statins also reduce intraplaque inflammation, neoangiogenesis, apoptosis, and metalloproteinase activity. These pleiotropic properties, acting together for the plaque stabilization, may contribute to the clinical outcome [108, 109].

Coronary angiography and IVUS techniques for serial examination have demonstrated that statins are able to slow the rate of plaque progression and even to induce a small amount of coronary atherosclerosis regression if target of low-density lipoprotein (LDL) cholesterol levels are achieved.

Reduction in LDL cholesterol level to 80 mg/dl by atorvastatin was associated with no increase in coronary plaque burden [110], and more intensive therapy with rosuvastatin to reduce LDL cholesterol to 60 mg/ml results in significant reduction of coronary atherosclerosis [111]. This means a strong relation between cholesterol reduction and changes in atheroma volume.

However, to date, limited data exists to relate the effect of statin use to specifically coronary plaque “features” and morphology beyond stenosis severity [112]. For example, it has been shown that statins increase plaque hypercholesterogenicity by grey-scale IVUS (independently by plaque volume) and significantly reduce the degree of the fibrofatty intraplaque constituents (conversely increasing intraplaque calcified composition) by virtual histology IVUS [113]. However, IVUS requires an invasive approach and is not suitable for nonischemic patients with nonobstructive plaques (only moderate cardiovascular risk).

Cardiac CT has historically had a role in risk stratification using the Coronary Artery Calcification Score (CAC). CAC is strongly associated with cardiovascular risk. Once coronary calcification is initiated, it follows a predictable pattern of progression, with no consistent evidence of the ability to regress in response to therapy. Although standard CAC score appears to have no role in evaluating therapeutic response or change in atherosclerotic disease over time [40, 114], new CAC scoring approaches discriminating calcium density from volume might provide significant assessment of therapeutic changes, supporting the often asserted (but as yet unvalidated) view that calcification may play a role in plaque stabilization [115].

CCTA is the most promising noninvasive method that has the potential to fully phenotype an individual’s coronary artery plaque volume. It has been shown that noncalcified plaques as detected by CCTA represent the component of atherosclerotic plaque that is relevantly influenced by statin therapy and then account for the benefits of therapy [116, 117]. Compared to IVUS, CCTA has undoubted advantages as noninvasiveness and lower cost. Various studies demonstrated the feasibility of using serial CCTA to assess plaque changes with high intra- and interobserver reproducibility, allowing this method to potentially track atherosclerosis noninvasively. [118]

Inoue et al. in a preliminary study on 32 patients, who underwent CCTA with suspected coronary artery disease, demonstrated that the use of statins—even at a low dosage—resulted in a reduction in plaque quantity and decrease in necrotic core volume. Interestingly, changes in plaque morphology may even occur with relatively less robust changes in the lipid profile and early after initiation of downstream statin treatment [119].

In a recently published multicenter prospective observational study, Li et al. divided patients with baseline mild noncalcified coronary plaque on CCTA according to the statin protocol undertaken [intensive statin therapy (n=55), moderate statins (n = 85), and no statin (n = 66)]. Their results confirmed that statin can delay progression and even induce plaque regression of mild non-calcified coronary plaque. LAP volume, total plaque volume, and

percent plaque volume showed significant regression among intensive statins compared to no statin group. On multivariable model both moderate and intensive statin therapy were independent predictors of plaque regression (although standardized coefficients of the intensive statin was greater than that of the moderate statin:  $-0.36P < 0.001$  vs  $-0.21 P = 0.004$ , respectively). Moreover, patients with greater baseline plaque burden and higher basal hyperlipidemia are more likely to benefit from statin therapy. These results could have important implications for disease prevention strategy, suggesting the potential need of stronger statin approach for patients with noncalcified plaque, especially for patients with high risk vulnerable plaque features [117].

The greater benefit from statin therapy even among asymptomatic individuals with higher coronary plaque burden as assessed by CCTA has recently been confirmed also independently from scores for the prediction of 10-year cardiovascular risk [120]. However, despite reducing progression and promoting regression of coronary atherosclerosis, statin therapy just partly addresses residual cardiovascular risk. More than 20% of patients with LDL-C $\leq$ 70 mg/dL continue to have progression over time in pooled analysis of IVUS studies [40]. This residual risk could potentially be minimized by intensification of lipid-lowering therapy or initiation of non-statin medications, but these approaches are not without drawbacks.

Literature shows that omega-3 fatty acid eicosapentaenoic acid (EPA) has a broad range of beneficial effects on the atherosclerotic pathway, including those on lipids, lipoproteins, inflammation, oxidation, phospholipid membranes, and the atherosclerotic plaque itself [121]. The implications of eicosapent ethyl add-on to statin therapy (in subjects with well-controlled low-density lipoprotein cholesterol levels) for changes in atherosclerotic plaque morphology (plaque burden and/or plaque vulnerability as assessed by CCTA) are currently investigated from ongoing trials that will provide important imaging-derived data [122].

The activation of renin-angiotensin system (RAS) is another important risk factor in atherogenesis. Angiotensin II promotes atherogenesis by stimulating inflammation, oxidative stress, and endothelial dysfunction. In animal models ACE inhibitors and ARBs have been shown to reduce the progression of atherosclerosis [123], and in human study the perindopril has shown to prevent coronary remodeling [124]. Recent studies with CCTA indicate that combination of statins with ACE inhibitor or ARB would be more effective for antiatherosclerotic therapy than statin alone even in patients with CAD, suggesting an inhibitory effect of the combination therapy on vascular remodeling [125].

Also colchicine has been postulated to have beneficial effects on atherosclerosis. In a recently published paper on 80 patients with recent ACS (<1 month) followed for 1 year, colchicine therapy (0.5 mg/day colchicine plus OMT vs OMT alone) was significantly associated with greater reduction in low attenuation plaque volume ( $p = 0.039$ ) on CCTA, independent of high-dose statin therapy. The improvements in plaque morphology were likely driven by the anti-inflammatory properties, as demonstrated by reductions in high-sensitivity C-reactive protein (hsCRP), rather than

changes in lipoproteins. Colchicine could be beneficial as an additional second-lines, add-on, and prevention therapy in patients post-ACS if validated in future studies [126].

Although currently it is not possible to recommend serial scans to monitor the therapeutic efficacy of a medical interventions, the plaque modulation, as a part of risk modification, is a feasible strategy. Direct visualization of the natural course of atherosclerosis, as well as identification of the clinical determinants of plaque progression or regression, holds the potential to shift the paradigm of CAD monitoring among low- to moderate-risk patients with suspected CAD, with aims of offering earlier therapeutic strategies [127]. It is reasonable to accept that a substantial reduction in plaque vulnerability by therapeutic intervention should contribute into plaque stability and in turn decrease cardiovascular event rates. Further studies should be warranted for elucidates this matter.

## 7. Conclusions

Nowadays, primary prevention of major cardiac events needs a strong implementation for ethic and economic reasons. Early identification of CAD, characterization of atherosclerotic process, evaluation of ischemia-related plaque features, and assessment of “vulnerable plaque,” sometimes in the context of “vulnerable patient”, are mandatory endpoints in order to reach this aim. To date, CCTA is the only technique able to approach comprehensively these topics. Moreover, according to the first encouraging literature reports, CCTA could be able to monitor and guide the therapeutic approach which is the ultimate goal of events prediction.

## Conflicts of Interest

No relationship with industry and financial associations within the past 2 years posing conflicts of interest in connection with the submitted article exists.

## Acknowledgments

Dr. Gianluca Pontone received institutional grant and fee from GE Healthcare, Medtronic, Bracco, Heartflow.

## References

- [1] M. J. Wolk, S. R. Bailey, J. U. Doherty et al., “Multimodality appropriate use criteria for the detection and risk assessment of stable ischemic heart disease. american college of cardiology foundation appropriate use criteria task force,” *Journal of the American College of Cardiology*, vol. 63, no. 2, pp. 380–406, 2014.
- [2] G. Pontone, D. Andreini, A. L. Bartorelli et al., “Comparison of accuracy of aortic root annulus assessment with cardiac magnetic resonance versus echocardiography and multidetector computed tomography in patients referred for transcatheter aortic valve implantation,” *Journal of the American College of Cardiology*, vol. 112, no. 11, pp. 1790–1799, 2013.
- [3] N. Gaibazzi, T. Porter, V. Lorenzoni et al., “Effect of coronary revascularization on the prognostic value of stress myocardial contrast wall motion and perfusion imaging,” *Journal of the American Heart Association*, vol. 6, no. 6, p. e006202, 2017.
- [4] A. I. Guaricci, C. Basso, and G. Tarantini, “Recurrent syncope on effort due to concealed constrictive pericarditis,” *European Heart Journal*, vol. 34, no. 24, p. 1817, 2013.
- [5] G. Pontone, D. Andreini, E. Bertella et al., “Comparison of cardiac computed tomography versus cardiac magnetic resonance for characterization of left atrium anatomy before radiofrequency catheter ablation of atrial fibrillation,” *International Journal of Cardiology*, vol. 179, pp. 114–121, 2015.
- [6] G. Pontone, D. Andreini, A. I. Guaricci et al., “The STRATEGY study (stress cardiac magnetic resonance versus computed tomography coronary angiography for the management of symptomatic revascularized patients): resources and outcomes impact,” *Circulation: Cardiovascular Imaging*, vol. 9, no. 10, Article ID 005171, 2016.
- [7] “CT coronary angiography in patients with suspected angina due to coronary heart disease (SCOT-HEART): an open-label, parallel-group, multicentre trial,” *The Lancet*, vol. 385, no. 9985, pp. 2383–2391, 2015.
- [8] E. Maffei, S. Seitun, C. Martini et al., “CT coronary angiography and exercise ECG in a population with chest pain and low-to-intermediate pre-test likelihood of coronary artery disease,” *Heart*, vol. 96, no. 24, pp. 1973–1979, 2010.
- [9] A. I. Guaricci, P. Carità, V. Lorenzoni et al., “QT-interval evaluation in primary percutaneous coronary intervention of ST-segment elevation myocardial infarction for prediction of myocardial salvage index,” *PLoS ONE*, vol. 13, no. 2, p. e0192220, 2018.
- [10] J. J. Bax, S. E. Inzucchi, R. O. Bonow, J. D. Schuijff, M. R. Freeman, and E. J. Barrett, “Cardiac imaging for risk stratification in diabetes,” *Diabetes Care*, vol. 30, no. 5, pp. 1295–1304, 2007.
- [11] G. Pontone, D. Andreini, A. I. Guaricci et al., “Association between haptoglobin phenotype and microvascular obstruction in patients with ST-segment elevation myocardial infarction: a cardiac magnetic resonance study,” *JACC: Cardiovascular Imaging*, 2018.
- [12] G. Pontone, D. Andreini, E. Bertella et al., “Prognostic value of dipyridamole stress cardiac magnetic resonance in patients with known or suspected coronary artery disease: a mid-term follow-up study,” *European Radiology*, vol. 26, no. 7, pp. 2155–2165, 2016.
- [13] G. Pontone, A. I. Guaricci, D. Andreini et al., “Prognostic benefit of cardiac magnetic resonance over transthoracic echocardiography for the assessment of ischemic and nonischemic dilated cardiomyopathy patients referred for the evaluation of primary prevention implantable cardioverter–defibrillator therapy: clinical perspective,” *Circulation: Cardiovascular Imaging*, vol. 9, no. 10, p. e004956, 2016.
- [14] G. Pontone, A. I. Guaricci, D. Andreini et al., “Prognostic stratification of patients with ST-segment-elevation myocardial infarction (PROSPECT): a cardiac magnetic resonance study,” *Circulation: Cardiovascular Imaging*, vol. 10, no. 11, p. e006428, 2017.
- [15] D. Andreini, E. Martuscelli, A. I. Guaricci et al., “Clinical recommendations on Cardiac-CT in 2015: a position paper of the Working Group on Cardiac-CT and Nuclear Cardiology of the Italian Society of Cardiology,” *Journal of Cardiovascular Medicine*, vol. 17, no. 2, pp. 73–84, 2016.
- [16] G. Pontone, D. Andreini, E. Bertella et al., “Impact of an intra-cycle motion correction algorithm on overall evaluability and diagnostic accuracy of computed tomography coronary



- angiography," *European Radiology*, vol. 26, no. 1, pp. 147–156, 2016.
- [17] T. Arcadi, E. Maffei, C. Mantini et al., "Coronary CT angiography using iterative reconstruction vs. Filtered back projection: Evaluation of image quality," *Acta Biomedica*, vol. 86, no. 1, pp. 77–85, 2015.
- [18] E. Maffei, C. Martini, S. De Crescenzo et al., "Low dose CT of the heart: a quantum leap into a new era of cardiovascular imaging," *La radiologia medica*, vol. 115, no. 8, pp. 1179–1207, 2010.
- [19] J. Abdulla, K. S. Pedersen, M. Budoff, and K. F. Kofoed, "Influence of coronary calcification on the diagnostic accuracy of 64-slice computed tomography coronary angiography: A systematic review and meta-analysis," *The International Journal of Cardiovascular Imaging*, vol. 28, no. 4, pp. 943–953, 2012.
- [20] A. I. Guaricci, E. Maffei, N. D. Brunetti et al., "Heart rate control with oral ivabradine in computed tomography coronary angiography: a randomized comparison of 7.5 mg vs 5 mg regimen," *International Journal of Cardiology*, vol. 168, no. 1, pp. 362–368, 2013.
- [21] A. I. Guaricci, J. D. Schuijf, F. Cademartiri et al., "Incremental value and safety of oral ivabradine for heart rate reduction in computed tomography coronary angiography," *International Journal of Cardiology*, vol. 156, no. 1, pp. 28–33, 2012.
- [22] G. Pontone, D. Andreini, A. I. Guaricci et al., "Incremental diagnostic value of stress computed tomography myocardial perfusion with whole-heart coverage CT scanner in intermediate-to high-risk symptomatic patients suspected of coronary artery disease," *JACC: Cardiovascular Imaging*, 2018.
- [23] G. Pontone, E. Bertella, S. Mushtaq et al., "Coronary artery disease: diagnostic accuracy of CT coronary angiography—a comparison of high and standard spatial resolution scanning," *Radiology*, vol. 271, no. 3, pp. 688–694, 2014.
- [24] G. Pontone, D. Andreini, A. I. Guaricci et al., "Rationale and design of the perfection (comparison between stress cardiac computed tomography perfusion versus fractional flow reserve measured by computed tomography angiography in the evaluation of suspected coronary artery disease) prospective study," *Journal of Cardiovascular Computed Tomography*, vol. 10, no. 4, pp. 330–334, 2016.
- [25] J. Abdulla, S. Z. Abildstrom, O. Gotzsche, E. Christensen, L. Kober, and C. Torp-Pedersen, "64-Multislice detector computed tomography coronary angiography as potential alternative to conventional coronary angiography: a systematic review and meta-analysis," *European Heart Journal*, vol. 28, no. 24, pp. 3042–3050, 2007.
- [26] E. Maffei, C. Martini, C. Tedeschi et al., "Diagnostic accuracy of 64-slice computed tomography coronary angiography in a large population of patients without revascularisation: registry data in NSTEMI acute coronary syndrome and influence of gender and risk factors," *La radiologia medica*, vol. 116, no. 7, pp. 1014–1026, 2011.
- [27] E. Maffei, C. Martini, S. Seitun et al., "Computed tomography coronary angiography in the selection of outlier patients: a feasibility report," *Radiol Med*, vol. 117, no. 2, pp. 214–229, 2012.
- [28] M. Dewey, A. L. Vavere, A. Arbab-Zadeh et al., "Patient characteristics as predictors of image quality and diagnostic accuracy of MDCT compared with conventional coronary angiography for detecting coronary artery stenoses: CORE-64 multicenter international trial," *American Journal of Roentgenology*, vol. 194, no. 1, pp. 93–102, 2010.
- [29] R. Wang, U. J. Schoepf, R. Wu et al., "Diagnostic Accuracy of Coronary CT Angiography," *Journal of Computer Assisted Tomography*, vol. 38, no. 2, pp. 179–184, 2014.
- [30] N. Ahmadi, V. Nabavi, F. Hajsadeghi et al., "Mortality incidence of patients with non-obstructive coronary artery disease diagnosed by computed tomography angiography," *American Journal of Cardiology*, vol. 107, no. 1, pp. 10–16, 2011.
- [31] E. Maffei, C. Martini, C. Tedeschi et al., "Diagnostic accuracy of 64-slice computed tomography coronary angiography in a large population of patients without revascularisation: registry data on the comparison between male and female population," *La radiologia medica*, vol. 117, no. 1, pp. 6–18, 2012.
- [32] E. Maffei, C. Martini, C. Tedeschi et al., "Diagnostic accuracy of 64-slice computed tomography coronary angiography in a large population of patients without revascularisation: registry data on the impact of calcium score," *La radiologia medica*, vol. 116, no. 7, pp. 1000–1013, 2011.
- [33] M. J. Budoff, D. Dowe, J. G. Jollis et al., "Diagnostic performance of 64-multidetector row coronary computed tomographic angiography for evaluation of coronary artery stenosis in individuals without known coronary artery disease: results from the prospective multicenter ACCURACY (Assessment by Coronary Computed Tomographic Angiography of Individuals Undergoing Invasive Coronary Angiography) trial," *Journal of the American College of Cardiology*, vol. 52, no. 21, pp. 1724–1732, 2008.
- [34] J. M. Van Werkhoven, F. Cademartiri, S. Seitun et al., "Diabetes: prognostic value of CT coronary angiography - Comparison with a nondiabetic population," *Radiology*, vol. 256, no. 1, pp. 83–92, 2010.
- [35] G. Montalescot, U. Sechtem, and S. Achenbach, "ESC guidelines on the management of stable coronary artery disease: the Task Force on the management of stable coronary artery disease of the European Society of Cardiology," *European Heart Journal*, vol. 34, no. 38, pp. 2949–3003, 2013.
- [36] NICE Guidelines, *Chest Pain of Recent Onset: Assessment and Diagnosis. Clinical Guideline [CG95]*, 2016, <https://www.nice.org.uk/guidance/cg95>.
- [37] J. K. Min, A. Dunning, F. Y. Lin et al., "Age- and sex-related differences in all-cause mortality risk based on coronary computed tomography angiography findings: results from the international multicenter CONFIRM (Coronary CT Angiography Evaluation for Clinical Outcomes: an International Multicenter Registry) of 23,854 patients without known coronary artery disease," *Journal of the American College of Cardiology*, vol. 58, no. 8, pp. 849–860, 2011.
- [38] W. F. Fearon, B. Bornschein, P. A. Tonino et al., "Economic Evaluation of Fractional Flow Reserve-Guided Percutaneous Coronary Intervention in Patients With Multivessel Disease," *Circulation*, vol. 122, no. 24, pp. 2545–2550, 2010.
- [39] S. Motoyama, H. Ito, M. Sarai et al., "Plaque characterization by coronary computed tomography angiography and the likelihood of acute coronary events in mid-term follow-up," *Journal of the American College of Cardiology*, vol. 66, no. 4, pp. 337–346, 2015.
- [40] A. C. Kwan, K. N. Aronis, V. Sandfort, R. S. Blumenthal, and D. A. Bluemke, "Bridging the gap for lipid lowering therapy: plaque regression, coronary computed tomographic angiography, and imaging-guided personalized medicine," *Expert Review of Cardiovascular Therapy*, vol. 15, no. 7, pp. 547–558, 2017.

- [41] E. Romagnoli, F. Burzotta, F. Giannico, and F. Crea, "Culprit lesion seen 1 hour before occlusion: Limits of coronary angiography in detecting vulnerable plaques," *Circulation*, vol. 113, no. 5, pp. e61–e62, 2006.
- [42] M. Gössl, D. Versari, H. Hildebrandt et al., "Vulnerable Plaque: Detection and Management," *Medical Clinics of North America*, vol. 91, no. 4, pp. 573–601, 2007.
- [43] R. Virmani, A. P. Burke, A. Farb, and F. D. Kolodgie, "Pathology of the vulnerable plaque," *Journal of the American College of Cardiology*, vol. 47, no. 8, pp. C13–C18, 2006.
- [44] A. P. Burke, A. Farb, G. T. Malcom, Y. Liang, J. Smialek, and R. Virmani, "Coronary risk factors and plaque morphology in men with coronary disease who died suddenly," *The New England Journal of Medicine*, vol. 336, no. 18, pp. 1276–1282, 1997.
- [45] A. Farb, A. L. Tang, A. P. Burke, L. Sessums, Y. Liang, and R. Virmani, "Sudden coronary death: Frequency of active coronary lesions, inactive coronary lesions, and myocardial infarction," *Circulation*, vol. 92, no. 7, pp. 1701–1709, 1995.
- [46] R. Virmani, F. D. Kolodgie, A. P. Burke, A. Farb, and S. M. Schwartz, "Lessons from sudden coronary death: a comprehensive morphological classification scheme for atherosclerotic lesions," *Arteriosclerosis, Thrombosis, and Vascular Biology*, vol. 20, no. 5, pp. 1262–1275, 2000.
- [47] M. Naghavi, P. Libby, E. Falk et al., "From vulnerable plaque to vulnerable patient: a call for new definitions and risk assessment strategies: Part I," *Circulation*, vol. 108, no. 14, pp. 1664–1672, 2003.
- [48] E. Falk, P. K. Shah, and V. Fuster, "Coronary plaque disruption," *Circulation*, vol. 92, no. 3, pp. 657–671, 1995.
- [49] E. Braunwald, "Progress in the noninvasive detection of high-risk coronary plaques," *Journal of the American College of Cardiology*, vol. 66, no. 4, pp. 347–349, 2015.
- [50] K. Sakakura, M. Nakano, F. Otsuka, E. Ladich, F. D. Kolodgie, and R. Virmani, "Pathophysiology of atherosclerosis plaque progression," *Heart, Lung and Circulation*, vol. 22, no. 6, pp. 399–411, 2013.
- [51] F. D. Kolodgie, A. P. Burke, A. Farb et al., "The thin-cap fibroatheroma: a type of vulnerable plaque: the major precursor lesion to acute coronary syndromes," *Current Opinion in Cardiology*, vol. 16, no. 5, pp. 285–292, 2001.
- [52] V. Sandfort, J. A. C. Lima, and D. A. Bluemke, "Noninvasive imaging of atherosclerotic plaque progression: status of coronary computed tomography angiography," *Circulation: Cardiovascular Imaging*, vol. 8, no. 7, Article ID e003316, 2015.
- [53] S. Glagov, E. Weisenberg, and C. K. Zarins, "Compensatory enlargement of human atherosclerotic coronary arteries," *The New England Journal of Medicine*, vol. 316, no. 22, pp. 1371–1375, 1987.
- [54] A. P. Burke, F. D. Kolodgie, A. Farb, D. Weber, and R. Virmani, "Role of circulating myeloperoxidase positive monocytes and neutrophils in occlusive coronary thrombi," *Journal of the American College of Cardiology*, vol. 39, p. 256, 2002.
- [55] S. Sugiyama, Y. Okada, G. K. Sukhova, R. Virmani, J. W. Heinecke, and P. Libby, "Macrophage myeloperoxidase regulation by granulocyte macrophage colony-stimulating factor in human atherosclerosis and implications in acute coronary syndromes," *The American Journal of Pathology*, vol. 158, no. 3, pp. 879–891, 2001.
- [56] G. W. Stone, A. Maehara, A. J. Lansky et al., "A prospective natural-history study of coronary atherosclerosis," *The New England Journal of Medicine*, vol. 364, no. 3, pp. 226–235, 2011.
- [57] H. Yabushita, B. E. Bouma, S. L. Houser et al., "Characterization of human atherosclerosis by optical coherence tomography," *Circulation*, vol. 106, no. 13, pp. 1640–1645, 2002.
- [58] P. Raggi, G. Pontone, and D. Andreini, "Role of new imaging modalities in pursuit of the vulnerable plaque and the vulnerable patient," *International Journal of Cardiology*, vol. 250, pp. 278–283, 2018.
- [59] G. Pundziute, J. D. Schuijf, J. W. Jukema et al., "Head-to-head comparison of coronary plaque evaluation between multislice computed tomography and intravascular ultrasound radiofrequency data analysis," *JACC: Cardiovascular Interventions*, vol. 1, no. 2, pp. 176–182, 2008.
- [60] C. Thomsen and J. Abdulla, "Characteristics of high-risk coronary plaques identified by computed tomographic angiography and associated prognosis: A systematic review and meta-analysis," *European Heart Journal—Cardiovascular Imaging*, vol. 17, no. 2, pp. 120–129, 2016.
- [61] S. Schroeder, A. F. Kopp, A. Baumbach et al., "Noninvasive detection and evaluation of atherosclerotic coronary plaques with multislice computed tomography," *Journal of the American College of Cardiology*, vol. 37, no. 5, pp. 1430–1435, 2001.
- [62] K. Otsuka, S. Fukuda, A. Tanaka et al., "Napkin-ring sign on coronary CT angiography for the prediction of acute coronary syndrome," *JACC: Cardiovascular Imaging*, vol. 6, no. 4, pp. 448–457, 2013.
- [63] S. Leschka, S. Seitun, M. Dettmer et al., "Ex vivo evaluation of coronary atherosclerotic plaques: characterization with dual-source CT in comparison with histopathology," *Journal of Cardiovascular Computed Tomography*, vol. 4, no. 5, pp. 301–308, 2010.
- [64] J. Hur, Y. J. Kim, H. Lee et al., "Quantification and characterization of obstructive coronary plaques using 64-Slice computed tomography," *Journal of Computer Assisted Tomography*, vol. 33, no. 2, pp. 186–192, 2009.
- [65] A. G. Van Der Giessen, M. H. Toepker, P. M. Donnelly et al., "Reproducibility, accuracy, and predictors of accuracy for the detection of coronary atherosclerotic plaque composition by computed tomography: An ex vivo comparison to intravascular ultrasound," *Investigative Radiology*, vol. 45, no. 11, pp. 693–701, 2010.
- [66] D. R. Obaid, P. A. Calvert, D. Gopalan et al., "Dual-energy computed tomography imaging to determine atherosclerotic plaque composition: a prospective study with tissue validation," *Journal of Cardiovascular Computed Tomography*, vol. 8, no. 3, pp. 230–237, 2014.
- [67] D. Yamak, P. Panse, W. Pavlicek, T. Boltz, and M. Akay, "Non-calcified coronary atherosclerotic plaque characterization by dual energy computed tomography," *IEEE Journal of Biomedical and Health Informatics*, vol. 18, no. 3, pp. 939–945, 2014.
- [68] K. N. Jin, C. N. De Cecco, and D. Caruso, "Myocardial perfusion imaging with dual energy CT," *European Journal of Radiology*, vol. 85, no. 10, pp. 1914–1921, 2016.
- [69] M. Kidoh, D. Utsunomiya, S. Oda et al., "Evaluation of the effect of intracoronary attenuation on coronary plaque measurements using a dual-phase coronary CT angiography technique on a 320-row CT Scanner—in vivo validation study," *Academic Radiology*, vol. 23, no. 3, pp. 315–320, 2016.
- [70] A. S. Go, M. Dariush, L. R. Ve et al., "American heart association statistics committee and stroke statistics subcommittee disease and stroke statistics—2014 update," *Circulation*, vol. 129, no. 3, pp. e28–e292, 2014.

- [71] M. P. Ostrom, A. Gopal, N. Ahmadi et al., "Mortality Incidence and the Severity of Coronary Atherosclerosis Assessed by Computed Tomography Angiography," *Journal of the American College of Cardiology*, vol. 52, no. 16, pp. 1335–1343, 2008.
- [72] C. Cheruvu, B. Precious, C. Naoum et al., "Long term prognostic utility of coronary CT angiography in patients with no modifiable coronary artery disease risk factors: results from the 5 year follow-up of the confirm international multicenter registry," *Journal of Cardiovascular Computed Tomography*, vol. 10, no. 1, pp. 22–27, 2016.
- [73] C. D. Maroules, C. Hamilton-Craig, K. Branch et al., "The Coronary Artery Disease-Reporting and Data System (CAD-RADS): Prognostic and Clinical Implications Associated With Standardized Coronary Computed Tomography Angiography Reporting," *Journal of Cardiovascular Computed Tomography*, vol. 11, no. 1, pp. 78–89, 2018.
- [74] J. X. Xie, P. Eshtehardi, T. Varghese et al., "Prognostic Significance of Nonobstructive Left Main Coronary Artery Disease in Women Versus Men: Long-Term Outcomes From the CONFIRM (Coronary CT Angiography Evaluation For Clinical Outcomes: An International Multicenter) Registry," *Circulation: Cardiovascular Imaging*, vol. 10, no. 8, 2017.
- [75] E. A. Hulten, S. Carbonaro, S. P. Petrillo, J. D. Mitchell, and T. C. Villines, "Prognostic value of cardiac computed tomography angiography: a systematic review and meta-analysis," *Journal of the American College of Cardiology*, vol. 57, no. 10, pp. 1237–1247, 2011.
- [76] E. Maffei, S. Seitun, C. Martini et al., "Prognostic value of computed tomography coronary angiography in patients with chest pain of suspected cardiac origin," *La radiologia medica*, vol. 116, no. 5, pp. 690–705, 2011.
- [77] E. Maffei, M. Midiri, V. Russo et al., "Rationale, design and methods of CTCA-PRORECAD (Computed Tomography Coronary Angiography Prognostic Registry for Coronary Artery Disease): a multicentre and multivendor registry," *La radiologia medica*, vol. 118, no. 4, pp. 591–607, 2013.
- [78] A. I. Guaricci, G. Pontone, N. D. Brunetti et al., "The presence of remodeled and mixed atherosclerotic plaques at coronary ct angiography predicts major cardiac adverse events — The café-pie study," *International Journal of Cardiology*, vol. 215, pp. 325–331, 2016.
- [79] J. Tian, H. Dauerman, C. Toma et al., "Prevalence and characteristics of TCFA and degree of coronary artery stenosis," *Journal of the American College of Cardiology*, vol. 64, no. 7, pp. 672–680, 2014.
- [80] P. Libby, "Mechanisms of acute coronary syndromes and their implications for therapy," *The New England Journal of Medicine*, vol. 368, no. 21, pp. 2004–2013, 2013.
- [81] P. Libby and G. Pasterkamp, "Requiem for the 'vulnerable plaque,'" *European Heart Journal*, vol. 36, no. 43, pp. 2984–2987, 2015.
- [82] G. Pontone, D. Andreini, A. Baggiano et al., "Functional relevance of coronary artery disease by cardiac magnetic resonance and cardiac computed tomography: myocardial perfusion and fractional flow reserve," *BioMed Research International*, vol. 2015, Article ID 297696, 10 pages, 2015.
- [83] G. I. Cohen, R. Aboufakher, R. Bess et al., "Relationship Between Carotid Disease on Ultrasound and Coronary Disease on CT Angiography," *JACC: Cardiovascular Imaging*, vol. 6, no. 11, pp. 1160–1167, 2013.
- [84] L. La Grutta, M. Marasà, P. Toia et al., "Integrated non-invasive approach to atherosclerosis with cardiac CT and carotid ultrasound in patients with suspected coronary artery disease," *La radiologia medica*, vol. 122, no. 1, pp. 16–21, 2017.
- [85] S. Novo, P. Carità, E. Corrado et al., "Preclinical carotid atherosclerosis enhances the global cardiovascular risk and increases the rate of cerebro- and cardiovascular events in a five-year follow-up," *Atherosclerosis*, vol. 211, no. 1, pp. 287–290, 2010.
- [86] A. I. Guaricci, T. Arcadi, N. D. Brunetti et al., "Carotid intima media thickness and coronary atherosclerosis linkage in symptomatic intermediate risk patients evaluated by coronary computed tomography angiography," *International Journal of Cardiology*, vol. 176, no. 3, pp. 988–993, 2014.
- [87] U. Bulughapitiya, S. Siyambalapatiya, J. Sithole, and I. Idris, "Is diabetes a coronary risk equivalent? Systematic review and meta-analysis: Original Article: Epidemiology," *Diabetic Medicine*, vol. 26, no. 2, pp. 142–148, 2009.
- [88] J.-J. Kim, B.-H. Hwang, I. J. Choi et al., "Impact of diabetes duration on the extent and severity of coronary atheroma burden and long-term clinical outcome in asymptomatic type 2 diabetic patients: evaluation by coronary CT angiography," *European Heart Journal—Cardiovascular Imaging*, vol. 16, no. 10, pp. 1065–1073, 2015.
- [89] N. Chaowalit, A. L. Arruda, R. B. McCully, K. R. Bailey, and P. A. Pellikka, "Dobutamine stress echocardiography in patients with diabetes mellitus: Enhanced prognostic prediction using a simple risk score," *Journal of the American College of Cardiology*, vol. 47, no. 5, pp. 1029–1036, 2006.
- [90] F. B. Sozzi, A. Elhendy, J. R. T. C. Roelandt et al., "Prognostic value of dobutamine stress echocardiography in patients with diabetes," *Diabetes Care*, vol. 26, no. 4, pp. 1074–1078, 2003.
- [91] E. Maffei, S. Seitun, K. Nieman et al., "Assessment of coronary artery disease and calcified coronary plaque burden by computed tomography in patients with and without diabetes mellitus," *European Radiology*, vol. 21, no. 5, pp. 944–953, 2011.
- [92] A. I. Guaricci, V. Lorenzoni, M. Guglielmo et al., "Prognostic relevance of subclinical coronary and carotid atherosclerosis in a diabetic and nondiabetic asymptomatic population," *Clinical Cardiology*, vol. 41, no. 6, pp. 769–777, 2018.
- [93] J. S. Rana, J. Y. Liu, H. H. Moffet, M. Jaffe, and A. J. Karter, "Diabetes and Prior Coronary Heart Disease are Not Necessarily Risk Equivalent for Future Coronary Heart Disease Events," *Journal of General Internal Medicine*, vol. 31, no. 4, pp. 387–393, 2016.
- [94] J. M. van Werkhoven, J. D. Schuijf, O. Gaemperli et al., "Prognostic value of multislice computed tomography and gated single-photon emission computed tomography in patients with suspected coronary artery disease," *Journal of the American College of Cardiology*, vol. 53, no. 7, pp. 623–632, 2009.
- [95] J. D. Schuijf, W. Wijns, J. W. Jukema et al., "Relationship between noninvasive coronary angiography with multi-slice computed tomography and myocardial perfusion imaging," *Journal of the American College of Cardiology*, vol. 48, no. 12, pp. 2508–2514, 2006.
- [96] H.-B. Park, R. Heo, B. Ó Hartaigh et al., "Atherosclerotic plaque characteristics by CT angiography identify coronary lesions that cause ischemia: A direct comparison to fractional flow reserve," *JACC: Cardiovascular Imaging*, vol. 8, no. 1, pp. 1–10, 2015.
- [97] R. Nakazato, H. Park, H. Gransar et al., "Additive diagnostic value of atherosclerotic plaque characteristics to non-invasive FFR for identification of lesions causing ischaemia: results from

- a prospective international multicentre trial," *EuroIntervention*, vol. 12, no. 4, pp. 473–481, 2016.
- [98] S. Gaur, K. A. Øvrehus, D. Dey et al., "Coronary plaque quantification and fractional flow reserve by coronary computed tomography angiography identify ischaemia-causing lesions," *European Heart Journal*, vol. 37, no. 15, pp. 1220–1227, 2016.
- [99] H. Kitabata, J. Leipsic, M. R. Patel et al., "Incidence and predictors of lesion-specific ischemia by FFR CT: Learnings from the international ADVANCE registry," *Journal of Cardiovascular Computed Tomography*, vol. 12, no. 2, pp. 95–100, 2018.
- [100] F. Secchi, M. Ali, E. Faggiano et al., "Fractional flow reserve based on computed tomography: an overview," *European Heart Journal Supplements*, vol. 18, pp. E49–E56, 2016.
- [101] A. Rizvi, B. O. Hartaigh, P. Knaapen et al., "Rationale and design of the CREDENCE trial: computed tomographic evaluation of atherosclerotic Determinants of myocardial Ischemia," *BMC Cardiovascular Disorders*, vol. 16, no. 1, p. 190, 2016.
- [102] A. I. Guaricci, G. Pontone, L. Fusini et al., "Additional value of inflammatory biomarkers and carotid artery disease in prediction of significant coronary artery disease as assessed by coronary computed tomography angiography," *European Heart Journal-Cardiovascular Imaging*, vol. 18, no. 9, pp. 1049–1056, 2017.
- [103] P. M. Ridker, B. M. Everett, T. Thuren et al., "CANTOS trial group. anti-inflammatory therapy with canakinumab for atherosclerotic disease," *The New England Journal of Medicine*, vol. 377, no. 12, pp. 1119–1131, 2017.
- [104] T. B. Arrey-Mbi, S. M. Klusewitz, and T. C. Villines, "Long-term prognostic value of coronary computed tomography angiography," *Current Treatment Options in Cardiovascular Medicine*, vol. 19, no. 12, p. 90, 2017.
- [105] M. S. Bittencourt, E. A. Hulten, V. L. Murthy et al., "Clinical Outcomes after Evaluation of Stable Chest Pain by Coronary Computed Tomographic Angiography Versus Usual Care: A Meta-Analysis," *Circulation: Cardiovascular Imaging*, vol. 9, no. 4, 2016.
- [106] C. Baigent, A. Keech, and P. M. Kearney, "Efficacy and safety of cholesterol-lowering treatment: prospective meta-analysis of data from 90,056 participants in 14 randomised trials of statins," *The Lancet*, vol. 366, no. 9493, pp. 1267–1278, 2005.
- [107] P. M. Ridker, E. Danielson, F. A. Fonseca et al., "Rosuvastatin to prevent vascular events in men and women with elevated C-reactive protein," *The New England Journal of Medicine*, vol. 359, pp. 2195–2207, 2008.
- [108] K. K. Ray and C. P. Cannon, "The potential relevance of the multiple lipid-independent (pleiotropic) effects of statins in the management of acute coronary syndromes," *Journal of the American College of Cardiology*, vol. 46, no. 8, pp. 1425–1433, 2005.
- [109] U. Schönbeck and P. Libby, "Inflammation, immunity, and HMG-CoA reductase inhibitors: statins as anti-inflammatory agents?" *Circulation*, vol. 109, supplement 1, no. 21, pp. I18–I26, 2004.
- [110] S. E. Nissen, E. M. Tuzcu, P. Schoenhagen et al., "Effect of intensive compared with moderate lipid-lowering therapy on progression of coronary atherosclerosis: a randomized controlled trial," *JAMA*, vol. 291, no. 9, pp. 1071–1080, 2004.
- [111] S. E. Nissen, S. J. Nicholls, I. Sipahi et al., "Effect of very high-intensity statin therapy on regression of coronary atherosclerosis: the ASTEROID trial," *The Journal of the American Medical Association*, vol. 295, no. 13, pp. 1556–1565, 2006.
- [112] R. Nakazato, H. Gransar, D. S. Berman et al., "Statins use and coronary artery plaque composition: results from the international multicenter CONFIRM registry," *Atherosclerosis*, vol. 225, no. 1, pp. 148–153, 2012.
- [113] M. Scharfl, W. Bocksch, D. H. Koschyk et al., "Use of intravascular ultrasound to compare effects of different strategies of lipid-lowering therapy on plaque volume and composition in patients with coronary artery disease," *Circulation*, vol. 104, no. 4, pp. 387–392, 2001.
- [114] T. C. Priester and S. E. Litwin, "Measuring progression of coronary atherosclerosis with computed tomography: searching for clarity among shades of gray," *Journal of Cardiovascular Computed Tomography*, vol. 3, no. 2, pp. S81–S90, 2009.
- [115] I. C. Thomas, N. I. Forbang, and M. H. Criqui, "The evolving view of coronary artery calcium and cardiovascular disease risk," *Clinical Cardiology*, vol. 41, no. 1, pp. 144–150, 2018.
- [116] H. Hoffmann, K. Frieler, P. Schlattmann, B. Hamm, and M. Dewey, "Influence of statin treatment on coronary atherosclerosis visualised using multidetector computed tomography," *European Radiology*, vol. 20, no. 12, pp. 2824–2833, 2010.
- [117] Z. Li, Z. Hou, W. Yin et al., "Effects of statin therapy on progression of mild noncalcified coronary plaque assessed by serial coronary computed tomography angiography: A multicenter prospective study," *American Heart Journal*, vol. 180, pp. 29–38, 2016.
- [118] I. Zeb, D. Li, K. Nasir et al., "Effect of statin treatment on coronary plaque progression - A serial coronary CT angiography study," *Atherosclerosis*, vol. 231, no. 2, pp. 198–204, 2013.
- [119] K. Inoue, S. Motoyama, M. Sarai et al., "Serial coronary CT angiography-verified changes in plaque characteristics as an end point: evaluation of effect of statin intervention," *JACC: Cardiovascular Imaging*, vol. 3, no. 7, pp. 691–698, 2010.
- [120] R. Muniyappa, R. Noureldin, K. Abd-Elmoniem et al., "Personalized statin therapy and coronary atherosclerotic plaque burden in asymptomatic low/intermediate-risk individuals," *Cardiorenal Medicine*, vol. 8, no. 2, pp. 140–150, 2018.
- [121] J. R. Nelson, W. S. True, V. Le, and R. P. Mason, "Can pleiotropic effects of eicosapentaenoic acid (EPA) impact residual cardiovascular risk?" *Postgraduate Medical Journal*, vol. 129, no. 8, pp. 822–827, 2017.
- [122] M. Budoff, J. Brent Muhlestein, V. T. Le, H. T. May, S. Roy, and J. R. Nelson, "Effect of Vascepa (icosapent ethyl) on progression of coronary atherosclerosis in patients with elevated triglycerides (200–499 mg/dL) on statin therapy: Rationale and design of the EVAPORATE study," *Clinical Cardiology*, vol. 41, no. 1, pp. 13–19, 2018.
- [123] M. T. Johnstone, A. S. Perez, I. Nasser et al., "Angiotensin receptor blockade with candesartan attenuates atherosclerosis, plaque disruption, and macrophage accumulation within the plaque in a rabbit model," *Circulation*, vol. 110, no. 14, pp. 2060–2065, 2004.
- [124] G. A. Rodriguez-Granillo, S. de Winter, N. Bruining et al., "Effect of perindopril on coronary remodelling: insights from a multicentre, randomized study," *European Heart Journal*, vol. 28, no. 19, pp. 2326–2331, 2007.
- [125] T. Suzuki, T. Nozawa, N. Fujii et al., "Combination therapy of candesartan with statin inhibits progression of atherosclerosis more than statin alone in patients with coronary artery disease," *Coronary Artery Disease*, vol. 22, no. 5, pp. 352–358, 2011.
- [126] K. Vaidya, C. Arnott, G. J. Martínez et al., "Colchicine Therapy and Plaque Stabilization in Patients With Acute Coronary

Syndrome,” *JACC: Cardiovascular Imaging*, vol. 11, no. 2, pp. 305–316, 2018.

- [127] S.-E. Lee, H.-J. Chang, A. Rizvi et al., “Rationale and design of the Progression of Atherosclerotic Plaque Determined by Computed Tomographic Angiography IMaging (PARADIGM) registry: A comprehensive exploration of plaque progression and its impact on clinical outcomes from a multicenter serial coronary computed tomographic angiography study,” *American Heart Journal*, vol. 182, pp. 72–79, 2016.



**Hindawi**

Submit your manuscripts at  
[www.hindawi.com](http://www.hindawi.com)

