




Surgical complications following sentinel lymph node biopsy guided by γ -probe and methylene blue in 113 tumour-bearing dogs

Chiti Lavinia Elena^{1,2} | Gariboldi Elisa Maria¹ | Ferrari Roberta¹  | Luconi Ester³ | Boracchi Patrizia⁴ | De Zani Donatella¹ | Zani Davide¹ | Manfredi Martina¹  | Spediacci Carlotta¹ | Grieco Valeria¹ | Giudice Chiara¹ | Recordati Camilla¹ | Ferrari Francesco¹ | Stefanello Damiano¹ 

¹Dipartimento di Medicina Veterinaria e Scienze Animali, Università degli Studi di Milano, Lodi, Italy

²Unit of Medical Statistics, Biometry and Epidemiology, Department of Biomedical and Clinical Sciences (DIBIC) "L. Sacco", LITA Vialba Campus, Università degli Studi di Milano, Milan, Italy

³Unit of Medical Statistics, Biometry and Epidemiology, Department of Biomedical and Clinical Sciences (DIBIC) "L. Sacco", LITA Vialba campus, Università degli Studi di Milano, Milan, Italy

⁴Unit of Medical Statistics, Biometry and Epidemiology, Department of Biomedical and Clinical Sciences (DIBIC) "L. Sacco" & DSRC, LITA Vialba campus, Università degli Studi di Milano, Milan, Italy

Correspondence

Ferrari Roberta, Dipartimento di Medicina Veterinaria e Scienze Animali, Università degli Studi di Milano, 26900 Lodi, Italy.
Email: roberta.ferrari@unimi.it

Present address

Chiti Lavinia Elena, Klinik für Kleintierchirurgie, Vetsuisse-Fakultät, Universität Zürich, Zurich, Switzerland.

Abstract

Sentinel lymph node biopsy (SLNB) is an accepted veterinary surgical procedure given the impact of early detection of nodal metastases on staging of several canine malignancies. This study aims at reporting the incidence and risk factors for surgical complications of SLNB in tumour-bearing dogs. A total of 113 client-owned dogs that underwent tumour excision and SLNB guided by γ -probing and blue dye were retrospectively enrolled. Recorded variables included: signalment, location and number of extirpated lymphocenters and nodes, time for SLNB, histopathological status of excised nodes. Incidence of SLNB complications was calculated. They were classified as minor and major based on severity and required treatment, and as short-term (0–30 days) and long-term (31–90 days). Univariate analysis with generalized linear model with binomial error estimated the association between variables and incidence of SLNB complications. Significance was set at 5%. Median overall time for SLNB was 25 min. Surgeons excised one node in 38% of dogs and multiple nodes in 62% of cases, belonging to one (62%) or multiple (38%) lymphocenters. Metastases were detected in 45% of nodes. No intraoperative complications occurred. The overall incidence of postoperative complications of SLNB was 21.24%, the majority of which (91.67%) were minor. Only increasing dogs' weight was associated with an increased incidence of SLNB complications ($p = .00976$). Sentinel lymphadenectomy was associated with a relatively low incidence of complications, most of which were self-limiting. The low morbidity and previously reported impact on staging of SLNB justify its implementation to collect data for prognostic studies.

KEYWORDS

canine, complications, lymphadenectomy, sentinel lymph node

This is an open access article under the terms of the [Creative Commons Attribution-NonCommercial-NoDerivs](https://creativecommons.org/licenses/by-nc-nd/4.0/) License, which permits use and distribution in any medium, provided the original work is properly cited, the use is non-commercial and no modifications or adaptations are made.

© 2022 The Authors. *Veterinary and Comparative Oncology* published by John Wiley & Sons Ltd.

1 | INTRODUCTION

Lymphadenectomy has become part of the surgical management of several canine malignancies.^{1–9} Histopathology on the excised nodes is recommended for reliable identification of nodal metastases, given low sensitivity reported for physical examination, cytological sampling and second-level diagnostic imaging.^{10–16} Excision of the anatomically closest node, the regional lymph node (RLN) could also lead to false-negative results due to unpredictable drainage pathways occurring in 22%–63% of tumour-bearing dogs.^{2,4–6,14,17–22} Hence, a surgical approach to the sentinel lymph node (SLN), which is the first node within the lymphatic basin that drains the tumour, has been recently advocated for accurate nodal staging of canine tumours.^{20,21,23,24} Sentinel lymph node biopsy (SLNB) was firstly implemented in dogs with mast-cell tumours (MCT) and led to an upstaging in 42%–60% of cases.^{2,5,17} Likewise, in dogs with malignant tumours of the head and neck SLN metastases were detected in 42% of dogs without clinical evidence of cervical node metastases, and in 46.3% of bitches with mammary tumours.^{4,18} In a recent study, metastases were identified in 45% of dogs undergoing SLNB guided by indirect CT lymphography compared to only 5% of dogs with RLN cytological sampling, influencing treatment decision.¹¹ However, considering a prevalence of SLN metastases of 42%–56%, approximately half of dogs will ultimately undergo the procedure without clear therapeutic benefits.^{2,4,11,25} Ideally dogs at lower risk of having a positive SLN should be identified preoperatively and excluded from SLNB, although based on the current body of literature and the lack of strong evidence to safely support this decision-making process, a surgical approach to the SLN should be suggested for tumours that can spread through the lymphatics, at least for a correct tumour staging following the TNM system.^{24,25} In this scenario, assessment of the morbidity of SLNB is crucial to determine the actual risk–benefit ratio of the procedure.

Complications related to SLNB in dogs have not been systematically reported, although the procedure seems to be well tolerated.^{2,4,5,8,11,26,27} This explorative cohort study aims to retrospectively evaluate the incidence, severity, and risk factors associated with SLNB guided by intraoperative γ -probing and blue dye in dogs with naturally occurring tumours.

2 | MATERIALS AND METHODS

Records of client-owned dogs presented to our oncologic surgery unit with spontaneous solid tumours from March 2017 to October 2021 were revised for inclusion in this retrospective cohort study.

Inclusion criteria were:

1. SLN excision performed under intraoperative guidance (hand-held γ -probe and methylene blue) and concurrently with curative-intent surgical excision of the primary tumour. First presentations, recurrences and infiltrated scars (T0) were included. The mapping procedure was performed only in presence of clinically normal and/or no-palpable lymph nodes.

2. Availability of complete surgical records of SLNB and detailed records of intraoperative and postoperative complications.
3. Follow-up of at least 90 days

At the time of treatment, dogs' owners signed a written consent to the surgical procedure and data collection. All the procedures were carried out following the National requirements for animal welfare. Ethics committee approval was not deemed necessary at our Institution given that dogs were treated with standard-of-care procedures^{2,5,23} and treatment choices were not dictated by the study's purposes (retrospective design).

Dogs admitted to surgery staged negative for distant metastases following the current recommendations for each tumour type.^{5,9,12,28–30} Collected pre-surgical variables included breed, sex, age, weight, Body Condition Score (BCS), number of tumours (single vs multiple), tumour location, size, clinical presentation (first presentation, T0, recurrence), ulceration. Body condition score was reported on a nine-scale³¹ and grouped in three categories (underweight BCS <4; normal weight BCS = 4,5; overweight BCS >5) for statistical purposes. Sentinel lymph node biopsy was performed with intraoperative guidance of a hand-held γ -probe (Crystal probe SG04, Crystal Photonic GmbH, Berlin, Germany) and methylene blue, as previously reported.^{2,4,23} Retrieved variables related to SLNB were: location, laterality and total number of sentinel lymphocenter(s); total number and maximum diameter of excised SLN; time for SLNB (from skin incision to last stitch placement). Tumour type, location and size, and overall surgical time (for tumour excision and SLNB altogether) were also retrieved.

Surgical complications of SLNB were classified as intraoperative, if occurred during anaesthesia, and postoperative, when recorded after recovery from anaesthesia and within the first 90 days after surgery. Based on time of onset and resolution, postoperative complications of SLNB were classified in early (0–30 days postoperatively) and late (31–90 days postoperatively).^{32,33} Complications causing life-threatening events, requiring surgical revision, or causing permanent impairment of normal activities and quality of life were deemed as major complications.³⁴ Furthermore, surgical complications were retrospectively graded according to the VCOG-CTCAEv2 classification.³⁵ To distinguish seroma and lymphoedema the definition of the National Cancer Institute dictionary was used: seroma—A mass or lump caused by a build-up of clear fluid in a tissue, organ or body cavity. It usually goes away on its own; Lymphoedema—A condition in which extra lymph fluid builds up in tissues and causes swelling. It may occur if lymph vessels are blocked, damaged, or removed by surgery, and is most often observed in an arm or leg.

Wound healing complications at the tumour site were recorded and classified following the above-mentioned criteria. In dogs that experience complications of both primary tumour excision and SLNB, a possible relationship was statistically evaluated.

After surgery, dogs were hospitalized for 24 h. Subsequent hospitalization and medical therapies were decided based on the indications of the attending clinician. Surgical rechecks were scheduled at 7, 14 and 30 days postoperatively. If postoperative complications occurred, additional rechecks were planned until complete resolution.

Thereafter, follow-ups were collected during telephone calls with the owner and/or referring veterinarian, or during periodical clinical examination in case of inclusion in adjuvant treatment or owner requirements. Histopathological reports were revised for diagnosis of tumour type and metastatic status of the SLN.

2.1 | Statistical analysis

Descriptive statistics (minimum, maximum, median, mean, standard deviation for numerical variables; frequencies for categorical variable) were used to summarize the distribution of retrieved variables. The overall incidence of SLNB complications, the incidence of major and minor complications and the incidence of complications by anatomical site of the lymphocenter were estimated as the ratio between the number of complications over the number of dogs, as well as over the total of complications. Confidence intervals were calculated with the exact method.³⁶ Univariate analysis (linear generalized model) was performed to evaluate the impact of variables on the prevalence of SLNB. The following variables were included in the models: dogs' age, weight, BCS and breed; number of lymphocenters, total number of SLN per dog, location and laterality of SLN, SLN size, time for SLN biopsy, overall surgical time, complications at the tumour site, presence or absence of SLN metastases. Locations of SLN were grouped as follows: inguinal, popliteal, axillary/accessory axillary, superficial cervical, head and neck (including mandibular, retropharyngeal and parotid nodes) and iliac. In case of MCT, nodes with $HN > 1$ were considered metastatic. Concerning the multivariate variable models, the number of variables to be included was decided according to the event-per-variable (EPV) rule.³² Since a maximum of three variables were allowed, weight, number of sentinel lymphocenters and number of SLN were included based on clinical significance. Both univariate and multivariable analyses were performed with a generalized linear model with binomial error, with occurrence of SLNB complications as the dependent variable. Independent variables were both categorical and numerical: categorical variables were included as dummy variables and numerical variables were included in their original measurement scales. Given that the measure of interest is the incidence of complications, a link log for generalized linear model was used. This allowed to report model results as incidence ratio. For categorical variables one of the categories was considered as reference and the incidence ratio is the ratio between the incidence of each category and the incidence in the reference one. In the case of a numerical variable the incidence ratio is the change of the incidence ratio for each unit increase of the variable. Wald test was performed on each regression coefficient to evaluate the statistical significance of the association between the presence of complication and the independent variable in the model. For numerical variables with more than 6 modalities, the possible contribution of a non-linear association was also tested by likelihood ratio test. As expected, this contribution was not significant due to the low number of complications. Hence, the final model included only the linear effect. Based on multivariate model, a Nomogram was created as a tool for clinicians to easily predict the risk of

complication of lymphadenectomy in a given dog (Appendix–Figure 2).

For each dog, the location of each excised lymphocenter was repeated, and a generalized linear model for repeated measures was used to estimate the incidence of the complications for each location and corresponding 95% confidence interval. This approach allowed to consider the correlation of the SLN on the same dog, when multiple lymphocenters were excised.

The median follow-up time was estimated with the reverse Kaplan–Meier method.

The significance level was set at 0.05%. All the analyses were performed with a software (R-software vers R 4.0.4, packages: rms and PASWR; www.r-project.org).

3 | RESULTS

A total of 113 dogs with 132 tumours were included. Multiple tumours were excised in 13 dogs (11.5%), of which 10 had multiple (2, 3) MCT and 3 had multiple mammary tumours (2–4) that were removed all together through radical mastectomy. Demographics of the sample population and tumours' characteristics are reported in Table 1. Histopathological diagnoses on excised tumours were: 98 (74.2%) MCT (cutaneous $n = 70$; subcutaneous $n = 26$; conjunctival $n = 2$); 10 (7.5%) mammary carcinomas; 7 (5.3%) oral melanomas; 4 (3.0%) mammary adenomas; 4 oral squamous cell carcinoma; 3 (2.3%) cutaneous soft tissue sarcomas; 2 (1.5%) oral fibrosarcoma, 2 oral osteosarcoma, 1 (0.8%) salivary gland carcinoma and 1 thyroid carcinoma.

A 245 SLN belonging to 162 lymphocenters were excised. A single SLN was excised in 43 (38%) dogs and multiple SLN (2 – 7) in 70 (62%) dogs. Location of the sentinel lymphocenter was bilateral in 18 cases (15.9%), and unilateral in 95 cases (left-sided in 49%–43.4% and right-sided in 46%–40.7%), of which 2 cases were contralateral to the tumour. Of the excised SLN, 47(29%) nodes in 40(35%) dogs belonged to the inguinal lymphocenters, 35(22%) in 24 (21%) dogs belonged to the lymphocenters of the head and neck (mandibular, retropharyngeal, parotid), 31 (19%) in 29 (25.6%) dogs to the superficial cervical, 28(17%) in 23(20.4%) dogs to the axillary or pre-axillary, 14 (9%) nodes in 14 (12.4%) dogs to the popliteal and 7(4%) in 6 dogs (5%) to the iliac. The SLN corresponded to the RLN in 90 tumours (68.2%) and occurred at other sites in 42 tumours (31.8%). Size of the SLN was available for 210 (85.7%) nodes, and median size was 12.5 mm (range 1–42 mm). Nodal metastases were histologically detected in 51 of dogs (45%), of which 20 (39%) had an unpredictable SLN. The median overall surgical time was 65 min (range 10–205 min) and median time for lymphadenectomy alone was 25 min (range 5–92 min).

No intraoperative complications occurred. Postoperative complications of the lymphadenectomy are detailed in Table 2. They occurred in 24 dogs, leading to an estimated overall incidence of 21.2% (95% CI 14.11–29.93). Major postoperative complications occurred in 2 dogs, with an estimated incidence of 2.77% (95% CI:

TABLE 1 Population signalment and tumour characteristic: categorical and continuous variables

Categorical variables	Frequency ^a	%		
Breed				
• Mixed-breed	24	21.2		
• Retriever	24	21.2		
• Setter	8	7.1		
• Boxer	6	5.3		
• Dogo argentino	4	3.5		
• Others (<3 dogs each)	47	41.6		
Sex				
• Female	56	49.6		
• Female spayed	45	39.8		
• Male	57	50.4		
• Male castrated	14	12.4		
Body condition score				
• < 4	1	1.4		
• 4–5	28	37.8		
• > 5	45	60.8		
• NA	39	34.5		
Number of tumours				
• 1	100	88.5		
• 2	8 ^b	7.1		
• 3	4 ^c	3.5		
• 4	1 ^d	0.9		
Tumour site				
• Distal limbs	11	9.7		
• Proximal limbs	28	24.8		
• Head and neck	28	24.8		
• Trunk	38	33.6		
• Multiple sites	8	7.1		
Tumour presentation				
• First presentation	121	91.7		
• Recurrence	4	3		
• T0	7	5.3		
Tumour ulceration				
• Present	17	13.6		
• Absent	108	84.6		
• NA	7	5.3		
Continuous variables	Min–max	Std dev.	Mean	Median
Age (years)	0.6–16	3.15	8	8
Weight (Kg)	3–62	13.15	25.2	27.5
Tumour size (cm)	0.1–15.5	2.54	2.6	2

^aFrequency is calculated on the total number of dogs for the variables: breed, sex, body condition score, number of tumours, tumour site, and on the total number of tumours for the variables: presentation and ulceration; NA: not available.

^b6 with MCT and 2 with mammary tumours.

^cAll with MCT.

^dDog with mammary tumour.

0.22–6.25) on the sample population and of 8.3% (95% CI: 1.03–27) on the total complications. Severe seroma formation at the lymphadenectomy site occurred after superficial cervical node extirpation in one dog, and due to lack of improvement with non-steroidal anti-inflammatory drugs and strict rest, surgical revision was performed at 2 weeks with suturing of the deep fascial planes; complete healing was achieved after revision surgery. In the second dog, the superficial cervical, accessory and axillary nodes were removed as SLN of a MCT of the distal limb, and the site of tumour excision was left to heal by second intention; the dog developed severe lymphoedema of the limb that was impairing the healing of the tumour site and required massage under general anaesthesia and compressive bandage every 3 days for 2 weeks. Corticosteroids were also given for 3 weeks (Prednisolone PO 0.5 mg/kg q24 for 1 week then tapered and discontinued in 2 weeks). The lymphoedema resolved uneventfully in 25 days. Minor postoperative complications occurred in 22 dogs, with an estimate incidence of 19.47% (95% CI: 12.62–27.98) on the total of dogs and of 91.7% (95% CI: 73%–98.97%) on the total complications. Minor complications were temporary lymphoedema ($n = 11$), seroma ($n = 10$), hematoma ($n = 3$), superficial dehiscence ($n = 1$). Three dogs had multiple minor complications. The distal limbs ($n = 5$) and muzzle ($n = 4$) were most affected by lymphoedema (Table 2). Applying the VCOG-CTCAEv2 classification, 17 dogs had grade 1, 5 dogs had grade 2, and 2 dogs had grade 3 complications (corresponding to the 2 major complications; Table 2). Time of onset and resolution of SLNB complications were available in all but 7 cases. Overall, complications of the lymphadenectomy occurred at a median of 3 days (range 1–15 days) after surgery and resolved after a median of 8.5 days (range 2–30 days), and were thus all classified as early complications, whereas no late complications occurred. The probability of remaining in the follow-up for the whole study period was greater than 50%, and probability to have a follow-up of 204 or longer was 95.3%.

When considering the location of the excised SLN, the highest incidence of complications was for superficial cervical node(s) (29.03%; 95% CI: 0.17–0.51), while no complications occurred after extirpation of the iliac (Table 3). Among the examined variables, only increasing dogs' weight was associated with an increased incidence of complications of SLNB in univariate analysis ($p = .0098$, prevalence ratio: 1.04; 95% CI: 1.01–1.07) (Table 4). In multivariate model, dog's weight was independently significant ($p = .0073$, prevalence ratio: 1.04; 95% CI: 1.01–1.08) while number of excised SLN and lymphocenters remained non-significant (Table 5). The likelihood of developing complications in association with increasing patient weight is represented in Figure 1.

Complications of the site of tumour excision occurred in 29 cases (25.7%), with minor complications occurring in 19 dogs (16.81%; 95% CI: 10.44–25.01) and major complication in 10 dogs (8.85%; 95% CI: 4.33–15.67). Two dogs were humanely euthanized at 7 and 25 days after extensive surgery of the oral cavity due to the progressively deteriorating clinical conditions resulting from the complication of tumour excision. Nine dogs (7.9%) developed concurrent complications at the lymphadenectomy and tumour excision sites. In univariate

TABLE 2 Complications of sentinel lymphadenectomy recorded in the study population: lymphocenter excised type of complication, onset, duration and treatment

Case	Sentinel lymphocenter	Dog's weight (kg)	Type	Grade ^a	Onset ^c	Duration ^d	Treatment
#1	Inguinal-R	18	Hematoma	1	—	—	None
#2	Inguinal-R	41.5	Hematoma	1	—	—	None
	Inguinal-L		Hematoma	1	—	—	None
	Superficial cervical-R		Seroma	1	—	—	None
#3	Mandibular-L Parotid-L	47	Seroma	1	5	17	None
#4	Superficial cervical-L	36.5	Seroma	1	1	4	None
#5	Superficial cervical-L	41	Seroma	1	2	7	None
#6	Superficial cervical-L	35.5	Seroma	1	5	9	None
#7	Parotid-R	15	Seroma	1	3	7	None
#8	Mandibular-L	42.5	Seroma	1	4	10	None
#9	Superficial cervical-L	55	Seroma	1	3	6	None
			Superficial dehiscence	1			
#10	Superficial cervical-R	28	Seroma	2	15	8	Drainage, NSAIDs
	Axillary-R						
#11	Axillary-L	26	Seroma	1	4	15	NSAIDs
#12	Inguinal-L	34	Lymphoedema (hindlimb and prepuce)	1	—	—	None
#13	Popliteal-R Inguinal-R	27	Lymphoedema (hindlimb and abdomen)	1	—	—	None
#14	Inguinal-L Popliteal-R	33	Lymphoedema (hindlimb)	1	7	—	None
#15	Mandibular-R	45.8	Lymphoedema (muzzle)	2	3	30	NSAIDs
#16	Superficial cervical-L	30	Lymphoedema (neck)	2	7	7	Corticosteroids
#17	Mandibular-R Retropharyngeal-R	29.4	Lymphoedema (muzzle)	1	3	10	None
#18	Mandibular-R	35.9	Lymphoedema (muzzle)	1	5	10	None
#19	Inguinal-L Popliteal-L	18.5	Lymphoedema (hindlimb)	2	9	6	Corticosteroids
#20	Inguinal-L	40.7	Lymphoedema (scrotum)	2	1	12	Cold compresses and local ointment
	Inguinal-R						
#21	Mandibular-R	13.9	Lymphoedema (muzzle)	1	2	4	None
#22	Mandibular-R	5	Lymphoedema (muzzle)	1	2	2	None
#23	Superficial cervical-R	35	Seroma ^b	3	—	—	Surgical revision
#24	Superficial cervical-R	37.4	Lymphoedema (forelimb) ^b	3	2	25	Surgical revision and corticosteroids
	Axillary-R						
	Accessory axillary-R						

^aClassification according to the VCOG-CTCAEv2³⁵; R, right-sided lymphocenter; L, left-sided lymphocenter; —, not available data.

^bMajor complication.

^cDays between surgery and the onset of the complication.

^dDays between the onset of the complication and its resolution; NSAIDs, non-steroidal anti-inflammatory drugs.

TABLE 3 Distribution of sentinel lymph node biopsy complications related to the anatomical site of the excised lymphocenter

Sentinel lymphocenter	Total excised lymphocenters	Complications	Incidence	95% CI
Superficial cervical	31	9	29.03	0.17–0.51
Mandibular, retropharyngeal, parotid	35	10	28.57	0.15–0.55
Popliteal	14	3	21.43	0.08–0.58
Inguinal	47	10	21.28	0.11–0.42
Axillary/Accessory axillary	28	4	14.29	0.05–0.43
Iliac	7	0	0	–

Variables	Prevalence ratio	95% CI	p-value
Age			
Increasing of 1 year	0.92	0.81–1.06	.250
Weight			
Increasing of 1 kg	1.04	1.01–1.07	.0098 ^a
BCS			
Overweight (BCS >5)	0.73	0.28–1.93	.508
Breeds			
Retriever	0.55	0.13–1.52	.310
Setter	1.10	0.43–2.43	.831
Mixed breeds	1.10	0.19–3.12	.889
Sentinel lymphocenters number			
Increasing of 1 lymphocenter	1.11	0.63–1.67	.689
SLN number			
Increasing of 1 SLN	1.05	0.78–1.31	.737
SLN size			
Increasing of 1 cm	1.04	0.98–1.09	.16
SLN status			
Metastatic SLN	0.99	0.44–2.22	.986
Complications of Tumour excision			
Yes	1.79	0.73–3.9	.19
Laterality			
Left	1.22	0.43–5.01	.735
Right	1.43	0.52–5.81	.540
Time of lymphadenectomy			
Increasing of 1 min	1.00	0.98–1.02	.69
Overall surgical time			
Increasing of 1 min	1.01	0.99–1.02	.309

Note: For categorical variables, results are reported as prevalence ratio. For continuous variables results are reported as the prevalence ratio for any unitary increase.

^aStatistically significant at 5% level.

Variables	Incidence ratio	95% CI	p-value
Weight	1.04	1.01–1.08	.0073 ^a
Sentinel lymphocenters number (increasing of 1 lymphocenter)	1.47	0.58–3.55	.4012
SLN (increasing of 1 SLN per dog)	0.91	0.55–1.41	.7005

Note: Results are reported as the incidence ratio for any unitary increase.

^aStatistically significant at 5% level.

TABLE 4 Univariate analysis of risk factors for development of sentinel lymph node biopsy complications: results of linear generalized model**TABLE 5** Multivariate analysis of risk factors for development of sentinel lymph node biopsy complications: results of fine linear generalized model

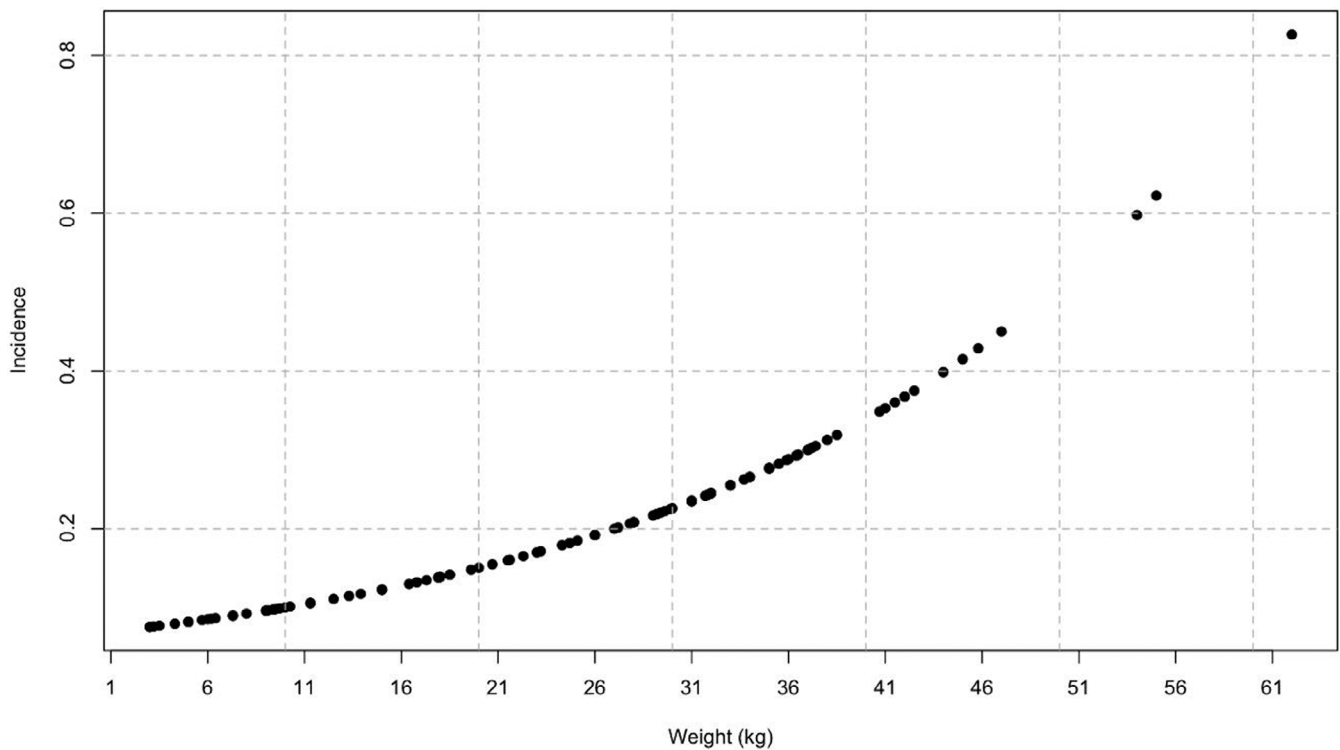


FIGURE 1 Predicted incidence of complications in association with increasing patient's weight (increasing of 1 kg). For a 3 kg dog, the estimated probability of complications of lymphadenectomy is 0.08, this probability increases to 0.18 for a dog that weights 25 kg and to 0.83 for a 62 kg dog.

model, there was no statistical correlation between occurrence of complications at the lymphadenectomy and tumour sites ($p = .19$; prevalence ratio: 1.74; 95% CI: 0.73–3.90) (Table 4).

4 | DISCUSSION

The present study is the first one specifically assessing the incidence and risk factors for surgical complications of SLNB in a large cohort of dogs. No intraoperative or fatal complications were reported. The observed incidence of postoperative complications following SLNB guided by γ -probing and blue dye was 21.2%, of which 91.7% were self-limiting and 8.3% required surgical revision. As there are no studies that have explored the incidence of complications in dogs with lymphadenectomies it is not possible to make a real comparison, however, the incidence of complications found in this study is comparable with complications reported for other clean surgical procedures (range 7.5%–37%).^{37–39} All the dogs that developed a postoperative complication of SLNB recovered uneventfully within the follow-up period, without permanent impairment of normal function or quality of life. The only variable that predicted a higher risk of developing postoperative complications at the lymphadenectomy site was increasing dogs' weight.

The implementation of SLNB in the management of various canine tumours is gaining increasing acceptance, given the impact on staging and treatment choices of early detection of nodal

metastases.^{4,5,9,25} However, the current body of literature is lacking detailed information on the morbidity of lymphadenectomies in cancer-bearing dogs. Worley (2014) firstly described the impact of SLNB with radiopharmaceutical and blue dye in a cohort of 20 dogs with MCT and reported temporary lymphoedema in 5 cases following extirpation of either the popliteal or mandibular nodes.⁵ In two recent investigations on SLNB with γ -probing and blue dye in dogs with MCT and head and neck tumours, no intraoperative complications were reported, whereas postoperative complications occurred in 17% and 27% of dogs, respectively, and consisted of lymphoedema in 3 dogs in each study, seroma in 2 dogs in each study, and surgical site infection with abscess formation in one dog in the MCT study.^{2,4} Lymphoedema of the limbs and seroma were also reported in 2/16 dogs with MCT and in 3/33 bitches with mammary gland tumours, respectively, following SLNB guided by preoperative indirect CT lymphography.^{8,11} Although in the mentioned studies the incidence of postoperative complication is not specifically assessed, the low number of dogs experiencing adverse events related to SLNB is in accordance with the low incidence that we report and corroborates the assumption that the procedure is well tolerated in dogs. Furthermore, in accordance with what observed in the study population, all previously reported postoperative complications resolved either spontaneously or with medical/surgical intervention and did not cause any long-term functional impairment.

In the above-mentioned studies, intraoperative complications (fatal or non-fatal) during SLNB are not reported, which is again in

accordance with the findings of the present study. Conversely, intraoperative complications of lymphadenectomy occurred in 11/125 dogs after the extirpation of the RLN either without intraoperative guidance, guided by methylene blue or by anchor wires in a recent investigation.⁴⁰ It should be noted, however, that intraoperative complications consisted of anchor breakage and methylene blue leakage in the subcutis in all but one dog, and were thus related to the technique used to identify the RLN rather than to the surgical procedure itself; only one dog experienced an intraoperative haemorrhage, and in this case the lymphadenectomy was performed without any intraoperative guidance, suggesting a possible impact of the intraoperative guidance in reducing the risk of intraoperative adverse events.⁴⁰ In the latter investigation, postoperative complications were also reported in only 17/125 and consisted of minor seroma in 9 dogs, wound breakdown in 4 cases, erythema in 2 dogs, cellulitis and surgical site infection in one dog each, all of which resolved within 14 days; again, the low number of adverse events following lymphadenectomies and their transitory nature are in accordance with the results of our study.⁴⁰

In the study population, reversible temporary lymphoedema and seroma were the most common postoperative complications. This result is in accordance with previous reports on SLNB with or without intraoperative guidance in dogs with different tumour types.^{2,4,5,8,11,40} Lymphoedema occurred more frequently to the distal limbs and muzzle in our study. Although comparable data are lacking in the veterinary literature, this observation is partially supported by the longstanding experience in human medicine that identifies lymphoedema of the arms and legs as one of the most common complication after axillary and inguinal/ilioinguinal lymphadenectomies, respectively.^{41,42} In human oncology, complications of lymphadenectomies have been thoroughly investigated, given their potential to permanently impair functionality and the negative impact on quality of life. Seroma and infection are the most reported short-term complications, meaning that they are observed within 30 days after surgery. They can occur in up to 56.8% and 46.7% of patients respectively after radical inguinal and ilioinguinal lymphadenectomy for cutaneous melanoma, while the incidence is reduced to 5.1% and 2.9% when a target approach to the SLN is performed.^{41,43} Lymphoedema is the most reported long-term complication in humans, meaning that it is usually observed later than 30 days. Conversely, in dogs lymphoedema is observed only as a short-term complication. In the study population the median time of complication onset was 3 days, and all adverse events, including lymphoedema, solved within 25 days. Likewise, previous studies reported that all complications related to SLNB in dogs solved within 24 days from surgery.^{2,4,5,8,11,40} In a recent study on a canine model, lymphatic anastomoses between the site of lymphadenectomy and lymph nodes of surrounding areas have been demonstrated.^{44,45} This observation could explain the lack of late and permanent post-operative lymphoedema in dogs, compared to humans, although further studies are needed to clarify the mechanism of lymphatic anastomoses after lymphadenectomy in dogs.

Among the examined variables, only increasing dog's weight was associated with a higher risk of developing postoperative

complications of the lymphadenectomy site, while BCS showed no significant effect. This result is in accordance with a previous report in which an increased risk of postoperative complications of injection-site sarcoma excision was found in cats with higher body weight.³⁵ In people, there are conflicting data regarding the impact of Body Mass Index (BMI).^{32,46} Furthermore, nutrition status in humans seems to have a negligible influence on early complications and to be mainly correlated with an increased risk of late postoperative complications.^{32,46} Hence, it could be argued that our result is due to the lack of long-term complications in the study population. Another possible explanation is that in dogs the development of postoperative complications is influenced by size rather than by nutritional status, meaning that heavier dogs belonging to larger breeds are at higher risk of adverse events compared to small breeds. Although dog's breed was not significant in univariate analysis, it should be noted that for statistical purposes breeds were grouped based on the prevalence in the population and not based on medium weight, which could have been a source of bias. Furthermore, the low number of recorded complications allow for inclusion of BCS in the statistical model as a variable with three modalities only rather than nine, which could also have introduced a bias in our evaluation.

The number of excised SLN is a well-known predictor of short-term postoperative complications of lymphadenectomies in humans.^{32,46} In the present study, we failed to demonstrate a similar correlation. This could be due to the fact that the mapping procedure guided the dissection towards a low number of nodes, with only one SLN removed in 30% of dogs, and more than 3 SLN excised in only 12.4% of cases. Although the location of SLNB could not be included as a variable in the univariate model, the incidence of complications following lymphadenectomy of the superficial cervical lymphocenter seems to be higher compared to other locations. The superficial cervical nodes are located between the lateral aspect of the serratus ventralis and scalenus muscles and cranial to the supraspinatus, and their dissection inevitably results in creation of dead space in an area of movement, thus possibly implying a higher risk of postoperative complications. Prospective, randomized clinical trials are required to statistically address the impact of the site of lymphadenectomy on the risk of developing postoperative complications.

The combination of intraoperative γ -probing and blue dye offers precise guidance during surgical dissection, potentially contributing to the lack of intraoperative complications and the relatively low incidence and mild severity of most postoperative complications that we report. Indeed, radiopharmaceutical involves a preoperative phase with identification of the draining lymphocenter, and an intraoperative phase during which the surgical approach is directed, precisely towards the SLN by a hand-held gamma probe, from skin incision till complete nodal removal. When blue dye is combined, the surgeon could also directly visualize the lymph nodes and easily distinguish them from the surrounding tissues.² With this approach, surgical dissection can be minimized, potentially avoiding unnecessary tissue trauma and reducing the surgical morbidity. In a multicentric trial on complications of SLNB in women with early-staged breast cancer, the authors reported a significantly higher risk of seroma formation when

radiopharmaceutical was used without combining the methylene blue, supporting the assumption that a better intraoperative guidance could reduce the morbidity on SLNB.⁴⁶ Further studies are warranted to assess the impact of the combined technique on the risk of SLNB complications in dogs.

In the study population, 51% of dogs were upstaged following SLNB, and in 45% of those cases, the SLN did not correspond to the clinically expected RLN, meaning that without lymphadenectomy or with traditional RLN extirpation a significant proportion of dogs would have been incorrectly staged and potentially undertreated. This result is consistent with previous studies that reported an upstaging after SLN mapping in 42%–60% of dogs with MCT, in 42% of dogs with malignancies of the head and neck, and in 46.3% of bitches with mammary tumours.^{2,4,5,8,17} Although non-metastatic nodes were ultimately excised in nearly half of dogs of the study population, the low morbidity that we report suggest an acceptable benefit to risk ratio and justify wider exploration of SLNB in veterinary practice, at least until the prognostic weight of the procedure would be further clarified and defined for each tumour-type.

ACKNOWLEDGEMENT

Open Access Funding provided by Università degli Studi di Milano within the CRUI-CARE Agreement.

FUNDING INFORMATION

None.

CONFLICT OF INTEREST

The authors declare the absence of conflicts of interest.

DATA AVAILABILITY STATEMENT

The data that support the findings of this study are available from the corresponding author upon reasonable request.

ORCID

Ferrari Roberta  <https://orcid.org/0000-0002-7960-6165>

Manfredi Martina  <https://orcid.org/0000-0002-1721-3884>

Stefanello Damiano  <https://orcid.org/0000-0003-2726-0366>

REFERENCES

- Ferrari R, Marconato L, Buracco P, et al. The impact of extirpation of non-palpable/normal-sized regional lymph nodes on staging of canine cutaneous mast cell tumours: a multicentric retrospective study. *Vet Comp Oncol*. 2018;16(4):505-510. doi:10.1111/vco.12408
- Ferrari R, Chiti LE, Manfredi M, et al. Biopsy of sentinel lymph nodes after injection of methylene blue and lymphoscintigraphic guidance in 30 dogs with mast cell tumors. *Vet Surg*. 2020;49(6):1099-1108. doi:10.1111/vsu.13483
- Weishaar KM, Thamm DH, Worley DR, Kamstock DA. Correlation of nodal mast cells with clinical outcome in dogs with mast cell tumour and a proposed classification system for the evaluation of node metastasis. *J Comp Pathol*. 2014;151(4):329-338. doi:10.1016/j.jcpa.2014.07.004
- Chiti LE, Stefanello D, Manfredi M, et al. To map or not to map the cNO neck: impact of sentinel lymph node biopsy in canine head and neck tumours. *Vet Comp Oncol*. 2021;19(4):661-670. doi:10.1111/vco.12697
- Worley DR. Incorporation of sentinel lymph node mapping in dogs with mast cell tumours: 20 consecutive procedures. *Vet Comp Oncol*. 2014;12(3):215-226. doi:10.1111/j.1476-5829.2012.00354.x
- Skinner OT, Boston SE, de Souza CHM. Patterns of lymph node metastasis identified following bilateral mandibular and medial retropharyngeal lymphadenectomy in 31 dogs with malignancies of the head. *Vet Comp Oncologia*. 2017;15(3):881-889. doi:10.1111/vco.12229
- Mendez SE, Drobatz KJ, Duda LE, White P, Kubicek L, Sorenmo KU. Treating the locoregional lymph nodes with radiation and/or surgery significantly improves outcome in dogs with high-grade mast cell tumours. *Vet Comp Oncol*. 2020;18(2):239-246. doi:10.1111/vco.12541
- Soultani C, Patsikas MN, Mayer M, et al. Contrast enhanced computed tomography assessment of superficial inguinal lymph node metastasis in canine mammary gland tumors. *Vet Radiol Ultrasound*. 2021;62(5):557-567. doi:10.1111/vru.13002
- Baginski H, Davis G, Bastian RP. The prognostic value of lymph node metastasis with grade 2 MCTs in dogs: 55 cases (2001–2010). *J Am Anim Hosp Assoc*. 2014;50(2):89-95. doi:10.5326/JAAHA-MS-5997
- Langenbach A, McManus PM, Hendrick MJ, Shofer FS, Sorenmo KU. Sensitivity and specificity of methods of assessing the regional lymph nodes for evidence of metastasis in dogs and cats with solid tumours. *J Am Vet Med Assoc*. 2001;218(9):1424-1428. doi:10.2460/javma.2001.218.1424
- Lapsley J, Hayes GM, Janvier V, et al. Influence of locoregional lymph node aspiration cytology vs sentinel lymph node mapping and biopsy on disease stage assignment in dogs with integumentary mast cell tumours. *Vet Surg*. 2021;50(1):133-141. doi:10.1111/vsu.13537
- Skinner OT, Boston SE, Giglio RF, Whitley EM, Colee JC, Porter EG. Diagnostic accuracy of contrast-enhanced computed tomography for assessment of mandibular and medial retropharyngeal lymph node metastasis in dogs with oral and nasal cancer. *Vet Comp Oncol*. 2018;16(4):562-570. doi:10.1111/vco.12415
- Grimes JA, Secrest SA, Wallace ML, Laver T, Schmiedt CW. Use of indirect computed tomography lymphangiography to determine metastatic status of sentinel lymph nodes in dogs with a pre-operative diagnosis of melanoma or mast cell tumour. *Vet Comp Oncol*. 2020;18(4):818-824. doi:10.1111/vco.12592
- Grimes JA, Mestrinho LA, Berg J, et al. Histologic evaluation of mandibular and medial retropharyngeal lymph nodes during staging of oral malignant melanoma and squamous cell carcinoma in dogs. *Small Animals & Exotic*. 2019;254(8):938-943. doi:10.2460/javma.254.8.938
- Fournier Q, Cazzini P, Bavcar S, Pecceu E, Ballber C, Elders R. Investigation of the utility of lymph node fine-needle aspiration cytology for the staging of malignant solid tumors in dogs. *Vet Clin Pathol*. 2018;47(3):489-500. doi:10.1111/vcp.12636
- Ku CK, Kass PH, Christopher MM. Cytologic-histologic concordance in the diagnosis of neoplasia in canine and feline lymph nodes: a retrospective study of 367 cases. *Vet Comp Oncol*. 2017;15(4):1206-1217. doi:10.1111/vco.12256
- Fournier Q, Thierry F, Longo M, et al. Contrast-enhanced ultrasound for sentinel lymph node mapping in the routine staging of canine mast cell tumours: a feasibility study. *Vet Comp Oncol*. 2021;19(3):451-462. doi:10.1111/vco.12647
- Collivignarelli F, Tamburro R, Aste G, et al. Lymphatic drainage mapping with indirect lymphography for canine mammary tumours. *Animals*. 2021;11(4):1115. doi:10.3390/ani11041115
- Beserra HEO, Grandi F, Dufloth RM, et al. Metastasis of mammary carcinoma in bitches: evaluation of the sentinel lymph node technique. *Adv Breast Cancer Res*. 2016;5(2):58-65. doi:10.4236/abcr.2016.52006

20. Beer P, Pozzi A, Rohrer Bley C, Bacon N, Pfammatter NS, Venzin C. The role of sentinel lymph node mapping in small animal veterinary medicine: a comparison with current approaches in human medicine. *Vet Comp Oncol*. 2018;16(2):178-187. doi:10.1111/vco.12372
21. Liptak JM, Boston SE. Nonselective lymph node dissection and sentinel lymph node mapping and biopsy. *Vet Clin North Am Small Anim Pract*. 2019;49(5):793-807. doi:10.1016/j.cvsm.2019.04.003
22. Herring ES, Smith MM, Robertson JL. Lymph node staging of Oral and maxillofacial neoplasms in 31 dogs and cats. *J Vet Dent*. 2002; 19(3):122-126. doi:10.1177/089875640201900301
23. Manfredi M, de Zani D, Chiti LE, et al. Preoperative planar lymphoscintigraphy allows for sentinel lymph node detection in 51 dogs improving staging accuracy: feasibility and pitfalls. *Vet Radiol Ultrasound*. 2021;62(5):602-609. doi:10.1111/vru.12995
24. Tuohy JL, Milgram J, Worley DR, Dernel WS. A review of sentinel lymph node evaluation and the need for its incorporation into veterinary oncology. *Vet Comp Oncol*. 2009;7(2):81-91. doi:10.1111/j.1476-5829.2009.00183.x
25. Ferrari R, Boracchi P, Chiti LE, et al. Assessing the risk of nodal metastases in canine integumentary mast cell tumours: is sentinel lymph node biopsy always necessary? *Animals*. 2021;11(8):2373. doi:10.3390/ani11082373
26. Grimes JA, Secrest SA, Northrup NC, Saba CF, Schmiedt CW. Indirect computed tomography lymphangiography with aqueous contrast for evaluation of sentinel lymph nodes in dogs with tumours of the head. *Vet Radiol Ultrasound*. 2017;58(5):559-564. doi:10.1111/vru.12514
27. Rossanese M, Pierini A, Pisani G, et al. Ultrasound-guided placement of an anchor wire or injection of methylene blue to aid in the intraoperative localization and excision of peripheral lymph nodes in dogs and cats. *J Am Vet Med Assoc*. 2022;260(S1):S75-S82. doi:10.2460/javma.20.09.0499
28. Stefanello D, Valenti P, Faverzani S, et al. Ultrasound-guided cytology of spleen and liver: a prognostic tool in canine cutaneous mast cell tumor. *J Vet Intern Med*. 2009;23(5):1051-1057. doi:10.1111/j.1939-1676.2009.0354.x
29. Finora K, Leibman NF, Fettman MJ, Powers BE, Hackett TA, Withrow SJ. Cytological comparison of fine needle aspirates of liver and spleen of Normal dogs and of dogs with cutaneous mast cell tumours and an ultrasonographically normal appearing liver and spleen. *Vet Comp Oncol*. 2006;4(3):178-183. doi:10.1111/j.1476-5829.2006.00107.x
30. Congiusta M, Lawrence J, Rendahl A, Goldschmidt S. Variability in recommendations for cervical lymph node pathology for staging of canine oral neoplasia: a survey study. *Front Vet Sci*. 2020;7:506. doi:10.3389/fvets.2020.00506
31. Chun JL, Bang HT, Ji SY, et al. A simple method to evaluate body condition score to maintain the optimal body weight in dogs. *J Anim Sci Technol*. 2019;61(6):366-370. doi:10.5187/jast.2019.61.6.366
32. Wever L, de Vries HM, Dell'Oglio P, et al. Incidence and risk factor analysis of complications after sentinel node biopsy for penile cancer. *BJU Int*. 2022;130:486-495. doi:10.1111/bju.15725
33. Gould N, Kamelle S, Tillmanns T, et al. Predictors of complications after inguinal lymphadenectomy. *Gynecol Oncol*. 2001;82(2):329-332. doi:10.1006/gyno.2001.6266
34. Cantatore M, Ferrari R, Boracchi P, et al. Factors influencing wound healing complications after wide excision of injection site sarcomas of the trunk of cats. *Vet Surg*. 2014;43(7):783-790. doi:10.1111/j.1532-950X.2014.12217.x
35. LeBlanc AK, Atherton M, Bentley RT, et al. Veterinary cooperative oncology group-common terminology criteria for adverse events (VCOG-CTCAE v2) following investigational therapy in dogs and cats. *Vet Comp Oncol*. 2021;19(2):311-352. doi:10.1111/vco.12677
36. Clopper CJ, Pearson ES. The use of confidence or fiducial limits illustrated in the case of the binomial. *Biometrika*. 1934;26(4):404. doi:10.2307/2331986
37. Muraro L, White RS. Complications of ovariohysterectomy procedures performed in 1880 dogs. *Tierarztl Prax Ausg K Kleintiere Heimtiere*. 2014;42:297-302.
38. Evans BJ, Holt DE, Stefanovski D, Sorenmo KU. Factors influencing complications following mastectomy procedures in dogs with mammary gland tumours: 140 cases (2009-2015). *J Am Vet Med Assoc*. 2021;258(3):295-302. doi:10.2460/javma.258.3.295
39. Rossanese M, German AJ, Comerford E, Pettitt R, Tomlinson A, de Vicente F. Complications following surgical correction of medial patellar luxation in small-to-medium-size dogs. *Vet Comp Orthop Traumatol*. 2019;32(4):332-340. doi:10.1055/s-0039-1683872
40. Rossanese M, Pierini A, Pisani G, et al. Ultrasound-guided placement of an anchor wire or injection of methylene blue to aid in the intraoperative localization and excision of peripheral lymph nodes in dogs and cats. *Am Vet Med Assoc*. 2021;260(S1):75-82. doi:10.2460/javma.20.09.0499
41. Söderman M, Thomsen J, Sørensen JA. Complications following inguinal and ilioinguinal lymphadenectomies: a meta-analysis. *J Plast Surg Hand Surg*. 2016;50(6):315-320. doi:10.3109/2000656X.2016.1173560
42. Manca G, Tardelli E, Rubello D, et al. Sentinel lymph node biopsy in breast cancer: a technical and clinical appraisal. *Nucl Med Commun*. 2016;37(6):570-576. doi:10.1097/MNM.0000000000000489
43. Moody JA, Ali RF, Carbone AC, Singh S, Hardwicke JT. Complications of sentinel lymph node biopsy for melanoma—a systematic review of the literature. *Eur J Surg Oncol*. 2017;43(2):270-277. doi:10.1016/j.ejso.2016.06.407
44. Suami H, Scaglioni MF, Dixon KA, Taylor RC. Interaction between vascularized lymph node transfer and recipient lymphatics after lymph node dissection—a pilot study in a canine model. *J Surg Res*. 2016; 204(2):418-427. doi:10.1016/j.jss.2016.05.029
45. Hlusko KC, Cole R, Tillson DM, et al. The effect of surgery on lymphoscintigraphy drainage patterns from the canine brachium in a simulated tumor model. *Vet Surg*. 2020;49(6):1118-1124. doi:10.1111/vsu.13473
46. Wilke LG, McCall LM, Posther KE, et al. Surgical complications associated with sentinel lymph node biopsy: results from a prospective international cooperative group trial. *Ann Surg Oncol*. 2006;13(4):491-500. doi:10.1245/ASO.2006.05.013

How to cite this article: Elena CL, Maria GE, Roberta F, et al. Surgical complications following sentinel lymph node biopsy guided by γ -probe and methylene blue in 113 tumour-bearing dogs. *Vet Comp Oncol*. 2022;1-11. doi:10.1111/vco.12861

APPENDIX A: Nomogram (Figure 2)

A nomogram can be used to predict the risk of SLN biopsy complications based on the variables included in multivariate analysis: weight, number of lymphocenters and total number of excised SLN.

For a given dog, the values of weight, number of lymphocenters and number of SLN are identified on the corresponding scale of the Nomogram. Three lines are then drawn starting from the identified values and hitting perpendicularly the 'Point' axis on the Nomogram. Obtained values on the 'Point' axis for each variable are then summed and the resulting value is identified on the "Total points" axis. The probability of the developing surgical complications after SLN biopsy for the

dog is identified on the 'Predictor value' axis by drawing a perpendicular line starting from the resulting value on the 'Total points' axis.

For example, a dog of 25 kg with 3 SLN belonging to 3 different lymphocenters removed, receives 38 points for "weight", 26 points

for "number of lymphocenters" and 12 for "number of SLN", leading to a total of 76 points and to an associated probability of developing complications of the lymphadenectomy site of around 0.30.