



## Case Report

## A novel *RRM2B* mutation associated with mitochondrial DNA depletion syndrome

Monica Fumagalli<sup>a,b,1</sup>, Dario Ronchi<sup>c,1</sup>, Maria Francesca Bedeschi<sup>d</sup>, Arianna Manini<sup>c</sup>, Gloria Cristofori<sup>a</sup>, Fabio Mosca<sup>a,b</sup>, Robertino Dilella<sup>e</sup>, Monica Sciacco<sup>f</sup>, Simona Zanotti<sup>f</sup>, Daniela Piga<sup>g</sup>, Gianluigi Ardissino<sup>h</sup>, Fabio Triulzi<sup>c,i</sup>, Stefania Corti<sup>c,g</sup>, Giacomo P. Comi<sup>c,f,\*</sup>, Leonardo Salvati<sup>j,k</sup>

<sup>a</sup> Fondazione IRCCS Cà Granda Ospedale Maggiore Policlinico, Neonatal Intensive Care Unit, Milan, Italy

<sup>b</sup> University of Milan, Department of Clinical Sciences and Community Health, Milan, Italy

<sup>c</sup> Dino Ferrari Center, Department of Pathophysiology and Transplantation, University of Milan, Milan, Italy

<sup>d</sup> Fondazione IRCCS Cà Granda Ospedale Maggiore Policlinico, UOD Medical Genetics, Milan, Italy

<sup>e</sup> Fondazione IRCCS Cà Granda Ospedale Maggiore Policlinico, UO Neurophysiology, Milan, Italy

<sup>f</sup> Fondazione IRCCS Cà Granda Ospedale Maggiore Policlinico, Neuromuscular and Rare Disease Unit, Milan, Italy

<sup>g</sup> Fondazione IRCCS Cà Granda Ospedale Maggiore Policlinico, Neurology Unit, Milan, Italy

<sup>h</sup> Fondazione IRCCS Cà Granda Ospedale Maggiore Policlinico, UO Nefrologia, Dialisi E Trapianto Pediatrico, Milan, Italy

<sup>i</sup> Fondazione IRCCS Cà Granda Ospedale Maggiore Policlinico, Unit of Neuroradiology, Milan, Italy

<sup>j</sup> Clinical Genetics Unit, Department of Women's and Children's Health, and Myology Center, University of Padova, Padova, Italy

<sup>k</sup> IRP Città della Speranza, Padova, Italy

## ARTICLE INFO

## Keywords:

Mitochondrial DNA depletion  
RRM2B  
Ribonucleotide reductase  
Mitochondrial encephalomyopathy  
Next generation sequencing

## ABSTRACT

Mitochondrial DNA (mtDNA) depletion syndromes are disorders characterized by infantile-onset, severe progression, and the drastic loss of mtDNA content in affected tissues. In a patient who showed severe hypotonia, proximal tubulopathy and sensorineural hearing loss after birth, we observed severe mtDNA depletion and impaired respiratory chain activity in muscle due to heterozygous variants c.686G > T and c.551-2A > G in *RRM2B*, encoding the p53R2 subunit of the ribonucleotide reductase.

### 1. Introduction

In mitochondrial DNA (mtDNA) depletion syndromes (MDDS), the loss of mtDNA content severely affects mitochondrial respiratory chain activity, thus impairing the energetic balance of either a specific tissue (most commonly muscle, liver and brain) or of multiple organs. [1]

MDDS usually display neonatal or infantile-onset and a rapid progression, resulting in death in the first years of life. [2] Loss of function mutations have been detected in several genes encoding for proteins involved in mtDNA maintenance. [2] In proliferating tissues, mtDNA replication mainly relies on cytosolic deoxyribonucleotides (dNTPs) metabolism, which is cell-cycle dependent. Instead, in postmitotic cells, dNTPs supply is guaranteed by a dedicated set of mitochondrial enzymes belonging to the dNTPs salvage pathway. [3] The regulatory subunit of

the p53-inducible ribonucleotide reductase (p53R2), encoded by the *RRM2B* gene, takes part in the cytoplasmic *de novo* conversion of ribonucleoside diphosphates into the corresponding deoxyribonucleoside diphosphates. [4] Biallelic *RRM2B* mutations have been mainly associated with infantile-onset myopathic MDDS with renal proximal tubulopathy, sensorineural deafness and neurological deterioration. [5,6] An adult case presenting mitochondrial neurogastrointestinal encephalopathy (MNGIE) was also associated to recessive *RRM2B* variants. [7] Heterozygous *RRM2B* mutations have been also described in adult patients showing a mild myopathic phenotype and an accumulation of multiple mtDNA deletions in skeletal muscles. [8]

Here we present the clinical, molecular, and biochemical findings of an Italian patient, who presented at birth with hypotonia, progressive

\* Corresponding author at: Neuromuscular and Rare Diseases Unit, Department of Neuroscience, Fondazione IRCCS Ca' Granda Ospedale Maggiore Policlinico, Milan 20122, Italy.

E-mail address: [giacomo.comi@unimi.it](mailto:giacomo.comi@unimi.it) (G.P. Comi).

<sup>1</sup> These authors equally contributed to this work.

<https://doi.org/10.1016/j.ymgmr.2022.100887>

Received 21 April 2022; Received in revised form 10 June 2022; Accepted 10 June 2022

Available online 18 June 2022

2214-4269/© 2022 The Authors. Published by Elsevier Inc. This is an open access article under the CC BY-NC-ND license (<http://creativecommons.org/licenses/by-nc-nd/4.0/>).

muscle weakness, and severe proximal tubulopathy, and died after 64 days due to multiorgan failure.

## 2. Materials and methods

The “Comitato Etico Milano Area 2 Fondazione IRCCS Ca’ Granda Ospedale Maggiore Policlinico” (Milan, Italy) approved the study, and the parents of the proband provided written informed consent. Molecular analysis was carried out using the Illumina TruSight ONE kit and an Illumina NextSeq 550 sequencer as described. [9] Variant calling and bioinformatic analysis were performed using the Illumina Variant Studio Software, and were filtered using a list of 390 mitochondria-related genes (the list is available upon request). Variants were confirmed by Sanger sequencing. Southern blot, quantitative polymerase chain reaction (qPCR) of mtDNA and spectrophotometric analysis of muscle mitochondrial respiratory chain complex activities were performed as previously described. [10]

## 3. Case presentation and results

The female proband was the first child of non-consanguineous Italian parents. Family history was negative for neurological disorders. After an uneventful gestation, the mother developed mild fever at the end of pregnancy, and cardiotocography monitoring showed trace alterations, so that an emergency cesarean section was performed at 42 weeks of gestation. The Apgar score was 8/10 at the 1st and 5th minutes. The birthweight was 3530 g. As a 13% weight loss was recorded on the third day after birth, intravenous infusion of 5% glucose solution and complementary feeding with standard Formula were introduced, with no clinical benefit. The newborn showed progressive worsening of neurological performance including poor suck, mild hypotonia, and lethargy and was transferred to our unit at day 12 after birth. Glycosuria and proteinuria were detected at urine test strips, and metabolic acidosis with fluctuating hyperlactacidemia, ranging between 2 and 12 mmol/L (normal values 0.6–1.8), was shown by arterial and capillary blood gas analyses. Mean daily plasma lactate levels from admission (day 12 of postnatal age) are shown in Fig. 1A. Echocardiography, cerebral and kidney ultrasound scans were normal. The Brainstem Auditory Evoked Responses revealed a severe bilateral deficit consistent with sensorineural deafness. Neonatal brain magnetic resonance imaging (MRI), performed 27 days after birth, showed diffuse white matter hyperintensity on T2-weighted imaging, reduced subarachnoid spaces and slit-like ventricles, possibly due to vasogenic edema (Fig. 1B). Diffusion-weighted imaging (DWI) and proton magnetic resonance spectroscopy (<sup>1</sup>H-MRS) were normal. The clinical status progressively worsened during the first 6 weeks of life, with marked generalized hypotonia, hyposthenia, loss of deep tendon reflexes, respiratory failure, and arousal deterioration. Mild slowing of background activity was reported at the electroencephalography. 42 days after birth, nerve conduction studies (NCS) revealed a mild reduction of compound muscle action potential amplitude of the median and ulnar nerves with normal sensory conduction parameters, whereas needle electromyography showed myopathic changes. A muscle biopsy performed on day 44 of postnatal age demonstrated lipids accumulation (Fig. 1C), normal staining for Succinate Dehydrogenase (SDH) activity and the total loss of Cytochrome c Oxidase (COX) activity, as documented by double COX/SDH staining (Fig. 1D).

Despite the active correction of metabolic acidosis and other supportive treatments, a progressive respiratory insufficiency led to exitus 64 days after birth.

Clinical exome sequencing, performed in parallel with muscle biopsy, revealed two compound heterozygous mutations in *RRM2B* (NM\_015713) in the proband: c.551-2A > G inherited from the father, and the c.686G > T (p.Gly229Val), inherited from the mother.

The c.551-2A > G mutation is absent from public databases. It is predicted to disrupt an acceptor splice site, thus resulting in skipping of

exon 6 with loss of the canonical reading frame. This prediction was confirmed at molecular level by RT-PCR analysis of *RRM2B* transcript in proband's muscle, which showed a lower band corresponding to the skipping of exon 6 likely resulting in the partial degradation of the aberrant splicing transcript by nonsense-mediated mRNA decay (Fig. 1E).

The p.Gly229Val mutation has been previously reported as pathogenic. [11] This rare variant (gnomAD MAF  $1.6 \times 10^{-5}$ ) affects a highly conserved glycine in an alpha-helix region likely involved in the catalytic activity of p53R2.

Southern blot and qPCR analysis documented mtDNA depletion in patient's muscle, similarly to what was observed in the muscle of *TK2* MDDS patients affected by early-onset myopathy (Fig. 1F). [10] Biochemical activities of mtDNA-dependent respiratory chain complexes I, III and IV were dramatically reduced in proband's muscle (Fig. 1G).

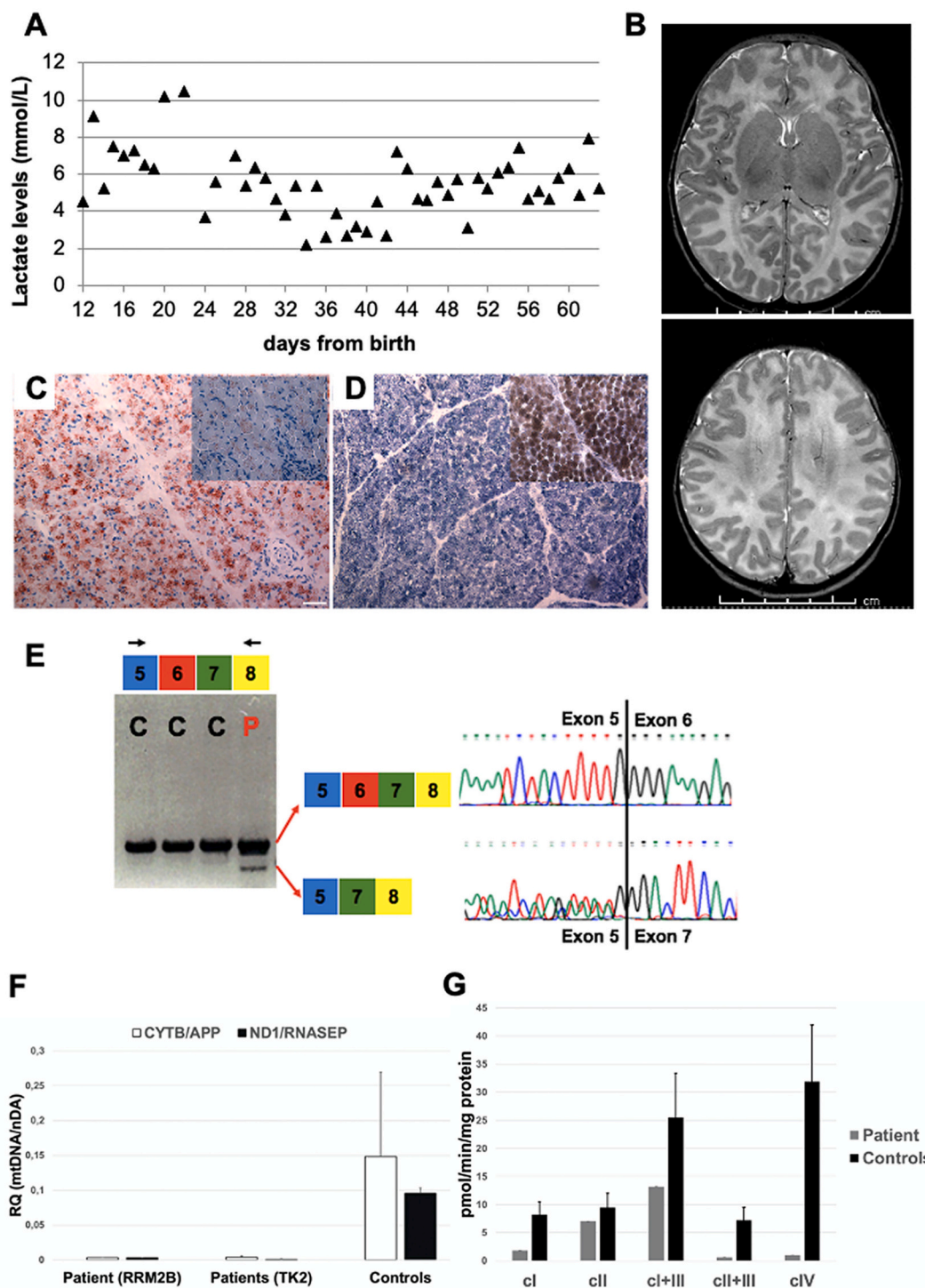
## 4. Discussion

Mitochondrial DNA maintenance defects are associated with a variety of neurological and systemic manifestations, including myopathy, progressive external ophthalmoparesis (PEO), ptosis, parkinsonism, gastrointestinal disturbances, bulbar dysfunction, seizures and sensorineural deafness. [2,12]

We report a patient affected by neonatal-onset MDDS with compound heterozygous *RRM2B* mutations, who presented with myopathy, proximal tubulopathy and sensorineural deafness. To date, >30 cases of infantile-onset *RRM2B* deficiency have been reported. Patients usually present with truncal hypotonia, generalized weakness, and early failure to thrive. [13] Seizures and non-neurological manifestations are often observed, including respiratory distress, renal tubulopathy, sensorineural hearing loss and gastrointestinal disturbances. [13] In our case, the diagnostic process was supported by several factors in addition to the clinical picture: severe loss of COX activity at COX/SDH double staining, impaired activity of mtDNA-encoded respiratory chain complexes, severe mtDNA depletion (levels <2% of age-matched controls). The p. Gly229Val mutation has been previously detected in two Sudanese siblings, who died in infancy, and in a Caucasian patient, affected by severe hypotonia, seizures and sensorineural deafness. [11,14] In all cases, massive mtDNA loss was observed in muscle. [11,14] On the contrary, the c.551-2A > G mutation is novel and results in exon 6 skipping. According to the American College of Medical Genetics and Genomics (ACMG) guidelines, the c.551-2A > G variant, meeting pathogenicity criteria PVS1, PM2 and PM3, can be classified as “pathogenic” (ACMG Class 5). [15]

In *RRM2B*-mutated patients, the residual mtDNA levels, which reflect the ribonucleotide reductase activity, have been correlated with the clinical phenotype. [16] Specifically, null alleles are associated with severe mtDNA depletion in muscle and early-onset presentation with multisystemic signs and symptoms, which lead to death soon after birth. [13] Missense biallelic mutations, otherwise, have been detected in childhood-onset cases (mean age at onset, 7 years) with severe and multisystem disorders, longer post-onset survival and accumulation of multiple mtDNA deletions at muscle biopsy. [16] In a single adult case, a MNGIE-like presentation was associated to recessive *RRM2B* missense mutations causing moderate muscle mtDNA depletion. Finally, dominantly-inherited heterozygous variants have been linked to late-onset (mean age at onset 46 years) milder forms of myopathy, characterized by PEO, ptosis, proximal muscle weakness, bulbar dysfunction, and multiple mtDNA deletions in muscle. [16]

Consistently with previous genotype-phenotype correlation studies, we provided further evidence that the combination of a null allele and a catalytic site mutation causes severe early-onset MDDS characterized by encephalomyopathy, respiratory insufficiency, renal impairment, and hearing loss. [13,16] Overall, we suggest considering *RRM2B* screening when the clinical suspicion is high, even prior to muscle biopsy. Indeed,



**Fig. 1.** (A) Proband's daily plasma lactate levels from birth. (B) T2-weighted (T2W) turbo spin-echo (TSE) MRI images performed at 41 weeks from birth reveal diffuse white matter hyperintensity likely due to vasogenic edema. (C) Oil Red O staining in patient shows a marked lipids accumulation (insert: Oil Red O staining on age-matched control muscle section). (D) Double staining for SDH and COX activities showed the complete absence of COX activity in the patient (insert: double staining for SDH and COX activities on age-matched control biopsy). Magnification 20 $\times$ . Scale bar 50  $\mu$ m. (E) RT-PCR analysis of muscle-derived *RRM2B* cDNA encompassing Exons 5 and 8. Patient's lane (P) shows a shorter band compared to controls (C). Sequence electropherograms of the amplicons disclose the physiological (top) and abnormal (down) splicing event. (F) Quantitative PCR analysis of muscle-extracted DNA by using two independent duplex assays for the simultaneous detection of mitochondrial and nuclear DNA (CYTB/APP and ND1/RNASEP). The bars indicate Relative Quantification levels of mitochondrial DNA content normalized to nuclear DNA. Age matched healthy controls ( $n = 10$ ) and *TK2*-mutated patients ( $n = 3$ ) are shown for comparison. (G) Respiratory chain complex activities normalized to the matrix enzyme Citrate Synthase. Values are expressed as pmol/min/mg proteins. Control values are indicated as mean  $\pm$  standard deviation.

molecular testing might precede (and often make unnecessary) invasive procedures, especially in pediatric patients. On the other hand, we stress the relevance of muscle biopsy to sustain the diagnosis of primary mitochondrial dysfunction and, in cases like ours, to provide material for biochemical and molecular studies (including a reliable assessment of mtDNA content) required to support the pathogenicity of novel *RRM2B* variants. In this scenario, a targeted NGS gene panel approach can be used to investigate simultaneously multiple mtDNA maintenance-related genes, including *TK2*, for which a disease-modifying therapy is currently under investigation. [17]

### Ethics statement

The “Comitato Etico Milano Area 2 Fondazione IRCCS Ca’ Granda Ospedale Maggiore Policlinico” (Milan, Italy) approved the study, and the parents of the proband provided written informed consent.

### Data availability statement

Data that support the findings of this study are available upon request.

### Funding

This study was supported by Fondazione Cariplo (Project 2014–1010 to D.R.), Italian Telethon (Grant GSP16001 to G.P.C.), partially funded by Italian Ministry of Health - Current research IRCCS (to G.P.C.) and by a grant from Fondazione IRP Città della Speranza to L.S. This work was promoted within the European Reference Network (ERN) for Neuro-muscular Diseases.

### Conflict of interest

The authors declare that they have no conflict of interest.

### Author contributions

MF, DR and GC interpreted the results, conceived the idea, revised the literature, and wrote the manuscript. GC, MFB, MF, FM and GA performed clinical assessment. RD performed neurophysiological studies. FT performed neuroradiological studies. DR and LS performed genetic analysis. DP performed mtDNA studies. MS and SZ performed histological studies on muscle. SC, GPC and LS performed a critical revision of the manuscript for important intellectual content. All the authors have read and approved the manuscript.

### Acknowledgements

We thank the Associazione Centro Dino Ferrari for its support. Muscle biopsy and DNA samples were provided by the Bank of muscle tissue, peripheral nerve, DNA, and Cell Culture, member of Telethon Network of Genetic biobanks, at Fondazione IRCCS Ca’ Granda, Ospedale Maggiore Policlinico, Milano, Italy.

### References

- [1] A. Spinazzola, F. Invernizzi, F. Carrara, E. Lamantea, A. Donati, M. DiRocco, I. Giordano, M. Meznaric-Petrusa, E. Baruffini, I. Ferrero, M. Zeviani, Clinical and

- molecular features of mitochondrial DNA depletion syndromes, *J. Inher. Metab. Dis.* 32 (2009) 143–158, <https://doi.org/10.1007/s10545-008-1038-z>.
- [2] C. Viscomi, M. Zeviani, mtDNA-maintenance defects: syndromes and genes, *J. Inher. Metab. Dis.* 40 (2017) 587–599, <https://doi.org/10.1007/s10545-017-0027-5>.
- [3] L. Wang, Mitochondrial purine and pyrimidine metabolism and beyond, *Nucleosides Nucleotides Nucleic Acids* 35 (2016) 578–594, <https://doi.org/10.1080/15257770.2015.1125001>.
- [4] D.S. Byun, K.S. Chae, B.K. Ryu, M.G. Lee, S.G. Chi, Expression and mutation analyses of p53R2, a newly identified p53 target for dna repair in human gastric carcinoma, *Int. J. Cancer* 98 (2002) 718–723, <https://doi.org/10.1002/ijc.10253>.
- [5] A. Bourdon, L. Minai, V. Serre, J.-P. Jais, E. Sarzi, S. Aubert, D. Chrétien, P. de Lonlay, V. Paquis-Flucklinger, H. Arakawa, Y. Nakamura, A. Munnich, A. Rötig, Mutation of *RRM2B*, encoding p53-controlled ribonucleotide reductase (p53R2), causes severe mitochondrial DNA depletion, *Nat. Genet.* 39 (2007) 776–780, <https://doi.org/10.1038/ng2040>.
- [6] B. Acham-Roschitz, B. Plecko, F. Lindbichler, R. Bittner, C.J. Mache, W. Sperl, J. A. Mayr, A novel mutation of the *RRM2B* gene in an infant with early fatal encephalomyopathy, central hypomyelination, and tubulopathy, *Mol. Genet. Metab.* 98 (2009) 300–304, <https://doi.org/10.1016/j.ymgme.2009.06.012>.
- [7] A. Shaibani, O.A. Shchelochkov, S. Zhang, P. Katsonis, O. Lichtarge, L.J. Wong, M. Shinawi, Mitochondrial neurogastrointestinal encephalopathy due to mutations in *RRM2B*, *Arch. Neurol.* 66 (2009) 1028–1032, <https://doi.org/10.1001/archneurol.2009.139>.
- [8] C. Fratter, P. Raman, C.L. Alston, E.L. Blakely, K. Craig, C. Smith, J. Evans, A. Sella, B. Czermin, M.G. Hanna, J. Poulton, C. Brierley, T.G. Staunton, P. D. Turnpenny, A.M. Schaefer, P.F. Chinnery, R. Horvath, D.M. Turnbull, G. S. Gorman, R.W. Taylor, *RRM2B* mutations are frequent in familial PEO with multiple mtDNA deletions, *Neurology* 76 (2011) 2032–2034, <https://doi.org/10.1212/wnl.0b013e31821e558b>.
- [9] M. Mainardi, L. Lerjefors, G. Bonato, C. Bertolin, L. Salviati, M. Carecchio, An adult patient with 3-methylglutaconic aciduria type 1 and movement disorders, *J. Neurol.* (2022), <https://doi.org/10.1007/s00415-022-10999-y>.
- [10] S. Galbiati, A. Bordoni, D. Papadimitriou, A. Toscano, C. Rodolico, E. Katsarou, M. Sciacco, A. Garufi, A. Prella, M. Aguenouz, M. Bonsignore, M. Crimi, A. Martinuzzi, N. Bresolin, A. Papadimitriou, G.P. Comi, New Mutations in *TK2* Gene Associated With, 2006, pp. 177–185, <https://doi.org/10.1016/j.pediatrneurol.2005.07.013>.
- [11] G. Kollberg, N. Darin, K. Benan, A.R. Moslemi, S. Lindal, M. Tulinius, A. Oldfors, E. Holme, A novel homozygous *RRM2B* missense mutation in association with severe mtDNA depletion, *Neuromuscul. Disord.* 19 (2009) 147–150, <https://doi.org/10.1016/j.nmd.2008.11.014>.
- [12] A. Manini, E. Abati, G. Pietro Comi, S. Corti, D. Ronchi, Mitochondrial DNA homeostasis impairment and dopaminergic dysfunction: a trembling balance, *Ageing Res. Rev.* 76 (2022), 101578, <https://doi.org/10.1016/j.arr.2022.101578>.
- [13] N. Keshavan, J. Abdenur, G. Anderson, Z. Assouline, G. Barcia, L. Bouhikbar, A. Chakrapani, M. Cleary, M.C. Cohen, F. Feillet, C. Fratter, N. Hauser, T. Jacques, A. Lam, H. McCullagh, R. Phadke, A. Rötig, M. Sharrard, M. Simon, C. Smith, E. W. Sommerville, R.W. Taylor, W.W. Yue, S. Rahman, The natural history of infantile mitochondrial DNA depletion syndrome due to *RRM2B* deficiency, *Genet. Med.* (2019), <https://doi.org/10.1038/s41436-019-0613-z>.
- [14] K. Iwanicka-Pronicka, E. Ciara, D. Piekutowska-Abramczuk, P. Palat, M. Pajdowska, M. Pronicki, Congenital cochlear deafness in mitochondrial diseases related to *RRM2B* and *SERAC1* gene defects. A study of the mitochondrial patients of the CMHI hospital in Warsaw, Poland, *Int. J. Pediatr. Otorhinolaryngol.* 121 (2019) 143–149, <https://doi.org/10.1016/j.ijporl.2019.03.015>.
- [15] S. Richards, N. Aziz, S. Bale, D. Bick, S. Das, J. Gastier-Foster, W.W. Grody, M. Hegde, E. Lyon, E. Spector, K. Voelkerding, H.L. Rehm, Standards and guidelines for the interpretation of sequence variants: a joint consensus recommendation of the American College of Medical Genetics and Genomics and the Association for Molecular Pathology, *Genet. Med.* 17 (2015) 405–424, <https://doi.org/10.1038/gim.2015.30>.
- [16] R.D.S. Pitceathly, C. Smith, C. Fratter, C.L. Alston, L. He, K. Craig, E.L. Blakely, J. C. Evans, J. Taylor, Z. Shabbir, M. Deschauer, U. Pohl, M.E. Roberts, M.C. Jackson, C.A. Halpenny, P.D. Turnpenny, P.W. Lunt, M.G. Hanna, A.M. Schaefer, R. McFarland, R. Horvath, P.F. Chinnery, D.M. Turnbull, J. Poulton, R.W. Taylor, G.S. Gorman, Adults with *RRM2B*-related mitochondrial disease have distinct clinical and molecular characteristics, *Brain* 135 (2012) 3392–3403, <https://doi.org/10.1093/brain/aws231>.
- [17] C. Domínguez-González, M. Madruga-Garrido, F. Mavillard, C. Garone, F. J. Aguirre-Rodríguez, M.A. Donati, K. Kleinstaub, I. Martí, E. Martín-Hernández, J.P. Morealejo-Aycinena, F. Munell, A. Nascimento, S.G. Kalko, M.D. Sardina, C. Álvarez del Vayo, O. Serrano, Y. Long, Y. Tu, B. Levin, J.L.P. Thompson, K. Engelstad, J. Uddin, J. Torres-Torronteras, C. Jimenez-Mallebrera, R. Martí, C. Paradas, M. Hirano, Deoxynucleoside therapy for thymidine kinase 2-deficient myopathy, *Ann. Neurol.* 86 (2019) 293–303, <https://doi.org/10.1002/ana.25506>.