

Short Case Report

Diode laser as local treatment for oral Kaposi's sarcoma in HIV young patient: a case report

Niccolò Lombardi^{1,*}, Elena Varoni¹, Laura Moneghini², Giovanni Lodi¹

¹ Dipartimento di Scienze Biomediche, Chirurgiche ed Odontoiatriche, Università degli Studi di Milano, Milan, Italy

² ASST Santi Paolo e Carlo, Presidio Ospedaliero San Paolo, Human Pathology Unit, Milan, Italy

(Received: 19 February 2021, accepted: 21 February 2021)

Keywords:
Kaposi's sarcoma /
diode laser /
oral cancer / HIV

Abstract – Introduction: Kaposi's sarcoma (KS) is a malignant mucocutaneous neoplasm caused by human herpesvirus 8 (HHV-8). Four types of KS exist and, in each of them, the patient could develop skin and visceral lesions. Surgical excision, radiotherapy, intralesional chemotherapy and systemic chemotherapy are widely accepted as treatment options. **Observation:** The aim of this paper is to present diode laser as minimally invasive procedure in management of oral KS. We report here a case of multiple oral lesions of acquired immunodeficiency syndrome (AIDS)-associated KS, which has been solely treated with diode laser. **Discussion:** There is no bibliography on local treatment of oral KS with diode laser and this clinical case appears to be the first regarding this technique. **Conclusion:** This conservative approach, in association with highly active antiretroviral therapy (HAART), is safe and effective, shows fewer side effects than chemotherapy, radiotherapy and surgical excision and may be evaluated as potential treatment for oral KS.

Observation

A 33-year-old man was referred to the unit of oral medicine for multiple intra-oral lesions developed approximately eight months before. Six months before our examination, he had received diagnosis of HIV-infection (center for disease control and prevention stage C3), associated to pneumocystis jirovecii pneumonia (PCP), genital herpes and CD4 count of 30/mm³ and viral load of 13 300 copies/ml. He declared unprotected homosexual behavior and referred that the last HIV-test had been performed 9-years before. Genital herpes and PCP resolved after therapy with aciclovir and atovaquone. Thanks to HAART, CD4 count recovered up to 245/mm³ and viral load was not detectable (<20 copies/ml). The patient reported an initial reducing in lesions' size following HAART. Then, the clinical picture became stable for months till our visit.

At the intraoral examination, three painless, red-purplish, papular and nodular lesions of the hard-palate mucosa were detected (Fig. 1). The lesions did not blanch on diascopic examination and had a variable size from 7 to 15 mm.

An incisional diagnostic biopsy was performed with putative diagnosis of multiple AIDS-related oral Kaposi's sarcoma (KS). Differential diagnosis included hemangiomas,

vascular malformations, hematological and mesenchymal malignancies. Histopathological analysis confirmed the diagnosis of oral KS (Fig. 2).

Gastroscopy, colonoscopy and chest computed tomography were performed, not detecting any other lesions. Evaluating the absence of systemic involvement, local treatment with diode laser was planned. Continuously emission of 3W energy was released by a 320 μm fiber. The tip was moved slowly over the lesion with no contact to the palatal mucosa, at a distance of 1–2 mm, leading to transmucosal thermocoagulation. The treatment was repeated in three consecutive sessions, two weeks apart. At nine months follow-up, the complete blood count revealed stable CD4 count (266/mm³) and not detectable viral load (<20 copies/ml). Clinically, the palatal mucosa showed complete healing and absence of recurrence (Fig. 3).

Discussion

KS is a mucocutaneous malignant angioproliferative tumour of endothelial origin [1]. Cutaneous lesions may occur alone or associated to visceral manifestations of the disease involving the oral cavity or the pulmonary and gastrointestinal tracts [1]. Human herpesvirus 8 (HHV-8) has been identified as causative agent of almost all cases of Kaposi's sarcoma [1,2]. Four clinical forms of KS have been identified: classic or Mediterranean, epidemic or AIDS-related, iatrogenic or post-transplant, and

* Correspondence: niccolo.lombardi@unimi.it

endemic or African [1]. Epidemic KS is the most frequent type and has an unfavorable prognosis in absence of therapy [1]. It more commonly occurs in the context of advanced HIV-related immunodepression, but it could seldom represent the first manifestation of HIV infection [1].

Involvement of the oral cavity occurs in up to 71% of AIDS-related KS cases and oral KS manifestations appear as initial sign of the disease in 22% of them [1-3]. Epidemic oral KS have a wide range of clinical presentation which may vary from slow- to fast-growing masses [1]. The first oral signs may appear as ecchymotic patches which evolve to papular, nodular, and exophytic lesions presenting a color that can vary from dark reddish to purplish blue [1,2]. The most frequent affected intra-oral sites are the hard-palatal mucosa (50%) and the

gingiva (28%) [3]. Size of the lesions varies from few millimeters to some centimeters and the growing of multiple lesions could lead to large, confluent masses involving an entire area of the oral cavity [1,3]. Oral KS affecting the palate and gingiva should be considered in differential diagnosis with other lesions such as pyogenic granuloma, peripheral giant cell granuloma, haemangioma, haematological and mesenchymal neoplasms [3,4].

Local surgery and highly active antiretroviral therapy (HAART) are considered keystones in the management of epidemic KS [1].

HAART is able to prevent systemic spreading of KS, on the other hand the local therapy is essential in the management of patients affected by oral KS [1-3].

The therapeutic approach could range from surgical excision to radiotherapy, local or systemic chemotherapy and potential related side effects should be considered during the therapeutic selection [1-3]. Systemic chemotherapy is indicated just in cases of advanced disease and it's often associated with severe adverse effects as myelosuppression, opportunistic infections, alopecia, gastrointestinal toxicity and peripheral neuropathy [1]. Oral KS has been demonstrated to be highly responsive to radiotherapy, which may give, unfortunately, important side-effects such as severe mucositis, pain, dysgeusia and hyposalivation [1]. Intralesional injections of vinblastine, have been effective for local treatment of mucocutaneous lesions, but the procedure is painful and associated with the potential risk of necrosis and ulceration of the surrounding healthy tissues [1]. Isolated and superficial mucocutaneous lesions are susceptible to surgical excision, while diffuse or multifocal KS are not suitable for this option due to potential functional impairment of the tissues and

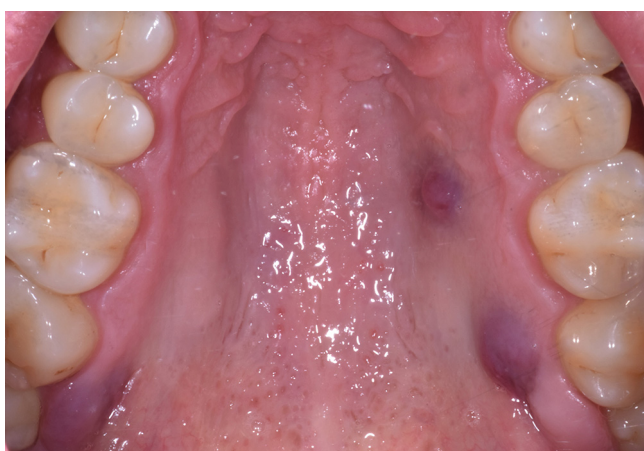

Fig. 1. Occlusal view of three painless, red-purplish, papular and nodular lesions of the hard-palate mucosa.

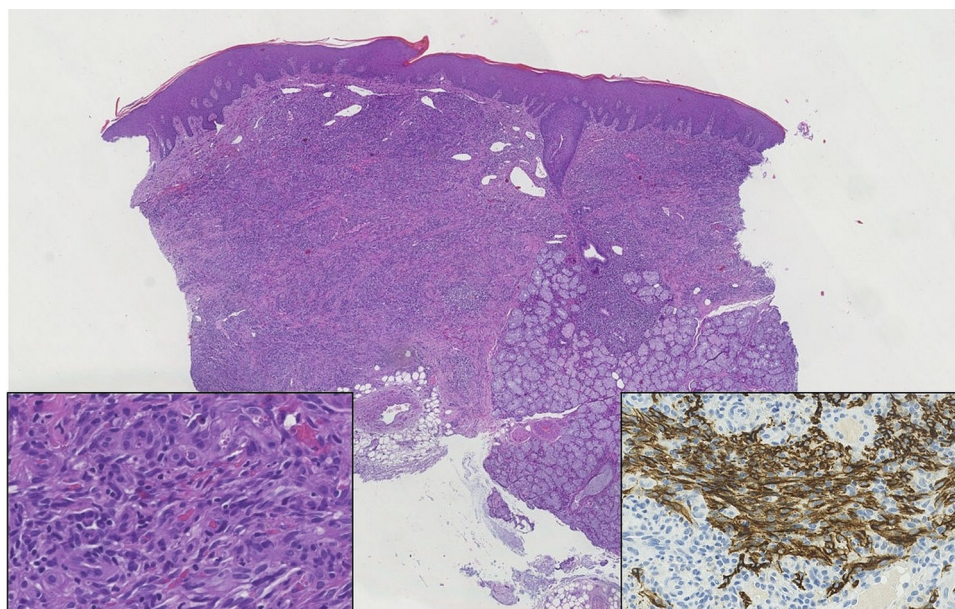


Fig. 2. Panoramic histological aspect of the sample; the typical aspects with spindle cells with cytoplasmic hyaline globules (inset on the left) and immunohistochemical positivity for podoplanin (inset on the right).

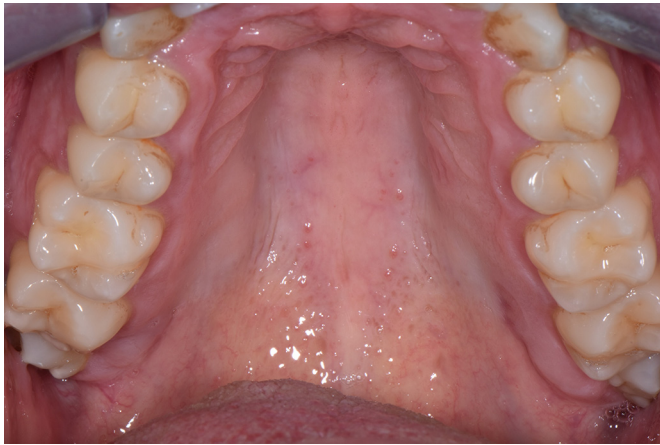

Fig. 3. Complete healing and absence of recurrence at 6-months follow-up.

development of multiple scars [1–3]. In case of isolated oral lesions with no widespread involvement, surgical excision and CO₂ laser ablation have proven to be effective treatment options which may lead to complete resolution of the disease [1,2].

The use of diode laser is widely reported for vascular oral lesions, such as hemangiomas, with high rate of success, low recurrences and minimal side-effects [5]. The energy emitted by diode laser is highly absorbed by hemoglobin into the lesion and may lead to a photocoagulation process down to a depth of 7–10 mm in the tissues [5]. Diode laser-based surgery is a safe procedure, easy to use even on large vascular lesions. Diode laser guarantees a reduced intra-operative bleeding, it leads to minimal post-operative discomfort for the patient and the following scars are minimal with no evidence of tissue retraction [5]. The major disadvantage of this technique is the need of multiple laser sessions to achieve the complete removal of the lesions.

This case report seems to be the first which describe the use of diode laser, with transmucosal thermocoagulation, as solely local treatment for multiple oral KS.

Local treatment of oral KS with diode-laser appears effective, safe and associated to reduced intra and post-operative bleeding risk. This procedure, guaranteeing a minimally invasive approach, is not associated with the side effects of chemotherapy or radiotherapy, and may be considered among treatment alternatives in the management of isolated oral KS.

Funding

This research did not receive any specific grant from funding agencies in the public, commercial, or not-for-profit sectors.

Conflicts of interest

Authors have no conflict of interests to disclose.

Informed consent

Data and sample were collected under patient's informed written consent.

References

1. Fatahzadeh M. Kaposi sarcoma: review and medical management update. *Oral Surg. Oral Med. Oral Pathol. Oral Radiol.* 2012;113: 2–16.
2. Lombardi N, Varoni E, Sardella A, Lodi G. Oral Kaposi's sarcoma in a HIV-negative young patient. *Oral Oncol.* 2020;103:104567.
3. Sanchez IM, DiTommaso LE, Tsoukas MM, Oral Kaposi Sarcoma. *JAMA Dermatology* 2019;155:370.
4. Lombardi N., Flora A, Franchini R, Sorrentino D, Lodi G, Varoni EM. Gingival localisation of extramedullary multiple myeloma. *Lancet Oncol.* 2019;20:e653.
5. Jasper J, Camilotti RS, Pagnoncelli RM, Poli VD, da Silveira Gerzson A, Gavin Zakszeski AM. Treatment of lip hemangioma using forced dehydration with induced photocoagulation via diode laser: report of three cases. *Oral Surg. Oral Med. Oral Pathol. Oral Radiol.* 2015;119:e89–e94.