J Oral Med Oral Surg 2021;27:33
https://doi.org/10.1051/mbcb/2021008

https://www.jomos.org

JOMOS
Journal of Oral Medicine and Oral Surgery

Short Case Report

Maxillary extrafollicular adenomatoid odontogenic tumor: root resorption and involvement of the maxillary sinus and nasal cavity

Lombardi Niccolò[1,2,*], Sorrentino Daniela[1], Bianchi Arianna[1], Nicali Andrea[1,2], Moneghini Laura[3], Cucurullo Marco[4], Rabbiosi Dimitri[4]

[1] Università degli Studi di Milano, Dipartimento di Scienze Biomediche Chirurgiche e Odontoiatriche, Milan, Italy
[2] ASST Santi Paolo e Carlo, Ospedale San Paolo, UO Odontostomatology II, Milan, Italy
[3] ASST Santi Paolo e Carlo, Ospedale San Paolo, UO Human Pathology, Milan, Italy
[4] ASST Santi Paolo e Carlo, Ospedale San Paolo, UO Maxillofacial Surgery, Milan, Italy

(Received: 13 March 2021, accepted: 1 April 2021)

Keywords:
Adenomatoid odontogenic tumor / odontogenic cysts / oral surgery

Abstract – Adenomatoid odontogenic tumor (AOT) is a benign, slow-growing lesion and it is considered the fourth most common odontogenic tumor. AOT affects more frequently the young subjects with a predilection for the second and third decades of life. We present here the case of a 36-year-old man affected by large extrafollicular AOT which caused roots resorption of multiple teeth. The lesion involved the entire right maxillary bone and extended into the right maxillary sinus up to the orbital floor and the nasal cavity. Intra-oral surgical excision of the AOT and functional endoscopic sinus surgery led to complete clinical healing in absence of local recurrences.

Observation

A 36-year-old man came to our department of oral medicine for right facial swelling neither associated with painful symptoms nor fever. The patient reported that the swelling had arose approximately one month before in association with homolateral rhinorrhea. The general practitioner prescribed antibiotic therapy (amoxicillin 1 g twice daily) which did not lead to relevant improvement of the local swelling.

At the extra-oral examination facial deformity was detectable in absence of cervical lymphadenopathy. At intra-oral examination a painless, hard and firm submucosal swelling was observed in the buccal alveolar fornix of the right maxilla, extending from the right lateral incisor to the homolateral first molar. Dental pulp vitality and percussion tenderness were tested for each tooth of the upper right maxilla achieving a non-pathological response for each of them. Indeed, both right upper premolars showed first degree mobility at clinical examination.

An orthopantomography and a maxillary CT were right away performed, revealing a wide osteolytic lesion spreading into the right maxillary sinus and extending up to the right orbital floor and to the homolateral nasal cavity (Fig. 1). The lesion, extended from the central right incisor to the last right molar, caused root resorptions of premolars and molars teeth. Considering the clinical presentation and radiographic picture, an incisional biopsy of the bone lesion was carried out on the same day of first visit.

The histopathological analysis led to diagnosis of intra-osseous extrafollicular cystic adenomatoid odontogenic tumour (AOT), showing characteristic duct-like structures and eosinophilic tumor droplets material. Immunohistochemical profile was positive for cytokeratin (CK) 5/6, CK 14 and CK 9, while Ki67 quantification was $<1\%$.

Considering the lesion's extension up to the orbital floor and to the nasal right cavity, surgical resection and functional endoscopic sinus surgery (FESS) were planned. The intraoral surgical access allowed the complete excision of the maxillary lesion while FESS improved the sinus ventilation and nasal drainage (Fig. 2).

At six-month follow-up, despite root resorptions, all the teeth preserved vitality, and complete clinical healing in absence of local recurrences were observed (Fig. 3).

Discussion

Adenomatoid odontogenic tumor (AOT) is a benign, slow-growing odontogenic tumor characterized by microscopic duct-like structures [1,2]. AOT is considered the fourth most common odontogenic tumor, accounting for 2.2–7.1% of them [1–3].

* Correspondence: niccolo.lombardi@unimi.it

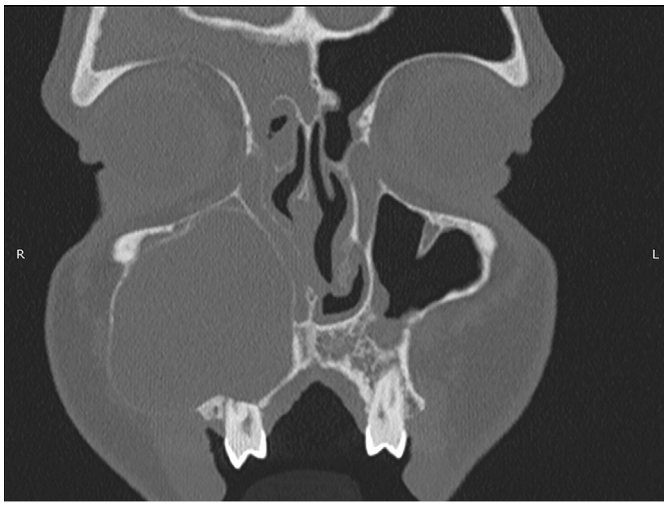

(a)

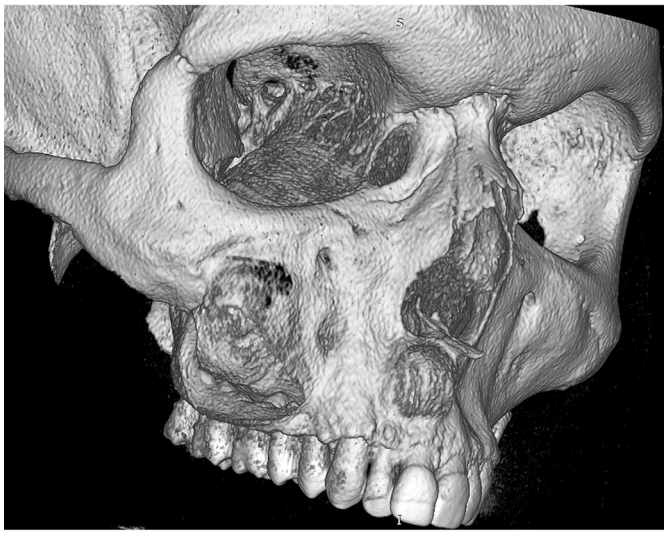

(b)

Fig. 1. The maxillofacial-CT showed a wide well-defined *osteolytic* lesion of the right maxillary; coronal (a) and 3D (b) views.

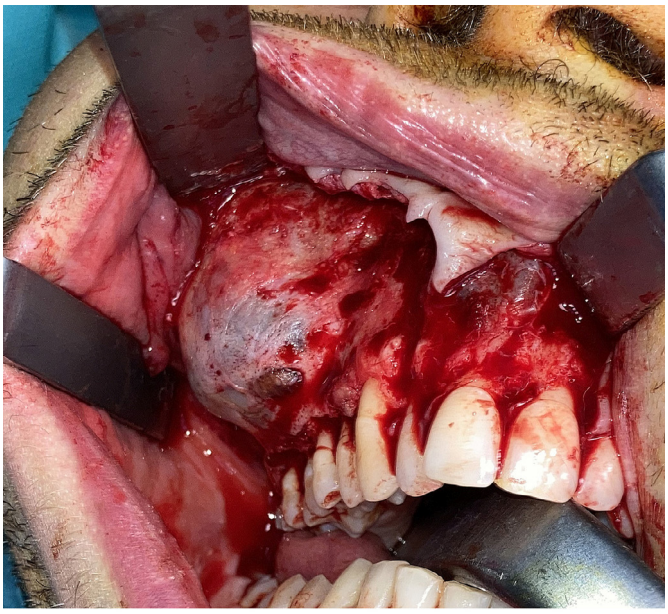

(a)

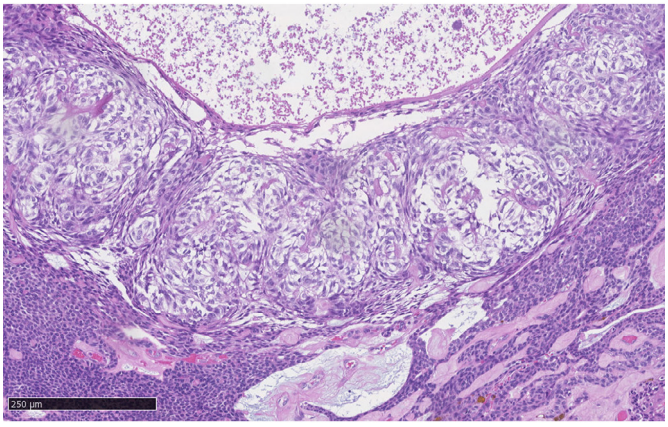

(b)

Fig. 2. Full thickness intraoral flap revealed the bone lesion (a). The solid part of the cystic coating consists of the growth of monomorphic medium/small rounded elements, alternating with deposits of eosinophilic matrix. Towards the luminal part of the solid growth, there are aggregates of ductal structures of elements of medium size, oval/cylindrical, with clear cytoplasm. At the center of some ductal structures there are intensely eosinophilic acellular droplets. To complete the lining of the cystic formation, towards the lumen, there is a similar epitheliomorphic/paucistratified lining (b).

As for its histogenesis and its histopathological attribution, the AOT is still a source of debate: some authors consider it a real benign tumor, meanwhile others classify it as a hamartoma and still others believe that the AOT can be more similar to an odontogenic cyst [2,4].

Even if cases have been reported in patients from 3 to 82 years-old, AOT presents a predilection for young subjects [2–4]. AOT shows a peak of incidence (88% of the cases) during the second and third decades of life, affecting teenagers (13–19 years old) in approximately 53% of the cases and patients between 20 and 29 years old in 21% [2–4]. AOT seems to be more frequent in females with a global F:M ratio of 2:1 which become 4:1 during the third decade of life, but undergoes a reversal for patients older than 30 years old (F:M = 1:2) [2,4]. There is no evidence relatively racial difference in the AOT onset, even though in some studies it seems to be more common in blacks [4].

AOT is more prevalent in the upper maxilla, especially in the anterior region of the jaws than in the posterior one [2]. Evidence shows that AOT is frequent associated with a permanent unerupted tooth, frequently the canine (2/3 of cases), while the association between AOT and deciduous teeth is very rare [2,3]. Multiple AOTs of the jaws are extremely rare and only few cases have been reported in association with Schimmelpenning syndrome [2]. AOT is almost always an asymptomatic lesion which presents a progressive slow-growth [4]. For these reasons, AOT is often a casual finding during

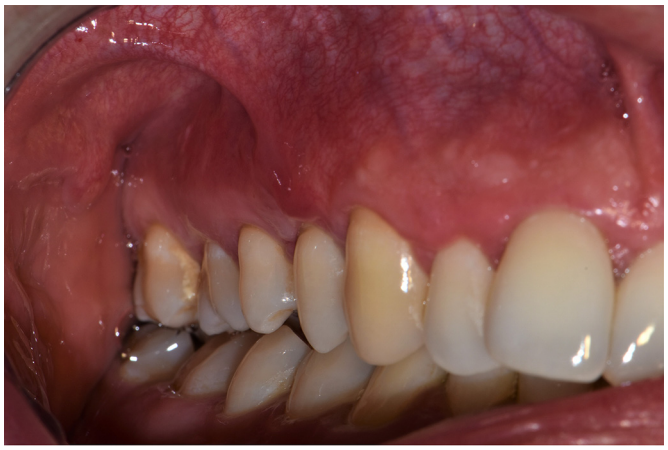

(a)

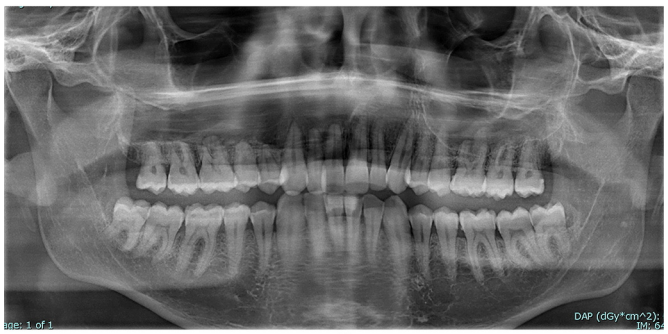

(b)

Fig. 3. Six-months follow-up: intra-oral complete clinical healing (a); involved teeth maintain vitality despite root resorptions detectable on orthopantomography (b).

routine radiographic investigations, for example for failed-eruption of a permanent tooth [4].

Clinically there are two variants of AOT described in literature: peripheral (extraosseous) and central (intraosseous) [2,3]. The central type is the most frequent accounting for more than 95% of all AOTs [3]. Intraosseous AOTs can be sub-classified into follicular type, associated with the crown of an unerupted permanent tooth, and extrafollicular type which, appearing similar to radicular cysts, doesn't show any relationship with an impacted tooth [2,3]. The central variant is often associated with cortical bone expansion and teeth displacement, while cortical bone perforation is unusual [2]. The peripheral variant is uncommon and, according with a recent review, only 30 cases have been reported in literature [2]. Peripheral AOT often appears as gingival mass and are 10 times more frequent in the maxillary gingiva than in the mandibular one [4].

Radiographically, the AOT usually appears as a well demarcated unilocular radiolucency which is often associated with teeth displacement and roots divergence [4]. AOT's growth often leads to bone expansion, but causes root resorption of the adjacent teeth only in 17% of the cases [2].

At histopathological analysis AOT presents a so-called "duct-like structures" formed by spindle-shape or cuboidal epithelial cells associated with minimal stroma and surrounded by a well-defined fibrous capsule [1,2].

The differential diagnosis should be made with odontogenic cysts, ameloblastoma, fibro-osseous lesions and tumors of mesenchymal origin [4,5].

Complete surgical enucleation is the treatment of choice for AOT [2–4]. The recurrence of AOT is extremely rare and the cases of relapse reported in literature showed doubtful histopathological results [2,4].

Considering the slow-growth and the almost absence of recurrence, a conservative surgical approach is widely suggested in the management of AOT [2].

Funding

This research did not receive any specific grant from funding agencies in the public, commercial, or not-for-profit sectors.

Ethical committee approval and informed consent

The study was performed in compliance with the recognized international standards, including the principles of the Declaration of Helsinki. Data and sample were collected under patient's informed written consent, guaranteeing anonymity. Ethics committee approval was not required for case report.

Conflicts of interests

Authors have no conflict of interests to disclose.

References

1. Thakur A, Tupkari JV, Joy T, Hanchate AV. Adenomatoid odontogenic tumor: What is the true nature? Med Hypotheses 2016;97:90–93.
2. Chrcanovic BR, Gomez RS. Adenomatoid odontogenic tumor: an updated analysis of the cases reported in the literature. J Oral Pathol Med 2019;48:10–16.
3. Fujita A, Ueyama Y, Nagatsuka H, Kawamata H. A case of large adenomatoid odontogenic tumor in the posterior region of the mandible showing root resorption. J Oral Med Oral Surg 2021;27:19.
4. Rick GM. Adenomatoid odontogenic tumor. Oral Maxillofac Surg Clin North Am 2004;16:333–354.
5. Lombardi N, Varoni EM, Bazzacchi R, Moneghini L, Lodi G. Secondary undifferentiated pleomorphic sarcoma of the mandible in a HIV patient who underwent radiotherapy for oral carcinoma. Spec Care Dent. Published online February 5, 2021:scd.12574. doi: 10.1111/scd.12574.