

CONTEMPORARY REVIEW

Segmental nonocclusive cryoballoon ablation of pulmonary veins and extrapulmonary vein structures: Best practices III

Arash Aryana, MD, PhD, FHRS,* Wilber Su, MD, FHRS,[†] Malte Kuniss, MD,[‡]
Kaoru Okishige, MD, PhD, FHRS,[§] Carlo de Asmundis, MD, PhD, FHRS,[¶]
Claudio Tondo, MD, PhD, FHRS,^{||**} Gian-Battista Chierchia, MD, PhD[¶]

From the *Mercy General Hospital and Dignity Health Heart and Vascular Institute, Sacramento, California, [†]Banner University Medical Center, Phoenix, Arizona, [‡]Department of Cardiology, Kerckhoff-Klinik, Bad Nauheim, Germany, [§]Heart Center, Japan Red Cross Yokohama City Bay Hospital, Yokohama, Japan, [¶]Heart Rhythm Management Center, UZ Brussel–VUB, Brussels, Belgium, ^{||}Heart Rhythm Center, Centro Cardiologico Monzino IRCCS, and ^{**}Department of Biochemical, Surgical and Dental Sciences, University of Milan, Milan, Italy.

Although cryoballoon ablation of atrial fibrillation (AF) traditionally has been guided by pulmonary vein (PV) occlusion, there is evidence and growing interest in performing segmental, nonocclusive cryoballoon ablation to target not only large/common PVs but extra-PV structures such as the left atrial (LA) roof and posterior wall in conjunction with PV isolation. A number of studies have demonstrated improved clinical efficacy associated with nonocclusive cryoballoon ablation of the LA roof and posterior wall in addition to PV isolation, particularly in patients with persistent AF. Not only can the cryoballoon be used for targeting extra-PV structures through segmental, nonocclusive ablation, but the large size and durability of cryolesions coupled with the enhanced stability afforded through

cryoadhesion render the cryoballoon an effective tool for such an approach. This article reviews the rationale and practical approach to segmental, nonocclusive cryoballoon ablation of large/common PV antra and the LA roof and posterior wall.

KEYWORDS Atrial fibrillation; Catheter ablation; Cryoablation; Cryoballoon; Intracardiac echocardiography; Mapping; Posterior wall; Pulmonary vein isolation; Roof

(Heart Rhythm 2021; ■:1–10) © 2021 Heart Rhythm Society. This is an open access article under the CC BY license (<http://creativecommons.org/licenses/by/4.0/>).

Introduction

Historically, cryoballoon ablation of atrial fibrillation (AF) has been guided by pulmonary vein (PV) occlusion.¹ This is supported by preclinical² and clinical³ studies, which have shown that the magnitude of PV occlusion is a significant determinant of PV isolation (PVI) durability. However, PV occlusion is not an absolute requirement for creating durable cryolesions.^{4,5} Based on available data, myocardial cells are rendered electrically dormant (ie, reversible ion channel block) at +20°C to +25°C with irreversible, lethal effects achieved at temperatures of –20°C to –50°C.^{6,7} Although PV occlusion likely augments the “magnitude of

the freeze,” optimal tissue contact and not necessarily PV occlusion, which in itself implies the same, is quintessential for creating durable cryolesions. This notion is further supported by finite element modeling data⁸ and clinically corroborated when performing nonocclusive cryoballoon ablation (NOCA) to target large-sized PVs in a segmental approach, as in the case of large or common PV ostia⁹ and the left atrial (LA) roof (NOCA_{ROOF})^{10–13} and posterior wall (PW) (NOCA_{LAPW}).^{14–18} In fact, PV occlusion using currently available, fixed-diameter cryoballoons (23/28 mm) is more likely to yield suboptimal results (ie, ostial level PVI) when treating large-sized PVs or patients with persistent/long-standing persistent AF who typically exhibit large LA and PV antra.^{19,20} This article examines the procedural and practical aspects of a segmental NOCA strategy for several LA structures, including large/common PVs as well as extra-PV structures such as the LA ridge, carina, roof, and PW.

NOCA of large/common PV ostia

The level of PVI achieved using cryoballoon ablation has been the subject of controversy. First investigated by Reddy et al,²¹ the level of isolation using a 23-mm cryoballoon was

Funding sources: The authors have no funding sources to disclose. Disclosures: Drs Aryana, Chierchia, de Asmundis, Kuniss, Okishige, and Tondo have received consulting fees and speaker honoraria from Boston Scientific, Biosense Webster, and Medtronic. Drs Aryana and Okishige have received research grants from Biosense Webster and Medtronic. Dr Su has received consulting fees, speaker honoraria, and research grants from Boston Scientific and Medtronic. **Address reprint requests and correspondence:** Dr Arash Aryana, Cardiovascular Services, Mercy General Hospital, 3941 J St, Suite #350, Sacramento, CA 95819. E-mail address: a_aryana@outlook.com.

found to occur distally and predominantly at the PV ostia, whereas the PV antra were left largely intact/unablated. However, subsequent studies examining the extent and level of PVI using a 28-mm cryoballoon found this to be more proximal in patients with paroxysmal AF and relatively normal-sized atria.^{22,23} Still, in patients with marked LA enlargement or large/common PV ostia, PV occlusion using the currently available, fixed-diameter cryoballoons can yield suboptimal/ostial PVI, even when the larger 28-mm cryoballoon is used (Figure 1A). Therefore, a segmental NOCA strategy may be required in many cases. Not only can such an approach achieve an antral-level PVI (Figure 1B), but it can eliminate the need for contrast medium injection and possibly even reduce the risk of right phrenic nerve (PN) injury by avoiding distal placement of the cryoballoon into the PV ostia.²⁴ Arguably, this is one of the main reasons accounting for the higher rate of PN injury using balloon-based vs point-by-point radiofrequency ablation (RFA) strategies.²⁴

The initial step for ensuring a successful segmental NOCA approach to achieve wide-area, antral PVI using any type of balloon catheter involves the careful planning of the transseptal puncture. A posterior or a mid/high transseptal site can significantly impede the catheter from reaching the desired locations on the lower segments of the LA posterior wall (LAPW) and the inferior PVs. A low and anterior transseptal puncture is essential. In fact, some of the authors specifically prefer crossing the interatrial septum at its utmost inferior (“thicker” or muscular) portion, adjacent to the inferior limbus for this approach (Figure 2). It is also believed that such a practice may reduce the incidence of postablation

iatrogenic atrial septal defects,²⁵ which may otherwise persist in more than one-third of the patients during long-term follow-up.²⁶

Once the balloon is inserted via the delivery sheath into the LA, it is advanced over an inner-lumen circular mapping catheter (ILC) or a guidewire (GW), which in turn is positioned inside one of the PVs. Proper positioning of the ILC/GW is critical to the procedure since it is used as a rail to place the cryoballoon over the desired locations. The ILC/GW is typically positioned in a superior PV for ablation of the superior antral regions and in an inferior PV for targeting the inferior segments. Initially, the ILC/GW may be placed distally in the desired PV to provide sufficient support and stability for the balloon, particularly when using the current-generation, short-tipped cryoballoon catheters. Subsequent advancement or withdrawal of the ILC/GW directs the cryoballoon away or toward the targeted PV, respectively. The delivery sheath should be deflected accordingly to point in the direction of the desired structure (ie, inferior PVs, inferior LAPW). It is much easier to navigate the cryoballoon anteriorly or posteriorly once it has been inflated. The balloon should be guided and advanced at all times over the ILC/GW to avoid injury to the tissue by the relatively firm tip of the cryoballoon catheter. With the ILC/GW placed inside the left PVs, clocking the delivery sheath will result in a posterior balloon alignment, whereas a counterclockwise torque will steer the balloon anteriorly. Conversely, with the ILC/GW positioned in the right PVs, a clockwise torque will guide the balloon anteriorly and a counterclockwise rotation will direct it posteriorly. Positioning of the balloon can be

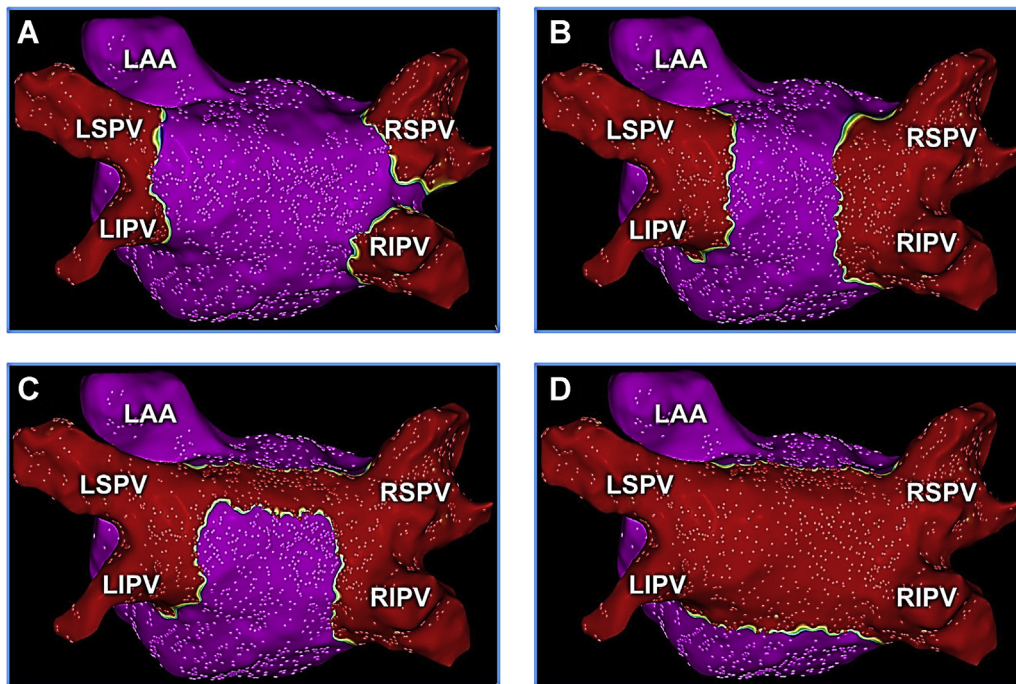


Figure 1 Cryoballoon ablation of pulmonary veins (PVs) and extra-PV structures. Three-dimensional electroanatomic voltage maps (scar voltage cutoff set to 0.05 mV) depicting suboptimal, ostial PVI (A), antral PVI (B), antral PVI with NOCA_{ROOF} (C), and PVI+PWI (D) performed using the cryoballoon. LAA = left atrial appendage; LIPV = left inferior pulmonary vein; LSPV = left superior pulmonary vein; NOCA = nonocclusive cryoballoon ablation; PVI = pulmonary vein isolation; PWI = posterior wall isolation; RIPV = right inferior pulmonary vein; RSPV = right superior pulmonary vein.

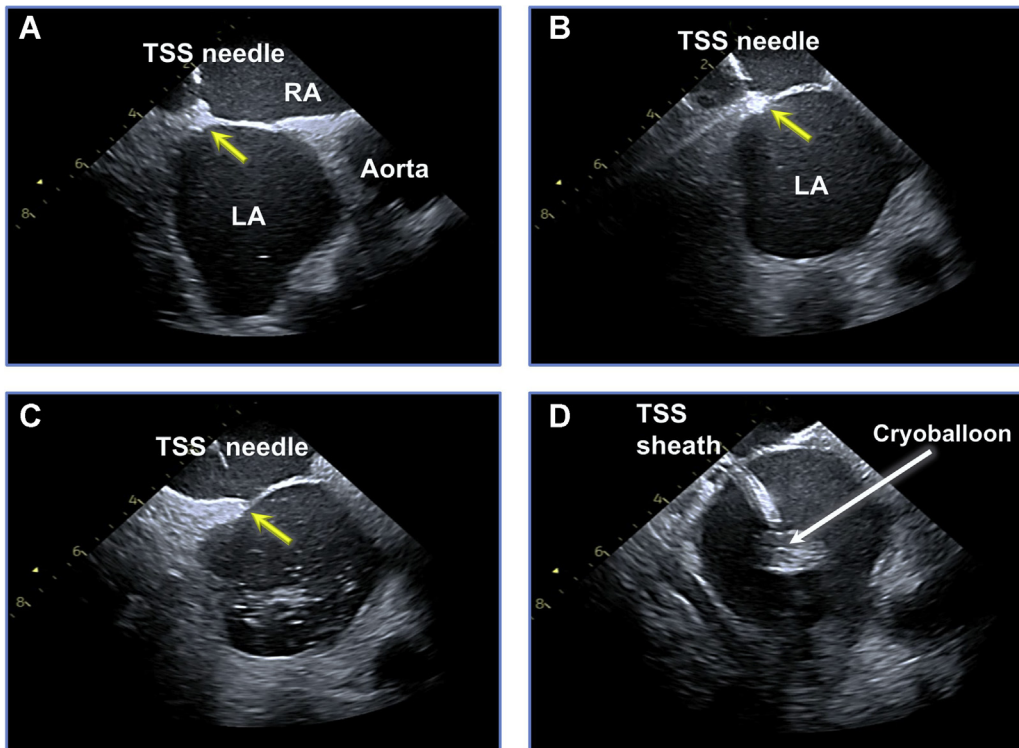


Figure 2 Suitable transseptal puncture site for nonocclusive cryoballoon ablation (NOCA). Intracardiac echocardiographic images illustrating a low and anterior transseptal needle position (*yellow arrow*) at the fossa ovalis (**A**, **B**), followed by transseptal puncture (**C**) and insertion of a cryoballoon sheath (**D**) through the most inferior segment of the interatrial septum, adjacent to the inferior limbus, most suitable for NOCA. LA = left atrium; RA = right atrium; TSS = transseptal.

further aided by intracardiac echocardiography (ICE), which in some systems can be integrated into the 3-dimensional (3D) electroanatomic map (CartoSound, Biosense Webster, Irvine, CA) to allow direct visualization and recording of the balloon position (**Figure 3**). Although fluoroscopy may help validate an antral balloon placement, injection of contrast medium, itself, adds little value and typically is avoided during segmental NOCA. Once the balloon is placed at the desired location, ablation may begin. If suboptimal tissue contact is suspected, the operator may exploit cryoadhesion for incremental adjustments in the catheter position. This can be achieved by further clocking or counterclocking the catheter in the desired direction to improve balloon–tissue contact. The balloon nadir temperature can prove particularly helpful in this regard, as reductions in nadir temperature correlate well with improvements in tissue contact during such an approach. This is also one of the inherent advantages of performing non-PV occlusive applications using the cryoballoon vs other similar tools. Although a comparable strategy can be adopted using the RFA balloon (HelioStar, Biosense Webster) – that is, not only to achieve wide-area, antral PVI, but also posterior wall isolation (PWI)²⁷ – in our experience, catheter stability afforded through cryoadhesion provides the cryoballoon a slight advantage for performing this strategy.

Perhaps the main limitation of NOCA as compared to a conventional PV occlusion-guided method involves the current lack of lesion quality and durability markers. Although a great deal of data has been acquired and pub-

lished over the last decade regarding the value of procedural and biophysical markers of cryoballoon ablation (eg, time to PVI, balloon cooling rate, and thaw time) in guiding cryodosing and assessing lesion quality and durability,^{1,3} these were all investigated in the context of PV occlusion and, therefore, do not reliably apply when performing NOCA. Thus, currently most operators simply deliver a series of overlapping 120-second cryoapplications at each balloon location.

NOCA of the LA ridge and carina

The LA ridge and carina are sites that are frequently spared during PV-occlusive cryoballoon applications. However, both can be effectively targeted using NOCA in a manner similar to that described for ablation of large PV antra. When ablating the LA ridge, the ILC/GW is placed in either the left PV (superior or inferior, depending on PV anatomies and orientation) or the LA appendage. The balloon is then exposed over the ILC/GW. Upon inflation, the balloon and sheath are counterclocked (with the ILC/GW inside a PV) or clocked (with the ILC/GW in the appendage), to position the balloon along the ridge. Once again, ICE can prove quite helpful in positioning the balloon. If the operator chooses the LA appendage as the anchor site for the ILC/GW, care should be taken to avoid injury to this structure using the balloon tip. As such, the balloon should always be advanced over an ILC/GW. In addition, knowledge of the LA appendage depth and morphology, as determined by ICE or angiography, is critical for safe practices. With respect to the duration of

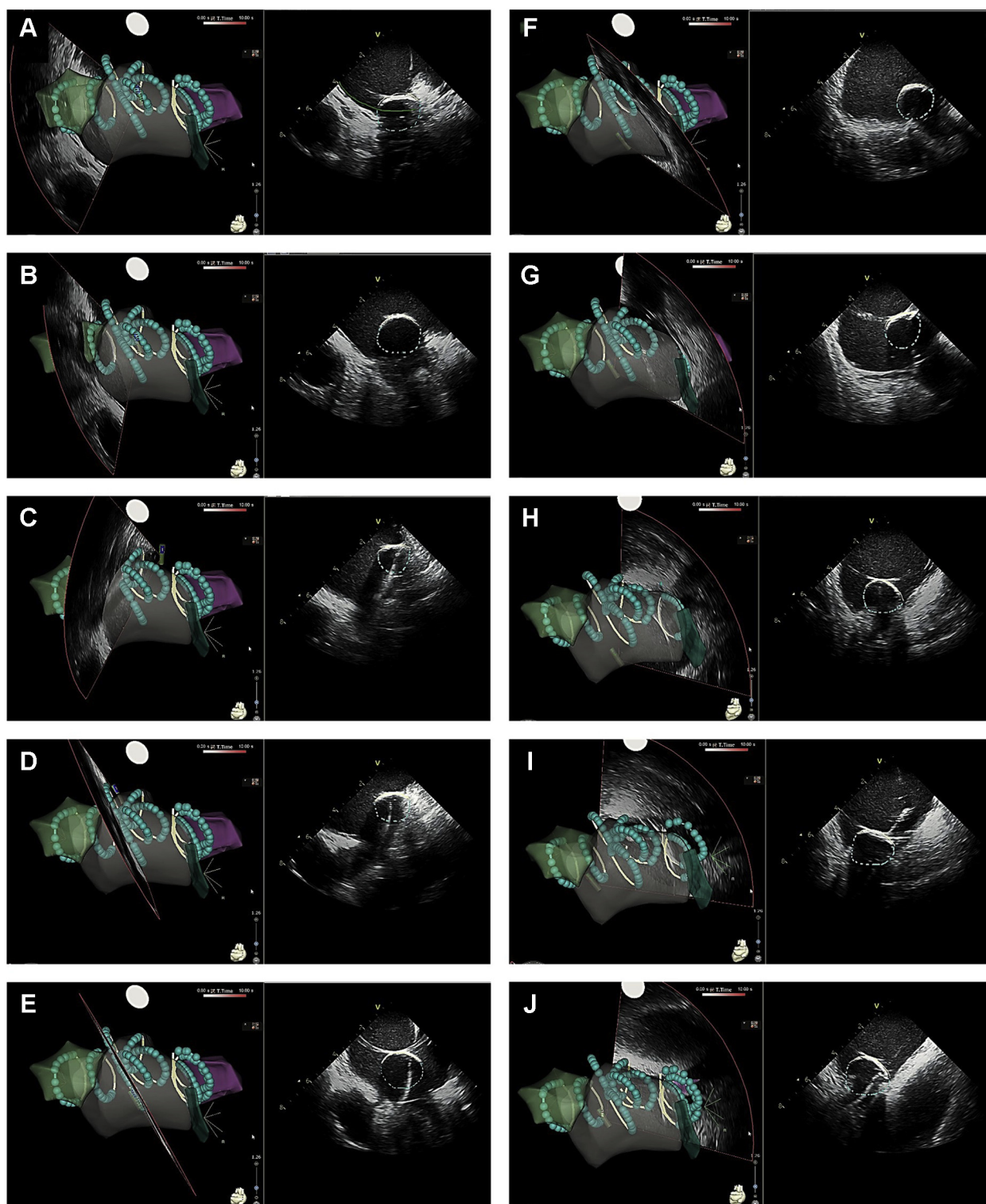


Figure 3 Intracardiac echocardiography (ICE)-guided nonocclusive cryoballoon ablation. Positions of 10 serial cryoballoon applications (A–J) delivered antrally, outside the pulmonary veins and along the roof and the posterior wall, visualized using ICE image integration (CartoSound, Biosense Webster). After creating a left atrial shell using ICE, the position of the cryoballoon can be directly recorded within the 3-dimensional map by creating ICE contours of the balloon at each location as depicted by each slice. *Turquoise* lesions represent the distal and *yellow* contours represent the proximal hemisurfaces of the cryoballoon to aid with proper balloon alignment.

applications, some of the authors favor prolonged cryoapplications in this area (eg, 180–240 seconds) to create transmural lesions and to also modify the ligament of Marshall.

For ablation of the LA carina between the right superior and inferior PVs, the ILC/GW is inserted initially distally into one of the right PVs (most commonly the superior) for

stability. Then, with a clockwise torque, the sheath and the inflated balloon are positioned anteriorly along the carina. A similar strategy can be used when targeting the anterior antral region of the right inferior PV by placing the ILC/GW into this vein. Once again, the key to ensuring optimal catheter maneuverability and successful completion of NOCA at this location is a low, anterior transseptal puncture. Although NOCA is believed to carry an overall lower likelihood of PN injury,²⁴ the anterior carina represents a site where PN suppression/injury might occur during ablation due to its relative proximity to the right PN. Thus, standard PN monitoring techniques (eg, high-output pacing) are warranted when targeting this region.²⁸ Moreover, cryoapplications at these locations typically are minimized to 120 seconds. Postablation, wide-area, antral PVI and successful ablation of the LA ridge and carina should be validated through detailed mapping, preferably using a high-density mapping catheter (eg, PentaRay, Biosense Webster; Advisor™ HD Grid, Abbott, Abbott Park, IL), as well as high-output pacing to illustrate absence of local pacing capture. If any gaps are identified, then ICE and specifically ICE image integration can be used for targeting these sites (Figure 4A).

NOCA of extra-PV structures

Rationale

Cryolesions created using the current-generation cryoballoons typically are large,^{29–32} continuous,^{31,32} and durable,^{4,5,33} which render it a rather attractive tool for ablation of extra-PV substrates. A study comparing lesion characteristics and clinical outcomes associated with catheter ablation of AF using the hot balloon (SATAKE HotBalloon, Toray Industries, Inc, Tokyo, Japan) vs the current-generation cryoballoon (Arctic Front Advance, Medtronic, Minneapolis, MN) found that lesions created using the latter were significantly larger ($38 \pm 12 \text{ cm}^2$ vs $24 \pm 8 \text{ cm}^2$).²⁹ Another study investigating the extent of LA isolation using the laser balloon (HeartLight™, CardioFocus, Inc, Marlborough, MA) vs the cryoballoon (Arctic Front Advance, Medtronic) discovered that total ($42 \pm 15 \text{ cm}^2$ vs $57 \pm 14 \text{ cm}^2$) and antral ($54 \pm 10\%$ vs $65 \pm 8\%$) areas of isolation both were greater using the latter.³⁰ Similar studies examining the sizes of ablation lesions and the areas of isolation using the cryoballoon vs force-sensing RFA have shown the lesions to be significantly wider ($16.7 \pm 5.1 \text{ mm}$ vs $5.3 \pm 2.3 \text{ mm}$)³¹ and more contiguous with fewer gaps³² using the cryoballoon. Although much of the published literature pertains to the Arctic Front Advance cryoballoon (Medtronic), early experiences with the Polar-X cryoballoon catheter (Boston Scientific, Marlborough, MA) suggests similar or improved efficacy due to the compliance of the latter ablation catheter.³⁴

Moreover, despite the weak level of evidence, some have also considered the cryoballoon a safer tool for this approach. Several studies have found a lower incidence of adverse events using cryoballoon vs point-by-point RFA, including a reduced rate of perforation and tamponade,^{35,36} and with

the exception of the PN, some have even suggested a higher degree of safety with respect to collateral structures.^{37,38} Along these lines, a comparative study by Ripley et al³⁷ found smaller esophageal lesions with cryoballoon vs point-by-point RFA. Additionally, cryoballoon was associated with a lower incidence of partial- and full-thickness esophageal ulcerations. Similarly, in a multicenter study of 376 patients with AF, Squara et al³⁸ compared the outcomes of cryoballoon vs force-sensing RFA and observed a lower incidence of severe complications, including esophageal injury, using the cryoballoon.

LA roof

In most patients, NOCA_{ROOF} can be effectively achieved through a series of sequential, nonocclusive, overlapping 120- to 180-second applications. This is a relatively common site for AF termination during NOCA in patients with persistent AF.¹⁴ In several studies, this approach, when performed using the cryoballoon in conjunction with PVI, has been shown to offer favorable outcomes in patient with persistent AF.^{10–13} This location is also the site of the main autonomic ganglionic plexi related to the LA dome (ie, superior LA ganglionated plexus), which is believed to modulate extrinsic cardiac innervation and facilitate the occurrence of AF in a hyperactive autonomic state.³⁹ As such, catheter ablation at this site is believed to greatly attenuate the input of these plexi to the PVs and interrupt vagosympathetic input to the ligament of Marshall and the inferior left ganglionated plexus, which are both highly implicated in the pathogenesis of AF.³⁹

Meanwhile, the LA roof is a location where adequate tissue contact using the cryoballoon can be readily achieved and catheter maneuverability is relatively unimpeded. For this, the ILC/GW typically is anchored in one of the superior PVs (most commonly the left). With the ILC/GW anchored, its progressive advancement farther into the vein displaces the inflated balloon outward or farther along the roof, away from the PV. This allows the operator to systematically ablate the LA roof using serial overlapping cryoapplications (Figure 5). Once again, ICE can prove quite helpful, particularly in the setting of image integration, which allows direct visualization of cryoballoon locations within the 3D map (Figure 3), and for targeting any remaining gaps (Figure 4B). Typically, between 3 and 5 applications are required to achieve block across the LA roof. With the ILC/GW inside the left superior PV, slight clockwise rotation of the sheath and the balloon can improve contact with the posterior aspect of the roof, whereas a counterclockwise rotation will guide the balloon anteriorly. The converse of this is true when the ILC/GW is anchored in the right superior PV. That is, the operator will need to rotate the sheath and the balloon counterclockwise to target the posterior segments of the roof, whereas a clockwise torque will guide the balloon anteriorly. Using the right superior PV as the anchor point is sometimes helpful when attempting to complete the right segments of the roof lesion set. In some instances, the right

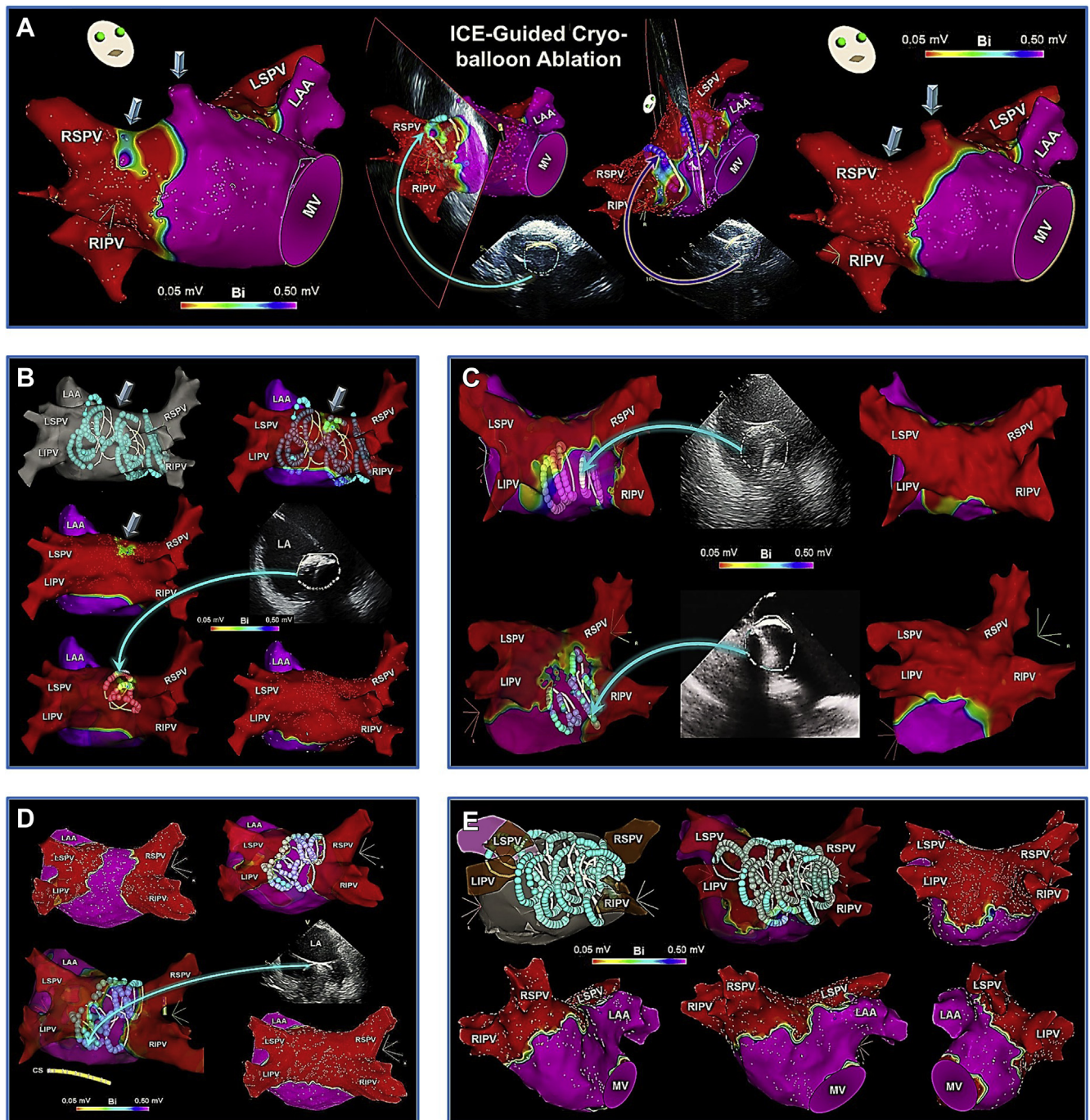


Figure 4 Intracardiac echocardiographic (ICE) image integration to target gaps and to complete LA roof and PWI. **A:** After cryoballoon PVI, a small gap/unablated area anterior to the right superior PV and a roof-associated PV branch (arrows) are detected on the postablation high-density voltage map (left). By positioning the cryoballoon directly over each site under the guidance of ICE and 3-dimensional (3D) mapping (middle), each one is successfully ablated using a single cryoapplication (right). **B:** Following PVI with NOCA_{LAPW}, a small gap/unablated area is detected on the LA roof (arrows) on the postablation voltage map. By directly positioning the cryoballoon at this location, guided by ICE and 3D mapping, the site of interest is targeted using NOCA. **C:** After completion of wide-area, antral PVI with NOCA_{ROOF}, PWI is performed using a series of additional cryoapplications guided by ICE image integration and direct visualization within the 3D map. **D:** After completion of PVI using a conventional PV occlusive strategy, the PV component of the LAPW is subsequently ablated using a series of overlapping cryoapplications guided by ICE image integration and 3D mapping. **E:** Cryoballoon positions within a 3D map as recorded on ICE to achieve wide-area, antral PVI with PWI within the PV component in a patient with persistent AF. LAPW = left atrial posterior wall; MV = mitral valve; other abbreviations as in Figures 1 and 2.

superior PV may be selected preferentially if the left superior PV exhibits an acutely superior takeoff (Supplementary Figure 1). In such a situation, the cryoballoon may not be aligned coaxially with the ILC/GW inside the left superior

PV, thereby compromising optimal tissue contact and balloon positioning along the roof.

Postablation, complete block across the LA roof can be verified by a delay in conduction across the roof >120 ms

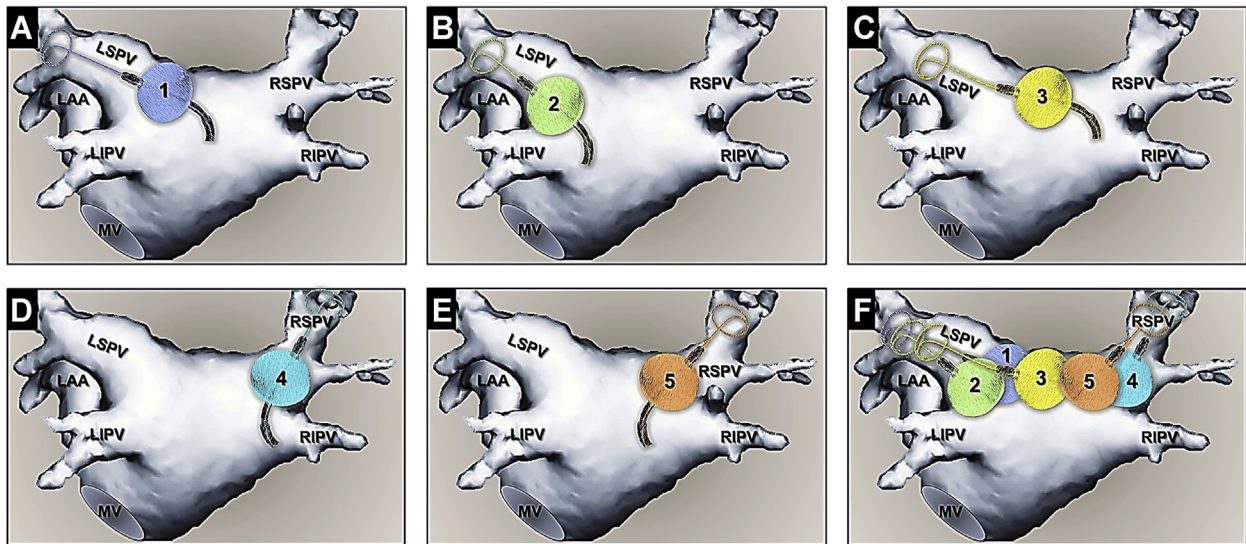


Figure 5 Cryoballoon positions for NOCA_{ROOF}. Typical positions of cryoballoon applications (1–5) on the roof, individually (A–E) and collectively (F), to complete NOCA_{ROOF}. Abbreviations as in Figures 1 and 4.

when pacing adjacent to the line/ablated area and an ascending activation over the LAPW.⁴⁰ Acute success in achieving block across the roof using the current-generation cryoballoons ranges between 88% and 92%.^{10–13} Compared to PVI alone, not only does this approach not result in higher incidences of complications or recurrent atrial arrhythmias, but this strategy is, in fact, associated with a lower incidence of arrhythmia recurrences during long-term follow-up (24.4% vs 43.0%; $P = .01$).¹² Moreover, in a multivariate analysis, NOCA_{ROOF} emerged as a significant predictor of freedom from recurrent atrial arrhythmias (hazard ratio: 2.13; $P < .01$).¹² Nonetheless, block across the roof must always be validated postablation to avoid the possibility of iatrogenic roof flutters/tachycardias.^{4,13} Rapid ventricular pacing at 350–500 ms (titrated to a systolic blood pressure >70 mm Hg) is an effective strategy practiced by some of the authors to improve cryoablation formation at this site and to facilitate NOCA_{ROOF}. This approach has been shown to increase the success of block across the LA roof through significant reductions in the balloon nadir temperature during NOCA_{ROOF}.⁴¹

LAPW

As with NOCA_{ROOF}, NOCA_{LAPW} has been a recent subject of growing interest and attention, particularly in patients with persistent AF. Although a role for empiric PWI has not yet been universally established,⁴² this approach seems plausible in patients with persistent AF given that it is generally considered not a triggered but a substrate-based arrhythmia. Not only does cryoballoon PVI+PWI within the region of the PV component (ie, LAPW segment lying between the PVs)³⁹ represent an extended form of wide-area, antral PVI, which in itself has been shown to be superior to ostial PVI strategies,⁴³ but anatomic^{39,44} and electrophysiologic^{45,46} evidence suggests that this region of the LAPW may significantly contribute to the genesis and maintenance

of AF (Supplementary Figure 2). Moreover, several studies have illustrated that cryoballoon PVI+PWI provides superior efficacy compared to PVI alone in patients with persistent AF.^{14–18} A multicenter retrospective study first analyzed this outcome and found that acute PWI using cryoballoon was feasible in more than two-thirds of the patients, yielding significantly greater LAPW (77% vs 41%) and total LA (53% vs 36%) isolation compared to PVI alone, with a higher incidence of AF termination/conversion.¹⁴ Adverse events were similar between the 2 strategies. However, recurrence of AF was significantly reduced with cryoballoon PVI+PWI at 12-months of follow-up ($\sim 20\%$ further reduction compared to PVI alone).¹⁴ Furthermore, in a Cox regression analysis, PVI+PWI emerged as a significant predictor of freedom from recurrent atrial arrhythmias (hazard ratio: 2.04; $P = .015$).¹⁴ Similar results have been reported in subsequent retrospective analyses,^{15,16} and another study also found this approach to be highly effective in patients undergoing repeat ablation for recurrent AF, in whom it yielded 85% freedom from recurrent atrial arrhythmias at 1 year.¹⁷ More recently, these findings were echoed by a multicenter, prospective, randomized-controlled trial (ClinicalTrials.gov Identifier: NCT03057548), which similarly showed that in patients with persistent AF, cryoballoon PVI+PWI was associated with $\sim 20\%$ reduction in AF recurrence at 12 months over and beyond PVI alone (25.5% vs 45.5%; $P = .028$).¹⁸ Additionally, PVI+PWI once again emerged as a significant independent predictor of freedom from recurrent AF during long-term follow-up (odds ratio 3.67; $P = .006$).¹⁸ A larger-scale, multicenter, prospective, randomized-controlled trial (G190171) is currently under way to further evaluate the acute and long-term outcomes of cryoballoon PVI with/without PWI.⁴⁷

As for the approach, NOCA_{LAPW} is practically similar to performing NOCA_{ROOF}. In addition to incorporating this strategy (Figure 5), the approach also includes NOCA of

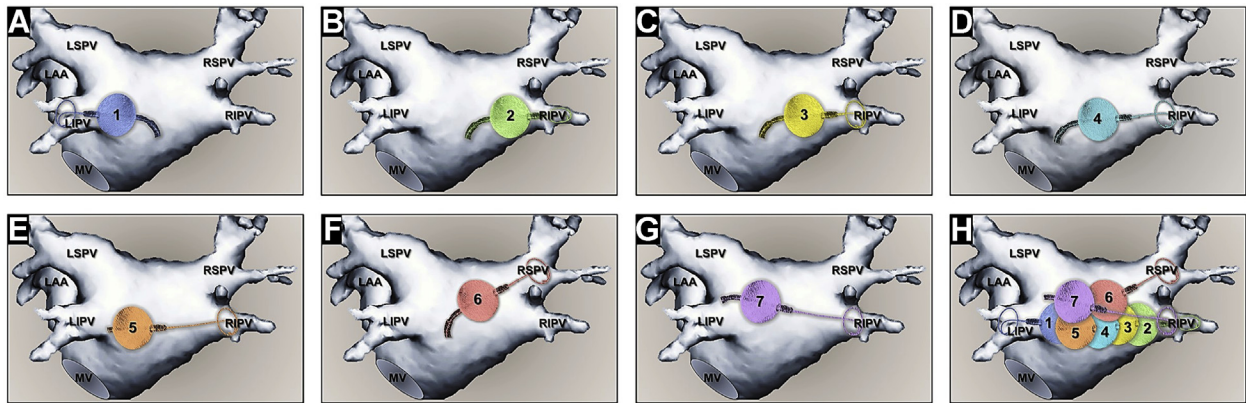


Figure 6 Cryoballoon positions for NOCA of the inferior segments of the left atrial posterior wall (LAPW). Positions of serial cryoballoon applications (1–7) along the inferior segments of the LAPW, individually (A–G) and collectively (H), to complete NOCA_{LAPW}. Abbreviations as in Figures 1 and 4.

the inferior segments of the PW (Figure 6) to directly ablate and eliminate all electrical activity within the PV component. To target the lower segments of the LAPW, the inferior PVs typically are used to anchor the ILC/GW, most commonly the right inferior PV which often exhibits a posterior takeoff. As with ablation of the roof, this is performed using sequential, overlapping 120- to 180-second applications by progressively advancing the ILC/GW deeper into the right inferior PV with each application. This in turn allows for gradual progression of the balloon away from the right inferior PV, along the inferior PW segments. Depending on the LA size, between 8 and 14 cryoapplications are commonly required to complete PWI. Cine recordings of the typical cryoballoon maneuvers for PWI are shown in Figure 7. Although complete PWI can be successfully achieved using a 28-mm cryoballoon without the need for adjunct point-by-point cryo/RFA,^{15,48,49} in some studies this has been shown to be necessary in at least one-third of the patients,^{4,14,18} particularly in those with LA diameters >48 mm.⁴ A gap, if present, is nor-

mally encountered along the mid-portion of the inferior PW (Figure 8). As with NOCA of other related structures, ICE and specifically ICE image integration (CartoSound, Biosense Webster), can prove remarkably helpful in identifying gaps among the lesion sets and completing the procedural endpoint, while minimizing the need for adjunct RFA (Figure 4).

Similar to NOCA_{ROOF}, block across the PW is critical when attempting PWI. As previously illustrated by Nanbu et al,¹³ the 1-year incidence of freedom from recurrent arrhythmias was significantly greater in those with vs without complete roof/PW block using cryoballoon (78% vs 45%, respectively). In another study, Aryana et al⁴ found that incomplete PWI was associated with a high rate of atypical roof/PW flutters, and almost every patient with LAPW reconnection exhibited such an arrhythmia, either clinically or inducible at electrophysiology study. They also found PWI using NOCA to be durable in 67 of 81 patients (82.7%) during 18 ± 4 months of follow-up.⁴ LA diameter emerged as a

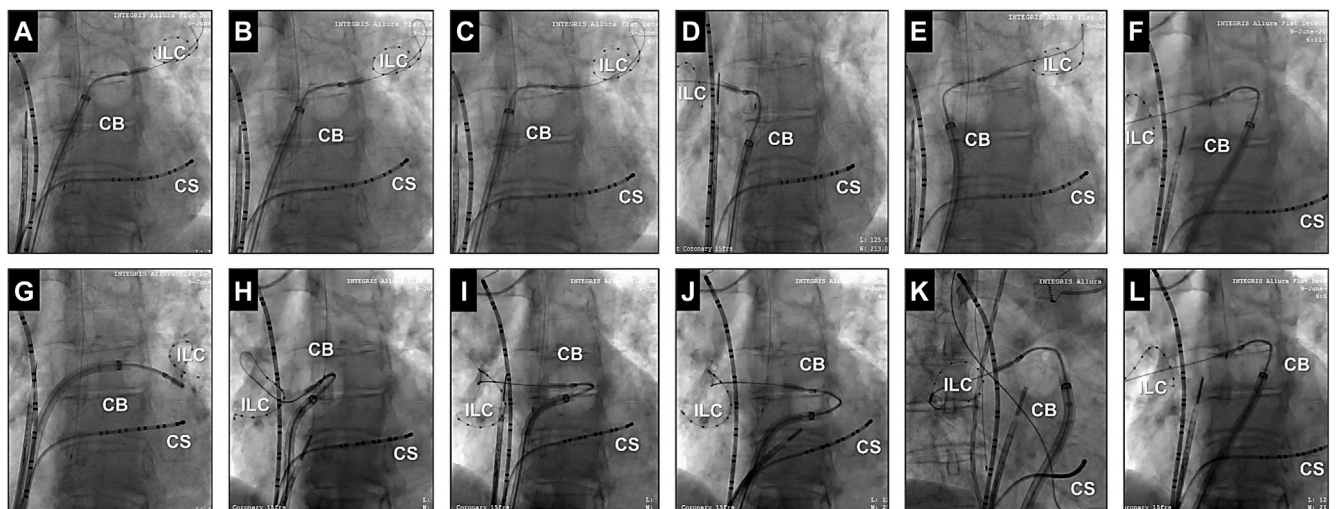


Figure 7 Cine images of the cryoballoon for performing PVI+PWI. **Top row:** Cine locations of the cryoballoon placed over an ILC for NOCA of the left (A) and right (D) superior pulmonary vein antra, the left (B), mid (C), and right (E) roof segments, and the mid-portion of the roof/posterior wall (F). **Bottom row:** Cryoballoon cine positions for NOCA of the left (G) and right (H) inferior pulmonary veins and the inferior (I, J) and mid (K, L) segments of the posterior wall. CB = cryoballoon; CS = coronary sinus; ILC = inner-lumen circular mapping catheter; other abbreviations as in Figure 1.

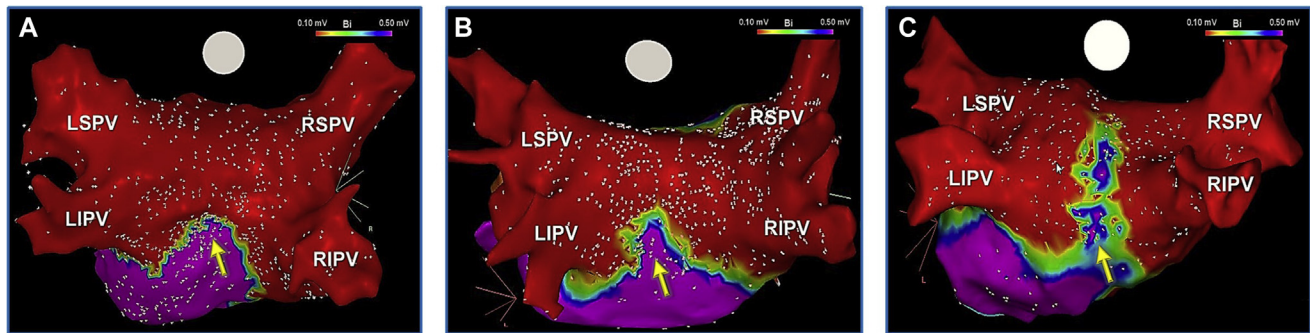


Figure 8 Incomplete isolation of the left atrial posterior wall (LAPW) using NOCA. Incomplete PWI using NOCA_{LAPW} may be observed in at least one-third of patients with markedly enlarged left atria, when performed using a 28-mm cryoballoon, sometimes requiring adjunct radiofrequency ablation for completion. **A–C:** Variations in gaps detected following NOCA_{LAPW}. When present, these gaps typically are encountered/most prominent along the mid-portion of the inferior LAPW (arrows). Abbreviations as in [Figure 1](#).

significant predictor for the need for adjunct RFA, particularly in those with LA diameters >48 mm (assessed in parasternal long-axis view). Additionally, patients with LAPW reconnection were also found to exhibit larger LA, such that 71% of those with PW reconnection exhibited LA diameters >48 mm (negative predictive value: 89.7%).⁴ Given these findings, when performing NOCA_{LAPW}, we strongly recommend that the operator always validate this endpoint through detailed high-density 3D mapping (eg, PentaRay and Advisor HD Grid) as well as high-output pacing illustrating absence of pacing capture, to avoid iatrogenic atrial arrhythmias.

Lastly, due to the close proximity of the LAPW to the esophagus, one must consider the possibility of detrimental injury to this structure. Although an increased risk of atrio-esophageal fistula has not yet been described with NOCA_{ROF}/NOCA_{LAPW}, the reported experience remains limited.^{14–18} Meanwhile, a study evaluating the outcomes of NOCA_{LAPW} found that interruption of cryoapplications at luminal esophageal temperatures >15°C is associated with absence of esophageal thermal lesions.⁴⁹ This recommendation seems tangible, as it is also consistent with findings from a previous study that reported the same when examining the risk of esophageal injury in the setting of cryoballoon PVI.⁵⁰

Conclusion

Cryoballoon ablation of AF guided exclusively by PV occlusion is not suitable for all types of anatomies or patients, particularly in those with enlarged LA/PV antra in whom this may lead to distal/ostial PVI. Alternatively, segmental NOCA represents an optimal strategy, not only for targeting large/common PV antra and the LA ridge and carina, but also for ablation of extra-PV structures such as the LA roof and PW. In fact, the large size, contiguity, and durability of cryolesions coupled with the enhanced stability afforded through cryoadhesion render the cryoballoon an attractive tool for such an approach. In several retrospective and prospective randomized studies, this strategy has been associ-

ated with improved clinical outcomes compared to traditional PV occlusion-guided isolation in patients with persistent AF. Though in general feasible, this approach will likely be further refined and facilitated through the advent of next-generation balloon designs such as those with larger (>28 mm) and variable diameters.

Acknowledgements

The authors wish to especially thank Kylee Schesser, BS for her valuable assistance with the illustrations depicted in this manuscript.

Appendix Supplementary data

Supplementary data associated with this article can be found in the online version at <https://doi.org/10.1016/j.hrthm.2021.04.020>.

References

1. Su W, Aryana A, Passman R, et al. Cryoballoon best practices II: practical guide to procedural monitoring and dosing during atrial fibrillation ablation from the perspective of experienced users. *Heart Rhythm* 2018;15:1348–1355.
2. Takami M, Misiri J, Lehmann HI, et al. Spatial and time-course thermodynamics during pulmonary vein isolation using the second-generation cryoballoon in a canine in vivo model. *Circ Arrhythm Electrophysiol* 2015;8:186–192.
3. Aryana A, Mugnai G, Singh SM, et al. Procedural and biophysical indicators of durable pulmonary vein isolation during cryoballoon ablation of atrial fibrillation. *Heart Rhythm* 2016;13:424–432.
4. Aryana A, Pujara DK, Baker JH, et al. Long-term durability of posterior wall isolation using the cryoballoon in patients with persistent atrial fibrillation: a multicenter analysis of repeat catheter ablations. *J Interv Card Electrophysiol* 2020 Sep 30; <https://doi.org/10.1007/s10840-020-00887-8>.
5. Shigeta T, Okishige K, Nishimura T, et al. Clinical investigation of the durability of the lesions created by left atrial linear ablation with a cryoballoon. *J Cardiovasc Electrophysiol* 2020;31:875–884.
6. Aufderheide T. Etiology, electrophysiology, and myocardial mechanics of pulseless electrical activity. In: Paradis N, Halperin H, Kern K, Wenzel V, Chamberlain E, eds. *Cardiac Arrest: The Science and Practice of Resuscitation Medicine, Second Edition*. New York: Cambridge University Press; 2007. p. 426–446.
7. Gage AA, Baust JM, Baust JG. Experimental cryosurgery investigations in vivo. *Cryobiology* 2009;59:229–243.
8. Handler M, Fischer G, Seger M, Kienast R, Hanser F, Baumgartner C. Simulation and evaluation of freeze-thaw cryoablation scenarios for the treatment of cardiac arrhythmias. *Biomed Eng Online* 2015;14:12.

9. Ströker E, Takarada K, de Asmundis C, et al. Second-generation cryoballoon ablation in the setting of left common pulmonary veins: procedural findings and clinical outcome. *Heart Rhythm* 2017;14: 1311–1318.
10. Kuniss M, Greif H, Pajitnev D, et al. Cryoballoon ablation of persistent atrial fibrillation: feasibility and safety of left atrial roof ablation with generation of conduction block in addition to antral pulmonary vein isolation. *Europace* 2017; 19:1109–1115.
11. Akkaya E, Berkowitsch A, Rieth A, et al. Clinical outcome and left atrial function after left atrial roof ablation using the cryoballoon technique in patients with symptomatic persistent atrial fibrillation. *Int J Cardiol* 2019;292:112–118.
12. Kuniss M, Akkaya E, Berkowitsch A, et al. Left atrial roof ablation in patients with persistent atrial fibrillation using the second-generation cryoballoon: benefit or wasted time? *Clin Res Cardiol* 2020;109:714–724.
13. Nanbu T, Yotsukura A, Suzuki G, et al. Important factors in left atrial posterior wall isolation using 28-mm cryoballoon ablation for persistent atrial fibrillation—block line or isolation area? *J Cardiovasc Electrophysiol* 2020;31:119–127.
14. Aryana A, Baker JH, Espinosa Ginic MA, et al. Posterior wall isolation using the cryoballoon in conjunction with pulmonary vein ablation is superior to pulmonary vein isolation alone in patients with persistent atrial fibrillation: a multicenter experience. *Heart Rhythm* 2018;15:1121–1129.
15. Nishimura T, Yamauchi Y, Aoyagi H, et al. The clinical impact of the left atrial posterior wall lesion formation by the cryoballoon application for persistent atrial fibrillation: feasibility and clinical implications. *J Cardiovasc Electrophysiol* 2019;30:805–814.
16. Nordsieck E, Zhang XJ, Malhotra P, Fan D, Pezeshkian NG, Srivatsa UN. Comparison of cryoballoon and hybrid surgical posterior wall isolation for persistent atrial fibrillation to conventional ablation. *J Atr Fibrillation* 2019; 11:2131.
17. Iacopino S, Paparella G, Capulzini L, et al. Posterior box isolation as an adjunctive ablation strategy during repeat ablation with the second-generation cryoballoon for recurrence of persistent atrial fibrillation: 1-year follow-up. *J Interv Card Electrophysiol* 2019;56:1–7.
18. Aryana A, Allen SL, Pujara DK, et al. Concomitant pulmonary vein and posterior wall isolation using cryoballoon with adjunct radiofrequency in persistent atrial fibrillation. *JACC Clin Electrophysiol* 2021;7:187–196.
19. Güler E, Güler GB, Demir GG, et al. Effect of pulmonary vein anatomy and pulmonary vein diameters on outcome of cryoballoon catheter ablation for atrial fibrillation. *Pacing Clin Electrophysiol* 2015;38:989–996.
20. Li B, Ma H, Guo H, et al. Pulmonary vein parameters are similar or better predictors than left atrial diameter for paroxysmal atrial fibrillation after cryoablation. *Braz J Med Biol Res* 2019;52:e8446.
21. Reddy VY, Neuzil P, d'Avila A, et al. Balloon catheter ablation to treat paroxysmal atrial fibrillation: what is the level of pulmonary venous isolation? *Heart Rhythm* 2008;5:353–360.
22. Chierchia GB, de Asmundis C, Sorgente A, et al. Anatomical extent of pulmonary vein isolation after cryoballoon ablation for atrial fibrillation: comparison between the 23 and 28 mm balloons. *J Cardiovasc Med (Hagerstown)* 2011;12:162–166.
23. Kenigsberg DN, Martin N, Lim HW, Kowalski M, Ellenbogen KA. Quantification of the cryoablation zone demarcated by pre- and postprocedural electroanatomic mapping in patients with atrial fibrillation using the 28-mm second-generation cryoballoon. *Heart Rhythm* 2015;12:283–290.
24. Aryana A. Rationale and outcomes of cryoballoon ablation of the left atrial posterior wall in conjunction with pulmonary vein isolation. *J Innov Card Rhythm Manag* 2021;12(8), <https://doi.org/10.19102/icrm.2021.120801>. Accessed May 9, 2021.
25. Rich ME, Tseng A, Lim HW, Wang PJ, Su WW. Reduction of iatrogenic atrial septal defects with an anterior and inferior transeptal puncture site when operating the cryoballoon ablation catheter. *J Vis Exp* 2015;100:e52811.
26. Linhart M, Werner JT, Stöckigt F, et al. High rate of persistent iatrogenic atrial septal defect after single transeptal puncture for cryoballoon pulmonary vein isolation. *J Interv Card Electrophysiol* 2018;52:141–148.
27. Aryana A, Allen SA, Di Biase L, Bowers MR, O'Neill PG, Natale A. Wide-area antral pulmonary vein and posterior wall isolation by way of segmental non-occlusive applications using the novel HelioStar radiofrequency ablation balloon. *HeartRhythm Case Rep* 2021. in press.
28. Kowalski M, Ellenbogen KA, Koneru JN. Prevention of phrenic nerve injury during interventional electrophysiologic procedures. *Heart Rhythm* 2014; 11:1839–1844.
29. Nagashima K, Okumura Y, Watanabe I, et al. Hot balloon versus cryoballoon ablation for atrial fibrillation: lesion characteristics and efficacy. *Circ Arrhythm Electrophysiol* 2018;11:e005861.
30. Perrotta L, Konstantinou A, Bordignon S, et al. What is the acute antral lesion size after pulmonary vein isolation using different balloon ablation technologies? *Circ J* 2017;81:172–179.
31. Kurose J, Kiuchi K, Fukuzawa K, et al. The lesion characteristics assessed by LGE-MRI after the cryoballoon ablation and conventional radiofrequency ablation. *J Arrhythm* 2018;34:158–166.
32. Okumura Y, Watanabe I, Iso K, et al. Mechanistic insights into durable pulmonary vein isolation achieved by second-generation cryoballoon ablation. *J Atr Fibrillation* 2017;9:18–24.
33. Reddy VY, Sediva L, Petru J, et al. Durability of pulmonary vein isolation with cryoballoon ablation: results from the SUSTAINED PV Isolation with ARctic Front Advance (SUPIR) Study. *J Cardiovasc Electrophysiol* 2015;26:493–500.
34. Moltrasio M, Kochi AN, Fassini G, Riva S, Tundo F, Tondo C. High-density mapping validation of antral pulmonary vein isolation and posterior wall isolation created with a new cryoballoon ablation system: the first reported case. *J Cardiovasc Electrophysiol* 2020;31:3318–3321.
35. Hoffmann E, Straube F, Wegscheider K, et al. Outcomes of cryoballoon or radiofrequency ablation in symptomatic paroxysmal or persistent atrial fibrillation. *Europace* 2019;21:1313–1324.
36. Fortuni F, Casula M, Sanzo A, et al. Meta-analysis comparing cryoballoon versus radiofrequency as first ablation procedure for atrial fibrillation. *Am J Cardiol* 2020;125:1170–1179.
37. Ripley KL, Gage AA, Olsen DB, Van Vleet JF, Lau C-P, Tse H-F. Time course of esophageal lesions after catheter ablation with cryothermal and radiofrequency ablation: implication for atrio-esophageal fistula formation after catheter ablation for atrial fibrillation. *J Cardiovasc Electrophysiol* 2007;18:642–646.
38. Squara F, Zhao A, Marijon E, et al. Comparison between radiofrequency with contact force-sensing and second-generation cryoballoon for paroxysmal atrial fibrillation catheter ablation: a multicentre European evaluation. *Europace* 2015;17:718–724.
39. Elbatran AI, Anderson RH, Mori S, Saba MM. The rationale for isolation of the left atrial pulmonary venous component to control atrial fibrillation: a review article. *Heart Rhythm* 2019;16:1392–1398.
40. Su WW, Alzubaidi M, Tseng R, Jebaily N, Lin YJ, Wang PJ. Novel usage of the cryoballoon catheter to achieve large area atrial substrate modification in persistent and long-standing persistent atrial fibrillation. *J Interv Card Electrophysiol* 2016;46:275–285.
41. Nishimura T, Okishige K, Yamauchi Y, et al. Clinical impact of rapid ventricular pacing on the left atrial posterior wall isolation by a cryoballoon application: a randomized controlled trial. *J Interv Card Electrophysiol* 2020;59:565–573.
42. Lee JM, Shim J, Park J, et al. The electrical isolation of the left atrial posterior wall in catheter ablation of persistent atrial fibrillation. *JACC Clin Electrophysiol* 2019;5:1253–1261.
43. Proietti R, Santangeli P, Di Biase L, et al. Comparative effectiveness of wide antral versus ostial pulmonary vein isolation: a systematic review and meta-analysis. *Circ Arrhythm Electrophysiol* 2014;7:39–45.
44. Jones SA, Yamamoto M, Tellez JO, et al. Distinguishing properties of cells from the myocardial sleeves of the pulmonary veins: a comparison of normal and abnormal pacemakers. *Circ Arrhythm Electrophysiol* 2008;1:39–48.
45. Mandapati R, Skanes A, Chen J, Berenfeld O, Jalife J. Stable microentrant sources as a mechanism of atrial fibrillation in the isolated sheep heart. *Circulation* 2000;101:194–199.
46. Spector P. Principles of cardiac electric propagation and their implications for reentrant arrhythmias. *Circ Arrhythm Electrophysiol* 2013;6:655–661.
47. Aryana A, Pujara DK, Allen SL, et al. Left atrial posterior wall isolation in conjunction with pulmonary vein isolation using cryoballoon for treatment of persistent atrial fibrillation (PIVoTAL): Study rationale and design. *J Interv Card Electrophysiol* 2020 Oct 3, <https://doi.org/10.1007/s10840-020-00885-w>. Accessed May 9, 2021.
48. Bisignani A, Overeinder I, Kazawa S, et al. Posterior box isolation as an adjunctive ablation strategy with the second-generation cryoballoon for paroxysmal atrial fibrillation: a comparison with standard cryoballoon pulmonary vein isolation. *J Interv Card Electrophysiol* 2020 Jul 6; <https://doi.org/10.1007/s10840-020-00812-z>.
49. Osório TG, Iacopino S, Coutinho HE, et al. Evaluation of the luminal esophageal temperature behavior during left atrium posterior wall ablation by means of second-generation cryoballoon. *J Interv Card Electrophysiol* 2019;55:191–196.
50. Fürnkranz A, Bordignon S, Böhmig M, et al. Reduced incidence of esophageal lesions by luminal esophageal temperature-guided second-generation cryoballoon ablation. *Heart Rhythm* 2015;12:268–274.