


CASE REPORT

Prostatic leiomyosarcoma in a dog treated using a multimodal approach

Marco Trovatielli¹  | Jessica Bassi² | Chiara Giudice¹ | Roberta Ferrari¹ |
 Maurizio Longo³ | Stefano Brizzola¹

¹Department of Veterinary Medicine, Università degli Studi di Milano, Lodi, Italy

²Veterinary and Zootechnical Experimental Clinical Centre, Università degli Studi di Milano, Lodi, Italy

³Centro Traumatologico Ortopedico Veterinario, Arenzano (GE), Italy

Correspondence

Stefano Brizzola, via dell'Università 6, 26900 Lodi, Italy.
 Email: stefano.brizzola@unimi.it

Abstract

Prostatic leiomyosarcoma is an uncommon tumor encountered in male dogs, with only 2 cases reported in the veterinary literature with no follow-up described. A 12-year-old male intact German Wirehaired Pointer presented for evaluation of straining to defecate and urinate. Whole body computed tomography (CT) examination identified a spherical multicavitary expansile mass arising from the prostate gland and severely obliterating the pelvic canal. Partial subcapsular prostatectomy was performed, and histological and immunohistochemical results were consistent with prostatic leiomyosarcoma. Metronomic cyclophosphamide and nonsteroidal anti-inflammatory drugs were administered as adjuvant chemotherapy. Follow-up CT 10 months later indicated no signs of recurrence or metastasis. To the best of our knowledge, this patient represents the first report of successful multidisciplinary treatment consisting of partial subcapsular prostatectomy and adjuvant chemotherapy for prostatic leiomyosarcoma in a dog. After 15 months of follow-up, the patient remained recurrence-free without metastasis.

KEYWORDS

CT, dog, metronomic chemotherapy, neoplasia, prostate

1 | INTRODUCTION

Prostatic neoplasia is rare in dogs, occurring at a mean age of 10 years at the time of diagnosis.¹ One study reported that, of 15 000 male dogs referred, 431 exhibited prostatic disease and 56 were diagnosed with prostatic carcinoma.² The incidence of prostatic disease was higher in other surveys, with up to 15% to 16% of dogs having prostatic disease diagnosed at necropsy.³

Prostatic leiomyosarcoma is a rare prostatic malignant tumor that arises from the smooth muscle component of the prostate, and has

been described in the dogs only twice, with a guarded prognosis of 12 hours survival⁴ and euthanasia performed at the time of diagnosis.⁵ To our knowledge, our case represents the first to dog with prostatic leiomyosarcoma that underwent partial subcapsular surgical excision and adjuvant metronomic chemotherapy, with a favorable prognosis and 15 months of follow-up.

2 | CASE DESCRIPTION

A 13-year-old 40 kg male intact German Wirehaired Pointer was presented to a primary care clinic for evaluation of straining to defecate and urinate. Abdominal ultrasound examination was performed by the

Abbreviations: ASMA, alpha smooth muscle actin; CT, computed tomography; FNA, fine needle aspiration.

This is an open access article under the terms of the Creative Commons Attribution-NonCommercial License, which permits use, distribution and reproduction in any medium, provided the original work is properly cited and is not used for commercial purposes.

© 2021 The Authors. *Journal of Veterinary Internal Medicine* published by Wiley Periodicals LLC. on behalf of the American College of Veterinary Internal Medicine.

referring veterinarian, who diagnosed a pelvic cystic mass. Fine needle aspiration (FNA) was performed, resulting in a diagnosis of pyogranulomatous inflammation.

The dog was referred to the Veterinary Teaching Hospital of the Università degli Studi di Milano (Lodi, Italy) for a second opinion 15 days after initial presentation to the referring veterinarian. The dog had a 2-year history of prostatitis that had resolved with medical treatment.

On physical examination, body condition score was 4/9, and the dog had normal mentation, adequate hydration, pink mucosal membranes, and normal capillary refill time. The popliteal lymph nodes were enlarged, and rectal temperature was normal. Caudal abdominal palpation identified a firm intra-abdominal mass, and rectal examination confirmed the presence of a mass causing extraluminal compression of the rectum.

Abdominal radiography disclosed severe dilatation of the colon with granular fecal material indicative of megacolon,⁶ moderate urinary bladder distension, and the presence of increased soft tissue opacity in the region of the prostate gland protruding cranially from the pelvic inlet and associated with severe segmental compression of the rectum, thoracic radiography was unremarkable (Figure 1). Abdominal ultrasound examination identified a multicavitary cystic mass, 9 × 6 cm in size, localized in the right pelvic region, adjacent to the prostate gland that had medium homogeneous echogenicity and smooth margins. The mass was causing compression and displacement of the rectum and urethra. No regional lymphadenopathy was detected (Figure 2).

Ultrasound-guided FNA was performed percutaneously from the right perineal area, and 20 mL of reddish-brown fluid was obtained for cytological analysis, which was nondiagnostic.

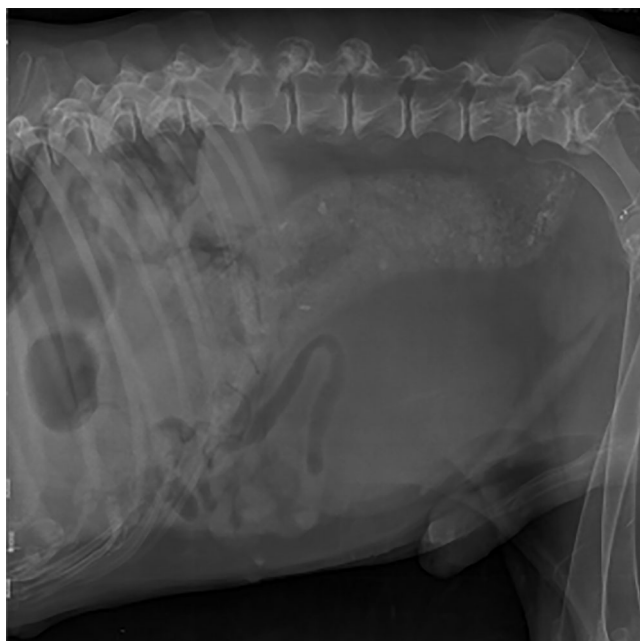


FIGURE 1 Right lateral abdominal radiography showing rectal compression, urinary bladder distension, and megacolon

Whole body computed tomography (CT) examination was performed under general anesthesia, which was induced using 4 mg/kg propofol (Propovet, Zoetis Italia Srl, Rome, Italy) and maintained with isoflurane in 100% oxygen (Isoflurane Vet, Merial, Lyon, France). Pre- and postcontrast examination was performed using a 16-slice CT scanner (Brightspeed, GE Healthcare, Milano, Italy). Computed tomography disclosed an ellipsoidal, well-defined multicavitary cystic mass, 48 × 53 × 70 mm in size, characterized by ring and heterogeneous contrast enhancement, with evidence of a thick enhancing wall, multiple septation, and distinctly marginated fluid-filled hypoattenuating cavities. The mass occupied up to 80% of the diameter of the pelvic canal on the transverse plane, with severe leftward compression of the rectum. The mass was located along the profile of the prostate gland, which was cranially displaced, but appeared within normal limits for size (18 × 32 × 35 mm) density and enhancement. No signs of abdominal or thoracic metastatic disease were identified. Differential diagnoses included prostatic mass (mesenchymal neoplasia, less likely prostatic or paraprostatic cyst or abscess), rectal wall exophytic neoplasia (eg, round cell tumor, carcinoma, less likely duplication cyst), and intrapelvic hemangiosarcoma. The day after CT, celiotomy with open subcapsular partial prostatectomy was scheduled.

The patient was sedated using dexmedetomidine 5 µg/kg IM (Dexdomitor, Vétoquinol Italia S.r.l., Bertinoro, Italy) and placed in dorsal recumbency. General anesthesia was induced using propofol 4 mg/kg (Propovet, Zoetis Italia S.r.l.) and maintained with isoflurane in 100% oxygen (Isoflurane Vet, Merial). The patient was catheterized and prepared for surgery.

A ventral midline celiotomy was performed, and a firm asymmetrical prostate gland, 9 cm in diameter, was observed. Large cysts were located along the dorsal prostatic profile adjacent to the colon. The cyst was drained of a brown liquid, and partial subcapsular prostatectomy was completed. The excised mass (Figure 3) was immersed in 10% buffered formalin and submitted for histopathology. The dog was neutered during the procedure.

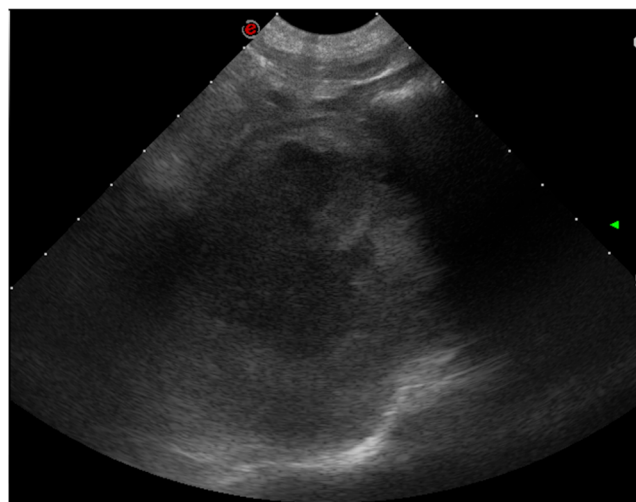


FIGURE 2 Ultrasonographic cystic appearance of pelvic mass

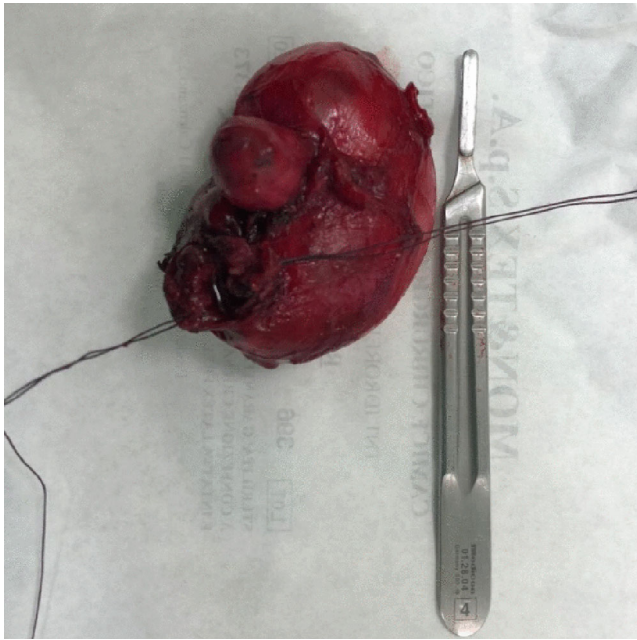


FIGURE 3 Prostatic tumor excised

Grossly, a large, well-defined, nonencapsulated grayish mass with a central pseudocystic cavity was observed. Sections of the mass were processed for histology, and embedded in paraffin. Sections (5 μm) were cut and stained with hematoxylin and eosin. Additional sections were immunostained (using the standard Avidin-Biotin Complex [ABC] method). Histologically, the neoplastic mass consisted of long, dense, irregularly interlaced bundles of spindle cells, multifocally separated by edema, demarcating a large necrotic and cystic central area infiltrated by degenerate neutrophils. Neoplastic cells exhibited poorly defined cell borders, fusiform nuclei with finely reticulated chromatin and multiple (1-3) small nucleoli, and a moderate amount of intensely eosinophilic cytoplasm. Moderate anisokaryosis and anisocytosis were evident, and mitoses ranged from 0 to 3 per high power field (7 mitoses/2.37 mm^2 ; Figure 4). Intense hyperemia and neutrophilic and lymphoplasmacytic mild multifocal infiltration were observed in the fibro-adipose tissue at the periphery of the mass.

Serial microtome sections of the mass also were processed for immunohistochemistry, applying the standard ABC method and antibodies against alpha smooth muscle actin (ASMA; clone 1A4, 1:2000 dilution; Dakocytomation, Glostrup, Denmark), vimentin (clone 3B4; 1:1000 dilution; Dakocytomation), and desmin (clone DER11; 1:200 dilution; Novocastra Laboratories, Newcastle, United Kingdom). Neoplastic cells were immunostained intensely with ASMA and desmin (Figures 5 and 6), and they were mostly negative for vimentin. Histological and immunohistochemical results were consistent with a diagnosis of leiomyosarcoma, most likely originating from the muscular component of the prostatic capsule.⁷⁻⁹

One month after surgery, follow-up with CBC, serum biochemistry, and abdominal ultrasound examination identified no abnormalities. At this time, the dog's owner consented to an adjuvant chemotherapy protocol using metronomic administration of

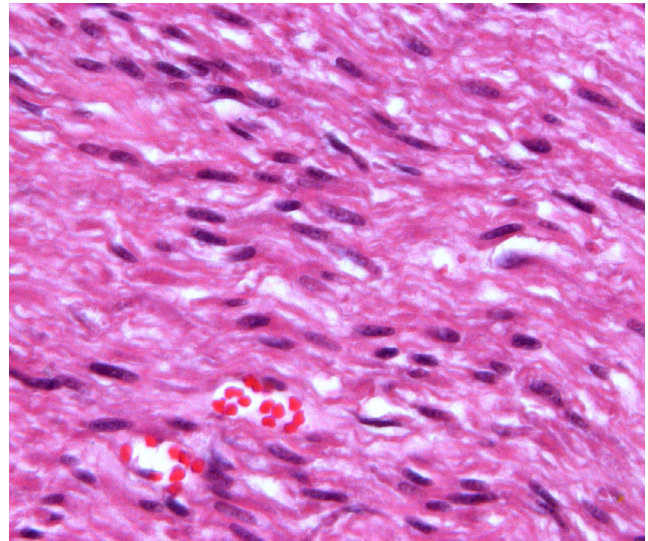


FIGURE 4 Neoplastic cells are spindle-shaped, organized in bundles, and characterized by cigar-shaped nuclei, and a moderate amount of intensely eosinophilic cytoplasm. Hematoxylin and eosin stain, original magnification $\times 20$

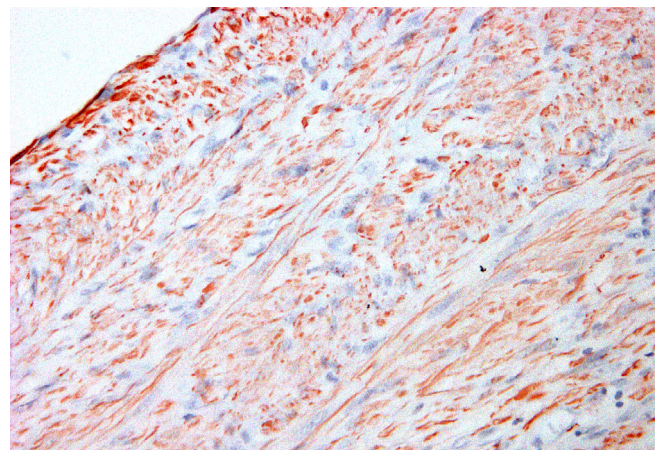


FIGURE 5 Neoplastic cells are diffusely and intensely desmin positive (aminoethyl carbazole chromogen, red staining). Desmin antibody stain, original magnification $\times 10$

cyclophosphamide at a dosage of 15 mg/m^2 PO q24h (Endoxan, Baxter, Italy) and the nonsteroidal anti-inflammatory drug firocoxib at a dosage of 5 mg/kg PO q24h (Previcox, Merial). The protocol consisted of monthly follow-up evaluations including clinical observation, CBC, and serum biochemistry. At the second follow-up, mild increases in renal function tests were detected, but they remained within the reference range. Consequently, administration of firocoxib was changed to q48h.

At the 3-month follow-up, urinalysis and abdominal ultrasound examinations were normal. Whole body CT examination was repeated 10 months after surgery, and no signs of local recurrence or distant metastasis were evident (Figure 7). The metronomic regimen was

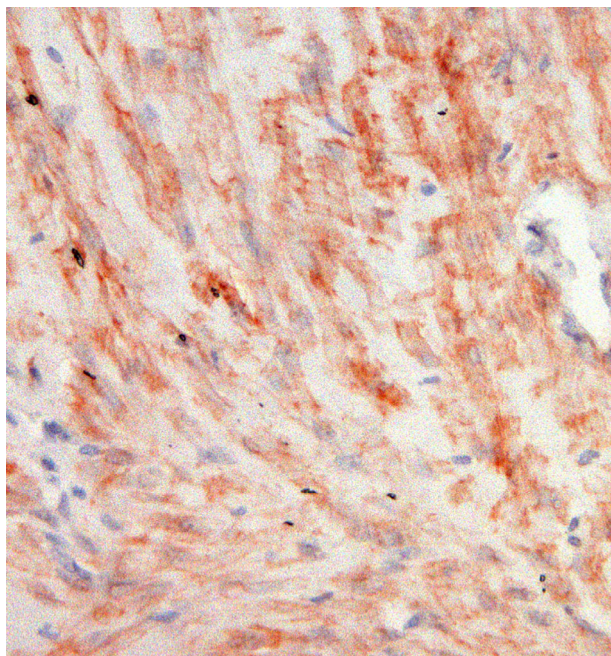


FIGURE 6 Alpha smooth muscle actin (α SMA), original magnification $\times 20$. Neoplastic cells are intensely and diffusely α SMA positive (aminoethyl carbazole chromogen, red staining)

discontinued after 15 months because of a persistent increase in serum creatinine concentration (1.7 mg/dL) and blood urea nitrogen concentration (98 mg/dL). No signs of local progression or distant metastasis were present at clinical examination at this time.

To our knowledge, this case represents the first report of a dog with prostatic leiomyosarcoma that underwent surgery and chemotherapy, resulting in successful outcome. In the veterinary literature, only 2 cases of prostatic leiomyosarcoma in dogs have been reported. Patients with this uncommon condition were characterized by poor,⁴ or no⁵ follow-up.

The prostate gland in dogs is covered by a fibromuscular capsule. Smooth muscle cells spread from the wall of urinary bladder binding the prostate capsule.⁸ Capsular trabeculae divide each prostatic lobe into lobules, with a stroma consisting of collagen fibers, fibroblasts, and smooth muscle. The smooth muscle cells localized in the periphery of the prostate enable prostatic contraction. Leiomyoma is a rare benign tumor, and only 1 case has been reported in male dogs,¹⁰ whereas prostatic leiomyosarcoma is a malignant and aggressive neoplasm with only 2 cases reported in the literature.^{4,5}

The dogs diagnosed with prostatic leiomyosarcoma in previous reports were 6 and 10 years old, and presented for evaluation of stranguria, dyschezia, and urinary incontinence. Diagnosis in previous cases was made using ultrasound-guided biopsy, prostatectomy, or necropsy. At the time of diagnosis, previously reported cases had metastasized to the lungs,^{4,5} regional lymph nodes, mesentery, and kidneys.⁴

No signs of vertebral metastasis have been identified in our patient or in the cases reported previously. The CT study in our case and necropsy in the previously reported cases did not show any

vertebral involvement. This result may have been associated with the imaging technique limitations and none of the patients had other more sensitive and specific procedures for the detection of skeletal metastases performed.¹¹ Other malignant prostatic tumors such as prostatic carcinoma are characterized by bone metastases,¹² both in human beings and in dogs.¹³ One of the main sites of metastatic bone distribution in prostatic carcinoma is the axial skeleton, in particular the lumbosacral vertebrae.⁹

The reason for this metastatic pathway can be explained by Batson's plexus.¹⁴ This anatomical structure is a vertebral valveless network of veins, present both in humans and dogs. In dogs, the plexus system, also known as vertebral venous plexuses, is composed of internal and external components.⁸ Prostatic tumor cells may metastasize by this route forming metastatic tumors in the lumbar vertebrae via a low-pressure, high-volume system. This metastatic spread of cells is subjected to retrograde movement, following a pressure mass effect that may happen during defecation, coughing, or after changes in recumbency.¹⁵

The origin and course of smooth muscle cells from the urinary bladder wall to the prostate capsule may be responsible for infiltration of the urinary bladder musculature, as reported in the literature.¹⁶ In our case, the prostatic neoplasia was exophytic, not infiltrating the surrounding structures, particularly the urethra and urinary bladder.

Diagnostic imaging features of prostatic leiomyosarcoma were described in a previous report.⁵ Ultrasonographic findings included a large heterogenous prostatic mass, characterized by a hyperechoic area surrounded by a hypoechoic band and the presence of large cystic lesions. The mass was reported to be hypoechoic compared to surrounding tissues after contrast medium injection. Computed tomography disclosed a large asymmetric and irregularly shaped prostate gland, heterogeneously attenuating, including large cystic areas. Contrast enhancement was minimal and heterogenous, with no enhancement of the cystic content. In a second case report,⁴ prostatic leiomyosarcoma was described radiographically as a caudal abdominal calcified mass. In both reports,^{4,5} lung nodules were present, consistent with metastatic disease and, in 1 of the 2 cases, severe diffuse metastatic lymphadenopathy also was observed.

In our case, the pelvic mass was not mineralized and no extension into the surrounding structures or regional lymph nodes enlargement was observed, suggesting a probable benign nature of the mass.¹⁷ Moreover, lung metastases were not detected. On both ultrasonography and CT, the origin of the mass was not clear, but its exophytic distribution resembled that described in a former case report of prostatic leiomyoma,¹⁰ supporting the diagnosis of a benign mass. However, the previously reported prostatic leiomyoma appeared as a homogenous soft tissue attenuating mass with homogenous contrast enhancement on CT, whereas in our case some large cyst-like hypoattenuating areas with no contrast enhancement were present, as previously reported in prostatic leiomyosarcoma,^{4,5} prostatic hemangiosarcoma,¹⁸ and malignant intrapelvic masses.^{19,20}

In our case, despite the absence of metastatic disease and evidence of aggressive features typical of malignant neoplasms, necropsy identified a malignant neoplasm compatible with leiomyosarcoma.

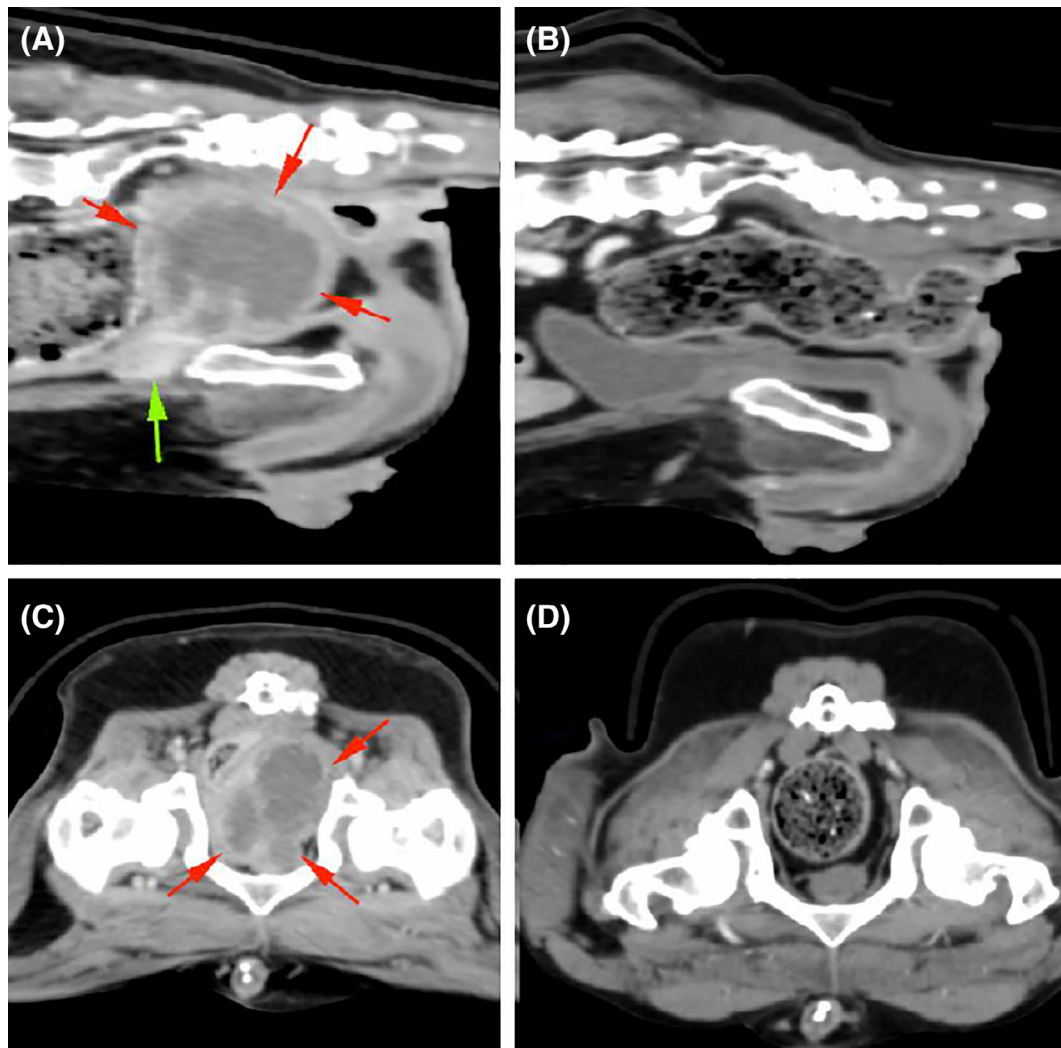


FIGURE 7 A,C, Sagittal and transverse computed tomography (CT) images acquired before surgery, revealing prostate gland (green arrow) and the cystic mass (red arrows). B,D, Sagittal and transverse images from follow-up CT examination revealing no evidence of recurrence

Moreover, the lack of prostatic calcification, which might be indicative of a chronic prostatitis or neoplasia such as adenocarcinoma, was absent in this case.²¹ Recently, features of lymphoma affecting the prostatic gland were reported on ultrasound examination with typical hypoechoic appearance associated with lymphadenopathy, which was not supported in our findings of a cystic mass without lymphadenopathy.²²

Because of the rarity of primary leiomyosarcoma, the therapeutic approach remains unclear, and multimodal treatment is recommended.²³

In our case, the patient underwent partial subcapsular prostatic resection. The decision to perform a partial prostatectomy was made to avoid pubic symphysiotomy in an older dog with severe degenerative disease of the coxofemoral joints. A standard ventral approach was used to avoid the main prostatic vessels, mitigate hemorrhage, and obtain a clear surgical field. Total prostatectomy has been associated with a high incidence of postoperative incontinence,²⁴ but has yielded no increase in survival time in patients with prostatic diseases.²⁵

When chemotherapy was proposed, ifosfamide, cyclophosphamide, or dacarbazine have been the chemotherapeutic agents commonly selected in human medicine.²⁶ Metronomic chemotherapy was reported to decrease cutaneous soft tissue sarcoma recurrence in dogs,²⁷ but no data are available for visceral sarcomas. Adjuvant therapy options were discussed with the owner and metronomic chemotherapy was chosen with consideration of the patient's quality of life and owner compliance (ie, better tolerability and low cost).

No long-term follow-up was described in the clinical cases previously reported in the literature.^{4,5} One of the 2 cases was euthanized because of poor prognosis and the other died during hospitalization. As a particularly aggressive but rare cancer in veterinary medicine, information regarding clinical monitoring of these patients is lacking. The novelty of our case was the multimodal therapeutic approach and long postoperative follow-up, which ultimately yielded good outcome (survival 15 months after surgery, with no sign of distant metastases or local recurrence, based on CT; Figure 7B,D).

The main limitation of our study was the fact that it was only a single case, which reflects the rarity of this type of tumor in dogs. Multimodal treatment using partial subcapsular prostatectomy and adjuvant metronomic chemotherapy in an older patient with localized cancer therefore may be indicated in dogs presenting with cystic exophytic masses suggestive of prostatic leiomyosarcoma.

ACKNOWLEDGMENT

No funding was received for this study.

CONFLICT OF INTEREST DECLARATION

Authors declare no conflict of interest.

OFF-LABEL ANTIMICROBIAL DECLARATION

Authors declare no off-label use of antimicrobials.

INSTITUTIONAL ANIMAL CARE AND USE COMMITTEE (IACUC) OR OTHER APPROVAL DECLARATION

Authors declare no IACUC or other approval was needed.

HUMAN ETHICS APPROVAL DECLARATION

Authors declare human ethics approval was not needed for this study.

ORCID

Marco Trovattelli  <https://orcid.org/0000-0003-2413-9499>

REFERENCES

- Krawiec DR, Heflin D. Study of prostatic disease in dogs: 177 cases (1981-1986). *J Am Vet Med Assoc.* 1992;200:1119-1122.
- Teske E, Naan EC, van Dijk EM, van Garderen E, Schalken JA. Canine prostate carcinoma: epidemiological evidence of an increased risk in castrated dogs. *Mol Cell Endocrinol.* 2002;197:251-255.
- Swinney G. Prostatic neoplasia in five dogs. *Aust Vet J.* 1998;76:669-674.
- Hayden DW, Klausner JS, Waters DJ. Prostatic leiomyosarcoma in a dog. *J Vet Diagn Invest.* 1999;11:283-286.
- Bacci B, Vignoli M, Rossi F, et al. Primary prostatic leiomyosarcoma with pulmonary metastases in a dog. *J Am Anim Hosp Assoc.* 2010;46:103-106.
- O'Brien TR. *Radiographic diagnosis of abdominal disorders in the dog and cat: Radiographic interpretation, clinical signs, pathophysiology.* Philadelphia, USA; Eastbourne; W.B. Saunders; 1978.
- McNeal JE. Normal histology of the prostate. *Am J Surg Pathol.* 1988;12:619-633.
- Evans H, de Lahunta A. *Miller's Anatomy of the Dog.* 4th ed. St. Louis, Missouri, USA: Saunders; 2012.
- Sun F, Báez-Díaz C, Sánchez-Margallo FM. Canine prostate models in preclinical studies of minimally invasive interventions: part I, canine prostate anatomy and prostate cancer models. *Transl Androl Urol.* 2017;6:538-546.
- Holdsworth A, Bléhaut T, Reeve L, et al. An incidental prostatic leiomyoma in a dog. *Vet Rec Case Rep.* 2015;3:1-5.
- Heindel W, Gübitz R, Vieth V, Weckesser M, Schober O, Schäfers M. The diagnostic imaging of bone metastases. *Dtsch Arztebl Int.* 2014;111(44):741-747.
- Abrahamsson P-A. Pathophysiology of bone metastases in prostate cancer. *Eur Urol Suppl.* 2004;3:3-9.
- Rosol TJ, Tannehill-Gregg SH, Corn S, Schneider A, McCauley LK. Animal models of bone metastasis. *Cancer Treat Res.* 2004;118:47-81.
- Suzuki T, Kurokawa K, Okabe K, Ito K, Yamanaka H. Correlation between the prostatic vein and vertebral venous system under various conditions. *Prostate.* 1992;21:153-165.
- Resnik MI. Hemodynamics of prostate bone metastases. Karr JP, Yamanaka H (Eds.), *Prostate Cancer and Bone Metastasis (Advances in Experimental Medicine and Biology).* Boston, MA: Springer; 1992:77-81.
- Tazi K, Moudouni SM, Elfassi J, et al. Leiomyosarcoma of the prostate: a study of two cases. *Ann Urol.* 2001;35:56-59.
- Mattoon JS, Nyland TG. Prostate and testes. *Small Animal Diagnostic Ultrasound.* 2nd ed. Philadelphia, PA: W.B. Saunders; 2001:250-266.
- Della Santa D, Dandrieux J, Psalla D, et al. Primary prostatic haemangiosarcoma causing severe haematuria in a dog. *J Small Anim Pract.* 2008;49:249-251.
- Spector DI, Fischetti AJ, Kovak-McClaran JR. Computed tomographic characteristics of intrapelvic masses in dogs. *Vet Radiol Ultrasound.* 2011;52(1):71-74.
- Yoo S, Kim J, Myung H, et al. Primary intrapelvic hemangiosarcoma in a dog. *J Vet Med Sci.* 2016;79(1):192-196.
- Bradbury CA, Westropp JL, Pollard RE. Relationship between prostatomegaly, prostatic mineralization, and cytologic diagnosis. *Vet Radiol Ultrasound.* 2009;50(2):167-171.
- Di Donato P, Zweifel R, Koehler K, et al. Predominance of hypochoic tissue changes in nine dogs with malignant prostatic lymphoma. *Vet Radiol Ultrasound.* 2019;60(1):75-80.
- Venyo AK. A review of the literature on primary leiomyosarcoma of the prostate gland. *Adv Urol.* 2015;2015:485786.
- L'Eplattenier HF, van Nimwegen SA, van Sluijs FJ, et al. Partial prostatectomy using Nd:YAG laser for management of canine prostate carcinoma. *Vet Surg.* 2006;35:406-411.
- White RA. Prostatic surgery in the dog. *Clin Tech Small Anim Pract.* 2000;15:46-51.
- Chen W, Han DJ, Fu GQ, et al. Long term follow-up of surgery management of prostate leiomyosarcoma metastasized to the rib: a case report and literature review. *Mol Clin Oncol.* 2016;5:132-134.
- Elmslie RE, Glawe P, Dow SW. Metronomic therapy with cyclophosphamide and piroxicam effectively delays tumor recurrence in dogs with incompletely resected soft tissue sarcomas. *J Vet Intern Med.* 2008;22(6):1373-1379.

How to cite this article: Trovattelli M, Bassi J, Giudice C, Ferrari R, Longo M, Brizzola S. Prostatic leiomyosarcoma in a dog treated using a multimodal approach. *J Vet Intern Med.* 2021;35:1105-1110. <https://doi.org/10.1111/jvim.16081>