Regional Patterns of Fluid and Fat Accumulation in Patients with Lower Extremity Lymphedema Using Magnetic Resonance Angiography

Sir:

We read with interest the article entitled "Regional Patterns of Fluid and Fat Accumulation in Patients with Lower Extremity Lymphedema Using Magnetic Resonance Angiography," by Dayan et al.[1] They are to be congratulated for their work examining fluid and fat distribution in patients affected by primary or secondary lower extremity lymphedema on magnetic resonance imaging. Even if the acquisition parameters were not provided, the protocol included postcontrast T1-weighted sequences without fat saturation, shown in the figures. However, to best highlight the fluid infiltration that characterizes lower extremity lymphedema, heavily T2-weighted sequence with a long repetition time/echo time,[2,3] and short tau inversion recovery[4] were successfully used in the analysis of lower extremity lymphedema and lymphatic vessels.[2,3]

Therefore, we applied the scoring for fluid and fat accumulation proposed by the authors[1] to 50 patients (25 women and 25 men; age range, 35 to 77 years; mean age, 62 ± 11 years) affected by secondary lower extremity lymphedema of the lower limb, after lymphadenectomy related to prostatic cancer [n = 20 (40 percent)], endometrial cancer [n = 14 (28 percent)], cervical cancer [n = 9 (18 percent)], melanoma [n = 4 (8 percent)], and lymphoma [n = 3 (6 percent)], from our lower extremity lymphedema case series, who were studied with noncontrast magnetic resonance lymphography, including a three-dimensional short tau inversion recovery (repetition time, 3000 msec; echo time, 254 msec; inversion time, 160 msec; field of view, 460 × 504 mm; matrix, 315 × 384 pixels; slice thickness, 1 mm), that was used for the analysis (Fig. 1). As 24 (48 percent) of our patients showed bilateral lower extremity lymphedema (Fig. 2), the scoring for fat accumulation was applicable only in 26. This study received institutional review board approval (experiment no. 2019/ST/187; protocol no. 47427/2019).

Imaging evaluation was based on visual assessment and was performed by two independent readers (radiologists experienced in lower extremity lymphedema); the interreader agreement was estimated with Light kappa values with 95 percent confidence interval using IBM SPSS Version 20 (IBM Corp., Armonk, N.Y.).

On our magnetic resonance images, all patients showed fluid accumulation (100 percent).

Fig. 1. Coronal short tau inversion recovery image showing the legs of a female patient who developed lower extremity lymphedema after lymphadenectomy for cervical cancer. According to the article by Dayan et al. (Dayan JH, Wiser I, Verma R, et al. Regional patterns of fluid and fat accumulation in patients with lower extremity lymphedema using magnetic resonance angiography. *Plast Reconstr Surg*. 2020;145:555–563. DOI: 10.1097/PRS.0000000000006520), the patient was graded as fluid 2/fat 0. *White arrows* show deep lymph accumulation in the epifascial compartment, without significant fat accumulation. The contiguous fluid stripe along the lateral leg is consistent with fluid grade 2.

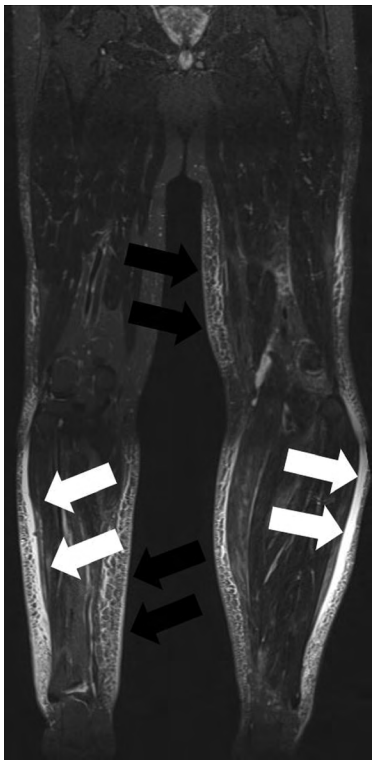

Fig. 2. Composing function of short tau inversion recovery sequences acquired in a female patient submitted to lymphadenectomy for uterine cancer. The lower extremity lymphedema was bilateral, with evidence of continuous fluid stripes on both sides (*white arrows*). A bilateral honeycomb pattern was also present (*black arrows*), with enlargement of the subcutaneous fat. The effect on both limbs prevents the application of the classification relating to the accumulation of fat.

Interobserver agreement was perfect in its grading, with a Light kappa of 1. Most patients showed some degree of fat accumulation [n = 40 (80 percent)], but most frequently it was located in the thigh [30 of 40 (75 percent)]. For fat grading, the Light kappa was 0.765 (95 percent CI, 0.521 to 0.941), slightly inferior to that reported in the study by Dayan et al.[1] The different results can be explained by the lower number of cases included in our analysis and by the fact that our assessment was based on visual assessment: in the reference study,[1] it was not specified whether measurements were made between the affected and unaffected limbs.

In conclusion, we observed that fluid accumulation grading showed excellent reproducibility, higher in short tau inversion recovery sequences aimed at highlighting fluids. In grading of fat accumulation, the main limitation of the proposed scoring, highlighted by our experience, was related to the nonapplicability in patients affected by bilateral lower extremity lymphedema, 48 percent in our case series. The study by Sen et al.[5] proposed a new threshold-based level set segmentation technique to differentiate fat, muscle, and lymph fluid on magnetic resonance imaging in lower extremity lymphedema patients. This method needs to be validated by further studies but could represent a useful tool in the selection of eligible liposuction candidates and follow-up of lower extremity lymphedema patients. Again, we congratulate Dr. Dayan et al. for their study and for striving to optimize imaging assessment of patients affected by lower extremity lymphedema.

DOI: 10.1097/PRS.0000000000007299

Michaela Cellina, M.D.
Radiology Department
Fatebenefratelli Hospital
Aziende Socio Sanitarie Territoriale Fatebenefratelli Sacco

Marta Panzeri, M.D.
Radiology Department
San Raffaele Hospital

Massimo Soresina, M.D.

Andrea Menozzi
Plastic Surgery Department
Fatebenefratelli Hospital
Aziende Socio Sanitarie Territoriale Fatebenefratelli Sacco

Carlo Martinenghi, M.D.
Radiology Department
San Raffaele Hospital

Daniele Gibelli, M.D., Ph.D.
Department of Biomedical Sciences for Health
University of Milan
Milano, Italy

Correspondence to Dr. Cellina
Radiology Department
Fatebenefratelli Hospital
Aziende Socio Sanitarie Territoriale Fatebenefratelli Sacco
Piazza Principessa Clotilde 3
Milano 20121, Italy
michaela.cellina@asst-fbf-sacco.it

DISCLOSURE

The authors declare no conflicts of interest.

REFERENCES

1. Dayan JH, Wiser I, Verma R, et al. Regional patterns of fluid and fat accumulation in patients with lower extremity lymphedema using magnetic resonance angiography. *Plast Reconstr Surg.* 2020;145:555–563.
2. Arrivé L, Derhy S, Dahan B, et al. Primary lower limb lymphoedema: Classification with non-contrast MR lymphography. *Eur Radiol.* 2018;28:291–300.
3. Cellina M, Oliva G, Menozzi A, Soresina M, Martinenghi C, Gibelli D. Non-contrast magnetic resonance lymphangiography: An emerging technique for the study of lymphedema. *Clin Imaging* 2019;53:126–133.
4. Borri M, Gordon KD, Hughes JC, et al. Magnetic resonance imaging-based assessment of breast cancer-related lymphoedema tissue composition. *Invest Radiol.* 2017;52:554–561.
5. Sen Y, Qian Y, Koelmeyer L, et al. Breast cancer-related lymphedema: Differentiating fat from fluid using magnetic resonance imaging segmentation. *Lymphat Res Biol.* 2018;16:20–27.

Timing of Microsurgical Reconstruction in Lower Extremity Trauma: An Update of the Godina Paradigm

Sir:

The study by Lee et al. investigating the optimal timing of flap reconstruction in lower extremity trauma is timely, as this remains a hot topic among surgeons worldwide.[1] Using a multi-institutional registry, the authors found that flaps performed less than or equal to 3 days after injury had 60 percent lower likelihood of major flap complications versus those performed after 4 to 90 days. Cases were divided into three new groups: less than or equal to 3 days, 4 to 9 days, and 10 to 90 days. Multivariable analyses then found that outcomes did not differ significantly between the less than or equal to 3-day and 4- to 9-day groups. Although the authors conclude that reconstruction can therefore be safely extended to less than or equal to 10 days of injury, we believe this requires careful interpretation.

The goal in traumatic lower extremity reconstruction is to restore function and minimize complications.[2] Nonunion, infection, osteomyelitis, and amputations are all outcomes that may adversely affect long-term lower limb function, and may be affected by the timing of reconstruction.[3,4] However, these outcomes were not assessed in the study. Moreover, delay in definitive reconstruction may also unnecessarily expose patients to various hospital-admission–related risks, including deep venous thrombosis, and delays rehabilitation.[5,6] The authors' conclusion that reconstruction can be safely extended to less than or equal to 10 days after injury only holds from the perspective of flap outcomes and therefore seems somewhat overdrawn.

Second, the authors raise negative-pressure wound therapy as a contributing factor for their findings.