

**CASE REPORT**

# Progressive growth of coronary aneurysms after bioresorbable vascular scaffold implantation: Successful treatment with OCT-guided exclusion using covered stents

Franco Fabbiochi MD<sup>1</sup> | Giuseppe Calligaris MD<sup>1</sup> | Antonio L. Bartorelli MD, FACC<sup>1,2</sup><sup>1</sup>Centro Cardiologico Monzino, IRCCS, Milan, Italy<sup>2</sup>Department of Biomedical and Clinical Sciences "Luigi Sacco", University of Milan, Milan, Italy**Correspondence**

Franco Fabbiochi, MD, Via C. Parea 4, 20138 Milan, Italy.

Email: franco.fabbiochi@ccfm.it

**Abstract**

The development and progressive enlargement over time of multiple saccular coronary artery aneurysms (CAA) after implantation of everolimus-eluting stent and bioresorbable vascular scaffolds (BVS) have been reported. CAA was successfully excluded by two overlapped covered stents expanded inside a long metallic drug-eluting stent to avoid dislodgment at the overlap point. Optical coherence tomography (OCT) was repeatedly performed to monitor CAA expansion and to guide treatment through precise measurement of aneurysm length and vessel size at the landing zone. At 10-month follow-up, coronary computed tomography angiography showed persistent CAA exclusion. To the best of our knowledge, this is the first report of this technique to exclude a long CCA segment.

**KEYWORDS**

coronary imaging, percutaneous intervention, vascular ectasia

**1 | INTRODUCTION**

Coronary artery aneurysm (CAA) development after bioresorbable vascular scaffold (BVS) implantation is uncommon and its treatment is not well established. We describe a case of acquired formation of multiple saccular aneurysms of the left anterior descending coronary artery (LAD) after BVS implantation and their progressive enlargement over time. Successful CAA exclusion was achieved with optical coherence tomography (OCT)-guided implantation of covered stents.

**2 | CASE REPORT**

A 50-year-old male, smoker and hyperlipidemic was hospitalized with anterior STEMI in a second level center. Emergency coronary angiography revealed subocclusion of the proximal left anterior descending coronary artery and subcritical disease of the mid and distal segments

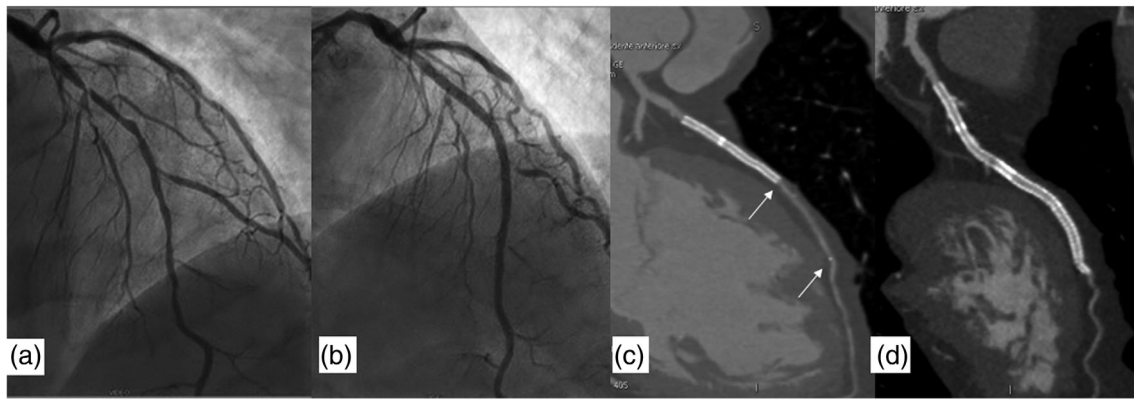
of the vessel. Primary PCI was performed with implantation of a metallic zotarolimus-eluting stent (ZES) (Resolute Onyx 2.75 × 18 mm, Medtronic, Santa Rosa, CA) (Figure 1a). Ten days later, the mid and distal diseased segments of the LAD were treated with elective implantation of two everolimus-eluting BVS (Absorb 2.5 × 28 mm + 2.5 × 12 mm, Abbott Vascular, Santa Clara, CA), while a metallic everolimus-eluting stent (EES) (Sinergy 2.75 × 28 mm, Boston Scientific, San José, CA) (Figure 1b) was deployed proximally to the BVS. Intravascular imaging was not performed at that time.

At 4-month follow-up, the patient was referred to our center because of chest pain at rest. Coronary computed tomography angiography (CCTA) showed patency and correct apposition of both metallic drug-eluting stents and BVS with normal lumen appearance (Figure 1c).

After 9 months, he was admitted to our emergency department because of recurrent chest pain. A rise of high-sensitivity troponin prompted urgent coronary angiography that showed multiple saccular

This is an open access article under the terms of the Creative Commons Attribution-NonCommercial License, which permits use, distribution and reproduction in any medium, provided the original work is properly cited and is not used for commercial purposes.

© 2020 The Authors. *Catheterization and Cardiovascular Interventions* published by Wiley Periodicals LLC.



**FIGURE 1** Coronary angiography showing severe stenosis of the proximal left anterior descending (LAD) coronary artery and moderate disease of the mid and distal segment of the vessel (a). Angiographic result after percutaneous revascularization with implantation of a single metallic zotarolimus-eluting stent (Resolute Onyx  $2.75 \times 18$  mm), one metallic EES (Sinergy  $2.75 \times 28$  mm), and two overlapping BVS (Absorb  $2.5 \times 28$  mm + Absorb  $2.5 \times 12$  mm) in the mid and distal LAD segment (b). CCTA multiplanar reconstruction at 4-month follow-up showing patency and correct apposition of the metallic DES with normal lumen appearance at the site of BVS implantation. Note the two BVS radiopaque markers (arrows) (c). Ten months after covered stent implantation, CCTA showed stent patency without restenosis and persistence of CAA exclusion (d)

CAA involving the mid and distal segments of the LAD previously treated with the BVS (Figure 2a). Intracoronary imaging with OCT (OPTIS Integrated System and DragonFly Imaging Catheter, Abbot Vascular, Santa Clara, CA) confirmed the presence of multiple aneurysmal dilations surrounding the central portion of the BVS and showed unopposed and floating polymeric struts (Figure 2b). A small aneurysm was also visible at the level of the metallic EES. We decided for a conservative approach and indefinite dual antiplatelet therapy (DAPT) was prescribed to prevent thrombus formation.

Although the patient had no symptoms, a follow-up coronary angiography was performed 27 months after the index PCI. The exam showed that the CAA had significantly increased in diameter and longitudinal extension (Figure 2c). In view of the progressive growth and the perceived risk of thrombosis, we decided to proceed with a percutaneous treatment.

Via a radial access, a 6 F large lumen guide catheter was positioned in the left main coronary artery and a guide extension (GuidELiner, Vascular Solutions, Sycamore, MN) was advanced to the mid LAD in order to achieve good back-up support and to provide adequate blood exclusion required for OCT imaging. The OCT scan showed that BVS geometry was preserved at the distal edge with complete endothelialization, while further CAA enlargement was visible in most of the BVS-treated segment. In this segment, partial strut degradation interspaced with residual struts embedded in the arterial wall was also observed. Restenosis at the overlap between the BVS and the EES was also visible (Figure 2d). Furthermore, focal vessel ectasia persisted around the EES, while the ZES was completely opposed to the coronary artery wall. Considering that no major side branches took off from the coronary segment with multiple CAA, we decided to treat the patient with polyurethane membrane covered stent implantation (PK Papyrus, Biotronik, Bulach, Switzerland). The length of the aneurysmatic vessel segment was assessed with OCT automatic longitudinal reconstruction and measured 42.6 mm, which

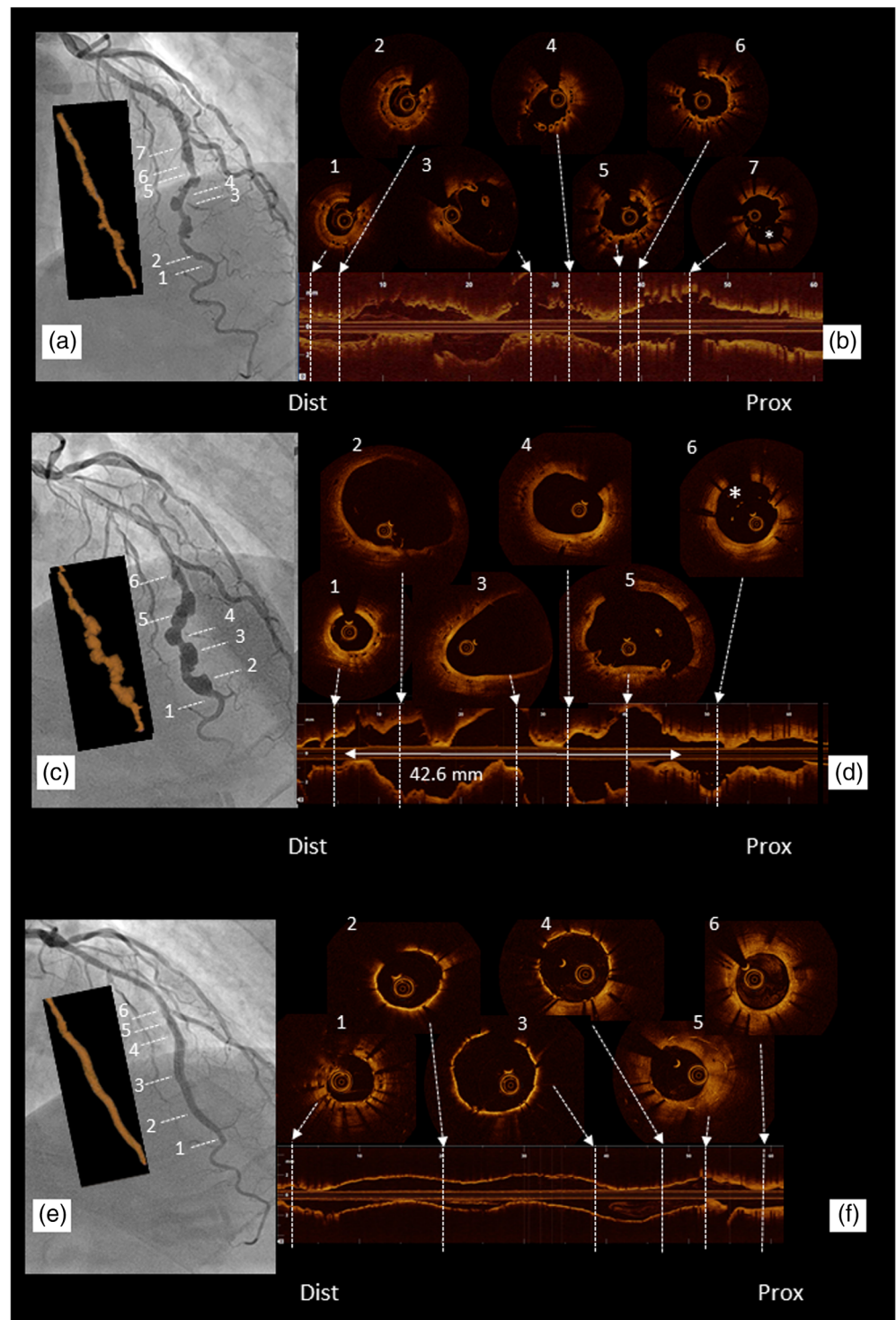
is longer than the maximal length of the available Papyrus covered stent (26 mm), thus requiring implantation of two devices. Our concern was the risk of articulation and dislodgement of the overlapping Papyrus covered stents due to the lack of apposition and anchoring inside the large aneurysmal segment.<sup>1,2</sup> Therefore, we first deployed a long metallic EES ( $2.5 \times 48$ -mm, Xience Xpedition; Abbot Vascular, Santa Clara, CA) across the CCA that was anchored to the proximal and distal ends of the aneurysmatic segment. We then implanted two Papyrus covered stents inside the metallic EES ( $2.5 \times 20$ -mm +  $3.0 \times 26$ -mm) with approximately 3-mm overlapping. Finally, postdilation with  $2.5 \times 15$ -mm and  $3.0 \times 15$ -mm NC balloons at 20 atm was performed. Complete CAA exclusion without leaks was confirmed with angiography (Figure 2e), while OCT showed complete covered stent expansion with a minimal stent area of  $5.48 \text{ mm}^2$  and a minimal lumen diameter of 2.64 mm (Figure 2f).

The patient was discharged the following day with life-long DAPT. At 10-month follow-up after covered stent implantation, he was asymptomatic and CCTA showed vessel patency, no dislodgment of covered stents, and persistence of CAA exclusion (Figure 1d).

### 3 | DISCUSSION

Acquired CAA following first-generation DES implantation is rare and their occurrence has been extensively described. Although underlying mechanisms remain unclear, DES components (antiproliferative drug, polymer, and stent strut) might cause vessel wall damage with subsequent hypersensitivity reactions and inflammatory changes of the medial wall affecting the vascular remodeling process.<sup>3-5</sup> There have been fewer reports of CAA formation after implantation of second- and third-generation DES probably due to improvements in the drug-polymer combination and reduction in strut thickness.<sup>6</sup> After BVS implantation, the formation of invaginations in the arterial wall is

**FIGURE 2** Coronary angiography and corresponding OCT imaging. Coronary angiography and three-dimensional OCT reconstruction 9 months after the index procedure showing multiple saccular CAA involving the mid-distal LAD previously treated with BVS (a). OCT longitudinal view and cross-sectional images from distal to proximal show the BVS distal segment well apposed and covered by a discrete neointima (1,2), vascular ectasia with floating struts (3,4), BVS-EES overlap with some white thrombus (5,6), and the metallic EES aneurysm (7, asterisk) (b). Significant increase in CAA size was evident at 27-month follow-up angiography and three-dimensional OCT reconstruction (c). OCT longitudinal view and cross-sectional images demonstrate huge increase in diameter and extension of the aneurysmatic segment (42.6 mm) not involving the BVS edges (1). Black boxes are still visible in some frames (1,3,4) together with unopposed and floating struts (5). A focal aneurysmatic dilation persists around the metallic EES (6, asterisk) (d). After implantation of two PK Papyrus covered stents inside a 48-mm long DES, coronary angiography and three-dimensional OCT reconstruction show complete exclusion of the long CAA segment (e). OCT longitudinal view and cross sectional images from the distal landing zone (1), through the PK Papyrus segments (2,3,4) and to the metallic EES (Synergy) with moderate hyperplasia (5) and endothelialization (6) (f) [Color figure can be viewed at [wileyonlinelibrary.com](http://wileyonlinelibrary.com)]



common and may lead to aneurysm development months after BVS placement.<sup>7</sup> The resulting strut malapposition and intraluminal bioresorption compromise the laminary flow and facilitate thrombosis.<sup>8,9</sup> Although aneurysms are predominantly focal,<sup>10,11</sup> progressive dilation was also reported by Varghese et al., 6 month after deployment of a 3.0 × 18-mm BVS in the left circumflex coronary artery with further enlargement at 12-month follow-up.<sup>12</sup>

Patients with large CAA may be clinically silent and incidentally detected during coronary angiography or CCTA. Nevertheless, acute coronary syndrome can develop due to occlusive thrombosis or distal thrombus embolization, particularly in the event of progressive increase of CAA size.<sup>9,10</sup> Patel et al. described a case of BVS bioresorption and thrombus formation leading to an acute coronary syndrome due to distal embolization 32 months after initial BVS

placement.<sup>8</sup> Furthermore, previous studies demonstrated that CAA are associated with higher rate of major adverse cardiac events, mainly driven by myocardial infarction and target lesion revascularization.<sup>11</sup> As treatment strategies are not clearly defined, due to the lack of randomized trials and published guidelines, CAA management should be individualized based on patient characteristics, clinical presentation and CAA location, morphology, and size. Our case is a unique report of multiple large aneurysms subsequent to BVS placement with progressive enlargement and longitudinal extension, whose treatment was justified by the perceived risk of thrombosis. Treatment options, apart from medical management, include surgical excision, coronary bypass grafting, and percutaneous intervention. In view of the distal LAD site of the CAA, surgical treatment was excluded. Thus, despite percutaneous CAA treatment is not well defined and is associated with technical challenges,<sup>13,14</sup> we decided to treat the patient with PK Papyrus covered stents because the aneurysmatic segment did not involve major side branches. We chose this device due to its advanced covered single-stent design that has greater flexibility and smaller crossing profile than the Graftmaster stent (Abbot Vascular, Santa Clara, CA), which is made of an ultra-thin layer of expandable polytetrafluoroethylene placed between two stents using a sandwich technique. As dislodgement of covered stent with consequent coronary thrombosis was reported in case of incomplete anchorage in aneurysmatic segments of the vessel,<sup>1,2</sup> we used a new technique consisting in the placement of two covered stents inside a long metallic EES placed from "nondilated to nondilated" landing segments. Pre-intervention OCT imaging played a key role to measure precisely the length of the aneurysmatic segment, to identify proximal and distal landing zones, and for choosing the appropriate stent size in order to obtain complete sealing. Moreover, the presence of a DES behind the covered stents may have played a role in preventing restenosis.<sup>15</sup> Indeed, the technique proved effective and we were able to exclude the CAA with good clinical and CCTA results at 10-month follow-up.

## 4 | CONCLUSION

Development of CAA after BVS implantation is uncommon and its treatment is not well established. When CAA enlarge over time, thrombosis or rupture risk may increase and exclusion by covered stent implantation may be indicated. In case of an aneurysmatic segment longer than the available covered stents, successful treatment can be achieved with OCT-guided covered stent implantation inside a previously deployed long metallic DES.

### ORCID

Franco Fabbiochi  <https://orcid.org/0000-0001-9452-1664>

## REFERENCES

1. Chou HH, Huang HL, Ko YL. Acute myocardial infarction due to prolapse of covered stent into coronary artery aneurysm. *JACC Cardiovasc Interv.* 2018;11:e147-e148.
2. Kaneko U, Kashima Y, Hashimoto M, Fujita T. Very late stent migration within a giant coronary aneurysm in a patient with Kawasasaki disease. *JACC Cardiovasc Interv.* 2017;10:1799-1800.
3. Bavry AA, Chiu JH, Jefferson BK, et al. Development of coronary aneurysm after drug-eluting stent implantation. *Ann Intern Med.* 2007;146:230-232.
4. Aoki J, Kirtane A, Leon MB, Dangas G. Coronary artery aneurysms after drug-eluting stent implantation. *J Am Coll Cardiol Intv.* 2008;1:14-21.
5. Kim U, Seol SH, Kim DI, et al. Clinical outcomes and the risk factors of coronary artery aneurysms that developed after drug-eluting stent implantation. *Circ J.* 2011;75:861-867.
6. Hong SJ, Kim H, Ahn CM, et al. Coronary artery aneurysm after second-generation drug-eluting stent implantation. *Yonsei Med J.* 2019;60:824-831.
7. Gori T, Jansen T, Weissner M, et al. Coronary evaginations and periscaffold aneurysms following implantation of bioresorbable scaffolds: incidence, outcome, and optical coherence tomography analysis of possible mechanisms. *Eur Heart J.* 2016;37(26):2040-2049.
8. Patel A, Nazif T, Stone GW, Ali ZA. Intraluminal bioresorbable vascular scaffold dismantling with aneurysm formation leading to very late thrombosis. *Catheter Cardiovasc Interv.* 2015;86:678-681.
9. Hemetsberger R, Gürocak O, Soud M, et al. Coronary artery aneurysm with thrombosis after implantation of a bioresorbable coronary scaffold. *JACC Cardiovasc Interv.* 2017;10:e173-e174.
10. Timmers L, Lim YC, Tan HC, Low AF. Coronary aneurysm without malapposition after bioresorbable vascular scaffold implantation. *EuroIntervention.* 2016;12:60.
11. Lee WC, Chung WJ, Fang HY, Wu CJ. Coronary artery aneurysm formation within everolimus-eluting stents and bioresorbable vascular scaffolds. *Int J Cardiol.* 2016;206:58-60.
12. Varghese S, Lauer B, Ohlow MA. Coronary artery aneurysm after everolimus-eluting bioabsorbable vascular scaffold implantation. *JACC Cardiovasc Interv.* 2016;9:e23-e25.
13. Kawsara A, Nunez Gil I, Alqahtani F, Moreland J, Rihal CS, Alkhouli M. Management of coronary artery aneurysms. *JACC Cardiovasc Interv.* 2018;11:1211-1223.
14. La Manna A, Mangiameli A, Capodanno D, Longo G, Sgroi C, Tamburino C. Managing bioabsorbable vascular scaffold failure: combined scaffold restenosis and late acquired coronary aneurysm treated with self-expandable stent. *Can J Cardiol.* 2015;31:691.E1-691.E3.
15. Parikh P, Banerjee K, Sammour Y, et al. Utilization and outcomes of polytetrafluoroethylene covered stents in patients with coronary artery perforation and coronary artery aneurysm: single center 15-year experience. *Catheter Cardiovasc Interv.* 2019;94(4):555-561.

**How to cite this article:** Fabbiochi F, Calligaris G, Bartorelli AL. Progressive growth of coronary aneurysms after bioresorbable vascular scaffold implantation: Successful treatment with OCT-guided exclusion using covered stents. *Catheter Cardiovasc Interv.* 2020;1-4. <https://doi.org/10.1002/ccd.29193>