

## VOLUME, ASYMMETRY AND RECIPROCAL RELATIONSHIPS BETWEEN PARANASAL SINUSES: A 3D SEGMENTATION STUDY ON HEAD CT-SCANS

Giulia Andrea Guidugli<sup>1,2a</sup> , Daniele Maria Gibelli<sup>1b</sup> , Michaela Cellina<sup>3c</sup> , Antonio Giancarlo Oliva<sup>3d</sup>,  
 Luisa Barni<sup>1e</sup> , Patrizia Sartori<sup>1f</sup> , Chiarella Sforza<sup>1g\*</sup> 

<sup>1</sup>Department of Biomedical Sciences for Health, University of Milan, I-20133 Milan, Italy

<sup>2</sup>Department of Orthopedics and Traumatology, Lugano Regional Hospital, CH-6900 Lugano, Switzerland

<sup>3</sup>Department of Radiology, Fatebenefratelli Hospital, ASST Fatebenefratelli Sacco, I- 20157 Milan, Italy

<sup>a,c,d</sup>MD; <sup>b</sup>MD, PhD; <sup>e,f</sup>BSc, PhD; <sup>g</sup>MD, Professor

### ABSTRACT

DOI: [https://doi.org/10.25241/stomaeduj.2020.7\(1\).art.3](https://doi.org/10.25241/stomaeduj.2020.7(1).art.3)

**Introduction:** Very little is known about the morphology of paranasal sinuses, especially with respect to symmetry.

**Methodology:** The head CT-scans of 100 patients (50 male, 50 female) were retrospectively analyzed. The volume segmentation of frontal, sphenoid and maxillary sinuses was performed through semi-automatic segmentation. An asymmetry index was extracted, and differences according to sex and side were assessed through ANOVA test ( $p < 0.05$ ). Pearson test was applied to verify possible correlation between age and volume and asymmetry index in different paranasal sinuses and sexes ( $p < 0.05$ ).

**Results:** On average, male sinuses were larger in volume than female ones ( $p < 0.01$ ). Generally, volumes of the three sinuses were significantly related each other in both sexes (correlation coefficients ranging between 0.34 and 0.58). In both sexes, the maxillary sinus was less asymmetric than the other two types, without significant sex-related differences ( $p > 0.05$ ). Significant inverse correlations between sinus volume and asymmetry index were found for the sphenoid and maxillary sinuses in males, and for the maxillary sinus in females. No correlation of sinus volume or asymmetry index with age was found, with the exception of maxillary volume/age in females.

**Conclusion:** The present results may find practical applications in planning surgical procedures involving paranasal sinuses.

### KEYWORDS

Anatomy; CT-Scan; Segmentation; Paranasal Sinuses; Surgery.


### 1. INTRODUCTION

The paranasal sinuses are air-filled anatomical structures inside the skull and facial bones forming a complex interconnected system communicating with the nasal cavities through an ostium [1,2]. There are four paired paranasal sinuses: the maxillary, frontal and sphenoid sinuses, and the ethmoid cells, with great inter- and intra-individual variations. Shape and size of the paranasal sinuses are probably the most variable of all the anatomical structures of the entire body [3,4]. Genetic diseases, infectious and environmental conditions may influence these variations [5]. A detailed knowledge of anatomy and anatomic variations of paranasal sinuses has become mandatory in the recent years due to advances in imaging technology and in functional endoscopic sinus surgery (FESS) which represents the current standard treatment for chronic paranasal

sinus pathology [6]. To detect sinus pathologies, determine therapy, plan endonasal surgeries and avoid careless manipulation, detailed knowledge of their morphology has a crucial clinical value [7].

Despite the great importance of this topic, the morphological characteristics of paranasal sinuses are incompletely known. Most of the studies performed on adults analyzed the maxillary sinuses, and very few investigations considered the maxillary, frontal and sphenoid sinuses together, and especially their symmetry [8].

The development of the paranasal sinuses starts in the late embryonic period and continues into young adulthood [8]. The maxillary sinus is the first sinus to appear and starts from ectodermal cells between the 7<sup>th</sup> and 10<sup>th</sup> week of development and grows until 17 years of life. It develops from a shallow groove expanding from the primitive infundibulum to the maxilla. After birth, the growth of the maxillary sinus

 **OPEN ACCESS** This is an Open Access article under the CC BY-NC 4.0 license.

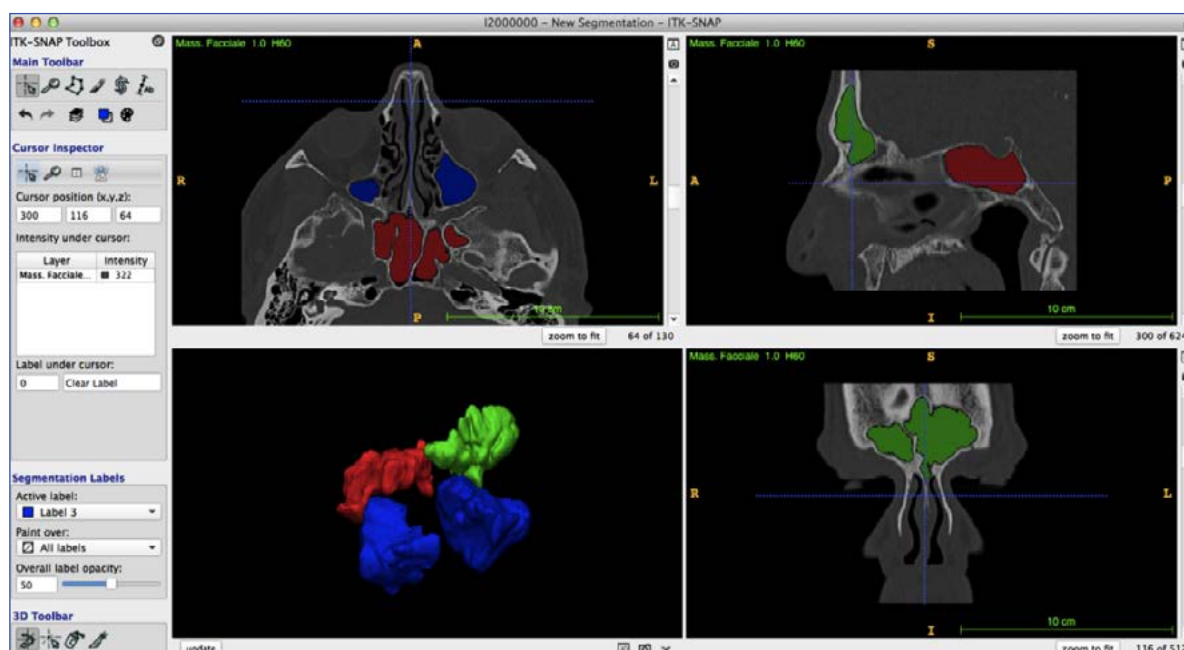
 **Peer-Reviewed Article**

**Citation:** Guidugli GA, Gibelli DM, Cellina M, Oliva AG, Barni L, Sartori P, Sforza C. Volume, asymmetry and reciprocal relationships between paranasal sinuses: a 3D segmentation study on head CT-scans. *Stoma Edu J.* 2020;7(1):20-27.

Received: January 13, 2020  
 Revised: February 07, 2020  
 Accepted: February 10, 2020  
 Published: February 11, 2020

**Corresponding author:**  
 Prof. Chiarella Sforza, MD  
 Department of Biomedical Sciences  
 for Health, University of Milan, Via Luigi  
 Mangiagalli, 31, I-20133 Milano MI, Italy  
 Tel/Fax: +39 02 5031 5384,  
 e-mail: [chiarella.sforza@unimi.it](mailto:chiarella.sforza@unimi.it)

**Copyright:** © 2020 the Editorial Council  
 for the Stomatology Edu Journal.



**Figure 1.** Example of 3D segmentation on CT-scan: in the lower left box, the 3D models of frontal, sphenoid and maxillary sinuses.

is biphasic: the first spurt occurs during the first three years then again between the ages of 7–12. After the age of 12, the growth slowly continues until adulthood. The sphenoid sinus develops as evagination of the spheno-ethmoidal recess about the 3<sup>rd</sup> intrauterine month and reaches full size at the age of 7. In extreme cases of pneumatization the optic nerve and internal carotid artery may lie naked within the sinus cavity [9]. The frontal sinus is the most variable; its development begins during the 16<sup>th</sup> prenatal week as a direct continuation of the embryonic infundibulum and frontal recess superiorly, or by upward migration of anterior ethmoidal air cells to penetrate the inferior aspect of the frontal bone between its outer and inner tables. The right and left sides of the frontal sinuses develop independently as a result of bone resorption and septations [10]. It remains as a cul de sac within the frontal bone till 2 years of age.

The pneumatization process continues till the age of 9, but the volume, height and width of frontal sinuses continue to increase until the age of 20 related to the growth pattern and grade of craniofacial structures [11,12].

During the sinus development, struts, structural components and bony deposition are crucial to protect against external physical forces. Several inter-individual differences in shape and behavior patterns can be noticed. According to Kim et al. [8], three different explanations can be considered. The first one is that the incessant conflict between epithelial expansion (formation of cavities) and bony deposition (protection from the external environment) can undergo different patterns, and produces a great variability. The second and third hypotheses try to explain differences between individuals through heredity: for the second one pneumatization is genetically determined and for

the latter hypothesis the degree of pneumatization also depends on the pathological involvement during childhood [8]. In recent years, the three-dimensional segmentation of medical image data has been largely applied to the morphological evaluation of the upper airways, included the paranasal sinuses. The volume of air cavities is the simplest and most significant parameter for the evaluation of the paranasal sinuses [13]. Several investigations analyzed the volume of paranasal sinuses [8,10,14-17], but little is known about their symmetry, and the calculation of asymmetry indices has been performed only in forensic contexts [17,18]. In the present study, we segmented CT-scan images to create three-dimensional models of the maxillary, frontal and sphenoid sinuses, and calculated their volume. The aim of the study was to investigate inter and intra-individual variations and possible correlations of the sinuses' volume and pneumatization in a large sample of adults. The results will improve knowledge concerning the morphological characteristics of paranasal sinuses.

## 2. METHODS AND MATERIALS

### 2.1. Sample

For this study, 100 head CT-scans were selected from the database of a hospital in Northern Italy and analyzed retrospectively. The CT-scans were anonymized according to local and international ethic rules. The study followed the guidelines of the Helsinki Declaration and was approved by the local ethical committee (7331/2019). The mean age of the male patients was  $49.32 \pm 18.9$  years (range, 21-91 years), while the mean age of the female patients was  $57.1 \pm 22.8$  years (range, 20-91 years). No differences were found in the age distribution between males and females (Student's t test,  $p > 0.05$ ). The most

**Table 1.** Volume of paranasal sinuses in 100 healthy subjects (mean±SD).

	Frontal sinuses			Sphenoid sinuses			Maxillary sinuses		
	Right	Left	Total	Right	Left	Total	Right	Left	Total
<b>Males</b>	4.2 ± 2.2	5.4 ± 3.6	9.6 ± w5.04	5.4 ± 3.6	5.6 ± 3.4	10.9 ± 5.3	16.4 ± 5.1	15.9 ± 5.6	32.3 ± 10.4
<b>Females</b>	2.2 ± 1.4	2.7 ± 1.8	4.9 ± 2.8	4.4 ± 2.6	3.9 ± 2.2	8.3 ± 2.9	13.2 ± 3.8	13.1 ± 3.6	26.3 ± 6.9
<b>M+F</b>	3.2 ± 2.1	4.0 ± 3.1	7.2 ± 4.7	4.9 ± 3.2	4.7 ± 2.9	9.6 ± 4.4	14.8 ± 4.8	14.9 ± 4.9	29.3 ± 9.3

All values are expressed in cm<sup>3</sup>

**Table 2.** Correlation coefficients among sinus volumes.

	Frontal	Sphenoid	Maxillary
Frontal		0.34*	0.36**
Sphenoid	0.58**		0.36**
Maxillary	0.23	0.47**	

Female values are in italics; \*p<0.05; \*\*p<0.01

**Table 3.** Correlation coefficients among age, sinus volumes and a symmetry indices.

	Sex	Volume			Asymmetry		
		Frontal	Sphenoid	Maxillary	Frontal	Sphenoid	Maxillary
Age	Females	-0.02	-0.04	-0.07	-0.14	-0.06	0.29*
Age	Males	-0.13	-0.21	-0.24	0.14	-0.14	0.16

Female values are in italics; \*p<0.05

frequent clinical requests for CT-scan were screening for fractures in case of trauma (57.3%), suspected sinusitis (20.0%), neurological symptoms (12.7%). Subjects with paranasal sinuses aplasia, chronic paranasal sinus pathology, edentulism, maxillofacial fractures or congenital craniofacial abnormalities, or any pathological conditions involving paranasal sinuses were excluded from the study.

### 2.2. CT-scan acquisition

All CT-scans were acquired through the same instrument, a second generation dual-source scanner, Somatom Definition Flash (Siemens, Forchheim, Germany). The acquisition parameters were: kV: 120; mAs: 320; collimation: 40 x 0.6 mm; tube rotation: 1 sec; reconstruction thickness: 3 mm; reconstruction filters: H21s smooth for soft tissues and H60 sharp for bone.

### 2.3. Data collection

Volume segmentation from the DICOM files was performed by a single operator using a semi-automatic segmentation with the freeware ITK-SNAP (Fig. 1) [19]. Volume was automatically calculated through VAM® (Vectra Analysis Module, version 2.8.3, Canfield Scientific Inc., USA) [20].

Intra-operator repeatability of segmentation through ITK-SNAP had already been tested: no significant differences between repeated segmentations and volume measurements were found, with a random error explaining less than 1% of sample variance [21]. The sinus side prevalence was assessed for every pair of sinuses, and an asymmetry index was calculated as follows:

$$|(volume_r - volume_l) / (volume_r + volume_l) \times 100|$$

Where volume<sub>r</sub> is the volume of the right sinus, volume<sub>l</sub> the volume of the left sinus. The index ranges from 0 (perfect symmetry) to 100 (totally asymmetrical).

### 2.4. Statistical analysis

The normal distribution and homoscedasticity for volumes and asymmetry index were assessed respectively through Jarque-Bera test and Bartlett tests. Tests were run through the MATLAB statistic toolbox. Possible statistically significant differences in volume and asymmetry index according to sex and type of sinus were assessed through the two-way ANOVA test. In case of statistically significant differences according to type of sinus, post-hoc tests were performed through the Tukey's Honestly Significant Difference (HSD), separately for males and females. Pearson correlation coefficients were calculated between age, sinus volume and asymmetry index.

A p value of 0.05 or less was considered significant.

## 3. RESULTS

The volume measurements are listed in Table 1. On average, male sinuses were larger in volume than female ones (F=38.87, p<0.0001), with the maxillary sinus being about three (sphenoid sinus) and four (frontal sinus) times larger than the other ones (F=387.75; p<0.0001).

Post-hoc HSD tests found that both the frontal and sphenoid sinuses were significantly smaller than the maxillary one in both males and females (p<0.01); in addition, in females also the difference between frontal and sphenoid sinuses was significant (p<0.01). No significant sex x sinus interaction was found (F=1.96, p=0.1427).

The volumes of the three sinuses were significantly related to each other in both sexes, except for the maxillary and frontal sinuses volumes in males (Table 2). However, in all cases the correlation coefficients were generally low, ranging between 0.34 and 0.58. No correlation of sinus volume with age was found (Table 3). The side prevalence was assessed for every pair of sinuses (Fig. 2). In both males and females the

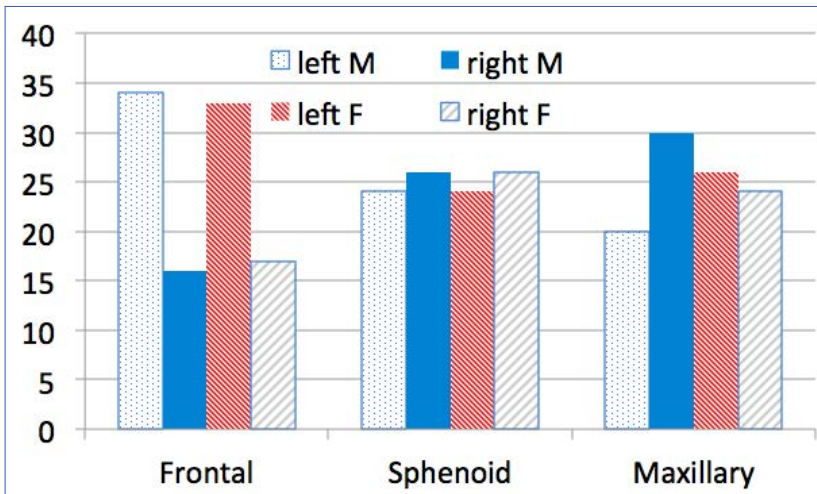


Figure 2. Distribution of side prevalence in the analyzed patients (M, males; F, females).

Table 4. Asymmetry indices in the analyzed paranasal sinuses (mean±SD).

	Frontal	Sphenoid	Maxillary
Males	22.28 ± 18.36	36.96 ± 26.00	7.47 ± 8.40
Females	28.69 ± 18.59	37.89 ± 27.89	8.11 ± 8.51
M+F	25.48 ± 18.66	37.43 ± 26.83	7.79 ± 8.42

All values are %.

left frontal sinus was prevailing in about two-thirds of patients (68% males and 66% females). For the sphenoid sinus, the larger volume was in the right side in 52% of patients (both males and females). The right maxillary sinus was prevalent in 60% of males and in 48% of females. Only 26% of subjects had the same side prevailing for all sinuses (17% left side and 9% right side).

The asymmetry indices calculated for the three pairs of sinuses and according to sex are reported in Table 4. In both sexes, the maxillary sinus was the less asymmetric of the other two, its asymmetry index being approximately one third of the frontal sinus and one fifth of the sphenoid sinus ( $F=58.53$ ,  $p<0.0001$ ).

Post hoc tests found that both the frontal and sphenoid sinuses were significantly more asymmetric than the maxillary one ( $p<0.01$  for both comparisons in both sexes), while the difference between the frontal and sphenoid sinuses was significant only in males ( $p<0.01$ ). No significant sex differences ( $F=1.4$ ,  $p=0.2377$ ) and sex x sinus interactions were found ( $F=0.7$ ,  $p=0.4974$ ). No correlations of sinus asymmetry with age were found, except for the maxillary sinus in females: older women had more asymmetric sinuses (Table 3).

Significant inverse correlations between the sinus volume and asymmetry index were found for the sphenoid ( $r= -0.28$ ,  $p<0.05$ ) and maxillary ( $r= -0.39$ ,  $p<0.01$ ) sinuses in males, and for the maxillary sinus in females ( $r= -0.37$ ,  $p<0.01$ ): in all occasions, larger sinuses were less asymmetric (Fig. 3).

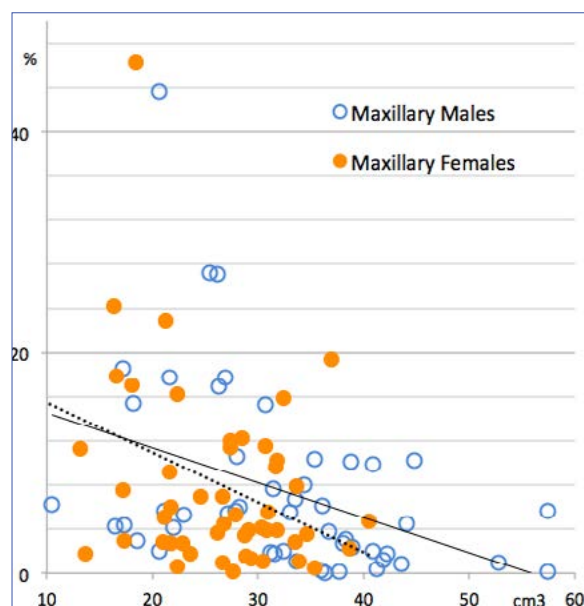


Figure 3. Correlation between maxillary sinus volume (X axis) and asymmetry index (Y axis) in males (open circles, continuous line) and in females (closed circles, interrupted line). Both regressions are significant ( $p=0.01$ ).

#### 4. DISCUSSION

The morphology of paranasal sinuses represents a long-time debated issue. In the last decades, the technological improvements and widening of applications of paranasal sinuses surgery have required further investigations to clarify some aspects still unexplored, such as the asymmetry of these structures. To the best of our knowledge, several studies have assessed the volume of the paranasal sinuses but very few studies have considered the frontal, maxillary and sphenoid sinuses together [17]. In addition, very few studies used an asymmetry index in order to evaluate the side prevalence for every pair of sinuses [8,22,23]. Only Kim et al. [8] and Yoshino et al. [24] provided some calculations of the frontal sinus asymmetry but within forensic contexts. They proposed a “bilateral asymmetry index” (BAI) calculated dividing the smaller sinus by the larger one multiplied by 100 and used it for

**Table 4.** Paranasal sinuses volume in literature (mean±SD). All values are cm<sup>3</sup>.

	Population	Age/side	Frontal sinuses			Sphenoid sinuses			Maxillary sinuses		
			Males	Females	Total	Males	Females	Total	Males	Females	Total
Karakas et al., 2005 (1)	Turkish	21-25 y	8.8±4.5	3.5±3.1		9.7±2.6	8.7±2.4		32.0±9.0	21.8±7.8	
		>25 y	8.4±4.0	3.5±2.4		8.5±4.2	7.88±3.0		31.0±11.4	22.7±9.8	
Emirzeoglu et al., 2007 (14)	Turkish	Total	7.5±4.3	4.1±2.9	5.8±4.1	7.7±4.0	6.1±3.2		19.8±6.3	16.0±5.0	18.0±6.0
Kim et al., 2010 (8)	Korean	Total	7.6	4.4	6.8	14.7	10.6	13.7	43.7	34.6	41.6
Yuksel et al., 2016 (9)	Turkish	Right			3.4±2.7						
		Left			4.1±2.7						
Oliveira et al., 2017 (15)	Brazilian	Right				6.1±3.4	6.09±3.63				
		Left				7.4±3.5	7.07±3.72				
Present Study	Italian	Total	9.6±5.0	4.9±2.8	7.2±4.7	10.9±5.3	8.3±2.9	9.6±4.5	32.3±10.4	26.3±6.9	29.3±9.3

classification purposes. This index maximizes the asymmetry values, and it was considered useful for individual identification, but it has not been applied to surgery. As far as sinus volumes are concerned, the comparison with existing literature highlights differences in values according to authors: these discordances may be explained by ethnic variations and by discrepancies in defining cranial structure.

As far as the Italian population is concerned, values for sphenoid volume are well in line with those already published in a previous publication [25]. Interestingly, different authors reporting data from the same population show discordances in volume measurements [10,14,15]; this detail may confirm the importance of ethnic variability which may be extended also to geographical location of different population groups. Another possible variant which may explain discordances in literature is the variety of techniques for volume extraction: however, Karakas and Kavakli found results similar to those of the present study for all three pairs of sinuses, although they used the Cavalieri principle to extract volume, and not a segmentation software (Table 5). On the other side, the Cavalieri principle was also used by Emirzeoglu et al. [15] to estimate the sinus volume, obtaining slightly different results from those currently calculated with semi-automatic segmentation for frontal and sphenoidal sinuses, and smaller values for the maxillary sinus. The use of the Cavalieri principle for the paranasal sinuses has been criticized because of the complex morphology of these organs. The method estimates the organ volume starting from a sample of cross sections, but they may not be sufficiently representative for the organ shape, thus producing unreliable results. Nonetheless, even if Kim et al. [18] used a segmentation software similar to that applied in the current study, their results are pretty different, with somewhat smaller values for the frontal sinus, and larger for the sphenoidal and maxillary ones. Moreover, also the segmentation protocol used by Oliveira et al. [16] in their analysis of the sphenoid sinus morphology was similar to the present one, but they obtained 1.2-1.6 larger volumes in both sexes. Therefore, possible differences due to the segmentation method cannot be excluded, although its influence cannot be clearly separated from the ethnic variability. Anyway, but for the differences in volumetric measurements, all studies are concordant on the sexual dimorphism of paranasal sinuses, with male structures always larger than the female ones [10,14,15]. An interesting result from the present study concerns the correlation between the volumes of different paranasal sinuses: Emirzeoglu et al. [15] found a high correlation between the volumes of the maxillary-frontal and maxillary-ethmoidal sinuses for female subjects, while in the male group the volumes of all sinuses correlated well with each other except for the frontal-sphenoid sinuses. These data confirm that paranasal sinuses are somehow linked one type to another: generally, the similarities in size of different types of paranasal sinuses may be explained by genetic variables involved in their development [8]. However, although statistically significant, the correlation coefficient is low (under 0.70) in all cases; this additional information seems to demonstrate that other factors (probably acquired and/or environmental) may be involved

in sinuses development. Finally, the present study provided novel data concerning the morphological characteristics of paranasal sinuses: first, both their volume and asymmetry seem not to be related to age, with the exception of maxillary sinus volume in females. Cohen et al. explored the same topic and found that both maxillary and sphenoid sinuses volumes are related with age (they decrease with age) in both sexes [17]. These discordances may be explained in different ways: with respect to the maxillary sinuses, possible alterations of the upper dental profile may represent a bias in assessing volumetric differences. On the other side, differences in sphenoid volume need to be explained, although the ethnic variable may have a role. Another innovative information concerns the significant correlation between the asymmetry index and volume (the smallest the sinuses, the most asymmetric). This has not been reported in literature yet, and proves that asymmetry and volume are somehow linked. However, again the coefficients are too small to exclude other possible variables in determining paranasal sinuses morphology. In the present study the volume segmentation of frontal, sphenoid and maxillary sinuses was performed using semi-automatic segmentation with the freeware ITK-SNAP. Although literature reports several investigations measuring the volume of paranasal sinuses, the systematic study of their asymmetry has been neglected so far. The asymmetry index applied in the current study is of easy calculation, and can complement the analysis of sinus volumes.

## 5. CONCLUSIONS

The current results show that paranasal sinuses in the single individual share some similarities in size possibly explained by underlying genetic

characteristics modulated by local modification due to environmental and acquired factors. Aging does not seem to be a key factor in explaining sinus dimensions and asymmetry, at least in healthy adults, but the two aspects are significantly related, with a larger asymmetry in small sinuses.

The present data may provide a contribution for improving our knowledge concerning the development of paranasal sinuses and possible factors involved in this process. Also, surgical treatments involving paranasal sinuses should consider these characteristics to better plan complex interventions.

## CONFLICT OF INTEREST

The authors declare no conflict of interest.

## AUTHORS CONTRIBUTIONS

GG: conception and design of the study, data acquisition, data analysis, drafting the article, final approval. DG: conception and design of the study, data analysis, data interpretation, drafting the article, revising the article, final approval. MC: data acquisition, data analysis, drafting the article, final approval. AO: data interpretation, revising the article, final approval. LB: data acquisition, revising the article, final approval. PS: data interpretation, revising the article, final approval. CS: conception and design of the study, data interpretation, revising the article, final approval.

**Drs. Guidugli and Gibelli equally contributed to this work.**

## REFERENCES

- Karataş D, Koç A, Yüksel F, et al. The effect of nasal septal deviation on frontal and maxillary sinus volumes and development of sinusitis. *J Craniofac Surg*. 2015;26(5):1508-1512. [\[Full text links\]](#) [\[CrossRef\]](#) [\[PubMed\]](#) [Google Scholar](#) [Scopus](#)
- Natsis K, Karabatakis V, Tsikarakis P, et al. Frontal sinus anatomical variations with potential consequences for the orbit. Study on cadavers. *Morphologie*. 2004;88(280):35-38. [\[Full text links\]](#) [\[CrossRef\]](#) [\[PubMed\]](#) [Google Scholar](#) [Scopus](#)
- Jang YJ, Park HM, Kim HG. The radiographic incidence of bony defects in the lateral lamella of the cribriform plate. *Clin Otolaryngol Allied Sci*. 1999;24(5):440-442. [\[Full text links\]](#) [\[CrossRef\]](#) [\[PubMed\]](#) [Google Scholar](#) [Scopus](#)
- Lorkiewicz-Muszyńska D, Kociemba W, Rewekant A, et al. Development of the maxillary sinus from birth to age 18. Postnatal growth pattern. *Int J Pediatr Otorhinolaryngol*. 2015;79(9):1393-1400. [\[Full text links\]](#) [\[CrossRef\]](#) [\[PubMed\]](#) [Google Scholar](#) [Scopus](#)
- Değermenci M, Ertekin T, Ülger H, et al. The age-related development of maxillary sinus in children. *J Craniofac Surg*. 2016;27(1):e38-e44. [\[Full text links\]](#) [\[CrossRef\]](#) [\[PubMed\]](#) [Google Scholar](#) [Scopus](#)
- Vaid S, Vaid N. Normal anatomy and anatomic variants of the paranasal sinuses on computed tomography. *Neuroimaging Clin N Am*. 2015;25(4):527-548. [\[Full text links\]](#) [\[CrossRef\]](#) [\[PubMed\]](#) [Google Scholar](#) [Scopus](#)
- Tingelhoff K, Moral AI, Kunkel ME, et al. Comparison between manual and semi-automatic segmentation of nasal cavity and paranasal sinuses from CT images. *Conf Proc IEEE Eng Med Biol Soc*. 2007;2007:5505-5508. [\[Full text links\]](#) [\[CrossRef\]](#) [\[PubMed\]](#) [Google Scholar](#) [Scopus](#)
- Kim J, Song SW, Cho JH, et al. Comparative study of the pneumatization of the mastoid air cells and paranasal sinuses using three-dimensional reconstruction of computed tomography scans. *Surg Radiol Anat*. 2010;32(6):593-599. [\[Full text links\]](#) [\[CrossRef\]](#) [\[PubMed\]](#) [Google Scholar](#) [Scopus](#)
- Gibelli D, Cellina M, Gibelli S, et al. Relationship between sphenoid sinus volume and protrusion of internal carotid artery and optic nerve: a 3D segmentation study on maxillofacial CT-scans. *Surg Radiol Anat*. 2019;41(5):507-512. [\[Full text links\]](#) [\[CrossRef\]](#) [\[PubMed\]](#) [Google Scholar](#) [Scopus](#)
- Yüksel Aslier NG, Karabay N, Zeybek G, et al. The classification of frontal sinus pneumatization patterns by CT-based volumetry. *Surg Radiol Anat*. 2016;38(8):923-930. [\[Full text links\]](#) [\[CrossRef\]](#) [\[PubMed\]](#) [Google Scholar](#) [Scopus](#)
- Buyuk SK, Simsek H, Karaman A. The relationship between frontal sinus morphology and skeletal maturation. *Folia Morphol (Warsz)*. 2018;77(3):503-508. [\[CrossRef\]](#) [\[PubMed\]](#) [Google Scholar](#) [Scopus](#)

12. Rossouw PE, Lombard CJ, Harris AM. The frontal sinus and mandibular growth prediction. *Am J Orthod Dentofac Orthop.* 1991;100(6):542-546.  
[\[Full text links\]](#) [\[CrossRef\]](#) [\[PubMed\]](#) [Google Scholar](#) [Scopus](#)
13. Park IH, Song JS, Choi H, et al. Volumetric study in the development of paranasal sinuses by CT imaging in Asian: a pilot study. *Int J Pediatr Otorhinolaryngol.* 2010;74(12):1347-1350.  
[\[Full text links\]](#) [\[CrossRef\]](#) [\[PubMed\]](#) [Google Scholar](#) [Scopus](#)
14. Karakas A, Kavakli S. Morphometric examination of the paranasal sinuses and mastoid air cells using computed tomography. *Ann Saudi Med.* 2005;25(1):41-45.  
[\[Full text links\]](#) [\[CrossRef\]](#) [\[PubMed\]](#) [Google Scholar](#) [Scopus](#)
15. Emirzeoglu M, Sahin B, Bilgic S, et al. Volumetric evaluation of the paranasal sinuses in normal subjects using computer tomography images: a stereological study. *Auris Nasus Larynx.* 2007;34(2):191-195.  
[\[Full text links\]](#) [\[CrossRef\]](#) [\[PubMed\]](#) [Google Scholar](#) [Scopus](#)
16. Oliveira JMM, Alonso MBCC, de Sousa E Tucunduva MJAP, et al. Volumetric study of sphenoid sinuses: anatomical analysis in helical computed tomography. *Surg Radiol Anat.* 2017;39(4):367-374.  
[\[Full text links\]](#) [\[CrossRef\]](#) [\[PubMed\]](#) [Google Scholar](#) [Scopus](#)
17. Cohen O, Warman M, Fried M, et al. Volumetric analysis of the maxillary, sphenoid and frontal sinuses: a comparative computerized tomography based study. *Auris Nasus Larynx.* 2018;45(1):96-102.  
[\[Full text links\]](#) [\[CrossRef\]](#) [\[PubMed\]](#) [Google Scholar](#) [Scopus](#)
18. Kim DI, Lee UY, Park SO, et al. Identification using frontal sinus by three-dimensional reconstruction from computed tomography. *J Forensic Sci.* 2013;58(1):5-12.  
[\[Full text links\]](#) [\[CrossRef\]](#) [\[PubMed\]](#) [Google Scholar](#) [Scopus](#)
19. Yushkevich PA, Yang G, Gerig G. ITK-SNAP: an interactive tool for semi-automatic segmentation of multi-modality biomedical images. *Conf Proc IEEE Eng Med Biol Soc.* 2016;2016:3342-3345.  
[\[Full text links\]](#) [\[CrossRef\]](#) [\[PubMed\]](#) [Google Scholar](#) [Scopus](#)
20. Yushkevich PA, Gerig G. ITK-SNAP: an interactive medical image segmentation tool to meet the need for expert-guided segmentation of complex medical images. *IEEE Pulse.* 2017;8(4):54-57.  
[\[CrossRef\]](#) [Google Scholar](#)
21. Codari M, Zago M, Guidugli GA, et al. The nasal septum deviation index (NSDI) based on CBCT data. *Dentomaxillofac Radiol.* 2016;45(2):20150327.  
[\[Full text links\]](#) [\[CrossRef\]](#) [\[PubMed\]](#) [Google Scholar](#)
22. Al-Abri R, Bhargava D, Al-Bassam W, et al. Clinically significant anatomical variants of the paranasal sinuses. *Oman Med J.* 2014;29(2):110-113.  
[\[Full text links\]](#) [\[CrossRef\]](#) [\[PubMed\]](#) [Google Scholar](#) [Scopus](#)
23. Kanat A, Yazar U, Ozdemir B, et al. Frontal sinus asymmetry: is it an effect of cranial asymmetry? X-ray analysis of 469 normal adult human frontal sinus. *J Neurosci Rural Pract.* 2015;6(4):511-514.  
[\[Full text links\]](#) [\[CrossRef\]](#) [\[PubMed\]](#) [Google Scholar](#)
24. Yoshino M, Miyasaka S, Sato H, Seta S. Classification system of frontal sinus patterns by radiography. Its application to identification of unknown skeletal remains. *Forensic Sci Int.* 1987;34(4):289-299.  
[\[Full text links\]](#) [\[CrossRef\]](#) [\[PubMed\]](#) [Google Scholar](#) [Scopus](#)
25. Gibelli D, Cellina M, Gibelli S, et al. Volumetric assessment of sphenoid sinuses through segmentation on CT scan. *Surg Radiol Anat.* 2018;40(2):193-198.  
[\[Full text links\]](#) [\[PubMed\]](#) [Google Scholar](#) [Scopus](#)

### Giulia Andrea GUIDUGLI

MD  
 Department of Orthopedics and Traumatology  
 Lugano Regional Hospital  
 CH-6900 Lugano, Switzerland



### CV

Dr. Giulia Andrea Guidugli is a medical doctor currently attending a Residency program in Orthopedics and Traumatology (Lugano Regional Hospital, Switzerland). Her fields of research are the morphological and metrical assessment of anatomical characteristics of bones, paranasal sinus and upper airways, including the analysis of facial anatomy in both healthy and pathological conditions through the study of CT and 3D reconstruction of the upper airways.

### Daniele Maria GIBELLI

MD, PhD  
 LAFAS-Laboratory of Functional Anatomy of the Stomatognathic System  
 Department of Biomedical Sciences for Health  
 University of Milan  
 I-20133 Milan, Italy



### CV

Dr. Daniele Maria Gibelli is a senior researcher in Human Anatomy in Department of Biomedical Sciences for Health, University of Milan, Italy. His fields of research are the morphological and metrical assessment of anatomical characteristics of bones and teeth, including anatomical dimorphism, their modification with age, ethnic variability and the analysis of individualizing characteristics. He also deals with the analysis of facial anatomy both in healthy and pathological conditions, for studies concerning the assessment of facial symmetry, modifications with mimicry and anatomical uniqueness of facial structures.

## Questions

### 1. When does the development of paranasal sinuses start?

- a. Childhood;
- b. Fetal period;
- c. Puberty;
- d. Adult age

### 2. On average, the volume of paranasal sinuses:

- a. Is higher in females than in males;
- b. Is equal in males and females;
- c. Is higher in males than in females;
- d. Cannot be analysed through 3D segmentation

### 3. Which paranasal sinus is the least asymmetric?

- a. Frontal sinus;
- b. Sphenoid sinus;
- c. Maxillary sinus;
- d. Ethmoid cells.

### 4. For which paranasal sinus a positive correlation was found between volume and age?

- a. Frontal sinus;
- b. Sphenoid sinus;
- c. Maxillary sinus;
- d. None.

**JULY 3-5, 2020**  
**AESTHETIC CONGRESS**  
**LONDON**

[www.ohi-s.com/eng/london/](http://www.ohi-s.com/eng/london/)