

Intrascrotal lipoblastoma in a ten year old: case report and review of literature

Ghassan Nakib,¹ Valeria Calcaterra,² Luigi Avolio,¹ Marinella Guazzotti,¹ Ilaria Goruppi,¹ Alessandra Viglio,³ Gloria Pelizzo¹

¹Department of Pediatric Surgery, IRCCS Policlinico San Matteo Foundation and University of Pavia; ²Department of Pediatrics, IRCCS Policlinico San Matteo Foundation and Department of Internal Medicine University of Pavia; ³Anatomic Pathology Section, Department of Human Pathology, University of Pavia, Foundation IRCCS Policlinico San Matteo, Pavia, Italy

Abstract

Lipoblastoma is a rare benign soft tissue tumor encountered almost exclusively in infancy and early childhood. The location of tumors varies, but most occur in the extremities, trunk, head and neck. Less frequently, lipoblastomas have been reported in the mediastinum, the retroperitoneum and the inguinal region. Only 7 cases of lipoblastoma in the scrotum have been reported so far in the English literature, with none of the patients older than 8. We report an intrascrotal lipoblastoma in a 10 year-old boy. The differential diagnosis is discussed with reference to the literature.

Introduction

Approximately 6% of all soft tissue neoplasms in the pediatric population are adipose tumors.¹ Of these, about two thirds are simple lipomas or variants, and up to 30% are lipoblastomas.²

Lipoblastoma is an uncommon benign soft tissue tumor encountered almost exclusively in infancy and early childhood.^{3,4} Tumors are asymptomatic, painless and are normally discovered as a mass on palpation. Although lipoblastomas can affect any part of the body, we are only aware of 7 reports of intrascrotal tumors,^{1,2,5-9} all reported in patients under 8 years of age. We report the case of an intrascrotal lipoblastoma in a 10 year-old boy and discuss the differential diagnosis with reference to the literature.

Case Report

A 10 year-old boy presented at the Emergency Paediatric Surgery Department in our Institution (IRCCS Policlinico S. Matteo Foundation, Pavia, Italy) for a sudden swelling in the right inguinal region with the apparent characteristics of an inguinal hernia. His parents reported that the mass had appeared one day before. A solid, painless, rubbery, mobile mass was palpated at the upper pole of the right testicle, which felt normal otherwise. The left testicle was in the left hemiscrotum. No evidence of hernia was noticed bilaterally.

Scrotal ultrasound showed a hyperechoic lesion measuring (2.50×1.58×0.88 cm) above the upper pole of the right testicle. Elastasonography detected a mainly elastic pattern. The left testicle was normal. All blood tests including tumor markers (HGC, fetoprotein) were normal. The lesion was approached via a right inguinal incision.

The mass was readily delivered with the right testicle from the wound incision. The fatty tumor was easily and totally dissected from the testicle and from the scrotal wall, and the testicle was fixed back in the scrotum. The macroscopic appearance was of a yellowish 5×5×1.5 cm mass, of rubbery consistency and homogeneous aspect (Figure 1A). At histology the mass was almost totally circumscribed with fibrous connective tissue of variable thickness, and composed of mature fatty tissue mixed with fibrotic septae of varying degrees of differentiation. Few focused and limited areas of myxoid aspect were observed interspersed with various lipoblastic elements. No evidence of necrosis, or mitosis was present. Unfortunately no tissue was obtained for cytogenetics tests (Figure 1B-D).

The child was discharged 24 hours later. Sonographic follow up 1 year postoperatively showed a lesion free left testicle.

Discussion

Lipoblastoma is a very rare, benign fetal embryonal white fatty tumor. In 1926 Jaffe attributed the term *lipoblastoma* to describe an atypical lipomatous lesion that consisted of cells resembling embryonic white fat.^{10,11} This term was intended to differentiate these lesions from common lipomas, which contain no lipoblasts.¹² The ability of a lipoblastoma to differentiate into a common lipoma was first describe by Van Meurs in 1947,¹³ supporting the concept that lipoblastomas are the result of continued proliferation of immature fat cells and lobules in the postnatal period. Lipoblastoma occurs most commonly in infants and children, with 80-90% of cases in the pub-

Correspondence: Gloria Pelizzo, Department of Pediatric Surgery, IRCCS Policlinico S. Matteo Foundation, P.le Golgi n.2, 27100 Pavia, Italy. Tel. +39.0382.502910 E-mail: g.pelizzo@smatteo.pv.it

Key words: lipoblastoma, intrascrotal, children, adipose tumors.

Contributions: GN, surgical support, draft preparation; LA, IG, surgical support; MG, diagnostic support; VC, draft preparation, revision of the literature; AV, microscopic evaluation; GP, surgical support, writing of the final manuscript.

Conflict of interests: the authors declare no potential conflicts of interests.

Received for publication: 18 October 2012. Revision received: 28 December 2012. Accepted for publication: 28 December 2012.

This work is licensed under a Creative Commons Attribution NonCommercial 3.0 License (CC BY-NC 3.0).

©Copyright G. Nakib et al., 2013 Licensee PAGEPress, Italy Rare Tumors 2013; 5:e11 doi:10.4081/rt.2013.e11

lished data occurring before the age of 3 years and 40% before the age of 1 year. Only rarely has the tumor been reported in older children or young adults.¹⁴ Male predominance, equal distribution, and female predominance, have all been described for this tumor.^{4,15,16}

The location of lipoblastoma varies; tumors occur most often in the extremities, trunk, head and neck. Smaller numbers have been reported in the mediastinum, retroperitoneum and inguinal region. To our knowledge, only 7 cases of lipoblastoma have been reported in the scrotum (Table 1 summarizes the clinical data);^{1,2,5-9} the ages of the subjects in these cases ranged from 7 months to 48 months. Our case is the first report of a patient older than 8 years with intrascrotal lipoblastoma.

Clinically, it is difficult to differentiate benign lipoblastomas from other scrotal masses such as malignant tumors. These lesions are asymptomatic and painless, and diagnosis is normally made upon the discovery of a mass on palpation.

Although preoperative radiological imaging is useful to assess the extent of the disease and as an aid for planning surgical excision, its use is limited in differentiating lipomatous tumors and there are no pathognomonic findings associated with lipoblastomas.¹⁷ Because of the limitations of radiological imaging, an accurate preoperative diagnosis of lipoblastoma is rarely made and total surgical excision should be performed.

Differential diagnosis may also be difficult

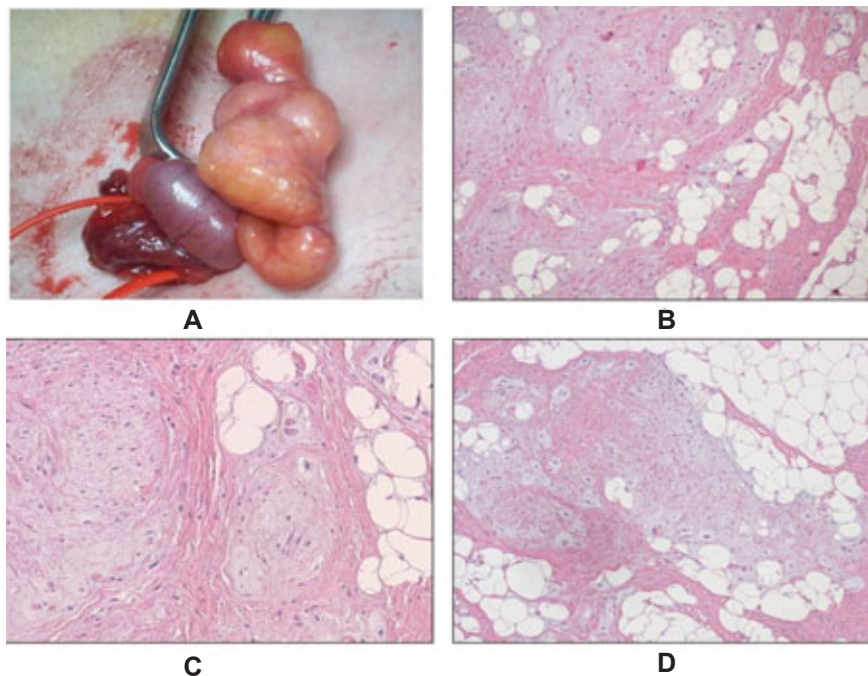


Figure 1. Macroscopic (A) and microscopic (B-D) appearance of the tumor.

Table 1. Summary of the clinical data of the 7 previously reported cases of pediatric intrascrotal lipoblastomas, including our case.

Author	Year	Age	Site	Size (cm)	Tests
Arda <i>et al.</i> ⁵	1993	15 months	Left	6.5×4×3	Spared
Turner <i>et al.</i> ⁶	1998	9 months	Left	5×2.5×1.5	Spared
Chun <i>et al.</i> ²	2001	18 months	Not described	2.3×2×1.3	Not described
Somers <i>et al.</i> ⁷	2004	7 months	Left	14×14×8	Not described
Del Sordo <i>et al.</i> ⁹	2007	48 months	Right	2×1.2×0.8	Spared
Dy <i>et al.</i> ⁸	2007	48 months	Not described	3.5×2	Spared
Kamal <i>et al.</i> ¹	2011	4 months	Right	10×9×7	Spared
Present case	2012	10 years	Right	5×5×15	Spared

Table 2. Clinical features, histologic criteria and cytogenetics tests for differential diagnosis of the adipose tumors.

	Lipoblastoma	Lipoblastomatosis	Liposarcoma (myxoid)	Hibernomas (brown lipoma)	Lipoma
Mitosis	No	No	Yes	No	No
Encapsulated	Yes	Yes	No	No	Yes
Nuclear atypia and abnormal mitoses	No	No	Yes	No	No
Recurrence rate	Low (localized)	Moderate (infiltration of adjacent structures) (diffuse)	High	Low	Low
Age	80-90% <3 year. First decade of life	Infancy and early childhood	Adult	Young adults	All
Location	Extremities, trunk, abdomen, head and neck, intrascrotal	head and neck, mediastinum, retroperitoneum, trunk, lung, mesentery, peritoneal cavity and intramuscular and inguinal canals	Thigh, upper extremities, abdomen, chest wall, mediastinum, and retroperitoneum	Back, chest, axilla, groin, or thighs, intra abdominal, retroperitoneal	Subcutaneous tissue or deep soft tissue any site
Chromosomal alteration	Rearrangement of 8q11-13	Rearrangement of 8q11-13	12q14.t(12;16) (q13; p11)	Rearrangement of 11q13	12q13-q15 13q12-q22 (ref.22)

for the pathologist due to the close resemblance between lipoblastomas and myxoid or well-differentiated liposarcomas and hibernomas. Liposarcoma and hibernoma have nearly the same histological findings. Both have monovacuolated lipoblasts with hyperchromatic, pleomorphic nuclei and anaplasia. However, hibernoma has a gray-brown color and a lobulated structure. The fat cells are mostly multivacuolated, vacuoles are greater in number than in lipoblastomatosis and cytoplasm is granular. Lipoblastomas are also lobulated; the cells show a wide spectrum of adipocytic differentiation, ranging from monovacuolated and multivacuolated lipoblasts to mature adipocyte. However, there are no atypical nuclei or abnormal mitoses. The stroma may be predominantly myxoid, contains variable numbers of stellate mesenchymal cells and has a plexiform vascular pattern.^{1,7,9,18,19}

Conclusions

Recent studies have described specific chromosomal abnormalities that characterize benign *vs* malignant adipose tissue. Distinctive clonal karyotypic rearrangements of chromosomal region 8q11-13 are found to be diagnostic of lipoblastomas, whereas a distinctive translocation t(12;16) is observed in myxoid liposarcomas.²⁰ Structural rearrangements involving 11q13 have been reported for hibernoma.^{21,22} To summarize, differential diagnosis depends on a combination of clinical features, histologic criteria and cytogenetics tests (Table 2).

Lipoblastomas are predominantly well-circumscribed and while no malignant degeneration has been documented, a rapid growth rate

has been reported.

There is general agreement on the treatment of lipoblastoma. Surgical exploration is mandatory and the modality adopted is as for malignant tumors. Complete surgical resection of lipoblastomas yields an excellent prognosis. Recurrence has been reported in 14% to 25% of cases, usually due to incomplete resection. Postoperative follow-up is important to detect relapses but there is no agreement on the appropriate length of follow-up for lipoblastomas. Kok *et al.*¹⁷ recommend a minimum follow-up period of 5 years.

References

- Kamal NM, Jouini R, Yahya S, Haiba M. Benign intrascrotal lipoblastoma in a 4-month-old infant: a case report and review of literature. *J Pediatr Surg* 2011;46:E9-12.
- Chun YS, Kim WK, Park KW, et al. Lipoblastoma. *J Pediatr Surg* 2001;36:905-7.
- Coffin CM. Adipose and myxoid tumours. In: Coffin CM, Dehner LP, O'Shea PA, eds. *Pediatric soft tissue tumours: a clinical, pathological, and therapeutic approach*. New Salt Lake City, Utah: JA Majors Company; 1997. pp 254-276.
- Stringel G, Shandling B, Mancor K, Ein SH. Lipoblastoma in infants and children. *J Pediatr Surg* 1982;17:277-80.
- Arda IS, Senocak ME, Gögüs S, Büyükpamukçu N. A case of benign intrascrotal lipoblastoma clinically mimicking testicular torsion and review of the literature. *J Pediatr Surg* 1993;28:259-61.
- Turner DT, Shah SM, Jones R. Intrascrotal lipoblastoma. *Br J Urol* 1998;8:166-7.
- Somers GR, Teshima I, Nasr A, et al. Intrascrotal lipoblastoma with a complex karyotype: a case report and review of the literature. *Arch Pathol Lab Med* 2004;128:797-800.
- Dy JS, Fuchs A, Palmer LS. Benign intrascrotal lipoblastoma in a child. *Urology* 2007;70:372.e1-2.
- Del Sordo R, Cavaliere A, Sidoni A, et al. Intrascrotal lipoblastoma: a case report and review of the literature. *J Pediatr Surg* 2007;42:E9-11.
- Jaffe RH. Recurrent lipomatous tumours of the groin: Liposarcoma and lipoma pseudomyxomatodes. *Arch Pathol* 1926;1:381-7.
- Collins MH, Chatten J. Lipoblastoma/lipoblastomatosis: a clinicopathologic study of 25 tumours. *Am J Surg Pathol* 1997;21:1131-7.
- Coffin CM, Williams RA. Congenital lipoblastoma of the hand. *Pediatr Pathol* 1992;12:857-64.
- Van Meurs DP. The transformation of an embryonic lipoma to a common lipoma. *Br J Surg* 1947;34:282-4.
- Grandi E, Trisolini MP. [Tumours of the adipose tissue during 10 years of diagnostic activities (1979-1988)]. *Pathologica* 1990;82:217-56. [Article in Italian].
- Mahour GH, Bryan BJ, Isaacs H Jr. Lipoblastoma and lipoblastomatosis—a report of six cases. *Surgery* 1988;104:577-9.
- Dilley AV, Patel DL, Hicks MJ, Brandt ML. Lipoblastoma: pathophysiology and surgical management. *J Pediatr Surg* 2001;36:229-31.
- Kok KY, Telisinghe PU. Lipoblastoma: clinical features, treatment, and outcome. *World J Surg* 2010;34:1517-22.
- Mentzel T, Calonje E, Fletcher CD. Lipoblastoma and lipoblastomatosis: a clinicopathological study of 14 cases. *Histopathology*. 1993;23:527-33.
- Hicks J, Dilley A, Patel D, et al. Lipoblastoma and lipoblastomatosis in infancy and childhood: histopathologic, ultrastructural, and cytogenetic features. *Ultrastruct Pathol* 2001;25:321-33.
- Miller GG, Yanchar NL, Magee JF, Blair GK. Tumour karyotype differentiates lipoblastoma from liposarcoma. *J Pediatr Surg* 1997;32:1771-2.
- Maire G, Forus A, Foa C, et al. 11q13 alterations in two cases of hibernoma: large heterozygous deletions and rearrangement breakpoints near GARP in 11q13.5. *Genes Chromosomes Cancer* 2003;37:389-95.
- Jin J, Niu J, Kim YM, et al. A novel t(8;13)(q21;q22) translocation in a pediatric lipoma. *Cancer Genet* 2011;204:629-33.