

# *Metastatic Squamous Cell Carcinoma of an Unknown Primary Localized to the Neck*

## *Advantages of an Aggressive Treatment*

F. DE BRAUD, MD, L. K. HEILBRUN, PHD, K. AHMED, MD, W. SAKR, MD, J. F. ENSLEY, MD,  
J. A. KISH, MD, E. TAPAZOGLU, MD, AND M. AL-SARRAF, MD

Treatment of patients with squamous cell carcinoma (SCC) of an unknown primary localized to the neck is still controversial, particularly regarding advanced disease. We reviewed 41 such patients treated with surgery and/or radiotherapy (RT) (n = 25) or with combined modality treatment including chemotherapy (CH) (n = 16). The male to female ratio was 28 to 13, and the median age was 58 years (range, 32 to 94 years). There were 27 (66%) patients with poorly differentiated SCC and 8 with moderately differentiated or well-differentiated cancer. Twenty-three (56%) patients had N3 disease, 16 (39%) had N2, and 2 had N1. The majority of N3 patients have been treated with CH and RT (n = 12) or with RT alone (n = 9). The combined CH-RT was well tolerated, with no life-threatening toxicity. The complete response (CR) to CH-RT was 81% (11 patients have no evidence of disease [NED] currently). The median survival time of this group was 37+ months. Of the 25 patients who had surgery and/or RT as their first planned treatment, 7 (28%) have NED currently. The median survival time of this group was 24 months. Patients with N3 disease who received CH had a higher CR rate and a longer survival time as compared with those treated with surgery and/or RT, despite a higher (N3) stage of disease. These findings warrant further investigation in randomized cooperative studies.

*Cancer* 64:510-515, 1989.

**A**PPROXIMATELY 5% of patients with metastasis to the lymph nodes of the neck have no evidence of a primary, despite a thorough workup. Squamous cell carcinoma (SCC) and undifferentiated carcinoma are the most frequent histopathologic diagnoses. These tumors are frequently found to involve upper and middle nodes (>60% of cases). However, multiple or lower localizations are present in 15% to 30% of patients.<sup>1</sup> In the supraclavicular area, the incidence of adenocarcinoma rises to 30% and the probability of a pulmonary, breast, or gastrointestinal origin is much higher. In the presence of a histologically confirmed diagnosis of carcinoma metastatic to the neck from an unknown primary, a thorough investigation for the possible primary site should be conducted. This investigation should include physical ex-

amination, complete examination of the upper aerodigestive tract (by palpation, indirect laryngo-pharyngoscopy, and naso-pharyngoscopy) with biopsies of any suspicious lesions, barium swallow, computed tomography (CT) scan or radiograph of paranasal sinuses, chest radiograph, and bone scan. Furthermore, when these examinations are unremarkable, triple endoscopy under general anesthesia should be performed. The hypopharynx, nasopharynx, and base of the tongue should undergo biopsy because they are the most probable sites of origin of the primary.<sup>1-3</sup>

Careful staging of the disease is very important because the therapeutic approach varies depending on the dimension and distribution of the tumor. Although the prognosis for patients with N1 is relatively good and more than 70% of these patients are free of disease more than 3 years after either radiotherapy (RT)<sup>1,4</sup> or radical neck dissection (RND),<sup>5</sup> very poor therapeutic results in terms of cure rate and survival have been obtained for N3 or massive disease. The combination of RT and surgery fails to induce a cure in 70% of the latter group of patients (Table 1).<sup>12-16</sup>

In this report, we have retrospectively analyzed the re-

From the Division of Hematology and Oncology, Wayne State University School of Medicine, and Department of Radiation Oncology and Pathology, Harper Hospital, Detroit, Michigan.

\* Supported by Italian Association for Cancer Research (A.I.R.C.)

Address for reprints: M. Al-Sarraf, MD, Division of Hematology and Oncology, Wayne State University School of Medicine, Harper-Grace Hospitals, P.O. Box 02188, Detroit, MI 48201.

Accepted for publication January 19, 1989.

sults obtained from this institution in the last 10 years when treating patients with carcinoma of an unknown primary localized to the neck with either traditional approaches without chemotherapy (CH) or more aggressive combinations with regimens including cisplatin (CDDP).

### Materials and Methods

From April 1976 to May 1987, 1577 patients were referred for head and neck (H & N) tumors to the Wayne State University School of Medicine in Detroit. Forty-seven (3%) had neck metastasis from carcinoma of an unknown primary, excluding adenocarcinomas. Their records were reviewed and 41 were considered evaluable for this study. Five patients were excluded because the workup showed systemic dissemination of the tumor and one patient was excluded due to multiple complications before he could start the therapy.

The following variables were studied: clinical characteristics of the patients, stage and histologic diagnosis of the disease, diagnostic workup, treatment, response to treatment, and survival. All 25 biopsies done by our group were carefully reexamined. The patients were divided into the following two major groups according to the treatment: (1) 25 who received one of three "standard therapies" (RT alone [n = 16], surgery alone [n = 2], or surgery followed by RT [n = 7]) and (2) 16 who were treated with multi-technique therapy that included CH (Table 2). In the latter group, four patients received concomitant CDDP and RT to the neck, nine patients received CDDP and 5-fluorouracil (5-FU) followed by RT, and three patients were treated with adjuvant CDDP and 5-FU consisting of 3 courses after surgery, 6 courses after surgery followed by RT, or 6 courses after surgery and RT. In the group treated with CH followed by RT, two patients received surgery before RT and two patients alternated CDDP and 5-FU with 2 courses of methotrexate (MTX) and 5-FU. Surgery always consisted of RND on the side where the tumor was previously biopsied. RT was given to all possible sites of the primary (nasopharynx, pyriform sinus, and base of the tongue). The RT dosage planned for the whole neck or supraclavicular area was 50 to 60 Gy, increasing to 65 to 76 Gy on the metastatic site. The same dosages also were adopted for adjuvant RT after RND. One patient treated with CH-RT at the same time received an interstitial implant for a dose of 15 Gy. All patients receiving CH as part of their first planned therapy were treated between 1982 and 1988 (13 of 16 after 1983).

The responses to treatment were evaluated as follows: a complete response (CR) required no detectable disease; a partial response (PR) required a reduction of more than 50% for every tumor localization; and no response (NR)

TABLE 1. Survival of Patients With Metastatic SCC of an Unknown Primary Localized to the Neck Treated With Surgery and RT

Author/year	Treatment	Yrs.	Survival	
			Total (%)	N3 or massive
Barrie/1970 <sup>16</sup>	S ± RT	3	35	Not reported
		5	31	
Jesse/1972 <sup>3</sup>	S, RT, S + RT	3	53	36% NED
Coker/1977 <sup>5</sup>	S + RT	2	57	27% NED
		5	48	14% NED
Nordstrom/1979 <sup>6</sup>	S, RT, S + RT	2	53	36%
		5	29	16%
Jose/1979 <sup>7</sup>	RT ± S	3	39	31%
		5	31	26%
Fermont/1980 <sup>8</sup>	RT	2	17	Not reported
		5	5	
Pacini/1981 <sup>9</sup>	RT	2	39	28%
		5	32	21%
Leipzig/1981 <sup>10</sup>	S, RT, S + RT	3	40	39% (N2-N3)
Spiro/1983 <sup>2</sup>	S, S + RT	5	50	41% (N2-N3)
Carlson/1986 <sup>11</sup>	RT/S + RT	10	70	Not reported
Mohit-Tabatai/1986 <sup>12</sup>	S, RT, S + RT	5	18	0% N3, 15% N2
McCunniff/1986 <sup>13</sup>	RT ± S	2	38	0% NED
Yang/1986 <sup>14</sup>	RT	5	37	Not reported
	CH	5	5	Not reported
Bataini/1987 <sup>15</sup>	S, RT	5	33	14-18%

S: surgery; RT: radiotherapy; CH: chemotherapy; NED: no evidence of disease.

included responses less than 50% and stable or progressive disease.

### Statistical Methods

A comparison between treatment groups (CH history versus no CH history) by N stage was done using Fisher's exact test.<sup>17</sup> Since there were only two Stage N1 patients (neither treated with CH), we combined them with Stage N2 patients. The following two survival outcome variables were analyzed: survival from date of diagnosis and, for

TABLE 2. Patients According to First Planned Therapy

Treatment	No. of patients
RT alone	16
S alone	2
S + RT	7
CDDP 100 mg/M <sup>2</sup> (day 1, 22, 43) with concurrent RT	4
CDDP 100 mg/M <sup>2</sup> (day 1, 22, 44)* 5-FU 1000 mg/M <sup>2</sup> 120 hr infusion followed by RT	9
RND followed by CDDP + 5-FU and RT	3

RT: radiotherapy; S: surgery; CDDP: cisplatin; RND: radical neck dissection; 5-FU: 5-fluorouracil.

\* See Materials and Methods.

TABLE 3. Patient Characteristics

No. of patients	41
Median age in yrs (range)	58 (32-94)
Male	28
Female	13
Stage of disease	
N1	2 (5%)
N2	16 (39%)
N3	23 (56%)
Histologic Diagnosis SCC	
PD	27 (66%)
MD	5
WD	3
NS	3
UD	3

SCC: squamous cell carcinoma; NS: not specified; WD: well differentiated; PD: poorly differentiated; MD: moderately differentiated; UD: undifferentiated carcinoma.

those patients obtaining a CR (or surgically rendered free of disease), the disease-free interval from that date forward. Follow-up for survival and disease-free status was complete as of December 31, 1987. Only one patient was lost to follow-up (as of April 1987) and was regarded as a censored observation. Standard Kaplan-Meier estimates of the survivorship function were made, and differences in survival were investigated with the generalized Wilcoxon test.<sup>18</sup>

### Results

Among 41 evaluable patients, 28 were men and 13 were women. The median age of the patients was 58 years

(range, 32 to 94 years). Seventeen had nodes on the right side of the neck, 19 had nodes on the left side, and 5 had bilateral involvement. Four patients had only supraclavicular nodes.

The lesions were staged according to the TNM classification (23 [56%] were N3 or N3b [ $>3$  cm or bilateral], 16 [39%] were N2 [ $>3$  but  $<6$  cm], and 2 [5%] were N1 [Table 3]).

The histologic diagnosis was performed on the surgical biopsy in all cases except one that was a needle aspiration. Sixteen patients with the histologic diagnosis were referred to our institution and the slides for 11 of them were reviewed before starting the treatment. Thirty-eight patients had SCC (27 [66%] poorly differentiated, 5 [12%] moderately differentiated, and 3 [7%] well differentiated). In three cases, the differentiation was not specified and three patients had undifferentiated carcinoma. The diagnostic workup consisted of careful evaluation of the upper aerodigestive tract by triple endoscopy ( $n = 38$ ) or indirect examination, CT scan, or radiography of the chest (100%) and paranasal sinus (70%).

Negative random biopsies of the nasopharynx or hypopharynx were performed on more than 80% of the patients. In nine cases, the chest radiograph showed multiple suspect lesions but they were not confirmed on subsequent examination or remained stable for more than 2 years. The median time interval between the first symptoms and the beginning of therapy was 4 months (range, 1 to 20 months; mean, 4.8 months), without regard to stage. All 41 patients were treated with curative intent. There were 29 CR (71%) and 18 (44%) of these patients are alive without evidence of disease (NED). The overall median survival time is 35+ months (range, 1 to 100+ months)

TABLE 4. Median Survival Time of Patients With Metastatic SCC of an Unknown Primary Localized to the Neck According to Response After First Planned Treatment

Treatment	No. of patients	Stage N3/N2	CR	NED 12/87	Median survival (mo)
CDDP + RT (concurrent)	4	4/0	4	4	(4+-36+)
CDDP + 5-FU + RT	9	7/2	6 <sup>a</sup>	4	30 mo (3-71+)
CH + CDDP + 5-FU + RT	3	1/2	3	3	(11+-33+)
Total	16	12/4	13 81%	11 69%	37+ mo (2+-66+)
RND + RT <sup>b</sup>	9	2/7	9	2	35 mo (4-60)
RT alone	16	9/7 <sup>c</sup>	6	5	10 mo (1-100)
Total	25	11/14	15 60%	7 28%	24 mo (1-100+)
	41		28 68%	18 44%	35 mo

(a) One patient expired in clinic CR during Rt (see test); (b) two patients were treated with CH alone; and (c) two patients were N1.

CR: complete response; NED: no evidence of disease; CDDP: cisplatin; 5-FU: 5-fluorouracil; RT: radiotherapy; RND: radical node dissection.

TABLE 5. Metastatic SCC of an Unknown Primary Localized to the Neck Treated With Combined Therapy Including Chemotherapy

Treatment	No. of patients	N3/N2	Response after chemotherapy			Response after combined treatment		
			CR	PR	NR	CR	PR	NR
Concurrent CDDP + RT	4	4/0				4	—	—
CDDP + 5-FU followed by RT	9	8/1	2	5	2	5	1	1
Adjuvant RT + chemotherapy after RND†	3	2/1				3	—	—

\* Two patients received RND after RD with chemotherapy; two patients died after chemotherapy, one in CR and one in PRO.

CR: complete response; PR: partial response; NR: no response; CDDP:

cisplatin; RT: radiotherapy; 5-FU: 5-fluorouracil; RND: radical neck dissection.

as shown in Table 4 The proportion of patients with N3 disease in the CH group was higher (75%) than that in the N0 CH group (44%), but not significantly higher ( $P = 0.063$ ).

Two of the nine patients treated with surgery as first planned therapy are still NED at 41 months and 19 months after surgery and surgery and RT, respectively. The median survival time of this group is 26 months. Three patients died of locoregional recurrences. A primary in the pyriform sinus with contralateral nodes developed in one patient 57 months from primary treatment (surgery alone). This patient died in 2 months. Two patients died of adenocarcinoma of the prostate at 12 months and 24 months after RND and one died of an unknown cause after 60 months.

In the group treated with RT alone, all six (38%) patients who obtained a CR are still alive (five NED [range, 19+ to 100+ months]). A primary (involving base of the tongue and false vocal cords) developed in two patients at 17 months and 28 months after RT. One patient with N1 disease had a local CR, but pulmonary metastasis developed at the end of the treatment. Five patients were PR or NR; distant metastasis developed in four of them (one to bone and three to lungs) and no one in this group survived more than 12 months). Two patients died during RT (one of disease progression and one of respiratory failure). Two patients discontinued treatment because of no response and died within 3 months. Patients treated with a combination technique that included CH constitute the most heterogeneous group. Twelve patients (75%) were in CR at the end of therapy (Table 5), and 11 (69%) of them are still NED as of December 31, 1987. The median survival time of the whole group is 37 months (Table 4).

Two patients died before completing treatment (one in clinical CR after CH from suspected cardiac toxicity during the first week of RT and one NR from Staph sepsis after the second course of CH). One patient progressed after CDDP, 5-FU, and MTX and reached a CR when treated with CDDP and concurrent RT. One patient had

an epiglottic primary discovered 10 months after the last therapy. He was treated with total laryngectomy but had a lung recurrence and died of progressive disease 24 months later. All three patients treated with adjuvant CH were disease-free after surgery and are still NED after at least 14 months. Three of four patients with supraclavicular nodes were treated without CH because of presenting N2 disease (two of them died at 10 months and 26 months out from therapy with local recurrence and bone metastasis). The remaining two patients are still alive NED at more than 30 months. None among this group showed lung or abdominal primary.

Patients with N3 disease who received CH had a higher CR rate (nine of 12; 75%) and longer survival time ( $P = 0.025$ ) than those who did not receive CH (four of 11; 36%) (see Fig. 1). Patients who received CH had a higher CR rate (81% versus 60%) and median survival time (37+ months versus 24 months) than those who did not receive CH. This evidence is confirmed in the N3 group.

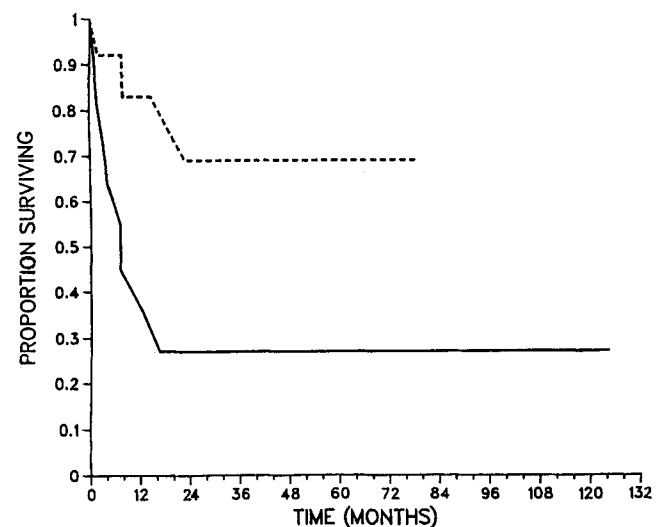


FIG. 1. Survival of patients only N3 disease treated with CH (-----) versus those patients treated without CH (——) ( $P = 0.025$ ).

### Discussion

Metastatic SCC to the neck usually has an occult primary origin most probably from the H & N area.<sup>1</sup> These tumors have a prognosis strongly related to stage of disease at diagnosis, regardless of whether or not the primary is found.<sup>2,19,20</sup> However, for node metastasis from an unknown primary, the staging is imprecise when it is not related to the tumor burden. The presence of two small mobile bilateral lymph nodes is considered the same stage as a huge fixed mass, whereas prognosis and therapeutic options are very different.<sup>4</sup> A second important prognostic factor for these tumors is the later development of a primary that usually renders these patients incurable.<sup>1,2</sup>

The traditional treatment of SCC of an unknown primary is still very controversial because both surgery and RT are effective for small lesions, but they often fail to provide adequate cure rates for larger tumors even when they are used in combination (Table 1).

Although the use of RT may reduce the later occurrence of a primary,<sup>3,6</sup> such an event may occur even when all possible sites of origin are adequately irradiated.<sup>13</sup> Perhaps this event is related to the presence of multiple primaries, since they occur in approximately 20% of H & N tumors.<sup>21-23</sup>

Our experience in the management of SCC of an unknown primary localized to the neck confirms the importance of an accurate workup to stage the extent of disease. Due to the unusually high incidence of poorly differentiated SCC (24 of 25), the biopsies of these patients were carefully reevaluated and confirmed. A possible explanation is the occult nasopharyngeal origin for these tumors. However, all the biopsies of the nasopharynx were negative and none of the four patients with a primary discovered after the end of therapy (10 to 57 months later) had that site involved (three were supraglottic and one base of the tongue). Furthermore, only one of them is still alive with disease that is inconsistent with nasopharynx (NP) primary. We did not find any notable association of distant metastasis and stage of disease or tumor differentiation.

We think that the introduction of CH as part of the first planned therapy has great merit. A better CR rate (83% versus 69%) has been obtained among patients treated with CH, despite the higher number of "inoperable" N3 diseases present in this group (Table 4). Furthermore, the patients with N3 who received CH had a higher CR rate and longer survival time compared with those with similar stage treated with other techniques (Fig. 1).

To define a better therapeutic approach for carcinomas of an unknown primary localized to the neck, we must consider the combination of at least two treatment tech-

niques for all nodal sites except N1. However, the majority of the published studies conducted with the combination of RT and surgery failed to induce a cure rate greater than 30% in patients with N3 disease.<sup>2,5-7,12,13</sup> An overall survival rate of 70% at 10 years has been reported by Carlson *et al.*,<sup>14</sup> but only 22% of those patients were N3 and all of them were resectable. The role of CH for this disease has been explored sporadically and not with the most active regimens. In the last few years, a continuous improvement in response rates to CH has been obtained for SCC of the H & N with CDDP-containing regimens.<sup>24,25</sup> For N2 and N3 disease we propose at least 3 courses of CDDP containing CH followed by concurrent CDDP and RT as first planned treatment and surgery on the residual disease. This is because of the synergistic action of concurrent CDDP and RT<sup>26-28</sup> and because surgery is the most effective treatment for recurrence, whereas both CH and RT are less effective on patients previously treated.<sup>29</sup>

Since our results indicate a survival advantage for patients with extensive disease treated with CH as part of the initial treatment of SCC of the H & N from an unknown primary, this therapeutic approach should be tested in a national randomized trial.

### REFERENCES

1. Fitzpatrick PT, Keane T. Cervical lymph node metastases from an unknown primary tumor: the place of radiotherapy. *Head and Neck Cancer*, Vol. 1. B.C. Decker Inc., publishers, 1985.
2. Spiro RH, DeRose G, Strong EW. Cervical node metastasis of occult origin. *Am J Surg* 1983; 146:441-446.
3. Jesse RH, Perez CA, Fletcher GH. Cervical node metastasis: unknown primary cancer. *Cancer* 1973; 31:854-859.
4. Young JEM. The unknown primary: prognosis and follow-up. *Head and Neck Cancer*, Vol. 1. B.C. Decker Inc., publishers, 1985.
5. Coker DD, Casterline PF, Chambers RG, Jaques DA. Metastases to lymph node of the head and neck from unknown primary site. *Am J Surg* 1977; 517-522.
6. Nordstrom DG, Tewfik HH, Latourette HB. Cervical lymph node metastases from an unknown primary. *Int J Radiat Oncol Biol Phys* 1979; 5:73-76.
7. Jose B, Bosch A, Caldwell WL, Frias Z. Metastasis to neck from unknown primary tumor. *Acta Radiol Oncol* 1979; 18:161-170.
8. Fermont DC. Malignant cervical lymphadenopathy due to an unknown primary. *Clin Radiol* 1980; 31:355-358.
9. Pacini P, Olmi P, Cellai E, Chiavacci A. Cervical lymph node metastases from an unknown primary tumor. *Acta Radiol Oncol* 1981; 20:311-314.
10. Leipzig B, Winter ML, Hokanson JA. Cervical nodal metastases of unknown origin. *Laryngoscope* 1981; 91:595-598.
11. Carlson LS, Fletcher GH, Oswald MJ. Guidelines for radiotherapeutic techniques for cervical metastases from an unknown primary. *Int J Radiat Oncol Biol Phys* 1986; 12:2101-2110.
12. Mohit-Tabatabai MA, Dasmahapatra KS, Rush BF, Ohanian M. Management of squamous cell carcinoma of unknown origin in cervical lymph nodes. *Am Surg* 1986; 52:152-154.
13. McCunniff A, Raben M. Metastatic carcinoma of the neck from an unknown primary. *Int J Radiat Oncol Biol Phys* 1986; 12:1849-1852.
14. Yang ZY, Hu YH, Yan JH, Cai WM, Qin DX, Xu GZ, Wu XL. Lymph node metastases in the neck from an unknown primary. *Acta Radiol Oncol* 1983; 22:17-22.

15. Bataini JP, Rodriquez J, Jaullery C, Brugere J, Ghossein NA. Treatment of metastatic neck nodes secondary to an occult epidermoid carcinoma of the head and neck. *Laryngoscope* 1987; 97:1080-1084.
16. Barrie JR, Knapper WH, Strong EV. Cervical nodal metastases of unknown origin. *Am J Surg* 1970; 120:466-470.
17. Everett BS. The analysis of contingency tables. London: Chapman and Hall, 1986; 15-20.
18. Lee ET. Statistical methods for survival data analysis. Belmont, CA: Lifetime Learning Publications, 1980:122-127.
19. Kumar PP, Good RR, Epstein BE, Yonkers AJ, Ogren FP, Moore GF. Outcome of locally advanced stage III and IV head and neck cancer treated by surgery and postoperative external beam radiotherapy. *Laryngoscope* 1987; 97:615-620.
20. Richard JM, Sancho-Garnier H, Micheau C, Saravane D, Cachin Y. Prognostic factors in cervical lymph node metastasis in upper respiratory and digestive tract carcinomas: study of 1713 cases during a 15-year period. *Laryngoscope* 1987; 97:97-101.
21. Silverman CL, Marks JE, Lee F, Ogura JH. Treatment of epidermoid and undifferentiated carcinomas from occult primaries presenting in cervical lymph nodes. *Laryngoscope* 1983; 93:645-648.
22. Weaver A, Fleming SM, Knechtges TC, et al. *Surgery* 1979; 86: 493-496.
23. Shibuya H, Hisamitsu S, Shioiri S, Horiuchi J, Suzuki S. Multiple primary cancer risk in patients with squamous cell carcinoma of oral cavity. *Cancer* 1987; 60:3083-3086.
24. Al-Sarraf M. Head and Neck Cancer: chemotherapy concepts. *Semin Oncol* (15) No. 1, 1988; 70-85.
25. Ensley JF, Kish JA, Tapazoglou E, Jacobs J, Weaver A, Crissman J, Al-Sarraf M. A progress report: a five course, alternating combination chemotherapy induction regimen in advanced squamous cell cancer of head and neck (SCC of H&N). *Proc Am Soc Clin Oncol* (5) 1986; 142 abstract 555.
26. Jacobs C, Goffinet DR, Goffinet L, Kohler M, Fee WE. Chemotherapy as a substitute for surgery in the treatment of advanced resectable head and neck cancer. *Cancer* 1987; 60:1178-1183.
27. Bellamy AS, Hill BT. Interactions between clinically effective antitumor drugs and radiation in experimental system. *Biochim Biophys Acta* 1984; 738:125-166.
28. Al-Sarraf M, Pajak TF, Marcial VA, Mowry P, Cooper JS, Stetz J, Ensley JF, Velez-Garcia E. Concurrent radiotherapy and chemotherapy with cisplatin in inoperable squamous cell carcinoma of head and neck: An RTOG study. *Cancer* 1987; 59:259-265.
29. Rider WD, Harwood AR. The Toronto philosophy in management in head and neck cancer. *J Otolaryngol* 1982; 11:14-16.