

## Disfiguring Nodular Cephalic Xanthoma Disseminatum: An Exceptional Variant of a Forgotten Entity

Arturo BONOMETTI<sup>1</sup>, Jessica GLIOZZO<sup>2\*</sup>, Chiara MOLTRASIO<sup>2</sup>, Filippo BAGNOLI<sup>3</sup>, Luigia VENEGONI<sup>4</sup>, Emanuela PASSONI<sup>2</sup>, Marco PAULLI<sup>1</sup> and Emilio BERTI<sup>2,4</sup>

<sup>1</sup>Unit of Anatomic Pathology, Department of Molecular Medicine, IRCCS San Matteo Foundation, University of Pavia, Pavia, <sup>2</sup>Unit of Dermatology, Fondazione IRCCS Ca' Granda Ospedale Maggiore Policlinico, Via Pace 9, Milan, <sup>3</sup>Department of Oncology and Hematology, and <sup>4</sup>Department of Pathophysiology and Organ Transplantation, University of Milan, Milan, Italy. E-mail: jessica.giozzo@gmail.com

Accepted Jan 7, 2019; E-published Jan 9, 2019

Xanthoma disseminatum (XD) is an extremely rare cutaneous, normolipidemic, proliferative disorder of the Mononuclear Phagocyte System. It was first described by Von Gräfe and Virchow but recognized as a distinct entity by Montgomery & Osterberg in 1938 (1). Approximately 140 cases are reported in the English literature. Clinically, XD is characterized by a symmetrical skin eruption of reddish papules or nodules, with predilection for the head, neck, flexural and intertriginous areas. These lesions, initially isolated, tend to slowly merge into large yellowish plaques, during years. The mean age at presentation is 30 years and male cases outnumber female ones by a ratio of 2:1. XD is generally thought to be a benign disorder with a chronic progressive course (2–4). Caputo et al. (5) recognized 3 clinical variants of XD: 1) a self-healing form; 2) a persistent form and 3) a progressive multi-system (MS) form. The report rate of this entity is becoming even lower now than in past years, perhaps due to its high diagnostic overlap with Erdheim-Chester Disease (ECD) (6, 7).

### CASE REPORT

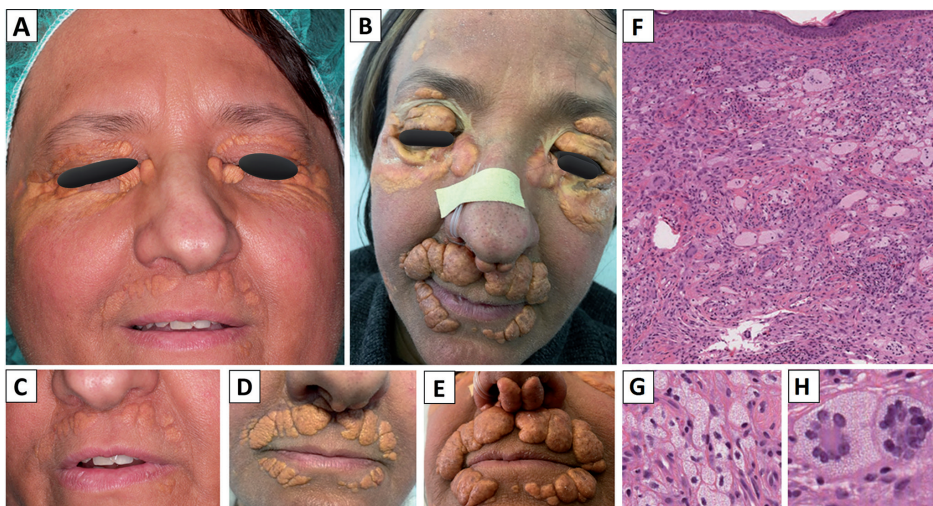
We hereby describe the case of a previously healthy 47-year-old Caucasian woman presented to our attention in January 2011, with a 2-year long history of cephalic xanthomas. Her lesions consisted of yellow periocular and perioral plaques extending to the zygomatic area as well as small yellow hard-elastic nodules growing next to the inner canthi (**Fig. 1**). Complete radiological, hematological (blood count, metabolic, renal and liver functions/profiles) and endocrinological examinations all tested negative

and failed to reveal any systemic involvement. Five years after our first diagnosis, she suffered of ischemic heart failure and therefore underwent percutaneous revascularization to complete normalization of cardiac function. During the following 7 years, the lesions displayed a slow but progressive extension with symmetrical involvement of the whole face (**Fig. 1**). She never developed diabetes insipidus or any other signs of systemic involvement. Previous therapy (hydroxychloroquine and cyclophosphamide) and surgeries (including CO<sub>2</sub> laser therapy) led to constant recurrences and subsequent regrowth of lesions, together with surgery-related keloid scars, resulting in high mechanical, psychological and sociological impairment. Skin biopsy (**Fig. 1**) showed a polymorphic dense upper- and mid-dermal infiltration consisting of large histiocytes, admixed with few lymphocytes and neutrophils. Histiocytes were mostly characterized by large nuclei often with prominent nucleoli and an abundant pale cytoplasm. Foamy, Touton and Langhans cells were also present, focally in large numbers. There were no signs of epidermotropism. Immunohistochemical profile of the histiocytes was positive for CD4, CD11c, CD14, CD68/PGM1, CD163, fXIIIa, vimentin, lysozyme, fascin but tested negative for CD1a, CD34 and CD207/langerin. Ki-67 stained 1–5 % of the cells. Altogether, clinical–pathological examination led to a non-conclusive diagnosis of xanthogranuloma vs xanthoma disseminatum. BRAF<sup>V600E</sup> analysis failed to reveal any alteration. Sixteen years after the first manifestation, the patient is alive and in a good clinical condition, although with chronic persistent evolution of the disfiguring lesions.

Informed consent was obtained in accordance with local ethical guidelines and with the Helsinki Declaration of 1975.

### DISCUSSION

Histiocytoses have recently been reclassified in 5 different groups based on a combination of clinical, ra-



**Fig. 1. Clinical and histopathological features of the patient.** The patient came to our attention with yellowish plaques limited to periocular and perioral regions (A, C). During the first 2 years of follow-up the lesions slowly increased in volume and extended to columella (D) and after 5 years they presented as thick tumor/nodular lesions and confluent plaques extending to the forehead, zygoma, eyelids, outer nostrils and mentolabial sulci (B, E). Skin biopsy revealed a dense and polymorphic histiocytic infiltrate (F) made up of large cells with abundant and often foamy cytoplasm (G) and multinucleated giant cells of the Touton (H) and Langhans type, admixed with small lymphocytes and neutrophils.

diographic, histopathological and molecular findings. XD belongs to the “xanthogranuloma-family” of the C(utaneous)-group, due to its prevalent skin involvement and the polymorphic histiocytic infiltrate made of foamy cells, large histiocytes with abundant eosinophilic cytosol, and giant multinucleated cells of the Touton and Langhans-type (6–8).

Clinical presentation of XD is highly heterogeneous: the skin is always involved, but location and evolution of the lesions may be highly variable. Mucous membrane manifestations appear in up to 50% of cases. The growth of the lesions may cause severe mechanical impairment (e.g. mechanical blindness, respiratory obstruction or difficulty in defecation). Diabetes insipidus is commonly seen (40% of cases). Involvement of other organs (i.e. bones, kidneys, pancreas, uterus, lymph nodes, central nervous system) is described, although less frequent (2–4).

Differential diagnosis of XD is highly problematic, same as for other non-Langerhans-cell histiocytosis (NLCHs) (see Table S1<sup>1</sup>). Purely cutaneous (single-system) XD cases generally involve multiple skin areas including eyelids, neck, axillae, elbows, groin and perianal region and should be clinically differentiated from adult xanthogranuloma, based on the number, distribution and evolution of the lesions. Differential diagnosis may be more challenging for multi-system-xanthoma disseminatum, as many clinical-pathological features coincide with the recently defined diagnostic criteria for ECD. For such reasons, those two rare histiocytoses have already been proposed to be a part of the same spectrum of entities, if not synonyms, as a matter of fact (9, 10). Our patient displays two very uncommon features for XD, namely the face-limited localization and the tumor-like lesions. In fact, the isolated cephalic involvement has been previously reported in only 3 cases (11). The limitation to head and neck region is seen in other NLCH but it is the predominant feature of benign cephalic histiocytosis (BCH), a pediatric histiocytosis presenting with a self-limiting papular eruption. XD could be differentiated from BCH on the basis of epidemiological, clinical and histopathological findings. Even though the pathogenesis of such a disorder is practically unknown, one hypothesis could relate such circumscribed localization to some regional (dis-) immune factors (10).

The development of nodular/tumor-like lesions, is otherwise seen in Progressive Nodular Histiocytosis (PNH), another rare C-histiocytosis characterized by a florid symmetrical proliferation of hundreds of large nodules/tumors all over the cutaneous surface. XD and PNH are generally indistinguishable from a histopathological point of view, although PNH may also display a spindle-shaped histiocyte morphology (12).

The presence of BRAF mutations in a significant percentage of patients with histiocytosis and the consequent hyper-activation of the MAPK-pathway seems to play an important role in histiocytic disorders and they have been proposed as diagnostic markers for some entities (e.g. ECD) (13). To the best of our knowledge, the present report is the only one that characterizes XD on a molecular level. Due to the limited amount of literature concerning the molecular landscape of XD, we consider it an important topic to be investigated. Even though the differential benefit of molecular analysis in histiocytoses has recently been denied, molecular characterization is important in order to gather information about the etiology and possibly prognostic stratification in such a rare disorder (13).

The standard therapy strategy for XD is still undefined, although, several therapeutic strategies have been described (14). A review on XD patients, with long-term follow-up, recognized a subset of cases with therapy-unrelated spontaneous partial or complete resolution of lesions (15). Beside these data, several other papers reported progression and/or death of XD patients even after aggressive chemotherapy regimens; consequently, the best therapeutic approach still needs to be weighed against the patient’s clinical severity (4, 11).

In conclusion, we described a very unusual case of XD. Our patient’s features conform to the clinical heterogeneity of histiocytoses and show how differential diagnosis, prognostic stratification and therapeutic approach to NLCH may be incredibly troublesome. Future works should point out the clinical-pathological overlaps between NLCH and perhaps adopt a descriptive nomenclature (as for langerhans cell histiocytosis) allowing for an easier approach to therapeutic decisions.

*The authors have no conflicts of interest to declare.*

## REFERENCES

1. Montgomery H, Osterberg AE. Xanthomatous correlation of clinical, histopathologic and chemical studies of cutaneous xanthoma. *Arch Dermatol Syphilol* 1938; 37: 373–402.7
2. Altman J, Winkelman RK. Xanthoma disseminatum. *Arch Dermatol* 1962; 86: 582–585.
3. Knobler RM, Neumann RA, Gebhart W, Radaskiewicz T, Ferenci P, Widhalm K. Xanthoma disseminatum with progressive involvement of the central nervous and hepatobiliary systems. *J Am Acad Dermatol* 1990; 23: 341–346.
4. Yang GZ, Wang LP: Disseminated intracranial xanthoma disseminatum: a rare case report and review of literature. *Diag Pathol* 2016; 11: 78.
5. Caputo R, Veraldi S, Grimalt R, Gianotti R, Tosti A, Varotti C, de Kaminsky AR. The various clinical patterns of xanthoma disseminatum. Considerations on seven cases and review of the literature. *Dermatology* 1995; 190: 19–24.
6. Emile JF, Ablu O, Fraitag S, Horne A, Haroche J, Donadieu J, et al. Revised classification of histiocytoses and neoplasms of the macrophage-dendritic cell lineages. *Blood* 2016; 127: 2672–2681.
7. Ozkaya N, Rosenblum MK, Durham BH, Pichardo JD, Abdel-Wahab O, Hameed MR, et.al. The histopathology of Erdheim-Chester disease: a comprehensive review of a molecularly characterized cohort. *Mod Pathol* 2018; 31: 581–597.

<sup>1</sup><https://www.medicaljournals.se/acta/content/abstract/10.2340/00015555-3111>

8. Berres M-L, Allen CE, Merad M. Pathological consequences of misguided Dendritic Cell differentiation in Histiocytic Diseases. *Adv Immunol* 2013; 120: 127–161.
9. Classen CF, Minkov M, Lehrnbecher T. The non-Langerhans cell histiocytoses (rare histiocytoses) - clinical aspects and therapeutic approaches. *Klin Padiatr* 2016; 228: 294–306.
10. Brousse N, Pileri SA, Haroche J. in: WHO classification of hematopoietic and lymphoid tissues, Revised 4th Edition. Lyon France: IARC Press, 2017: 480–481.
11. Ansarin H, Berenji Ardestani H, Tabaie SM, Shayanfar N. Xanthoma disseminatum with tumor-like lesion on face. *Case Rep Dermatol Med* 2014; 2014: 621798.3.
12. Hilker O, Kovneristy A, Varga R, Neubert T, Wesselmann U, Flaig MJ, et al. Progressive nodular histiocytosis. *J Dtsch Dermatol Ges* 2013; 11: 301–307.
13. Durham BH. Molecular characterization of the histiocytoses: Neoplasia of dendritic cells and macrophages. *Semin Cell Dev Biol* 2018 Mar 16. [Epub ahead of print].
14. Ceppi F, Abla O. Xanthoma Disseminatum. In: Abla O, Janka G. *Histiocytic Disorders*. Springer 2018; 17: 301–302.
15. Park HY, Cho DH, Kang HC, Yun SJ. A case of xanthoma disseminatum with spontaneous resolution over 10 years: review of the literature on long-term follow-up. *Dermatology* 2011; 222: 236–243.

**Comments from the Editorial Office: Please shorten the text by about 200 words to fit this within the 2-page limit of a Short Communication.**

**Table SI. Summary of the main clinical-pathological features characterizing non-Langerhans-cell histiocytosis**

	Erdheim-Chester disease	Xanthoma disseminatum	Adult xanthogranuloma	Progressive nodular histiocytosis	Benign cephalic histiocytosis
M:F	3:1	2.5:1	3:1	2/3:1	2:1
Age (years)	55-60	25-40	20-40	10-30	0-3
Diagnosis	Clinical-pathological, radiological and molecular (?)	Clinical-pathological	Clinical-pathological	Clinical-pathological	Clinical-pathological
Bone	95% (bilateral symmetric lesions of long bones).	Uncommon	Uncommon	None	None
CNS/Diabetes insipidus (DI)	30% DI. Neurodegenerative CNS involvement described.	40% DI. CNS lesions, uncommon.	Uncommon	None	None
Skin	Xanthelasma (33%), papules, plaques.	Xanthelasma, papules (confluent) plaques, nodules. Mucosal involvement	Single papules or nodules. Less often multiple papules	Hundreds of large nodules or tumor-like lesions all over the skin surface. Mucosal involvement	Several small papules distributed on head and neck region only
Histology	Polymorphic histiocytic infiltrate with foamy cells (prevalent especially in late phase of disease), Touton giant cells and sometimes (PNH) spindled histiocytes. Background with mixed inflammatory infiltrate.			Monomorphic non-foamy, non-epitheliomorphic histiocytic infiltrate admixed with few lymphocytes.	
Electron microscopy	Lipid vacuoles, myeloid bodies, highly developed endomembrane system, lysosomes, phagosomes.			Coated vesicles, comma-shaped bodies (20%)	
Immunohistochemistry	CD163+, CD68/PGM1+, CD68/KP1+, CD14+, CD4+, fXIIIa+, Vimentin+, S100+/-, CD1a-, CD207-.				
BRAF	50% [13]	n.d	7% [13]	n.d.	n.d.
Other mutations	45% [13]	n.d	50-60% [13]	n.d.	n.d.

The table highlights the great overlap among these entities, which makes a correct diagnosis difficult to make.