

# Hypoglossal-facial nerve anastomosis and rehabilitation in patients with complete facial palsy: cohort study of 30 patients followed up for three years

Elena Dalla Toffola, MD<sup>a,b</sup>  
Chiara Pavese, MD<sup>a</sup>  
Miriam Cecini, MD<sup>a</sup>  
Lucia Petrucci, MD<sup>b</sup>  
Susanna Ricotti, MD<sup>b</sup>  
Maurizio Bejor, MD<sup>a,c</sup>  
Grazia Salimbeni, MD<sup>d</sup>  
Federico Biglioli, MD<sup>e</sup>  
Catherine Klersy, MD, MSc<sup>f</sup>

<sup>a</sup> Department of Clinical, Surgical, Diagnostic and Pediatric Sciences, University of Pavia, Pavia, Italy

<sup>b</sup> Rehabilitation Unit - Fondazione IRCCS Policlinico San Matteo, Pavia, Italy

<sup>c</sup> Rehabilitation Unit, Fondazione Don Carlo Gnocchi ONLUS, "Santa Maria alle Fonti" Medical Center, Salice Terme, Pavia, Italy

<sup>d</sup> San Rossore Hospital, Pisa, Italy

<sup>e</sup> Unit of Maxillo-Facial Surgery, Department of Health Sciences, San Paolo Hospital, University of Milan, Milan, Italy

<sup>f</sup> Department of Biometry and Clinical Epidemiology, Fondazione IRCCS Policlinico San Matteo, Pavia, Italy

Correspondence to: Elena Dalla Toffola  
E-mail: elena.dallatoffola@unipv.it

## Summary

**Our study evaluates the grade and timing of recovery in 30 patients with complete facial paralysis (House-Brackmann grade VI) treated with hypoglossal-facial nerve (XII-VII) anastomosis and a long-term rehabilitation program, consisting of exercises in facial muscle activation mediated by tongue movement and synkinesis control with mirror feedback.**

Reinnervation after XII-VII anastomosis occurred in 29 patients, on average 5.4 months after surgery. Three years after the anastomosis, 23.3% of patients had grade II, 53.3% grade III, 20% grade IV and 3.3% grade VI ratings on the House-Brackmann scale. Time to reinnervation was associated with the final House-Brackmann grade. Our study demonstrates that patients undergoing XII-VII anastomosis and a long-term rehabilitation program display a significant recovery of facial symmetry and movement. The recovery continues for at

least three years after the anastomosis, meaning that prolonged follow-up of these patients is advisable.

*KEY WORDS:* facial nerve, facial palsy, hypoglossal-facial nerve anastomosis, mirror feedback, rehabilitation

## Introduction

Hypoglossal-facial nerve (XII-VII) anastomosis is a surgical procedure that has long been used to restore movement to the facial muscles in cases of paralysis of the seventh cranial nerve (Ozsoy et al., 2011). Many surgical techniques have been reported for this procedure, but clinical series in the literature seem to demonstrate comparable functional recovery for the different approaches (Lin et al., 2009). After surgery, the facial muscles are reinnervated by the twelfth cranial nerve, therefore patients have to learn how to control facial motility through the use of voluntary tongue movements (Rinn, 2007). This use of the new motor circuit is accompanied by a reorganization of brain activation patterns: hypoglossal motor cortex activation is observed when patients perform facial movements (Bitter et al., 2011). In a 2007 meta-analysis, Yetiser and Karapinar (2007) reported a median improvement of two levels on the House-Brackmann (HB) grading system in patients who underwent surgery alone.

Following XII-VII anastomosis, patients frequently undergo a rehabilitation program to learn how to use the new motor circuit and how to prevent or control synkinesis (Magliulo et al., 2001; Sleilati et al., 2010). Preliminary studies suggest a favorable effect of electromyographic biofeedback rehabilitation (Brudny et al., 1988; Dalla Toffola et al., 1996), but systematic studies assessing patients who have undergone XII-VII anastomosis and rehabilitation are still lacking. The aim of this study was to assess the grade and timing of recovery in patients with complete facial palsy treated with XII-VII anastomosis followed by a home rehabilitation program involving mirror visual feedback.

## Materials and methods

### Patients

Since 2002, we have planned and monitored the post-surgical rehabilitation of 47 patients with complete uni-

lateral facial palsy (HB grade VI) who had undergone XII-VII anastomosis. Patients who met the following inclusion criteria were included in the present study:

- first rehabilitation assessment at our unit within 12 months of surgery.
- follow-up at our unit at 12, 18 and 36 months after surgery.

The study was approved by the institutional ethics committee and the patients gave their written consent to participate in the research study.

### **Clinical assessment**

The HB grading system (House and Brackmann, 1985) was used to evaluate the severity of paralysis before the anastomosis, at the first rehabilitation assessment and at follow-up sessions 12, 18 and 36 months after surgery. The HB system grades facial function on a six-point scale of increasing severity from I (normal function) to VI (complete paralysis) (House and Brackmann, 1985).

### **Rehabilitation treatment**

The objectives of rehabilitation are i) for the patient to become aware of being able to perform new movements, ii) for the patient then to learn the tongue movements that produce facial muscle contractions, and iii) to render the newly acquired movements automatic (Dalla Toffola and Petrucci, 2007; Ross et al., 1991). At each clinical assessment patients were taught to perform specific exercises, according to their clinical status, and were then instructed to repeat them daily at home. For the first four to five months after surgery, before the first signs of reinnervation appear, patients who have undergone this procedure have complete facial paralysis. In order to reduce muscle atrophy and to improve musculocutaneous vascularization during this phase, they are trained to carefully massage their face. In addition, patients are taught compensatory techniques to help them in their activities of daily living and esthetic camouflage in an attempt to both reduce their disability and improve their social participation (Coulter and May, 2000; Dalla Toffola et al., 2011). During the next phase, at the first signs of reinnervation, patients, using mirror feedback, need to learn which tongue positions (thrust against teeth or palate) produce the desired facial expressions. At first, they need to use a strong tongue thrust to achieve static and dynamic facial symmetry. To help them memorize the correct position and strength of tongue thrust, they are told to repeat the movement several times a day. As reinnervation improves, the tongue thrust does not have to be so strong in order to achieve symmetry. At this point the patients are taught to use mirror visual feedback to dose the strength of tongue thrust necessary to achieve symmetry of muscle contraction between the reinnervated and the healthy side and to prevent the onset of synkinesis. Once patients have mastered static symmetry, they need to improve dynamic symmetry. To do this they

must learn how to produce a voluntary smile; again they need to use a mirror, dosing the strength of their tongue thrust and repeating the movement several times a day. The same process is then used to learn other voluntary movements such as snarling and lip puckering. If eye-mouth synkinesis occurs, patients are told to reduce the strength of their tongue thrust. Through repetition of these exercises the movements become automatic, i.e. patients, through the unconscious use of minimal tongue movements (just as in speaking) become able to move the reinnervated muscles.

### **Statistical analysis**

The data are described as mean values  $\pm$  standard deviation or range and median values with 25<sup>th</sup>-75<sup>th</sup> percentiles if continuous, and as counts and percentages if categorical. The median HB score at different time points was compared using the Friedman test. For post-hoc comparisons, the exact McNemar test was used, as well as a test for linear trend of the log-relative risk to exploit the ordinal nature of the score. Finally, the Spearman test was used to identify variables associated with the HB grade at 36 months. The Spearman R and 95% confidence interval (95%CI) were computed.

Stata 12 (Stata Corp, College Station, TX, USA) was used for computation. A two-sided p-value  $<0.05$  was considered to be statistically significant. The Bonferroni correction was applied for pairwise post-hoc comparisons over time (p-values  $<0.0125$  were considered significant).

### **Results**

Thirty patients were included in the study. The sample (mean age  $39\pm 18$  years) included 13 males (43%). The facial palsy involved the right side in 17 (57%) patients. The etiology of palsy was postsurgical in 17 (57%), expansive lesion in three (10%), traumatic in three (10%), vascular in six (20%) and infectious in one (3%) patient.

Surgery was performed on average at  $17\pm 12$  months (range 0.6-52) after paralysis at nine different hospitals. Twenty-six patients underwent the traditional XII-VII anastomosis technique whereas in four cases a 'jump' interpositional graft was performed.

Reinnervation occurred in 29 patients, on average at  $5.4\pm 2.1$  months (range 3-12) after the surgery. Only one patient, whose palsy was caused by a brain hemorrhage, did not show signs of reinnervation after the surgery.

The first rehabilitation assessment took place on average  $5.6\pm 3$  months (range 0.4-11.8) after the surgery. At the first rehabilitation assessment, 23 patients (77%) presented with deficits in other cranial nerves in addition to the seventh; in eight of those cases more than two cranial nerves were damaged. Eighteen patients had hypoacusis, due to the removal of a neuroma of the eighth cranial nerve in 16 patients, and to an expansive

lesion in two. To prevent eye complications related to incomplete eyelid closure, eight patients had gold weight implants and six patients had undergone tarsorrhaphy. Four patients had dysphagia, 11 complained of lachrymation disorders, and nine had ataxia.

During the rehabilitation period, 29 patients showed clinical improvement as revealed by the HB grading system. Scores significantly decreased over time, from a value of VI for all patients before surgery, to a median of V (25<sup>th</sup>-75<sup>th</sup> V-VI) at the first rehabilitation assessment and V (25<sup>th</sup>-75<sup>th</sup> IV-V), III (25<sup>th</sup>-75<sup>th</sup> III-IV) and III (25<sup>th</sup>-75<sup>th</sup> III-III) at 12, 18 and 36 months respectively (Friedman test  $p < 0.001$ ). All post-hoc comparisons showed a significant reduction in scores (test for trend:  $p < 0.01$  for all consecutive assessments; Fig. 1). An improvement of more than two levels on the HB rating scale was observed in 70% of patients at 18 months and in 77% at 36 months.

As shown in table I, only the time between XII-VII anastomosis and reinnervation showed a statistically significant ( $p = 0.015$ ), although moderate (Spearman R 46%), association with the HB score at 36 months, with lower HB scores obtained with shorter times to reinnervation.

At the end of the follow-up period, three patients presented dysphagia and four patients had mild post-surgery hemitongue atrophy without difficulty in moving their tongue.

Fourteen patients developed mild synkinesis involving contraction of the orbicularis oculi muscle on activation of the orbicularis oris, zygomaticus major and risorius muscles; two such cases were treated with botulinum toxin injections (Dalla Toffola et al., 2010).

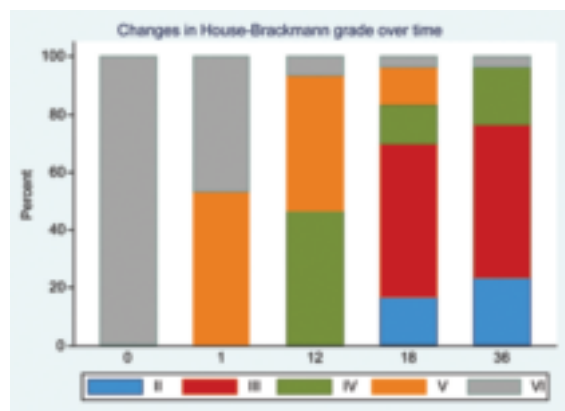


Figure 1 - Percent distribution of HB grades at surgery (0), at first rehabilitation assessment (1), and at 12, 18 and 36 months after the anastomosis.

Three years after surgery, 80% of the patients declared that they were able to automatically activate their facial muscles through tongue movements, but no patient was capable of producing a spontaneous smile.

### Discussion

Our study demonstrates that patients treated with XII-VII anastomosis followed by a rehabilitation program show a progressive improvement of facial function: the recovery of facial movement starts at an average of five months and continues for up to 36 months after surgery.

Our study confirms that XII-VII anastomosis provides good reinnervation of the facial muscles (Yetiser and Karapinar, 2007). In accordance with other studies, we found better motor recovery in the lower hemiface than in the frontalis muscle (Magliulo et al., 2001; Chang and Shen, 1984; Pellat et al., 1997; Manni et al., 2001). This result can be attributed to the number of fibers contained in this branch of the seventh cranial nerve (Chang and Shen, 1984).

Many surgical series show a significant correlation between early surgery and outcome (Yetiser and Karapinar, 2007; Celis-Aguilar et al., 2013), although this aspect is still debated in the literature. Other authors identify age as a prognostic factor for outcome (Malik et al., 2005; May et al., 1991). Our study did not reveal either of these correlations, which may be due to the fact that our patients were operated on by different surgeons. All of our patients were sent to us by different centers, so there is also a potential recruitment bias linked to both the selection of patients with fewer signs of recovery and the geographical origins of the patients. Our study included patients who underwent XII-VII anastomosis using different surgical techniques as it has been reported that they give similar results (Lin et al., 2009).

Only one patient did not show signs of reinnervation after surgery. This may be due to an unrecognized injury to the hypoglossal donor nerve following the brain hemorrhage that damaged the sixth and seventh cranial nerves.

Numerous authors of surgical studies have pointed out that XII-VII anastomosis patients can benefit from a long-term rehabilitation program, yet without describing such programs (Magliulo et al., 2001; Pellat et al., 1997).

Chang and Shen (1984) showed that the proximity between the cortical area of the hypoglossal and facial nerves favors rehabilitation after surgery.

Table I. Correlations of the House-Brackmann score at 36 months.

Variable	Spearman R	(95%CI)	p-value
Months from paralysis to XII-VII	9.9%	-27.1-44.3	0.60
Months from XII-VII to I assessment	-8.7%	-46.6-31.9	0.68
Months from XII-VII to reinnervation	46.3%	10.1-71.7	0.015
Age (years)	14.6%	-22.6-48.1	0.44

The advantage of mirror visual feedback, the rehabilitation technique reported in our study, is that it does not require special equipment and can be performed at home, unlike the electromyographic biofeedback technique described by Brudny et al. (1988). Both these rehabilitation techniques have been demonstrated to produce equivalent results in patients with idiopathic and post-surgical long-term paralysis (Ross et al., 1991) and in patients with recent Bell's palsy (Dalla Toffola et al., 2012).

The use of home rather than hospital-based rehabilitation offered certain advantages: we were able both to increase the frequency of sessions and include in our study patients who lived further afield. The disadvantage is that it was difficult to quantify patient compliance with the rehabilitation.

Most of our patients, who underwent targeted rehabilitation, already had good facial symmetry at 18 months after surgery. Our study, confirming the findings of Cattli et al. (2010) and Wang et al. (2013) showed that some patients continue to improve for up to 36 months or more (data not shown) after surgery, thus prolongation of home exercise periods should be considered.

Our patients demonstrated good synkinesis control, which can be strongly influenced by the rehabilitation process, as suggested by Brudny et al. (1988) and Manni et al. (2001).

One of the aims of rehabilitation is to recover a spontaneous smile, however whether this is feasible is still a matter of debate. Patients who have undergone XII-VII anastomosis are not considered to be capable of regaining control of their emotive facial expressions, the smile in particular, since this control is regulated by the extrapyramidal system (Rinn et al., 2007). Our results support this assumption: none of the patients had recovered a spontaneous smile at three years after surgery, as reported elsewhere (Flores, 2007).

Our study used a long-term follow-up period to confirm that XII-VII anastomosis combined with targeted rehabilitation produces a good functional recovery (Brudny et al., 1988; Dalla Toffola et al., 1996).

The meta-analysis conducted by Yetiser and Karapinar (2007), based on data of 460 patients derived from 23 studies, reported a median improvement of two levels on the HB grading system in patients who underwent surgery alone.

Our study is the first to report results obtained by combining XII-VII anastomosis with a prolonged systematic rehabilitation program in a large clinical series. After receiving a combined surgical and rehabilitation treatment, 77% of our patients improved by more than two levels on the HB scale. This finding provides sufficient indirect evidence of the effectiveness of rehabilitation after XII-VII anastomosis. Larger randomized clinical trials should be considered in order to provide more conclusive evidence.

### Acknowledgments

This work was supported by Fondazione IRCCS Policlinico San Matteo, Pavia, Italy.

C.P. is partially supported by an investigator fellowship from Collegio Ghislieri, Pavia, Italy. We thank Charlotte Buckmaster for her linguistic expertise.

### References

- Bitter T, Sorger B, Hesselmann V, et al (2011). Cortical representation sites of mimic movements after facial nerve reconstruction: a functional magnetic resonance imaging study. *Laryngoscope* 121:699-706.
- Brudny J, Hammerschlag PE, Cohen NL, et al (1988). Electromyographic rehabilitation of facial function and introduction of a facial paralysis grading scale for hypoglossal-facial nerve anastomosis. *Laryngoscope* 98:405-410.
- Cattli T, Bayazit YA, Gokdogan O, et al (2010). Facial reanimation with end-to-end hypoglossofacial anastomosis: 20 years' experience. *J Laryngol Otol* 124:23-25.
- Celis-Aguilar E, Lassaletta L, Roda JM, et al (2013). End-to-side interposed donor grafting as a facial nerve reinforcement technique after vestibular schwannoma surgery. *Ann Otol Rhinol Laryngol* 122:520-523.
- Chang CG, Shen AL (1984). Hypoglossofacial anastomosis for facial palsy after resection of acoustic neuroma. *Surg Neurol* 21:282-286.
- Coulter JP, May M (2000). Enhancing facial appearance with cosmetic camouflage. In: May M, Schaitkin BM (Eds) *The Facial Nerve*. May's Second Edition. New York, Thieme, pp. 819-833.
- Dalla Toffola E, Petrucci L, Ricotti S, et al (1996). Rehabilitation of facial nerve palsy after surgery for acoustic neuroma. In: Sterkers JM, Charachon R, Sterkers O (Eds) *Acoustic Neuroma and Skull Base Surgery*. Amsterdam-New York, Kugler Publications, pp. 419-422.
- Dalla Toffola E, Petrucci L (2007). Approccio clinico e riabilitativo alla paralisi del VII nervo cranico. In: Valobra G, Gatto R, Monticone M (Eds) *Nuovo Trattato di Medicina Fisica e Riabilitazione*, Turin, Utet Editore, pp. 2211-2222.
- Dalla Toffola E, Furini F, Redaelli C, et al (2010). Evaluation and treatment of synkinesis with botulinum toxin following facial nerve palsy. *Disabil Rehabil* 32:1414-1418.
- Dalla Toffola E, Pavese C, Quarenghi A, et al (2011). La terapia occupazionale nella paralisi periferica del nervo facciale. In: Bazzini G, Franchignoni F, Imbriani M (Eds) *Argomenti di Terapia Occupazionale*. Vol. III., Rome, Aracne Editore, pp. 79-94.
- Dalla Toffola E, Tinelli C, Lozza A, et al (2012). Choosing the best rehabilitation treatment for Bell's palsy. *Eur J Phys Rehabil Med* 48: 635-642.
- Flores LP (2007). Surgical results of the hypoglossal-facial nerve jump graft technique. *Acta Neurochir (Wien)* 149:1205-1210.
- House JW, Brackmann DE (1985). Facial nerve grading system. *Otolaryngol Head Neck Surg* 93:146-147.
- Lin V, Jacobson M, Dorion J, et al (2009). Global assessment of outcomes after varying reinnervation techniques for patients with facial paralysis subsequent to acoustic neuroma excision. *Otol Neurotol* 30:408-413.
- Magliulo G, D'Amico R, Forino M (2001). Results and complications of facial reanimation following cerebellopontine angle surgery. *Eur Arch Otorhinolaryngol* 258:45-48.
- Malik TH, Kelly G, Ahmed A, et al (2005) Saeed SR, Ramsden RT. A comparison of surgical techniques used in dynamic reanimation of the paralyzed face. *Otol Neurotol* 26:284-291.
- Manni JJ, Beurskens CH, van de Velde C, et al (2001).

- Stokroos RJ. Reanimation of the paralyzed face by indirect hypoglossal-facial nerve anastomosis. *Am J Surg* 182:268-273.
- May M, Sobol SM, Mester SJ (1991). Hypoglossal-facial nerve interpositional-jump graft for facial reanimation without tongue atrophy. *Otolaryngol Head Neck Surg* 104:818-825.
- Ozsoy U, Hizay A, Demirel BM, et al (2011). The hypoglossal-facial nerve repair as Method to improve recovery of motor function after facial nerve injury. *Ann Anat* 193:304-313.
- Pellat JL, Bonnefille E, Zanaret M, et al (1997). Hypoglossal-facial anastomosis. A report of 60 cases. *Ann Chir Plast Esthet* 42:37-43.
- Rinn WE (2007). Emotional facial expression in Parkinson's disease: a response to Bowers (2006). *J Int Neuropsychol Soc* 13:721-722.
- Ross B, Nedzelski JM, McLean JA (1991). Efficacy of feedback training in long-standing facial nerve paresis. *Laryngoscope* 101:744-750.
- Sleilati FH, Nasr MW, Stephan HA, et al (2010). Treating facial nerve palsy by true termino-lateral hypoglossal-facial nerve anastomosis. *J Plast Reconstr Aesthet Surg* 63:1807-1812.
- Wang Z, Zhang Z, Huang Q, et al (2013). Long-term facial nerve function following facial reanimation after translabyrinthine vestibular schwannoma surgery: a comparison between sural grafting and VII-XII anastomosis. *Exp Ther Med* 6:101-104.
- Yetiser S, Karapinar U (2007). Hypoglossal-facial nerve anastomosis: a meta-analytic study. *Ann Otol Rhinol Laryngol* 116:542-549.