isoforms that have been associated with cellular resistance to ionizing radiation.[3]

We want to bring attention to some significant unsolved issues. Frequency of this new mutation in AML population is unknown at present, since all large studies where *NPM*1 mutations were determined only involved exon 12 amplification from genomic DNA or use of specific probes for known mutations precluding exon 11 region[4–7] (see references cited in Mrozek *et al.*[1]), which let in all cases this new truncation mutation go unnoticed. Even recommended immunohistochemical determinations[2] may have failed detecting this alteration, due to its mixed staining pattern. New analyses of the thousands of samples available in large leukaemia study groups would allow to obtain the frequency for this new type of *NPM*1 mutation, thus opening the possibility of redefining new subclasses of AML-NK based in these molecular findings. At this point, it is interesting to add that in their recent review[2] Falini *et al.* mentioned an abstract where the presence of an exon 11 mutation in an AML patient is described (Albiero *et al. Haematologica* 2006; **91**: 237, abstract). The reported mutation at exon 11 is the same kind of eight nucleotide insertion as the one we have found and reported here, but the inserted nucleotides are different in sequence, although both alterations produce a similar truncated protein. These data reinforce the possibility that a new hot spot for insertional mutation in *NPM*1 might have been located and strengthen the need for establishing the frequency of this type of mutation in AML patients as well as the biological consequences of this new finding.

Acknowledgements

We thank Drs C Suárez-Nieto, M Roza and A Román for support. This work was financed in part by a Grant from Fundación MMA-Investigación Médica. IS is a recipient of a research fellowship from Instituto Universitario de Oncologia. Instituto Universitario de Oncología is supported by Obra Social Cajastur-Asturias and Red de Centros de Cáncer-Instituto Carlos III-Spain

AS Pitiot[1], I Santamaría[1], O García-Suárez[2], I Centeno[1], A Astudillo[2,3], C Rayón[4] and M Balbín[1]

[1]*Laboratorio de Oncología Molecular, Hospital Universitario Central de Asturias & Instituto Universitario de Oncología del Principado de Asturias, Oviedo, Spain;*
[2]*Laboratorio de Apoyo a la Investigación del Banco de Tumores, Instituto Universitario de Oncología del Principado de Asturias, Oviedo, Spain;*
[3]*Servicio de Anatomía Patológica, Hospital Universitario Central de Asturias, Oviedo, Spain and*
[4]*Servicio de Hematología, Hospital Universitario Central de Asturias, Oviedo, Spain*
E-mail: mbalbin@hca.es

References

1 Mrózek K, Marcucci G, Paschka P, Whitman SP, Bloomfield CD. Clinical relevance of mutations and gene-expression changes in adult acute myeloid leukaemia with normal cytogenetics: are we ready for a prognostically prioritized classification? *Blood* 2007; **109**: 431–448.
2 Falini B, Nicoletti I, Martelli MF, Mecucci C. Acute myeloid leukemia carrying cytoplasmic/mutated nucleophosmin: biologic and clinical features. *Blood* 2007; **109**: 874–885.
3 Dalenc F, Drouet J, Ader I, Delmas C, Rochaix P, Favre G *et al.* Increased expression of a COOH-truncated nucleophosmin resulting from alternative splicing is associated with cellular resistance to ionizing radiation in HeLa cells. *Int J Cancer* 2002; **100**: 662–668.
4 Suzuki T, Kiyoi H, Ozeki K, Tomita A, Yamaji S, Suzuki R *et al.* Clinical characteristics and prognostic implications of NPM1 mutations in acute myeloid leukaemia. *Blood* 2005; **106**: 2854–2861.
5 Schnittger S, Schoch C, Kern W, Mecucci C, Tschulik C, Martelli MF *et al.* Nucleophosmin gene mutations are predictors of favourable prognosis in acute myelogenous leukaemia with a normal karyotype. *Blood* 2005; **106**: 3733–3739.
6 Döhner K, Schlenk RF, Habdank M, Scholl C, Rüker FG, Corbacioglu A *et al.* Mutant nucleophosmin predicts favourable prognosis in younger adults with acute myeloid leukaemia and normal cytogenetics: interaction with other gene mutations. *Blood* 2005; **106**: 3740–3746.
7 Thiede C, Koch S, Creutzig E, Steudel C, Illmer T, Schaich M *et al.* Prevalence and prognostic impact of NPM1 mutations in 1485 adult patients with acute myeloid leukaemia (AML). *Blood* 2006; **107**: 4011–4020.

Cytoplasmic mutated nucleophosmin (NPM) defines the molecular status of a significant fraction of myeloid sarcomas

Leukemia (2007) **21,** 1566–1570; doi:10.1038/sj.leu.2404699; published online 19 April 2007

Detection of genetic lesions is critical for classification, prognostic stratification and monitoring of minimal residual disease of acute myeloid leukaemia (AML). Information on genetic lesions associated with myeloid sarcoma (MS), a tumor mass consisting of myeloblasts or immature myeloid cells at an extramedullary site,[1] is still limited.[2] This is mainly due to the fact that fresh cells are usually not available for cytogenetic and/or molecular studies. In fact, the diagnosis of MS is frequently unexpected and/or the size of the sample is small, such as a skin punch biopsy. Since MS is usually treated in the same way as AML, the frequent lack of available cytogenetics in MS represents a significant disadvantage, and the availability of techniques applicable to paraffin samples to detect specific genetic lesions would be of great help both for diagnostic and prognostic purposes.

Nucleophosmin (NPM) 1 mutations with consequent aberrant cytoplasmic expression of NPM[3,4] represent the most common genetic abnormality in AML, but no information is available on the role of NPM in MS. Since immunohistochemical detection of cytoplasmic NPM in AML predicts *NPM1* mutations,[5] we used anti-NPM antibodies[4] to detect cytoplasmic/mutated NPM in 181 paraffin-embedded MS samples (characteristics of these cases are provided in the Supplementary Information). Immunohistochemical results were confirmed in a subset of cases by a PCR assay that we developed for application on formalin-fixed samples. We found 26 NPMc+ MS, whose biological and clinical features are reported here.

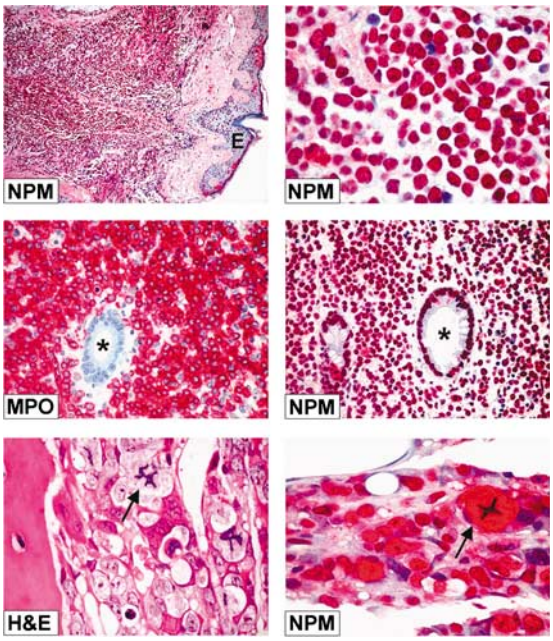

Figure 1 NPMc− myeloid sarcomas. (Top panels) MS of the skin showing nucleus-restricted NPM (mAb 376). E indicates epidermis. APAAP technique; hematoxylin conterstaining. (Middle panels) MS of the intestine. Leukaemic cells are myeloperoxidase-positive (MPO, left) and show nucleus-restricted positivity for NPM (mAb 376) (right). Asterisks indicate the lumen of residual glands. APAAP technique; hematoxylin conterstaining. (Bottom panels) MS of the bone. Leukaemic cells with monoblastic appearance (left, hematoxylin–eosin); mitoses (arrow) are numerous. Leukaemic cells show nucleus-restricted expression of NPM (mAb 376) (right); the arrow indicates the expected NPM cytoplasmic positivity of a mitotic figure. APAAP technique; hematoxylin counterstaining.

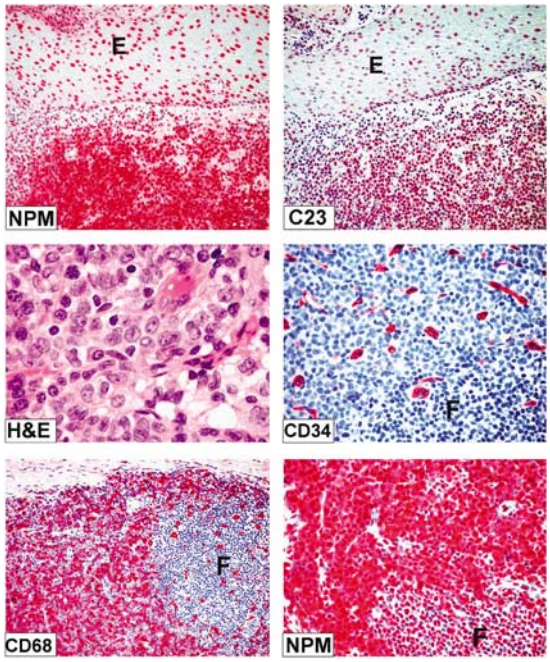

Figure 2 NPMc+ myeloid sarcomas. (Top panels) MS of the skin. Leukaemic cells show cytoplasmic (and nuclear) positivity for NPM (mAb 376) (left); while cells of epidermis (E) exhibit nucleus-restricted expression of NPM (mAb 376) (left). Leukaemic cells show the expected nucleus-restricted positivity for C23/nucleolin (right); the same staining pattern is observed in the cells of epidermis (E) (right). APAAP technique; hematoxylin counterstaining. (Middle and bottom panels) MS of the lymph node. Leukaemic cells show a monoblastic appearance (middle left, hematoxylin–eosin) and are CD34−negative (middle right); positive vessels serve as positive internal control for CD34; F indicates a residual lymphoid follicle. Leukaemic cells are CD68−positive (mAb PG-M1) while B cells of a residual follicle (F) are negative (with the exception of scattered macrophages) (bottom left). Leukaemic cells show cytoplasmic (and nuclear) NPM positivity (bottom right); cells of the residual follicle (F) show the expected nucleus-restricted NPM expression (bottom right). APAAP technique; hematoxylin conterstaining.

The 181 MS samples were first immunostained with the monoclonal antibody (mAb) 376 (recognizing both wild-type and mutated NPM proteins) (Supplementary Information). Immunostaining results were evaluable in 173/181 MS cases; in eight cases, they were difficult to interpret because of the small size of tissue samples, shrinkage artefacts and/or antigenic denaturation of the NPM protein. In 147/173 cases (85.0%), NPM showed a nucleus-restricted expression that was identical to nucleolin (C23) (Figure 1). This staining pattern is known to predict absence of *NPM1* mutations, as reported previously in AML.[5] In 26/173 cases (15.0%), aberrant cytoplasmic NPM expression was detected (Figure 2; Table 1), a staining pattern that is known to predict *NPM1* mutations.[5] The leukaemic cells from these cases also showed nuclear NPM positivity (Figure 2), due to the residual NPM wild-type protein in the nucleus.[4] All NPMc+ MS cases showed the expected nucleolin/C23 nucleus-restricted positivity (Figure 2).

NPM1 mutations are consistently heterozygous;[3,4] therefore, leukaemic cells contain both wild-type and mutated NPM proteins. Anti-NPM mAb 376 cannot discriminate between these two types of proteins.[4] To confirm that in MS samples, cytoplasmic NPM dislocation is the consequence of *NPM1* mutations, we stained paraffin sections by the alkaline phosphatase anti-alkaline phosphatase (APAAP) technique using polyclonal antibodies (Sil-A and Sil-C) that specifically recognize NPM mutant proteins (Supplementary Information). Immunostaining was performed on 18/26 NPMc+ MS samples for which a sufficient amount of paraffin-embedded material was available for analysis. Antigenicity of NPM mutant proteins was preserved in 14/18 immunostained cases. Paraffin sections from 15 NPM cytoplasmic-negative (NPMc−) MS specimens served as negative controls. In the 14 NPMc+ MS samples, where antigenicity was preserved, expression of NPM mutant protein was consistently cytoplasmic-restricted (Figure 3). This is in keeping with previous findings in NPMc+ AML,[4] and with the observation that, in transfected cells, NPM mutant constructs localize exclusively in the cytoplasm.[4] With one exception, none of the NPMc− MS reacted with Sil-A and Sil-C. The discrepant case was included in the subset of cases, which were subjected to PCR sequence analysis (see below).

To confirm further that subcellular NPM immunostaining pattern in MS samples predicts *NPM1* gene mutations, a PCR assay was designed that is suitable for application on RNA extracted from formalin-fixed paraffin-embedded samples (FFPE) (technical details are given in the Supplementary Information). We selected 16 MS samples for the analysis (7 NPMc+, 9 NPMc−). An evaluable PCR product was obtained in 12/16 cases investigated (5 NPMc+, 7 NPMc−) (Table 2). In 11/12 of these cases (5 NPMc+, 6 NPMc−) the aberrant cytoplasmic localization of NPM correlated with the presence or absence of *NPM1* mutations (Table 2); in one case (case 6) the result was

Table 1 Clinicopathological features of 26 NPMc+ myeloid sarcomas

No.	ID no.	Age/sex	Site	FAB	BM involvement	CD34 (%)	Therapy	Cytog./FISH	Outcome	Survival (Months)
1	H4796-04	47/F	Cervix	M4	No	0	NA	NA	Dead	4
2	H4769-99	79/M	Skin	M4/M5	No	0	NA	NA	Dead	2
3	H1636-99	69/M	Liver	M5	No	0	NA	NA	Dead	41
4	H4794-91	49/M	Paraspinal	M1	No	0	Ara-c	NA	Dead	26
5	H9240-96	79/F	Skin	M5	No	0	Chemo.	NA	Dead	8
6	H1475-95	76/F	Stomach	M5	No	0	Chemo.	NA	Dead	4
7	H4495-05	53/M	Gluteus	M4	No	30	NA	NA	Dead	1
8	H8266-97	86/F	Vulva	M4	No	0	Chemo.	NA	Dead	8
9	E2110/02	48/M	Testicle	M5a	No	0	NA	NA	Dead	12
10	H12213-99	79/M	Soft tissue	M2	Yes (subsequent)	0	Radiation	NA	Dead	1
11	H4386-94	53/M	Stomach	M5	Yes (subsequent)	0	NA	NA	Dead	11
12	H7901-04	70/F	Skin	NA	Yes (subsequent)	0	Chemo.	NA	Dead	7
13	S98-98	59/M	Liver, LN, Soft tissue	M5	Yes (subsequent)	0	Ara-c, Dauno.	NA	Dead	11
14	S231-95	86/M	Lung	NA	Yes (subsequent)	0	Chemo.	NA	Dead	3
15	E384/02	55/F	LN	M5	Yes (concurrent)	0		Trisomy 8[a]	Dead	NA
16	E4962/02	80/F	Skin	M5b	Yes (concurrent)	0	HU + PDS	46XX	Dead	5
17	E1446/04	46/F	Gums	M5	Yes (concurrent)	0	Chemo.	NA	Dead	8
18	O1	63/F	LN	M5	Yes (concurrent)	0	Chemo.	46XX	Alive	96
19	Q1	11/M	Eye	NA	Yes (concurrent)	54	Chemo.	46XX	Alive	72
20	PG-1	75/M	LN	M5	Yes (concurrent)	0	Chemo.	46XY		
21	E6420/02	78/M	Skin	NA	Yes (preceding)	0	Ara-c + TG	NA	Dead	4
22	E1	47/M	Common bile duct	NA	Yes (preceding)	NA	NA	NA	Dead	19
23	T1	76/F	Gums	M1	Yes (preceding)	NA	Chemo.	NA	Dead	10
24	PG-2	53/F	Skin	M5b	Yes (preceding)	0	Chemo./Allo.	46xx	Dead	24
25	PG-3	24/F	Skin	M4	Yes (preceding)[b]	0	Chemo.	46xx	Alive	10
26	H11038-89	77/F	Cervix	M2	NA	0	NA	n.a.	Dead	3

Abbreviations: Allo, allogeneic peripheral stem cell transplantation; Ara-c, cytosine-arabinoside; Chemo, chemotherapy; Dauno, daunorubicine; HU, hydroxyurea; LN, lymph node; NA, not available; PDS, prednisone; TG, thioguanine; VBS, vinblastine.
[a]Detected by FISH on lymph node cells.
[b]Skin involvement 20 years after the initial diagnosis of AML.[7] None of the cases was preceded by a chronic myeloproliferative disorder or myelodisplastic syndrome.

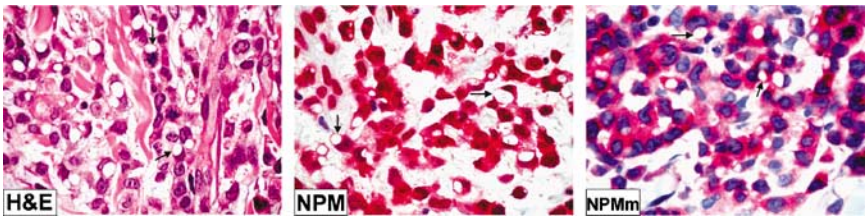

Figure 3 Labelling of mutated NPM in myeloid sarcoma. (Left) MS of soft tissue. Leukaemic cells are large and vacuolated (hematoxylin–eosin). (Middle) mAb 376 (recognizing wild-type and mutated NPM) labels both the nucleus and cytoplasm of leukaemic cells. (Right) Expression of the mutated NPM protein (NPMm) recognized by the Sil-C antibody is cytoplasmic-restricted. The arrows in all figures indicate leukaemic cells with a 'signet ring' appearance. APAAP technique; hematoxylin counterstaining.

discrepant. This case scored nuclear (NPMc−) with clone 376 but cytoplasmic with Sil-A and Sil-C antibodies (Table 2). The PCR assay revealed a mutated sequence, indicating that the immunostaining for mutated NPM predicted the mutations correctly (Table 2). Possibly, in this particular case, the epitope recognized by mAb 376 on wild-type NPM was better preserved than that recognized by sil-A and sil-C in mutated NPM, thus explaining the nucleus-restricted positivity that in NPMc + AML is mostly accounted by the residual wild-type NPM.[4] Comparison of the mutated sequences found in this study to published data, showed that five cases harbored the *NPM1* type A allele[3] and one case contained the Km allele.[6]

The clinicopathological and cytogenetic features of the 26 NPMc + MS are shown in Table 1. The male/female ratio was 1.00, similar to the NPMc− cases (1.03). Mean age of patients was 62.2 years (range 11–86) not significantly different from NPMc− cases (mean age 55.6 years, range 11–86). The most frequently involved sites were skin and lymph nodes; other extramedullary sites were involved less frequently (Table 1). In 24 patients, the tumor was localized; one patient (Table 1, case 25) showed multiple skin involvement, and one patient (Table 1, case 13) showed involvement of multiple sites (liver, lymph node and soft tissue). Fourteen patients (Table 1, cases 1–14) presented with *de novo* NPMc + MS and in 5/14 (Table 1, cases 10–14) bone marrow involvement was documented within 6 months after the diagnosis of MS. In six patients (Table 1, cases 15–20), MS and AML were concurrent. In five patients, MS was subsequent to diagnosis of AML (Table 1, cases 21–25) and in one of them (Table 1, case 25), which was reported previously,[7] skin involvement occurred 20 years after initial AML diagnosis. No data on bone marrow status were available in case 26. There was no history of a chronic myeloproliferative disorder or a myelodisplastic syndrome in any case.

Classification according to FAB was possible in 21/26 cases, and 17/21 (80.9%) were of myelo-monocytic or monocytic origin (M4 $n=4$; M5 $n=12$; M4 vs M5 $n=1$) (Table 1). M4

Table 2 *NPM1* gene sequencing results in comparison with immunohistochemical stainings[a]

Case	*ID no.*	*Anti-NPM*[b]	*Sil-A or Sil-C*[c]	*NPM1 gene sequence*
1	H4796/04	NPMc+	Positive	Type A[d]
2	H1475/95	NPMc+	Positive	Type A
3	H12213/99	NPMc+	Positive	Type A
4	H7901/04	NPMc+	Positive	Type Km[e]
5	H11038/89	NPMc+	Positive	Type A
6	H16916/03	NPMc−	Positive	Type A
7	H15647/00	NPMc−	Negative	Wild-type
8	H2250/03	NPMc−	Negative	Wild-type
9	H15319/96	NPMc−	Negative	Wild-type
10	H8848/98	NPMc−	Negative	Wild-type
11	H17905/98	NPMc−	Negative	Wild-type
12	H20049/90	NPMc−	Negative	Wild-type

[a]Carried out in FFPE sections.
[b]Monoclonal antibody 376 reacts with both the mutant and wild-type NPM.
[c]Polyclonal antibodies that specifically recognize NPM mutants.
[d]See Falini *et al.*[3]
[e]See Schnittger *et al.*[6]

cases were characterized by expression of myeloperoxidase and macrophage-restricted CD68 (PG-M1); M5 cases were positive only for macrophage-restricted CD68. The other 4/21 cases showed M1 ($n=2$) or M2 ($n=2$) morphology. These cases showed positivity for myeloperoxidase (range 20–100% of blast cells), in the absence of macrophage-restricted CD68. CD34 expression could be assessed in 24 cases; 22/24 (91.7%) were CD34− negative. Cytogenetics and/or FISH were available only in seven patients; six exhibited a normal karyotype and one showed trisomy 8. Only 3/26 patients are alive (follow-up of 10, 72 and 96 months).

Clinical and pathological data were available in 126 out of the 147 NPMc− MS samples (Supplementary Table). The NPMc− and NPMc+ MS cases clearly differed in respect to a previous chronic myeloproliferative disorder or a myelodysplastic syndrome (39.6% in NPMc− vs 0% in NPMc+, 0.001) and the frequency of cases showing CD34 positivity (12% in NPMc− vs 47.85% in NPMc+, $P<0.001$). Moreover, NPMc− MS cases showed a higher frequency of cytogenetic abnormalities, as only 4/21 patients (19%) for whom cytogenetics was available had normal karyotype, vs 6/7 NPMc+ cases (85.7%) ($P<0.001$). The 17 NPMc− MS cases with an abnormal karyotype (81%) showed the following cytogenetic abnormalities: *t*(8;21)(q22;q22) ($n=3$); *t*(9;22)(q34;q11.2) ($n=3$ chronic myeloid leukaemia in transformation); *t*(15;17)(q22;q21) ($n=1$); 47,XX,+5, *t*(8;21)(q22;q22) ($n=1$); 47XY,?+2, *t*(6;11),−12,?+21($n=1$); 47,XX,+8 ($n=1$); 47,XX,+8, *t*(9;22)(q34;q11.2)14/*t*(9;22)(q34;q11.2)4 ($n=1$ chronic myeloid leukaemia in transformation); 47,XX, *t*(2;5)(q35;q22),+8 ($n=1$); 46XX/46,XX, *t*(11;11)(p15;q22) (information on the number of mitosis analyzed is not available) ($n=1$); and complex karyotype ($n=4$). According to the method of Kaplan–Meier, the probability of the overall survival of the NPMc− MS cases was 0.089 at 2 years, not statistically different from the overall survival of the NPMc+ patients (median survival time 8 and 9 months respectively).

In this study, we used immunohistochemistry to search for aberrant cytoplasmic NPM expression in 181 MS samples and detected it in 15% of them. Immunohistochemistry can serve as a surrogate for molecular studies for detecting *NPM1* mutations in MS in most instances. In the few remaining cases, where interpretation of immunohistochemistry is difficult because of shrinkage artefacts and/or poor antigen preservation, the mutational status of *NPM1* gene can be assessed by PCR from the same biopsies. Thus, the combination of the two methods allows to overcome the lack of fresh material for diagnosis of MS.

Notably, our results identify *NPM1* mutations as the most frequent molecular lesion so far reported in MS, defining the molecular status in 15% of cases. NPMc+ MS showed the same distinctive features as *de novo* NPMc+ AML,[3] that is, frequent association with M4 and M5 FAB categories, lack of CD34 expression and association with normal karyotype. The presence of trisomy 8 in one case concurs with previous observations that about 14% of NPMc+ AML carry minor chromosomal abnormalities, which are probably secondary events.[3,4] As in NPMc− AML,[3] all MS cases carrying major genetic abnormalities, including *t*(8;21), MLL rearrangement, *t*(15;17) and complex karyotypes showed nucleus-restricted NPM expression, indicating the absence of *NPM1* mutations. Nucleus-restricted NPM expression was also observed in all 24 MS cases, arising in a setting of myelodysplasia or a chronic myeloproliferative disorder, consistent with the finding that NPMc+ AML is usually a *de novo* leukaemia.[3] Our findings that NPMc+ MS progressing to AML as well as NPMc+ AML relapsing as MS maintained, in these different stages of the disease, the aberrant cytoplasmic expression of NPM is in keeping with the previous reported stability of *NPM1* mutations.[8]

In AML, *NPM1* mutations in the absence of FLT3-ITD identify a subgroup of patients with favorable prognosis.[4,6] In contrast, only 3/26 of NPMc+ MS patients are still alive. Several reasons may underlie this discrepancy. Because of lack of fresh material, information on *FLT3* status is lacking in our patients. Advanced age is a known poor prognostic factor in AML; 15/26 patients with NPMc+ MS were older than 60 years. Treatment of patients in this series was very heterogeneous. Moreover, due to advanced age and delay in diagnosis, many patients underwent only radiotherapy or chemotherapy with one or two cytotoxic drugs.

Our results have important clinico-diagnostic implications. Morphologically, MS may be misdiagnosed as lymphoblastic or diffuse large-cell lymphoma or non-haematopoietic tumor. Immunophenotyping is mandatory for diagnosis[1] and the diagnostic panel usually include antibodies against myeloperoxidase, CD68, CD117, CD79a, CD3, glycophorin-A, CD61 and CD34. Our results clearly indicate that anti-NPM antibodies

should be added to this panel as they predict *NPM1* mutations. Our data also provide a rationale for a genetic-oriented classification of MS in the upcoming version of WHO classification.[1] Future efforts should integrate data on *NPM1* and *FLT3-ITD* status, to determine in prospective studies whether MS carrying mutated NPM in the absence of *FLT3-ITD* also constitutes a more favorable prognostic category, as has been reported for *de novo* NPMc+ AML.[4,6]

Acknowledgements

Supported by the Associazione Italiana per la Ricerca sul Cancro (A.I.R.C.), BolognAIL, and Deutsche Krebshilfe (70-3173-Tr3). NB is a recipient of a fellowship from FIRC (Federazione Italiana per la Ricerca sul Cancro). We thank Dr Geraldine Boyd for editing the manuscript, Nicole Lange, Barbara Bigerna, Alessandra Pucciarini and Roberta Pacini for the excellent technical support, and Mrs Claudia Tibidò for secretarial assistance. Brunangelo Falini applied for a patent on the clinical use of NPM mutants.

B Falini[1], D Lenze[2], R Hasserjian[3], S Coupland[2], D Jaehne[2], C Soupir[3], A Liso[4], MP Martelli[5], N Bolli[1], F Bacci[6], V Pettirossi[1], A Santucci[1], MF Martelli[1], S Pileri[6] and H Stein[2]
[1]*Section of Haematology and Immunology, University of Perugia, IBiT Foundation, Fondazione IRCCS Biotecnologie nel Trapianto, Perugia, Italy;*
[2]*Campus Benjamin Franklin, Charitè-Universitatsmedizin, Berlin, Germany;*
[3]*Department of Pathology, Massachusetts General Hospital, Boston, USA;*
[4]*Institute of Haematology, University of Foggia, Foggia, Italy;*
[5]*Institute of Haematology, University of Bari, Bari, Italy;*
[6]*Istitute of Haematology and Clinical Oncology 'L. and A. Seragnoli' and Unit of Haematopathology, Policlinico S. Orsola, University of Bologna, Bologna, Italy*
E-mail: faliniem@unipg.it

References

1 Brunning RD, Matutes E, Flandrin G, Vardiman J, Bennet J, Head D *et al.* Acute myeloid leukaemia not otherwise categorised. In: Jaffe E, Harris N, Stein H, Vardiman J (eds). *Pathology and Genetics of Tumours of Haematopoietic and Lymphoid Tissues.* IARC Press: Lyon, France, 2001, pp 104–105.
2 Pileri SA, Ascani S, Cox MC, Campidelli C, Bacci F, Piccioli M *et al.* Myeloid sarcoma: clinico-pathologic, phenotypic and cytogenetic analysis of 92 adult patients. *Leukemia* 2007; **21**: 340–350.
3 Falini B, Mecucci C, Tiacci E, Alcalay M, Rosati R, Pasqualucci L *et al.* Cytoplasmic nucleophosmin in acute myelogenous leukemia with a normal karyotype. *N Engl J Med* 2005; **352**: 254–266.
4 Falini B, Nicoletti I, Martelli MF, Mecucci C. Acute myeloid leukemia carrying cytoplasmic/mutated nucleophosmin (NPMc+ AML): biologic and clinical features. *Blood* 2007; **109**: 874–885.
5 Falini B, Martelli MP, Bolli N, Bonasso R, Ghia E, Pallotta MT *et al.* Immunohistochemistry predicts nucleophosmin (NPM) mutations in acute myeloid leukemia. *Blood* 2006; **108**: 1999–2005.
6 Schnittger S, Schoch C, Kern W, Mecucci C, Tschulik C, Martelli MF *et al.* Nucleophosmin gene mutations are predictors of favorable prognosis in acute myelogenous leukemia with a normal karyotype. *Blood* 2005; **106**: 3733–3739.
7 Bolli N, Galimberti S, Martelli MP, Tabarrini A, Roti G, Mecucci C *et al.* Cytoplasmic nucleophosmin in myeloid sarcoma occurring 20 years after diagnosis of acute myeloid leukaemia. *Lancet Oncol* 2006; **7**: 350–352.
8 Chou WC, Tang JL, Lin LI, Yao M, Tsay W, Chen CY *et al.* Nucleophosmin mutations in *de novo* acute myeloid leukemia: the age-dependent incidences and the stability during disease evolution. *Cancer Res* 2006; **66**: 3310–3316.

Supplementary Information accompanies the paper on the Leukemia website (http://www.nature.com/leu)

Thrombosis can occur at any phase of essential thrombocythemia with JAK2^{V617F} mutation: a single institutional study in Japan

Leukemia (2007) **21,** 1570–1571; doi:10.1038/sj.leu.2404666; published online 29 March 2007

The JAK2^{V617F} mutation is an activating kinase that is constitutively expressed in the vast majority of patients with polycythemia vera and approximately half of those with essential thrombocythemia (ET).[1] The significance of the association between JAK2^{V617F} mutation in ET and thrombosis is still controversial: we have shown that ET patients with JAK2^{V617F} had more frequent thrombotic episodes compared with those with wild-type JAK2, whereas the platelet count at the initial ET diagnosis did not differ between wild-type ET and JAK2^{V617F}-positive ET.[2] On the basis of this evidence, we retrospectively sought and evaluated thrombotic episodes in ET patients to obtain more insight into the risk factors of thrombosis in ET patients.

We used the JAK2 mutational status database in 49 patients with ET in our institute. The JAK2^{V617F} mutation was determined using by the semiquantitative sequence-specific primer single-molecule fluorescence detection (SSP-SMPD) assay. As reported previously, ET patients with JAK2^{V617F} showed a significantly higher incidence of thrombotic episodes (10/31 versus 1/18: $P=0.0308$), high leukocyte count ($P=0.0092$) and hemoglobin level ($P=0.0044$) than those with wild-type JAK2.[2] ET patients with thrombosis had higher hemoglobin (14.5 ± 1.5 versus 13.3 ± 1.5 g/dl: $P=0.0283$) at initial diagnosis, whereas no significant differences were noted in leukocyte count ($P=0.140$), hematocrit level ($P=0.0801$) or platelet count ($P=0.0877$) (Supplementary Information 1). Of the ET patients with JAK2^{V617F} mutation ($n=31$), no significant differences were noted in hematologic parameters regardless of whether they developed thrombosis or not.

In ET patients followed for at least 1 year, we found 11 patients who suffered thrombosis (Table 1): two patients at intermediate risk, and nine at high risk, according to the thrombotic risk.[3] Six ET cases were initially diagnosed by thrombosis, and the remaining five had thrombotic events during stable phase of the disease. Hematologic parameters at the time of initial ET diagnosis in these two groups did not significantly differ, including leukocyte count ($P=0.2703$), hemoglobin concentration ($P=0.1306$), hematocrit level ($P=0.4472$) or platelet count ($P=0.9662$). Except for one patient (JAK2_0050),