



Computed tomographic appearance of canine tonsillar neoplasia: 14 cases

Florence Thierry¹  | Maurizio Longo¹ | Evi Pecceu¹ | Davide D. Zani² | Tobias Schwarz¹ 

¹Royal (Dick) School of Veterinary Studies, Roslin Institute, University of Edinburgh, Roslin, EH25 9RG, UK

²Department of Veterinary Medicine, University of Milan, Via dell'Università, Lodi, 26900, Italy

Correspondence

Tobias Schwarz, Royal (Dick) School of Veterinary Studies, Roslin Institute, University of Edinburgh, Roslin EH25 9RG, UK.
Email: tobias.schwarz@ed.ac.uk

Abstract

The palatine tonsil is an uncommon site of oral canine neoplasia. For affected tonsils, squamous cell carcinoma is the most frequent type of neoplasia, followed by melanoma and lymphoma. Computed tomography (CT) is increasingly used for investigation of canine oropharyngeal pathology; however, limited information is available on the CT appearance of tonsillar neoplasms. Objectives of this retrospective descriptive case series were to characterize the CT features of canine tonsillar neoplasia and determine whether specific CT features differentiate nonneoplastic from neoplastic tonsils. Computed tomographic studies of 14 dogs diagnosed with tonsillar neoplasia were retrieved from two referral hospitals and reviewed by two observers. Diagnosis was based on histology or cytology. Carcinoma was diagnosed in 11 dogs, melanoma in two and lymphoma in one dog. Specific CT features of the tonsil and regional lymph nodes did not differentiate neoplastic from nonneoplastic tonsillar diseases, but regional lymph node CT features were useful for diagnosis in some cases. Marked enlargement (width \geq 18 mm, 12/18), heterogeneity (16/18), and loss of the hypoattenuating hilus (18/18) of the medial retropharyngeal lymph node were common concomitant features of tonsillar neoplasia. The medial retropharyngeal and mandibular lymphadenomegaly was ipsilateral to the neoplastic tonsil in 8/12 and 6/9 dogs, respectively. Five dogs demonstrated little or no enlargement of the tonsil despite the associated metastatic lymphadenomegaly. Tonsillar neoplasia should therefore be considered as a differential diagnosis for dogs with CT evidence of isolated medial retropharyngeal lymphadenomegaly (regardless of normally sized tonsils), or of any enlarged tonsil with no associated lymphadenomegaly.

KEYWORDS

CT, lymphoma, melanoma, squamous cell carcinoma, tonsil

1 | INTRODUCTION

The palatine tonsil is recessed within the tonsillar fossa and is an uncommon site of oropharyngeal neoplasia in the dog.^{1–4} Carcinoma is the most frequent tumor type and is associated with a guarded prognosis.^{4–8} Varying values of prevalence of canine tonsillar squamous cell carcinoma have been reported, most recently it has been described to represent 9% of canine oral tumors.^{4–8} Oral examination combined with tonsillar cytology or biopsy is often the initial step in the diagnosis of tonsillar neoplasia in the dog, which in many cases is sufficient for diagnosis without further imaging.^{4–6} For oncological staging and treatment planning of tonsillar neoplasia, computed tomography (CT) is increasingly being applied. In addition, CT is

commonly utilized in the first line of investigation for a large number of patients with suspected oropharyngeal or cranial neck masses of unknown origin. Scarce information is available on the CT appearance of palatine tonsillar neoplasia in the dog.

The pharyngeal walls contain a ring of lymphoreticular tissue acting as an immunological barrier for the respiratory and alimentary systems.¹ Tonsils are aggregates of multiple lymph nodes surrounded by a common capsule.¹ The dog has small, diffuse, unpaired lingual and pharyngeal tonsils and distinct, paired palatine tonsils.² The palatine tonsil (*tonsilla palatina*) has a fusiform protruding portion 25 mm in length, 5 mm in width, and 4 mm thickness in the normal adult dog located in the lateral oropharyngeal wall.^{2,3} There is a smaller deeper portion that lies under the mucosa forming the lateral wall of the fossa

This is an open access article under the terms of the Creative Commons Attribution-NonCommercial-NoDerivs License, which permits use and distribution in any medium, provided the original work is properly cited, the use is non-commercial and no modifications or adaptations are made.

© 2017 The Authors. *Veterinary Radiology & Ultrasound* published by Wiley Periodicals, Inc. on behalf of American College of Veterinary Radiology

that is usually only formed in pathologic conditions.³ Tonsillar enlargement can occur as a normal immune reaction to infectious stimuli, or as a primary or metastatic neoplasia.^{4,9,10}

The objectives of this study were to describe CT features of palatine tonsillar neoplasia in a group of dogs with confirmed disease and to determine whether specific CT features differentiate nonneoplastic from neoplastic tonsils. We hypothesized that CT characteristics of the canine palatine tonsil and regional lymph nodes would allow differentiation of neoplastic from nonneoplastic tonsillar diseases.

2 | METHODS

The study design was a retrospective descriptive case series. Data from dogs diagnosed with tonsillar neoplasia were retrieved from the databases of the referral hospitals of the University of Edinburgh and the University of Milan. Diagnosis was based on tonsillar biopsy, or if not available, on fine-needle aspiration of the tonsil. Inclusion criteria for participation in the study consisted of an available CT study of diagnostic quality of the head and neck before and within 5 min after manual intravenous contrast medium injection (740 milligrams iodine/kilogram) prior to biopsy or treatment, complete patient signalment data and cytological or histological diagnosis. Decisions for study inclusion were made by a diagnostic imaging resident (F.T.). Age, sex, clinical signs, cytological, and histological results of the tonsils and metastatic lesions were unblindly recorded by the same observer. Open or closed-mouth status during CT examination was noted.

All CT studies were randomized and reviewed by a board-certified veterinary radiologist (T.S.) who was unaware of the clinical findings, tumour type, and location. All assessments and measurements were performed using dedicated DICOM viewer software (OsiriX v5.8.5 64-bit, Geneva, Switzerland). A window width of 200 Hounsfield units (HU) and a window level of 50 HU were used. Thoracic CT images were reconstructed with a high frequency algorithm and were also reviewed when available.

The tonsillar appearance (homogeneity, heterogeneity, enhancement) before and after intravenous contrast medium injection was documented. The largest linear dimension of each tonsil was measured in a transverse plane on postcontrast images. The CT appearance of neoplastic tonsils was compared to the CT appearance of confirmed nonneoplastic tonsils on histology. The largest width and appearance of each medial retropharyngeal, mandibular, deep, and superficial lymph nodes were also recorded. The attenuation pattern (homogeneous or heterogeneous), presence of a postcontrast rim enhancement, and loss of the hypoattenuating hilus were documented for each lymph node. The size of the lymph nodes was qualitatively scored as normal or abnormally enlarged. This assessment was based on nodal width and asymmetry. Regions of interest were drawn on each tonsil, and each mandibular and medial retropharyngeal lymph node before and after intravenous contrast medium injection. Computed tomographic attenuation values in Hounsfield units and standard deviation of mean density were recorded.

Statistical analyses were performed by one author (F.T.) using a commercial software (SPSS 20 software for Macintosh, SPSS Inc.). In

order to take into account the breed effect on tonsillar size, dogs were categorized into small, medium, and large breed dogs. The difference in size between neoplastic tonsils and nonneoplastic tonsils was assessed with a Mann-Whitney U test. The critical significance level for statistical tests was set at 0.05.

3 | RESULTS

3.1 | Signalment and clinical findings

Fourteen dogs met the inclusion criteria: nine cases from the referral hospital of the University of Edinburgh over an 8-year period and five cases from the referral hospital of the University of Milan over a 4-year period. The median age for included dogs was 10.5 years ($N = 14$, range: 6–14). Canine breeds included Collie cross (4/14), Cavalier King Charles spaniel (1/14), springer spaniel (2/14), Labrador (1/14), West Highland white terrier (1/14), Maltese (1/14), Schnauzer (1/14), Czechoslovakian wolfdog (1/14), and cross breed dogs (2/14). There were seven females (two entire and five neutered) and seven males (two entire and five neutered). Dysphagia was the most common clinical sign reported (7/14). Lethargy (5/14) and hypersalivation (5/14) were also common clinical features, with halitosis only reported in two cases. The median duration of clinical signs was 4 weeks ($N = 13$, range: 1–16). Twenty tonsils were sampled, among which 17 were diagnosed neoplastic (10 by histology and 7 by cytology). Three tonsils were confirmed nonneoplastic on histology. Final diagnosis was established within 1 week after CT examination. Nine tonsils were diagnosed with tonsillar squamous cell carcinoma on histology (Fig. 1). On cytology, a squamous cell origin was suspected in four tonsils with carcinoma. Melanoma was found unilaterally in two tonsils (Fig. 2). Bilateral tonsillar lymphoma was diagnosed in case 1 by fine-needle aspiration (Fig. 3). A large cell lymphoma was suspected for this case but the owner declined further investigations. Both tonsils were sampled in six dogs and bilateral involvement confirmed in 50% of them (cases 1, 10, 12).

3.2 | Computed tomography image acquisition parameters

All CT examinations were performed under general anesthesia with an endotracheal tube in place except for one dog. Open-mouth CT examination was performed in seven dogs. Computed tomographic images were acquired with multidetector CT units. A 4-slice CT unit (University of Edinburgh - Somatom Volume Zoom, Siemens, Germany) and a 16-slice CT unit (University of Milan - GE BrightSpeed Elite, General Electric, Italy) were used. Scan settings included slice thickness from 1.25 to 3 mm, collimator pitch between 0.8 and 1.5, X-ray tube potential 120 kVp, tube current exposure time product 50 to 200 mAs, matrix 512×512 , reconstructed with a low frequency algorithm.

3.3 | Computed tomographic findings

Computed tomographic and diagnostic findings for individual dogs are provided in Appendix 1. Hyoid bone deviation due to tonsillar

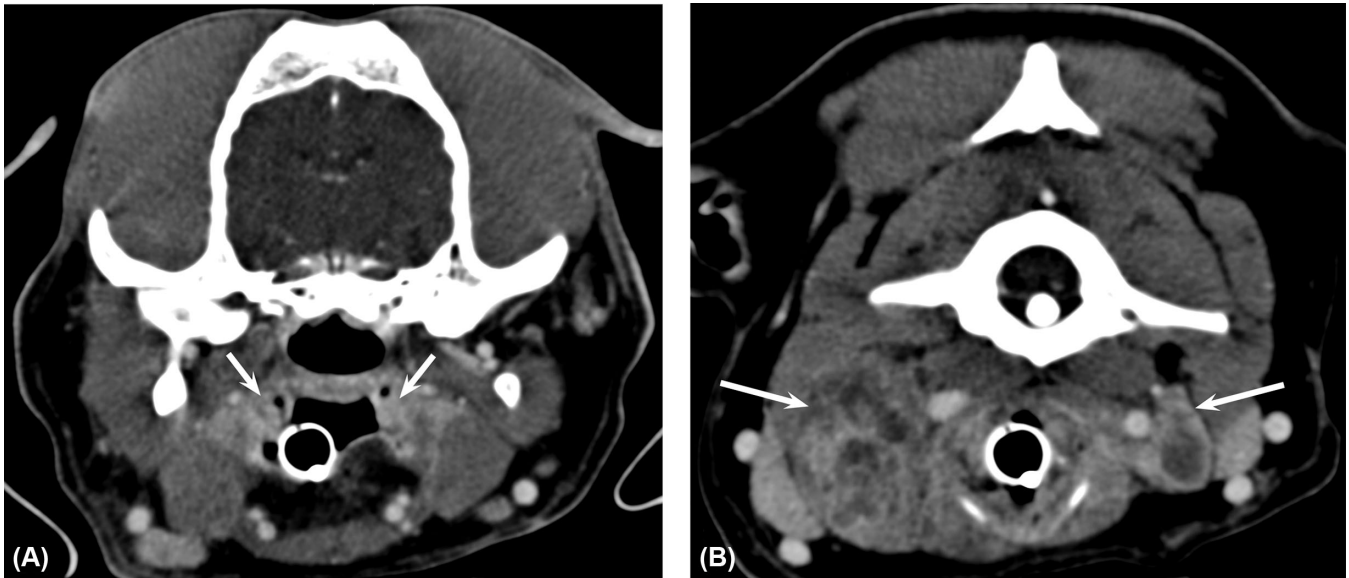


FIGURE 1 Postcontrast computed tomographic images of case 11, illustrating (A) minimal tonsillar enlargement due to bilateral carcinoma (arrows) and (B) enlargement and heterogeneity of both medial retropharyngeal lymph nodes with absent hilus (arrows). Window width = 200 HU, window level = 50 HU

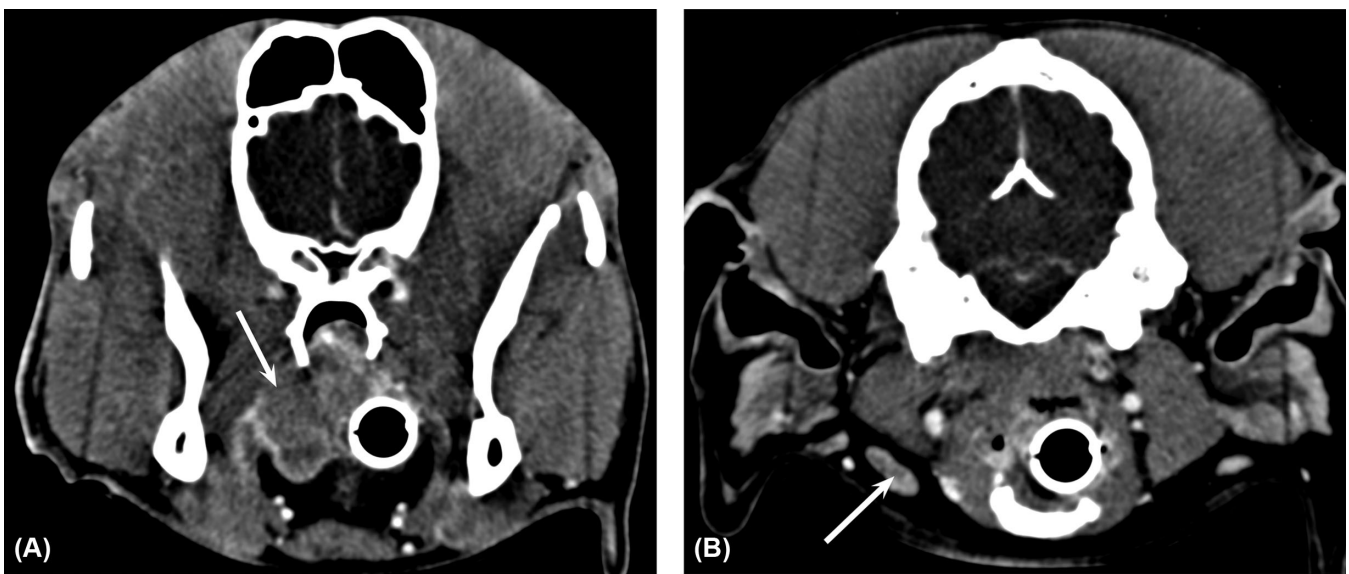


FIGURE 2 Postcontrast computed tomographic images of case 8, illustrating (A) right tonsillar enlargement due to melanoma associated with soft palate invasion (arrow) and (B) normal right mandibular lymph node with hypoattenuating hilus (arrow). Window width = 200 HU, window level = 50 HU

enlargement was found in three dogs (cases 2, 3, and 5), and deviation by the medial retropharyngeal lymph node was described in one dog (case 13). Hyoid bone and mandibular periosteal reaction was noted in one dog (case 3). A mineralized focus within the neoplastic tonsil was found in cases 3 and 14. Invasion of surrounding organs such as the parotid salivary gland and musculature of the neck by the metastatic medial retropharyngeal lymph node was described in case 14. Invasion of the soft palate by the neoplastic tonsil was reported in four dogs (cases 3, 8, 10, and 14; Fig. 2).

Computed tomographic features of neoplastic tonsils and confirmed nonneoplastic tonsils are summarized in Table 1. The size of neoplastic tonsils was significantly different from the size of nonneo-

plastic tonsils (Mann-Whitney U, $N_{\text{neoplastic}} = 17$, $N_{\text{nonneoplastic}} = 3$, $U = 199$, $P = 0.03$). A power analysis was not performed for this result. The median size of the confirmed neoplastic tonsils was quantitatively higher than for the confirmed nonneoplastic tonsils. The tonsillar size was considered small (≤ 10 mm) in three patients with tonsillar carcinoma. A metastatic lymphadenomegaly was confirmed for these three cases. When dogs were categorized according to their size, the median tonsillar size was 10.6 mm ($N = 4$, range: 5.9–14.4) for small dog breeds, 15.8 mm ($N = 11$, range: 9.7–37.2) for medium dog breeds, and 36.4 mm ($N = 2$, range: 33.8–39.1) for large dog breeds. The patient affected by tonsillar lymphoma exhibited one of the largest tonsillar sizes of our population. Nonneoplastic and neoplastic tonsils did not demonstrate

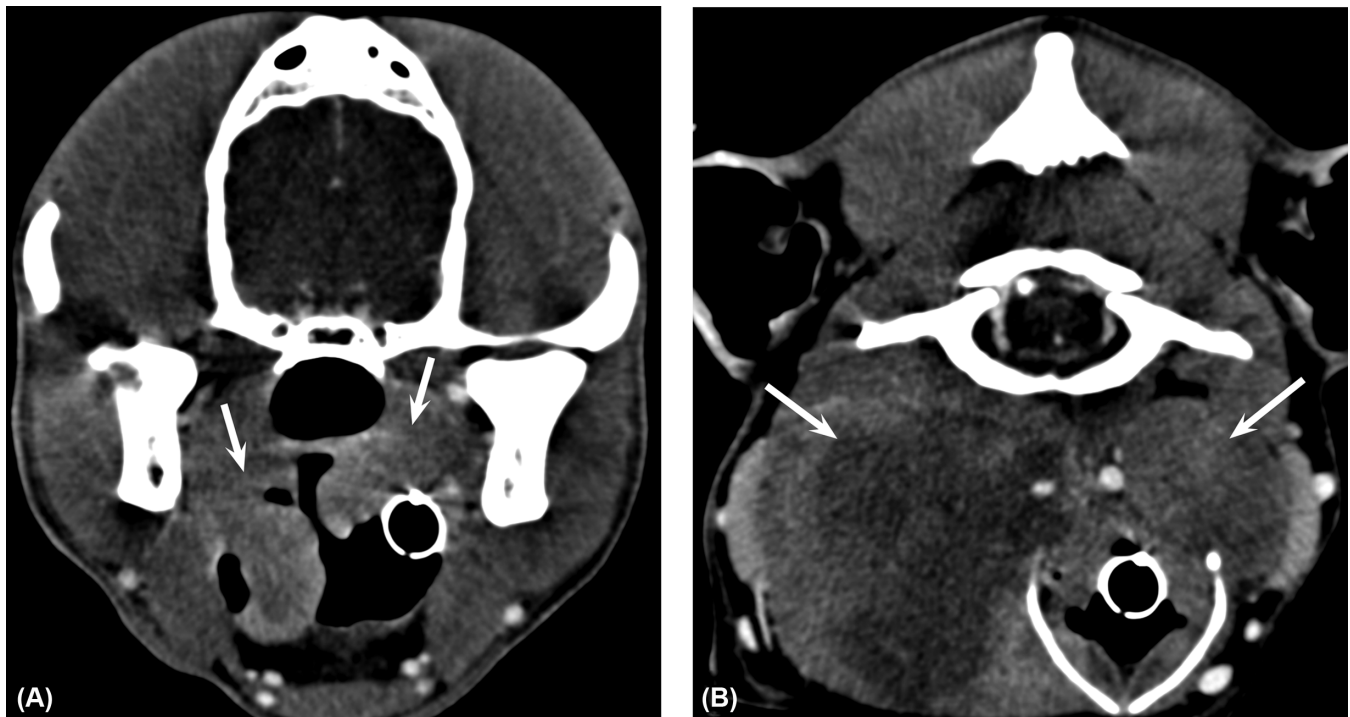


FIGURE 3 Postcontrast computed tomographic images of case 1, illustrating (A) bilateral tonsillar enlargement due to lymphoma (arrows) and (B) marked enlargement and heterogeneity of both medial retropharyngeal lymph nodes with absent hilus (arrows). Window width = 200 HU, window level = 50 HU

TABLE 1 Computed tomographic features of neoplastic and confirmed nonneoplastic tonsils

| | Neoplastic Tonsils (<i>n</i> = 17) | Nonneoplastic Tonsils (<i>n</i> = 3) |
|---|-------------------------------------|---------------------------------------|
| Median tonsillar size (range) | 15.8 mm* (5.9–41.6) | 9.7 mm* (5.7–11.5) |
| Median precontrast attenuation (range) | 49 HU (29–75) | 53 HU (53–58) |
| Median postcontrast attenuation (range) | 89 HU (53–165) | 98 HU (72–118) |

*statistical significant difference.
mm, millimeters; HU, Hounsfield units.

any specific contrast enhancement pattern. Postcontrast rim enhancement was reported in two tonsils with lymphoma, two tonsils with melanoma, one affected by squamous cell carcinoma but also within one hyperplastic tonsil.

Eighteen medial retropharyngeal lymph nodes were scored as enlarged in 12 dogs (median width: 19.6 mm). Marked enlargement was reported for 67% (12/18) of these lymph nodes (width superior or equal to 18 mm). In 73% of dogs (8/11), the medial retropharyngeal lymphadenomegaly was ipsilateral to the confirmed neoplastic tonsil. Six dogs had an enlarged mandibular lymph node ipsilateral to the confirmed neoplasia (*N* = 9, range: 7–11 mm). Heterogeneity was described for 69% of the enlarged lymph nodes (22/32) on postcontrast images (Figs. 1 and 3). This subjective finding of heterogeneity was supported by an increased standard deviation of the attenuation value measured within these lymph nodes on pre- and postcontrast images (Table 2). Rim enhancement was reported in seven heterogeneous lymph nodes. All normally sized lymph nodes had a homogeneous appearance on CT after contrast injection. Among the 32 lymph nodes reported as enlarged on CT, a loss of the hypoattenuating hilus was reported in 29 of them. The same feature was described in three

lymph nodes scored as normal in size. Lymphadenopathy was absent in two dogs with tonsillar squamous cell carcinoma. The mandibular and medial retropharyngeal lymphadenomegaly noted on CT was confirmed as metastatic for 41% of the lymph nodes (9/32 on histology and 4/32 on cytology). Eight of these 13 metastatic lymph nodes were heterogeneous with hypoattenuating centers, and 10 had a loss of the hypoattenuating hilus. Cases 2 and 9 had a mandibular lymph node of normal size (contralateral and ipsilateral, respectively) that was confirmed nonmetastatic on histology.

Regarding the deep cervical lymph nodes, lymphadenomegaly was reported in cases 1, 11, and 14 (3/12). These dogs also had bilateral mandibular and medial retropharyngeal lymphadenomegaly. All 24 superficial cervical lymph nodes identified on CT in the same 12 dogs were considered within normal limits on CT.

3.4 | Other findings and treatment

Thoracic CT was performed in 13 dogs (Appendix 1). A single dog demonstrated numerous pulmonary metastases up to 5 mm (case 10). In this case, concomitant bilateral thyroid carcinoma was

TABLE 2 Computed tomographic appearance of medial retropharyngeal and mandibular lymph nodes associated with tonsillar neoplasm in 14 dogs

| | Median | Minimum | Maximum |
|--|----------------|--------------|----------------|
| Precontrast attenuation of normal sized lymph node (<i>n</i> = 24) | 41 HU (SD 6.5) | 17 HU (SD 2) | 79 (SD 15) |
| Postcontrast attenuation of normal sized lymph node (<i>n</i> = 24) | 81 HU (SD 8) | 38 HU (SD 3) | 136 HU (SD 21) |
| Precontrast attenuation of enlarged lymph node (<i>n</i> = 32) | 36 HU (SD 8) | 18 HU (SD 2) | 57 HU (SD 17) |
| Postcontrast attenuation of enlarged lymph node (<i>n</i> = 32) | 92 HU (SD 14) | 41 HU (SD 3) | 126 HU (SD 26) |

HU, Hounsfield units; SD, standard deviation.

suspected as well on fine-needle aspiration. A 4 mm pulmonary nodule was described in case 8. Its size remained static on follow-up CT examination performed 10 months later, most consistent with a benign lesion. This dog diagnosed with right tonsillar melanoma also developed an aggressive neoplasia of the right mandible at that time. The owner declined sampling of this new lesion however based on the clinical history and imaging features, a primary tonsillar melanoma with a metastatic mandibular lesion was suspected. A large primary mandibular tumour was histologically diagnosed as melanoma in case 5.

4 | DISCUSSION

This is the first published study exclusively focusing on the tomographic features of tonsillar neoplasia in dogs. Carcinoma was the most common neoplasm affecting the tonsil (79% of dogs) in our case series, which is consistent with previous publications.^{7,8,11} Squamous cell carcinoma was histologically confirmed in most of these animals. Melanoma was the second most common malignancy (14%) and lymphoma was found in only one dog. It was interesting to note that, despite the greater risk for tonsillar neoplasia reported for male versus female dogs, in our study there was a similar proportion of female and male dogs.^{4–6,11} This could be due to selection bias, or related to the neutered status of most of the dogs in our study. In humans, several risk factors for tonsillar squamous cell carcinoma have been reported such as tobacco, alcohol consumption and, to a lesser extent, human papilloma virus.¹²

Interestingly, bilateral tonsillar neoplasia was reported in one dog with lymphoma and two dogs with carcinoma. We hypothesized that the largest tonsil may have represented the primary neoplasia that has metastasized to the contralateral tonsil. The most enlarged lymph node was always ipsilateral to the most enlarged tonsil in our population, which supported the same theory. A concomitant neoplastic occurrence in both tonsils is another possibility. The likelihood of bilateral neoplastic involvement was higher than in a previous study that reported bilateral tonsillar squamous cell carcinoma in 33% of nine cases.⁴ The high prevalence of 50% in our study may have been due to the small sample size or the biased sampling of enlarged tonsils only. Compression of surrounding soft tissue by the enlarged tonsil or lymph node was a common finding in 43% of the dogs. Vascular invasion and bone lysis were not common features of tonsillar neoplasia in our study although periosteal reaction was noted in one case of squamous cell carcinoma. The soft palate was the most common site of invasion by tonsillar neoplasms (29%). Such invasion is considered as an advanced stage of tumour growth in dogs.^{4,5,13}

The enhancement pattern of tonsils on CT was not specific to a particular type of neoplasia. As expected, neoplastic tonsils were generally enlarged compared to nonneoplastic tonsils. It should nevertheless be noted that the size of the neoplastic tonsil remained normal or minimally enlarged in three dogs affected by neoplasia. A tonsillar neoplasm can therefore easily be missed when the size of the tonsil remains small. To the author's knowledge, this feature has not been emphasized in the veterinary literature and diagnosis of these cases can be challenging.

The generalized mandibular and medial retropharyngeal lymphadenomegaly did not aid in differentiating between tumour types. In our study, 86% of patients exhibited enlargement of at least one medial retropharyngeal lymph node on CT. Mandibular lymphadenomegaly (64% of patients) was always described in association with medial retropharyngeal lymphadenomegaly. Among our included cases, there was no enlarged lymph node reported to have a width between 12 and 18 mm. Therefore, authors decided to consider 18 mm as a cut-off value above which node enlargement was considered marked. Most dogs with tonsillar neoplasia (64%) presented with a medial retropharyngeal lymphadenopathy superior or equal to 18 mm. Indeed medial retropharyngeal lymph nodes are close to the tonsils and are considered sentinel lymph nodes.³ In accordance with a recent publication on nontonsillar malignancies of the head, the authors hence recommend bilateral systematic sampling or removal of the medial retropharyngeal lymph node in view of histology, in addition to the mandibular lymph nodes, when a tonsillar neoplasm is suspected.¹⁴ In our study, 25% of dogs also presented with a deep cervical lymphadenomegaly, which was always seen in conjunction with a bilateral mandibular and medial retropharyngeal lymphadenomegaly. In view of a complete staging, we advise sampling of the deep cervical lymph nodes as well. A previous study on CT characteristics of pharyngeal neoplasia included eight dogs with tonsillar carcinoma but specific features of tonsillar neoplasia were not highlighted due to a merged description of multiple pharyngeal neoplasms.¹¹ Findings from this study were consistent with some of our findings and demonstrated that medial retropharyngeal lymph nodes were more frequently affected than the mandibular nodes and that markedly enlarged, rounded, and heterogeneous lymph nodes were associated with a 75% chance of nodal metastasis.¹¹ With canine tonsillar squamous cell carcinoma, it has been demonstrated that tumour size and nodal involvement are associated with survival time.⁴ Tonsillar neoplasms can however coexist with normal size lymph nodes as well (cases 4 and 7). The percentage of normal appearing lymph nodes on CT that was confirmed metastatic on cytology was estimated at 6% (5/82) in a previous study.¹⁵ The differential

diagnosis for tonsillar enlargement without associated lymphadenomegaly also includes several benign pathologies. Tonsillar lesions such as lymphangiomas and epithelial cysts have been reported.^{16,17} A study gathering eight dogs with tonsillar polyps, mostly found incidentally, did not describe any lymphadenomegaly.¹⁷ The CT features of medial retropharyngeal lymph nodes do have bearing in the radiological differential diagnosis. Neoplasia should remain in the differential diagnosis of enlarged tonsils with no associated lymphadenomegaly on CT, alongside with tonsillar polyp, hyperplasia, or tonsillitis.

Loss of the nodal hypoattenuating hilus was commonly reported in 91% of the enlarged lymph nodes in our study. Among the 13 confirmed metastatic lymph nodes, 77% of them presented this feature. With nodal metastasis, the absence of the hilus on CT is thought to be secondary to metastatic remodeling.¹⁸ As previously described in cats with nasal neoplasia, loss of the hypoattenuating hilus within the lymph node should be taken into account in the staging process of tonsillar neoplasia on CT.¹⁸ However, this feature may also be considered in a small number of cases as a normal node variant. Magnetic resonance imaging is another modality that can bring additional information in differentiating between neoplastic and inflammatory lymph nodes.¹⁹ Similar imaging features such as loss of the nodal hilus or heterogeneity are expected in metastatic lymph nodes due to tonsillar neoplasia. In our study, another common concomitant imaging feature of tonsillar neoplasia was nodal heterogeneity. A large number of confirmed metastatic lymph nodes (61%) were heterogeneous with hypoattenuating centers on postcontrast images. Such an appearance was compatible with nodal necrosis. The authors would like to point out that tonsillar neoplasia should be considered in the differential diagnosis when an isolated medial retropharyngeal lymphadenomegaly is noted on computed tomography, regardless of a normally sized tonsil. For these cases, sampling of both tonsils should be advised to the clinician.

Pulmonary metastases at time of diagnosis were only described in one case. Distant metastasis was not a common feature of tonsillar neoplasia in our population. The same finding was described in a retrospective study, in which none of the 33 dogs with tonsillar squamous cell carcinoma had lung metastasis on radiography at the time of diagnosis.⁶ An older study reported a higher rate of lung metastases on postmortem examination in 21% of 24 dogs with tonsillar squamous cell carcinoma.²⁰ Later stage cancer may explain the differing prevalence for distant lung metastasis. In case 5, the large mandibular melanoma likely represented a primary neoplasia that metastasized to the tonsil. The palatine tonsil does not have any afferent lymphatics so any metastasis in a tonsil originates from hematogenous spread, hence implying a poor prognosis.^{3,21} In the human literature, only 0.8% of tonsillar malignancies result from metastasis of nonhematological malignant neoplasm.⁹ Bilateral thyroid gland invasion was suspected in case 10. On computed tomography, both tonsils were relatively small, which precludes us from hypothesizing on the nature of the primary neoplasia for this case. These cases highlight the aggressive local metastatic potential of tonsillar neoplasia.

With respect to limitations of this study, the small sample size precluded us from performing meaningful statistics beyond the included tests. Due to the retrospective nature of the case series, histology

was not performed on all enlarged lymph nodes noted on CT. Patients had variable delays up to 5 min between the injection of contrast medium and the CT acquisition which may explain the wide variation of tonsillar enhancement on postcontrast images and lack of differentiation between neoplastic and nonneoplastic tonsils. This lack of differentiation may also be explained by the different concentrations of contrast medium products that have been used. The palatine tonsil is a small organ that can be challenging to delineate on CT. The use of open-mouth CT examination has been recommended to identify the pharyngeal structures.²² Open-mouth CT was performed in 50% of the examinations included in our study. In the author's experience, it greatly improved the visualization of the tonsils. Closed-mouth examination may have caused mild inaccuracy of the tonsillar measurements in seven cases. The small number of confirmed nonneoplastic tonsils is a limitation to the comparison between neoplastic and nonneoplastic tonsils in our study. The size of the two tonsils diagnosed as hyperplastic may have been slightly increased. This limitation is related to the lack of information in the literature on the tomographic appearance of normal canine tonsils.

In conclusion, our primary hypothesis that CT characteristics of the canine palatine tonsil and regional lymph nodes would differentiate neoplastic from nonneoplastic tonsils was rejected. However, the lymph node appearance was helpful in distinguishing neoplastic versus nonneoplastic disease for some cases. Marked enlargement (≥ 18 mm width on transverse CT images), heterogeneity, and loss of the hypoattenuating hilus of medial retropharyngeal lymph nodes were common concomitant features of tonsillar neoplasia on postcontrast CT images. Although these nodal features were not seen in all patients with tonsillar neoplasia, they represented a useful tool in the diagnostic process and differentiation between neoplastic and nonneoplastic tonsils for patients in which they were present. Tonsillar neoplasia should therefore be considered in the differential diagnosis list for dogs with CT features of tonsillar enlargement with or without regional lymph node enlargement, or isolated medial retropharyngeal lymphadenopathy with or without tonsillar enlargement.

LIST OF AUTHOR CONTRIBUTIONS

Category 1

- (a) Conception and Design: Thierry F, Longo M, Pecceu E, Schwarz T
- (b) Acquisition of Data: Thierry F, Longo M, Zani DD, Pecceu E, Schwarz T
- (c) Analysis and Interpretation of Data: Thierry F, Longo M

Category 2

- (a) Drafting the Article: Thierry F
- (b) Revising Article for Intellectual Content: Thierry F, Longo M, Zani DD, Pecceu E, Schwarz T

Category 3

- (a) Final Approval of the Completed Article: Thierry F, Longo M, Zani DD, Pecceu E, Schwarz T

ORCID

Florence Thierry  <http://orcid.org/0000-0003-4175-4397>

Tobias Schwarz  <http://orcid.org/0000-0001-8412-573X>

REFERENCES

1. König HE, Liebich HG. Mouth and pharynx. In: HE König, H-G Liebich, eds. *Veterinary anatomy of domestic mammals: textbook and colour atlas*. 3rd ed. Stuttgart: Schattauer; 2004:279–299.
2. Casteleyn C, Breugelmanns S, Simoens P, Van den Broeck W. The tonsils revisited: review of the anatomical localization and histological characteristics of the tonsils of domestic and laboratory animals. *Clin Dev Immunol*. 2011;2011:472460.
3. Evans HE, De Lahunta A. Pharynx. *Miller's Anatomy of the Dog*. 4th ed. St Louis: Saunders, an imprint of Elsevier; 2013:303–304.
4. Grant J, North S. Evaluation of the factors contributing to long-term survival in canine tonsillar squamous cell carcinoma. *Aust Vet J*. 2016;94:197–202.
5. Mas A, Blackwood L, Cripps P, et al. Canine tonsillar squamous cell carcinoma—a multicentre retrospective review of 44 clinical cases. *J Small Anim Pract*. 2011;52:359–364.
6. Kühnel S, Kessler M. Tonsillar squamous cell carcinoma in the dog. A retrospective study of 33 cases. *Tierärztl Prax*. 2010;38:367–373.
7. Bostock DE, Curtis R. Comparison of canine oropharyngeal malignancy in various geographical locations. *Vet Rec*. 1984;4:341–342.
8. White RAS, Jeffries AR, Freedman LS. Clinical staging for oropharyngeal malignancies in the dog. *J Small Anim Pract*. 1985;26:581–594.
9. Wang H, Chen P. Palatine tonsillar metastasis of rectal adenocarcinoma: a case report and literature review. *World J Surg Oncol*. 2013;11:114–119.
10. Windfuhr JP, Toepfner N, Steffen G, Waldfahrer F, Berner R. Clinical practice guideline: tonsillitis I. Diagnostics and nonsurgical management. *Eur Arch Otorhinolaryngol*. 2016;273:973–987.
11. Carozzi G, Zotti A, Alberti M, Rossi F. Computed tomographic features of pharyngeal neoplasia in 25 dogs. *Vet Radiol Ultrasound*. 2015;56:628–637.
12. Krüger M, Pabst AM, Walter C, et al. The prevalence of human papilloma virus (HPV) infections in oral squamous cell carcinomas: a retrospective analysis of 88 patients and literature overview. *J Craniomaxillofac Surg*. 2014;42:1506–1514.
13. Murphy S, Hayes A, Adams V, et al. Role of carboplatin in multimodality treatment of canine tonsillar squamous cell carcinoma—a case series of five dogs. *J Small Anim Pract*. 2006;47:216–220.
14. Skinner OT, Boston SE, Souza CH. Patterns of lymph node metastasis identified following bilateral mandibular and medial retropharyngeal lymphadenectomy in 31 dogs with malignancies of the head. *Vet Comp Oncol*. 2017;15:881–889.
15. Magestro LM, Gieger TL. Detection of synchronous primary tumours and previously undetected metastases in 736 dogs with neoplasia undergoing CT scans for diagnostic, staging and/or radiation treatment planning purposes. *Vet Comp Oncol*. 2017;15:576–581.
16. Miller AD, Alcaraz A, McDonough SP. Tonsillar lymphangiomatous polyp in an adult dog. *J Comp Path*. 2008;38:215–217.
17. Lucke VM, Pearson GR, Gregory SP, Whitbread TJ. Tonsillar polyps in the dog. *J Small Anim Pract*. 1988;29:373–379.
18. Nemanic S, Hollars K, Nelson NC, Bobe G. Combination of computed tomographic imaging characteristics of medial retropharyngeal lymph nodes and nasal passages aids discrimination between rhinitis and neoplasia in cats. *Vet Radiol Ultrasound*. 2015;56:617–627.
19. Johnson PJ, Elders R, Pey P, Dennis R. Clinical and magnetic resonance imaging features of inflammatory versus neoplastic medial retropharyngeal lymph node mass lesions in dogs and cats. *Vet Radiol Ultrasound*. 2016;57:24–32.
20. Withers FW. Squamous-celled carcinoma of the tonsil in the dog. *J Path Bact*. 1939;49:429–432.
21. Wakasugi S, Kageshita T, Ono T. Metastatic melanoma to the palatine tonsil with a favourable prognosis. *Br J Dermatol*. 2001;145:327–329.
22. Laurenson MP, Zwingenberger AL, Cissell DD, et al. Computed tomography of the pharynx in a closed vs open mouth position. *Vet Radiol Ultrasound*. 2011;52:357–361.

How to cite this article: Thierry F, Longo M, Pecceu E, Zani DD, Schwarz T. Computed tomographic appearance of canine tonsillar neoplasia: 14 cases. *Vet Radiol Ultrasound*. 2018;59:54–63. <https://doi.org/10.1111/vru.12561>

APPENDIX 1: COMPUTED TOMOGRAPHIC APPEARANCE OF TONSILLAR NEOPLASIA IN 14 DOGS

| Case | Breed | Age (years) | Sex | Size of right tonsil (in mm) | CT appearance of right tonsil (ROI in HU) | Right tonsil diagnosis | Size of left tonsil (in mm) | CT appearance of left tonsil (ROI in HU) | Left tonsil diagnosis | Lymphadenomegaly on CT (width in mm) | Confirmed metastatic lymph nodes |
|----------------------------|---------------|-------------|-----|------------------------------|---|------------------------|-----------------------------|--|-----------------------|---|---|
| 1 | Collie | 6 | MN | 42 mm | Pre: homogenous (66 HU) | Lymphoma (C) | 21 mm | Pre: homogenous (74 HU) | Lymphoma (C) | both mandibular (13 & 9 mm), both medial retropharyngeal (49 & 26 mm) | both mandibular (C), R medial retropharyngeal (C) |
| PC: heterogeneous (104 HU) | | | | | | | | | | | |
| 2 | Collie | 12 | MN | 10 mm | Pre: heterogeneous (53 HU) | Hyperplasia (H) | 37 mm | Pre: heterogeneous (29 HU) | SCC (H) | L mandibular (8 mm), L medial retropharyngeal (19 mm) | L mandibular (H), L medial retropharyngeal (H) |
| PC: heterogeneous (118 HU) | | | | | | | | | | | |
| 3 | Czech wolfdog | 12 | F | 39 mm | Pre: heterogeneous (50 HU) | SCC (H) | 18 mm | Pre: homogenous (49 HU) | n/a | both mandibular (8 & 7 mm), R medial retropharyngeal (18 mm) | n/a |
| PC: heterogeneous (53 HU) | | | | | | | | | | | |
| 4 | WHWT | 9 | F | 14 mm | Pre: heterogeneous (50 HU) | SCC (H) | 8 mm | Pre: homogenous (69 HU) | n/a | None | n/a |
| PC: heterogeneous (83 HU) | | | | | | | | | | | |
| 5 | Maltese | 10 | MN | 8 mm | Pre: heterogeneous (42 HU) | n/a | 14 mm | Pre: heterogeneous (40 HU) | Melanoma (H) | L mandibular (10 mm), L medial retropharyngeal (6 mm) | n/a |
| PC: heterogeneous (93 HU) | | | | | | | | | | | |
| 6 | Collie | 13 | NF | 10 mm | Pre: heterogeneous (42 HU) | n/a | 21 mm | Pre: heterogeneous (45 HU) | Carcinoma (C) | L mandibular (7 mm), both medial retropharyngeal (10 & 34 mm) | Suspected in L medial retropharyngeal (C) |

(Continues)

APPENDIX 1 (Continued)

| Case | Breed | Age (years) | Sex | Size of right tonsil (in mm) | CT appearance of right tonsil (ROI in HU) | Right tonsil diagnosis | Size of left tonsil (in mm) | CT appearance of left tonsil (ROI in HU) | Left tonsil diagnosis | Lymphadenomegaly on CT (width in mm) | Confirmed metastatic lymph nodes |
|------|------------------|-------------|-----|------------------------------|--|------------------------|-----------------------------|--|-----------------------|---|----------------------------------|
| 7 | Cross | 11 | M | 16 mm | PC: heterogeneous (150 HU) Pre: heterogeneous (41 HU) | SCC (H) | 9 mm | Pre: homogeneous (37 HU) PC: homogeneous (69 HU) | n/a | None | n/a |
| 8 | Labrador | 11 | NF | 34 mm | Pre: homogenous (43 HU) PC: heterogeneous (83 HU) | Melanoma (C) | 12 mm | Pre: homogenous (57 HU) PC: heterogeneous (117 HU) | n/a | R mandibular (7 mm), both medial retropharyngeal (12 & 8 mm) | n/a |
| 9 | CKCS | 9 | NM | 6 mm | Pre: homogenous (53 HU) PC: heterogeneous (72 HU) | Hyperplasia (H) | 25 mm | Pre: homogenous (45 HU) PC: heterogeneous (75 HU) | SCC (H) | L medial retropharyngeal (21 mm) | L medial retropharyngeal (H) |
| 10 | Springer spaniel | 11 | M | 16 mm | Pre: heterogeneous (45 HU) PC: heterogeneous (113 HU) | Carcinoma (C) | 12 mm | Pre: heterogeneous (49 HU) PC: heterogeneous (126 HU) | Carcinoma (C) | both mandibular (11 & 7.8 mm), both medial retropharyngeal (35 & 10 mm) | Both medial retropharyngeal (H) |
| 11 | Cross | 9 | NF | 13 mm | Pre: homogenous (49 HU) PC: homogenous (165 HU) | SCC (H) | 5 mm | Pre: homogenous (56 HU) PC: heterogeneous (120 HU) | n/a | R medial retropharyngeal (19 mm) | n/a |

(Continues)

APPENDIX 1 (Continued)

| Case | Breed | Age (years) | Sex | Size of right tonsil (in mm) | CT appearance of right tonsil (ROI in HU) | Right tonsil diagnosis | Size of left tonsil (in mm) | CT appearance of left tonsil (ROI in HU) | Left tonsil diagnosis | Lymphadenomegaly on CT (width in mm) | Confirmed metastatic lymph nodes |
|------|------------------------|-------------|-----|------------------------------|--|------------------------|-----------------------------|--|-----------------------|---|----------------------------------|
| 12 | Schnauzer | 6 | NF | 7 mm | Pre: homogenous (55 HU) PC: heterogeneous (89 HU) | SCC (H) | 6 mm | Pre: homogenous (47 HU) PC: homogeneous (83 HU) | SCC (H) | R medial retropharyngeal (9.3 mm) | Both medial retropharyngeal (H) |
| 13 | Collie | 14 | NF | 13 mm | Pre: homogenous (51 HU) | SCC (H) | 11 mm | Pre: homogenous (58 HU) | Normal (H) | both mandibular (8.9 & 11 mm), both medial retropharyngeal (32 & 24 mm) | Both medial retropharyngeal (H) |
| 14 | Springer Spaniel cross | 7 | NM | 8 mm | Pre: homogenous (58 HU) PC: heterogeneous (87 HU) | n/a | 10 mm | Pre: homogenous (53 HU) PC: homogeneous (98 HU) | Carcinoma (C) | both mandibular (9.3 & 10 mm), both medial retropharyngeal (19.8 & 28.8 mm) | L mandibular (C) |

H, histologically confirmed; C, cytologically confirmed; HU, Hounsfield unit; R, right; L, left; SCC, squamous cell carcinoma; Pre, precontrast CT images; PC, postcontrast CT images; WHWT, West Highland white terriers; CKCS, Cavalier King Charles spaniel; Czech, Czechoslovakian wolfdog.