

## Role of Intracardiac Echocardiography in Atrial Fibrillation Ablation

Antonio Dello Russo, MD PhD\*, Eleonora Russo, MD\*, Gaetano Fassini, MD\*, Michela Casella, MD PhD\*, Ester Innocenti, MD\*, Martina Zucchetti, MD\*, Claudia Cefalu', MD\*, Francesco Solimene, MD§, Gaetano Mottola, MD§, Daniele Colombo, MD\*, Fabrizio Bologna, MD\*, Benedetta Majocchi, MD\*, Pasquale Santangeli, MD\*\*, Stefania Riva, MD\*, Luigi Di Biase, MD, PhD\*\*, Cesare Fiorentini, MD\*, and Claudio Tondo, MD PhD, \*.

\*Cardiac Arrhythmia Research Centre, Centro Cardiologico Monzino IRCCS, Milan, Italy, \*\*Texas Cardiac Arrhythmia Institute, Austin Texas, USA, § Casa di Cura Montevergine, Mercogliano, Italy.

### Abstract

In the recent years, several new evidences support catheter-based ablation as a treatment modality of atrial fibrillation (AF). Based on a plenty of different applications, intracardiac echocardiography (ICE) is now a well-established technology in complex electrophysiological procedures, in particular in AF ablation. ICE contributes to improve the efficacy and safety of such procedures defining the anatomical structures involved in ablation procedures and monitoring in real time possible complications. In particular ICE allows: a correct identification of the endocardial structures; a guidance of transseptal puncture; an assessment of accurate placement of the circular mapping catheter; an indirect evaluation of evolving lesions during radiofrequency (RF) energy delivery via visualization of micro and macrobubbles tissue heating; assessment of catheter contact with cardiac tissues. Recently, also the feasibility of the integration of electroanatomical mapping (EAM) and intracardiac echocardiography has been demonstrated, combining accurate real time anatomical information with electroanatomical data. As a matter of fact, different techniques and ablation strategies have been developed throughout the years. In the setting of balloon-based ablation systems, recently adopted by an increasing number of centers, ICE might have a role in the choice of appropriate balloon size and to confirm accurate occlusion of pulmonary veins. Furthermore, in the era of minimally fluoroscopic ablation, ICE has successfully provided a contribute in reducing fluoroscopy time.

The purpose of this review is to summarize the current applications of ICE in catheter based ablation strategies of atrial fibrillation, focusing-on electronically phased-array ICE.

### Introduction

In the recent years, several new evidences support catheter-based ablation as a treatment modality of atrial fibrillation (AF), either in patients with drug-resistant symptomatic paroxysmal AF or as first-

line therapy in selected patients. The common endpoint of AF ablation procedure in most centers is Pulmonary Veins Isolation (PVI).<sup>1-4</sup> This anatomically based approach implies the need for a better visualization of left atrial anatomy and interventional catheter devices in addition to tra-

**Corresponding Address** : Antonio Dello Russo, MD PhD, Cardiac Arrhythmia Research Centre, Centro Cardiologico Monzino, IRCCS, Via Parea 4, 20138 Milan, Italy.

ditional fluoroscopy. Although the fluoroscopic two-dimensional “silhouette” imaging provides a general overview of the cardiac anatomy, it requires substantial experience to carefully recognize the target structures and to guide catheters location. Intracardiac echocardiography (ICE) allows to visualize the left atrium (LA) in real time during the course of the procedure and to identify all structures for the ablation accomplishment. ICE has proved to be helpful in the setting of electrophysiological (EP) procedures and in particular for AF catheter-based ablation allowing: (1) a correct identification of the endocardial structures (assessment of pulmonary veins anatomy, ostium size, and normal blood flow via 2-D anatomical imaging and Doppler measurements); (2) a guidance of transseptal puncture, particularly in the setting of complex or unusual anatomy; (3) an assessment of accurate placement of the circular mapping catheter; (4) an indirect evaluation of evolving lesions during radiofrequency (RF) energy delivery via visualization of micro and macrobubbles tissue heating, with the latter providing a signal for energy termination; (5) assessment of catheter contact with cardiac tissues.<sup>5-8</sup> Recently, also the feasibility of the integration of electroanatomical mapping (EAM) and intracardiac echocardiography has been demonstrated, combining accurate real time anatomical information with electroanatomical data.<sup>6,9-11</sup> As a matter of fact, different techniques and ablation strategies have been developed throughout the years. In the setting of balloon-based ablation sys-

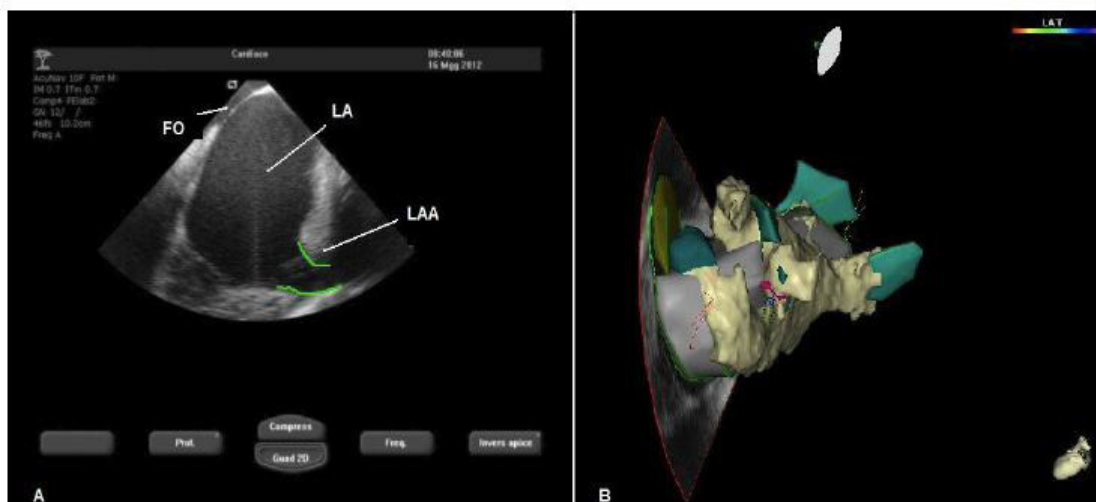
tems, recently adopted by an increasing number of centers, ICE might have a role in the choice of appropriate balloon size and to confirm accurate occlusion of pulmonary veins (PV).<sup>12-14</sup> Furthermore, in the era of minimally fluoroscopic ablation, ICE has successfully provided a contribute in achieving “near-to-zero” fluoroscopy ablation.<sup>10,15,16</sup>

The purpose of this review is to summarize the current applications of ICE in catheter based ablation strategies of atrial fibrillation, focusing-on electronically phased-array ICE.

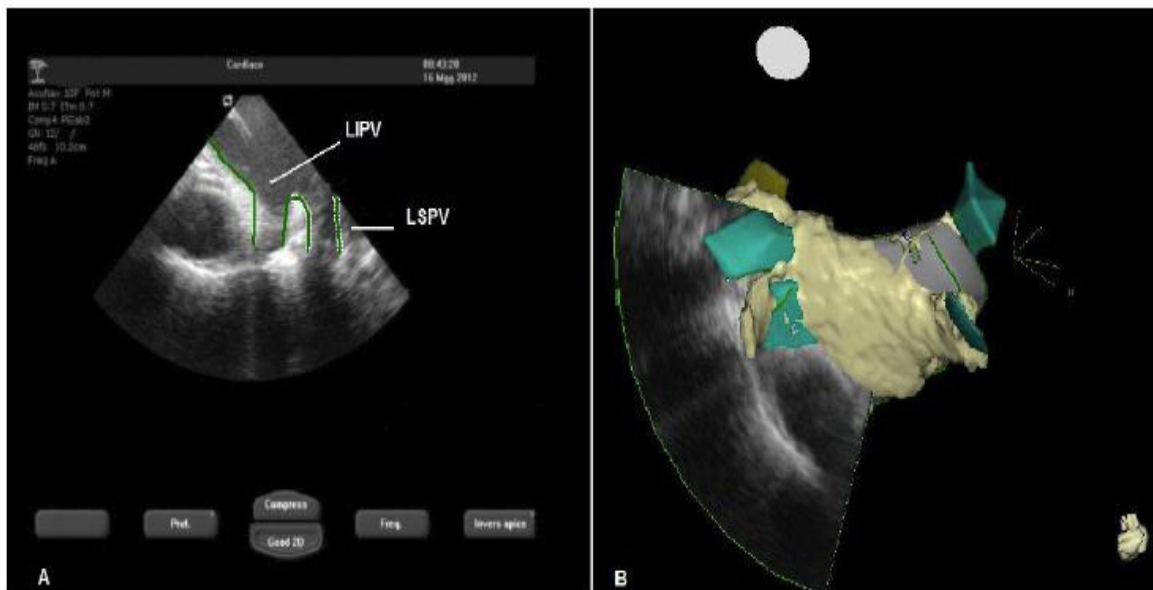
### Intracardiac Echocardiography: Types of ICE Probe

During the past 15 years, transducer miniaturization and advances in microelectric and piezoelectric crystal technology have allowed ICE to become an invaluable tool for cardiac assessment. Nowadays two different types of ICE imaging systems are available: the mechanical ultrasound catheter radial imaging system and the electronic phased-array catheter sector imaging system. In the mechanical ultrasound catheter (Ultra ICE) radial imaging system (EP Technologies, Boston Scientific), a single, rotating, crystal ultrasound transducer is mounted at the end of a nonsteerable 9 Fr (110-cm length) catheter. Mechanical ICE produces imaging frequencies between 9 and 12 MHz, thus providing near-field clarity (within 5 to 7 cm of the transducer) but poor tissue penetration and farfield resolution. As a result, this system has not

**Figure 1: Panel A:** Intracardiac echocardiography (ICE)-2D image of the left atrium (LA), left atrial appendage (LAA) and fossa ovalis (FO). The green lines represent the endocardial borders tracked in order to build a 3D anatomical shell. **Panel B:** Co-registration of the LA ICE-3D-anatomical shell and the pre-operative cardiac computed tomography (CT) scan.



**Figure 2: Panel A:** Intracardiac echocardiography (ICE) 2D image of the left atrium (LA), left superior and inferior pulmonary veins (LSPV and LIPV). The green lines represent the endocardial borders. **Panel B:** Co-registration of the LA ICE-3D-anatomical shell and the pre-operative cardiac CT scan

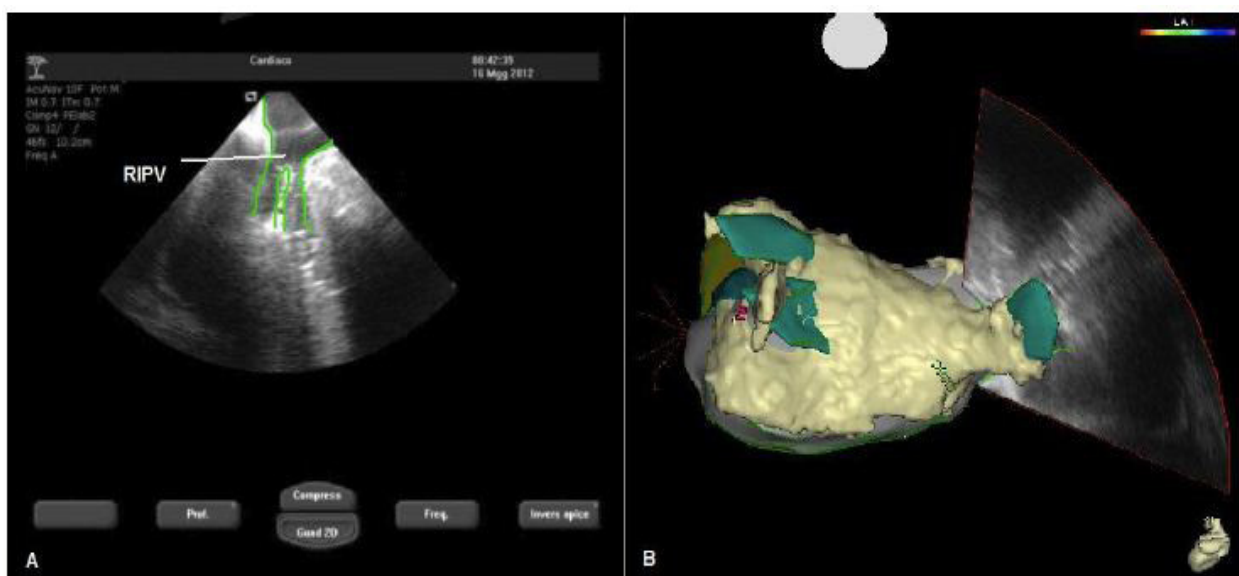


allowed clear imaging of the LA and PV, except when introduced directly into the LA (transseptally).<sup>6,17</sup>

In the electronic phased-array ultrasound catheter (AcuNav) coupled with sector imaging system (Acuson Corporation, Siemens Medical Solutions, Malvern, Pa.), the ultrasound transducer is mounted on the distal end of an 8 or 10 Fr (90-cm length) catheter and has a forward-facing 64-element vector phased-array transducer scanning in

the longitudinal plane. The catheter has a four-way steerable tip (160 degrees anteroposterior and left-right deflections). Imaging capabilities include 90-degree sector 2-D, M-mode, and Doppler imaging (pulsed-wave, continuous-wave, color, and tissue Doppler), with tissue penetration up to 16 cm, and variable ultrasound frequency (5.5, 7.5, 8.5, and 10 MHz). Electronically phased-array ICE can provide more detailed cardiac structural and functional imaging, comparable with transesophageal echocardiography, but without manipulation in a

**Figure 3: Panel A:** Intracardiac echocardiography (ICE)-2D image of the left atrium (LA), right inferior pulmonary vein (RIPV). The green lines represent the endocardial borders. **Panel B:** Co-registration of the LA ICE-3D-anatomical shell and the pre-operative cardiac CT scan.



limited esophageal space. It also provides hemodynamic evaluation with Doppler and color flow imaging for the atria, pulmonary veins and great vessels. These features have been of significant value for PV isolation procedures and creation of linear lesions in the LA.<sup>6,17</sup>

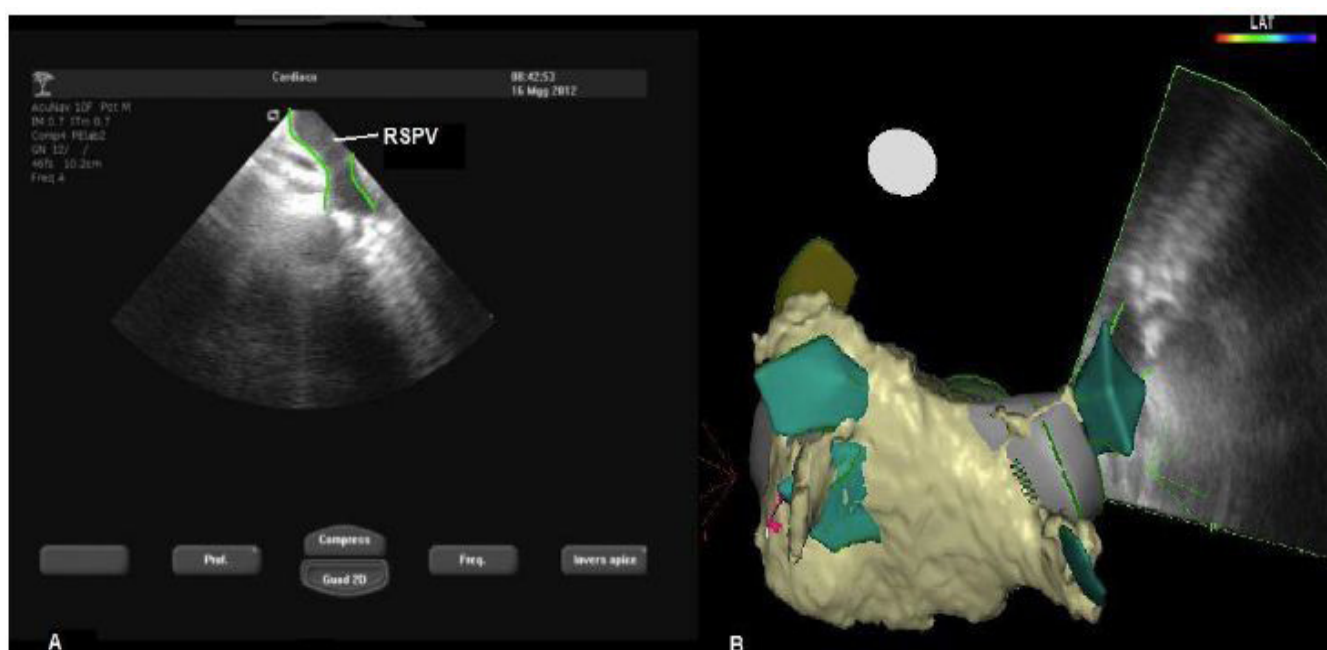
A newer phased array ultrasound catheter 64-element systems, the ViewFlex Plus (St. Jude Medical, Inc.) developed in association with Philips Medical Systems (Bothell, WA) is a steerable catheter via two-way articulation and runs on the ViewMate ultrasound system (EPMedSystems, Inc., Berlin, NJ). The ViewFlex Plus ICE catheter has a frequency ranging from 4.5 to 8.5 MHz, with an imaging depth of 12 cm. It appears to be somewhat similar to the AcuNav catheter that can be rotated axially and steered in anterior and posterior directions. The ViewMate Z System uses Zone Sonography from ZONEARE Medical Systems, a new approach to ultrasound image acquisition and processing. Using a small number of large “zones,” this technology acquires ultrasound data up to ten times faster than conventional systems and implements the full reality of data acquisition and management in software rather than hardware. By enhancing image resolution, uniformity, contrast, and penetration, ZONE Sonography provides high-quality images in real-time.<sup>6,17,18</sup>

## Visualization of Left Atrial Anatomy

Intracardiac echocardiography is usually performed introducing the catheter through the right femoral vein and then moving it into the right atrium (RA), the right ventricle or occasionally in the LA transeptally. By locating the ICE ultrasound probe in the RA a home long axis view of the RA, the RV and the tricuspid valve can be obtained.

From the home view position, a clockwise rotation of the catheter allows a subsequent view of the aorta, the pulmonary artery and the RV outflow tract. With a further rotation of the probe the Fossa Ovalis (FO), the LA, the mitral valve and left appendage become visible (Figure 1). Should a better view of the FO be required, the ICE catheter can be advanced or withdrawn accordingly to optimize its visualization. To better view the entire septum and the FO, the probe should be moved posteriorly. The left pulmonary veins are clearly visible rotating the probe from the left appendage view in a clockwise direction (Figure 2). A short-axis image obtained by inserting the probe into the RA and rotating it in a clockwise direction represents the best right pulmonary veins view (known as “owl-eyes”). During AF ablation is particularly relevant to visualize the right pul-

**Figure 4: Panel A:** Intracardiac echocardiography (ICE)-derived 2D image of the left atrium (LA), right superior pulmonary vein (RSPV). The green lines represent the endocardial borders. **Panel B:** Co-registration of the LA ICE 3D-anatomical shell and the pre-operative cardiac CT scan



monary veins in the long-axis view in order to get a better definition of the ostium-antrum border. This can be obtained by rotating the ICE probe posteriorly and placing it against the interatrial septum (Figure 3-4). A clear long axis view of both right pulmonary veins is usually much more difficult compared to the left ones. ICE plays also an important role in visualizing other structures of interest (e.g. the esophagus and the pericardium) whose anatomical positions are very important during AF ablation.

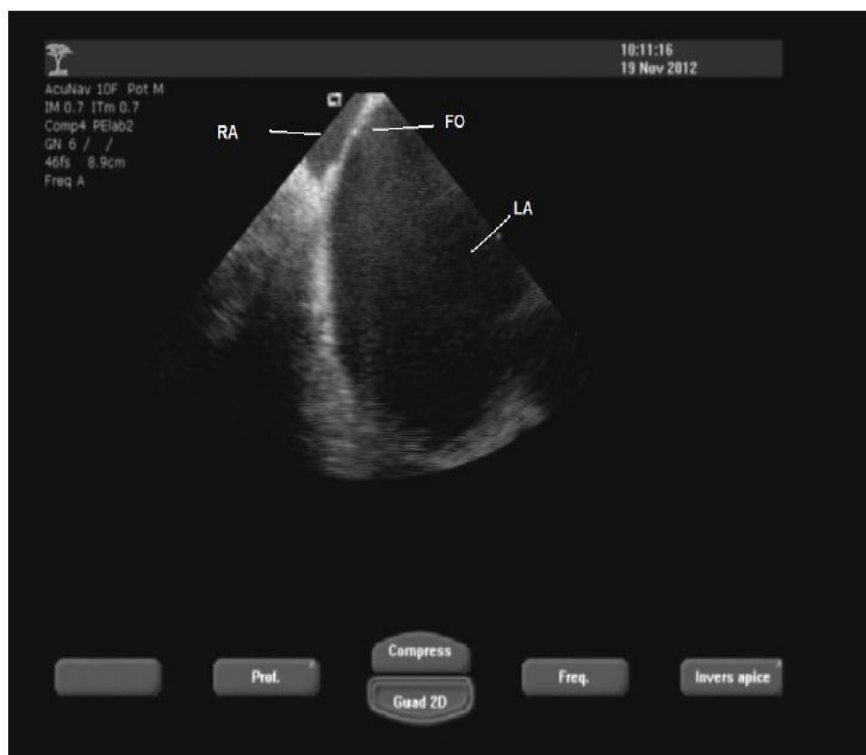### Guidance of Transseptal Puncture

Transseptal puncture has always been a challenge to the operator, due to the particular position of the fossa ovalis, the site of lowest resistance, located within the atrial septum between the posterior atrial wall and the bulb of the aorta. Traditionally, it has always been performed using fluoroscopic guidance, in which anatomic structures are not visualized directly and the catheter position is entirely estimated by its relationship with cardiac silhouette. Furthermore, it is possible to fluoroscopically estimate the position of fossa ovalis by standard electrode catheters as anatomical references.<sup>19</sup> Despite these strategies, complications

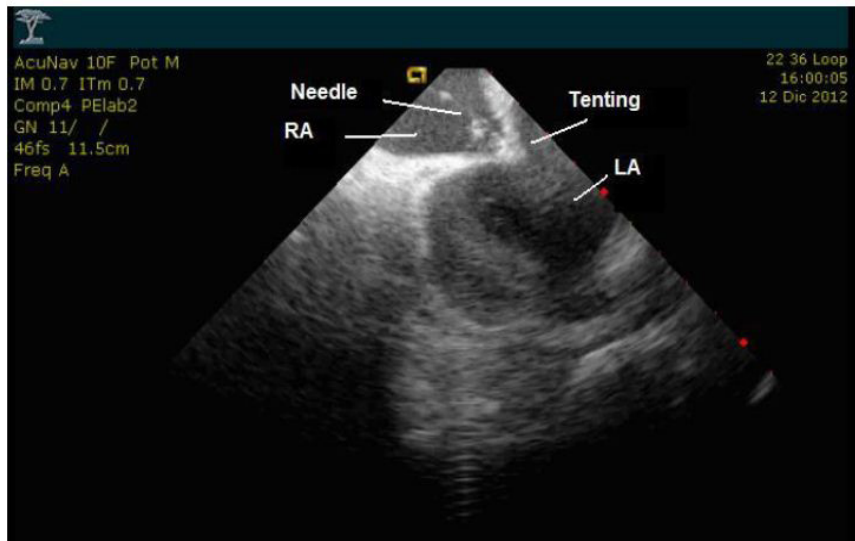
associated with transseptal puncture are estimated to occur in approximately 1% of procedures and are mostly related to the perforation of the posterior atrial wall or of the aortic root.<sup>20</sup>

Intracardiac echocardiography provides excellent display of the FO as previously described, and has recently become a complementary tool to fluoroscopy for a safer LA access (Figure 5). As a matter of fact, when advanced in the right atrium, the echocardiographic catheter provides a cross-sectional view of the FO, which allows the position of both the needle and the sheath to be checked in the middle of the FO (Figure 6). This helps to determine the exact position of the needle by looking for tenting of the membranous septum at the time of the puncture. It also confirms access to the left atrium via injection of contrast material through the needle, even though the HRS/EHRA/ECAS Expert Consensus Statement on Catheter and Surgical Ablation of Atrial Fibrillation recommends the use of ICE because of the possibility to visualize directly the interatrial septum, avoiding the use of iodine contrast whenever contraindicated.<sup>1,21</sup> According to this Statement, ICE should be used also thanks to the possibility of being able to perform, under echocardiographic guidance, transseptal

**Figure 5:** Two-dimensional ICE image derived from a transducer location in right atrium (RA). From this view it is possible to see the fossa ovalis (FO) and left atrium (LA)



**Figure 6:** Two-dimensional ICE image that shows the Brockenbrough-curve needle is advanced from the right atrium (RA) to the fossa ovalis (FO) for transseptal puncture guided by ICE. LA: left atrium

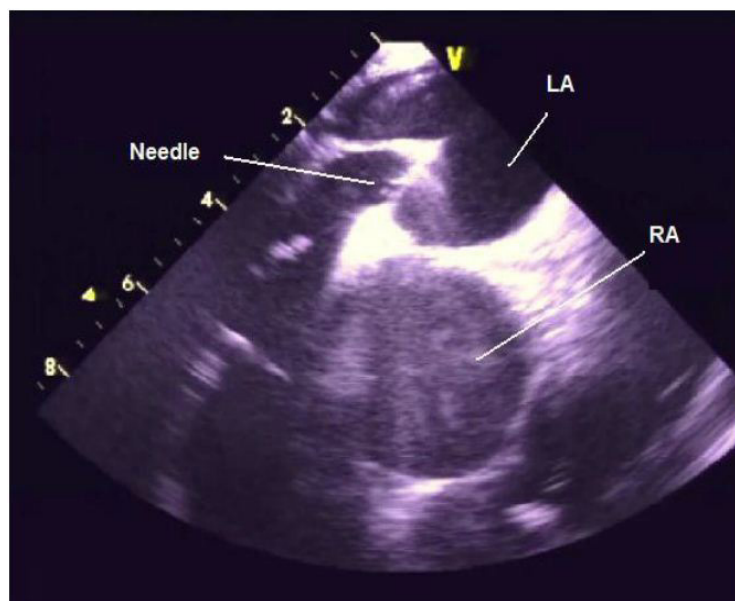


puncture in patients that are fully anticoagulated, since it may prevent cardiac tamponade.<sup>8</sup>

Continuous real-time observation of the interatrial septum also adds important information especially in patients with abnormal anatomy of the interatrial septum, such as aneurysmatic floppy septum, lipomatous hypertrophy of the septum, patent foramen ovale (PFO) or atrial septal defect (ASD) and previous cardiac surgery.<sup>5,22</sup> Double transseptal puncture in patients with ASD repair or PFO closure has been shown feasible and safe using

ICE. The effectiveness of a transseptal puncture through different devices as pericardial patches, septal stitches, Dacron patches, Cardioseal™ and Amplatzer™ guided by ICE have been described.<sup>23</sup> In patients with ASD closure devices the possibility to perform an eco-guided transseptal puncture both at the level of the native septum and of the implanted device was confirmed.<sup>24</sup> Furthermore, a recent study has demonstrated the role of ICE in the visualization of the intra-atrial membrane during transseptal catheterization in patients with AF and cor triatriatum, facilitating direct entry into

**Figure 7:** Interatrial septum visualized using ICE transoesophageally, tenting of the interatrial septum towards the left atrium (LA); RA, right atrium



the posterior-superior pulmonary vein chamber.<sup>25</sup> ICE can be used also for safe guidance of transseptal puncture to obtain biatrial access in patients affected by supraventricular arrhythmias, after atrial correction of the great arteries transposition.<sup>26</sup> An innovative approach consists in using ICE catheter transoesophageally, introducing the probe through the nasal route and performing close monitoring during the positioning of the transseptal needle, and withdrawing the probe after transseptal catheterization<sup>27</sup> (Figure 7). Even though fluoroscopy is still an important complementary tool during catheter positioning for the transseptal puncture, the possibility to perform the whole AF ablation procedure in both paroxysmal and persistent patients under ICE and electroanatomical mapping guidance has been recently described.<sup>28</sup>

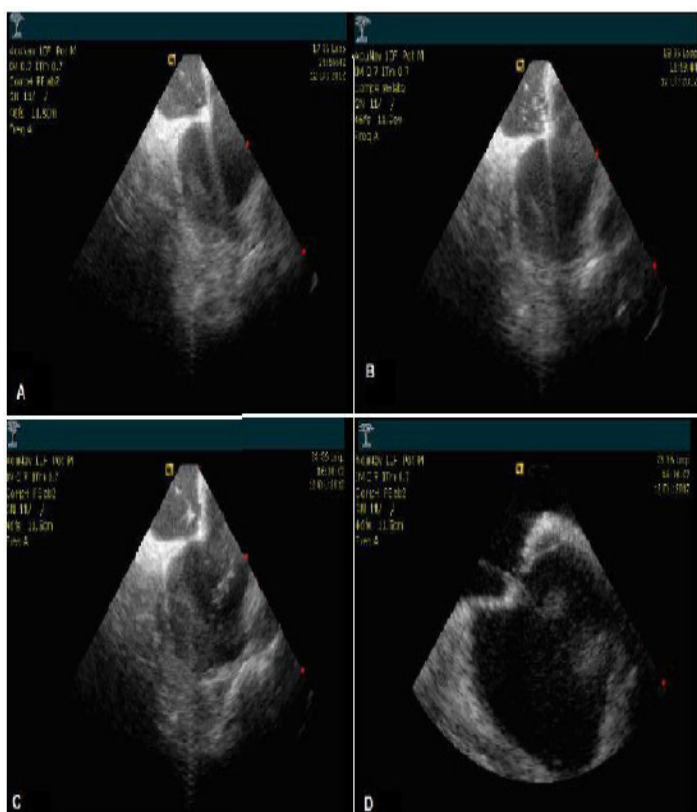
Some surveys have also shown that ICE is a useful tool in guiding difficult transseptal punctures requiring specifically designed radiofrequency needles (Toronto Transseptal Catheter, Baylis Medical Company Inc, Montreal, Canada) (Figure 8) or J-shaped transseptal guidewires (SafeSept, Pres-

sure Products, Inc., San Pedro, CA, USA).<sup>29,32</sup>

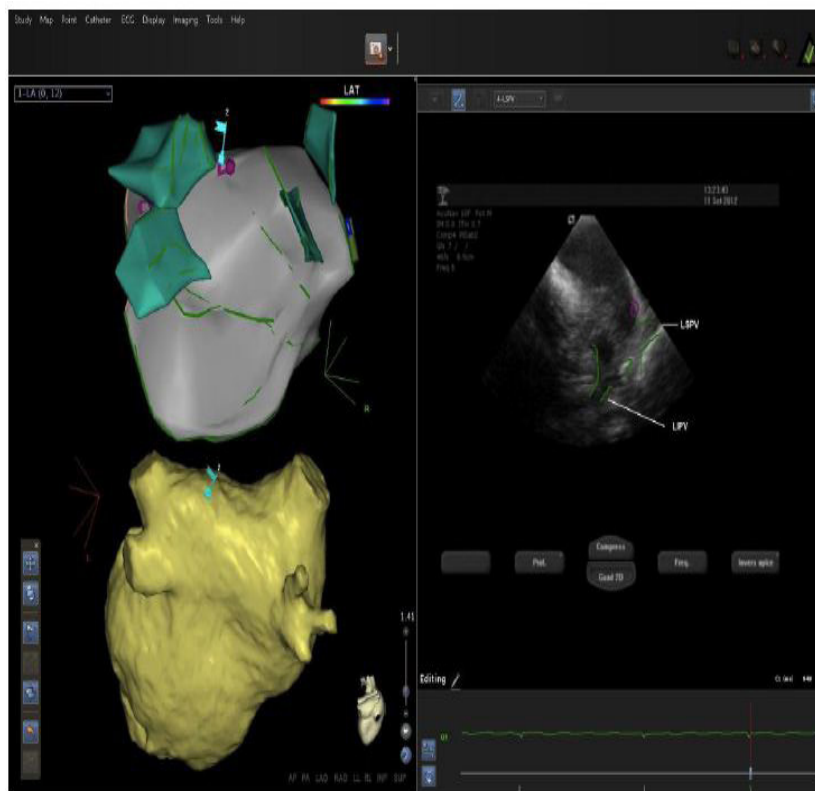
### Three-Dimensional Reconstruction of Left Atrial Anatomy

Integration of ICE imaging into a 3D reconstruction of the LA is an upgrade of the utility of ICE during AF ablation. The CARTOSound system (Biosense Webster, Inc.) allows to reconstruct multiple 2D ultrasound fans generated by ICE to a 3D shell of the cardiac chambers. By using a dedicated echocardiography probe (SoundStar 3D Ultrasound Catheter, Biosense Webster, Diamond Bar, USA) with a location sensor tracked by the mapping system, endocardial contours of the LA and PVs can be acquired while the catheter is still in the right atrium before transseptal puncture. The CARTOSound volume map of the cardiac chamber may be used as a stand-alone tool to guide navigation and ablation or as a facilitator of computed tomography (CT) scan or magnetic resonance imaging (MRI) image integration using an integrated software algorithm (CARTOMerge, Biosense Webster, Diamond Bar, USA). Continu-

**Figure 8:** Sequence of ICE imaging of transseptal puncture by radiofrequency delivery, crossing a thickened interatrial septum. Panel A: the tip of the powered needle is positioned in the fossa ovalis of the interatrial septum. Panel B: tenting of the fossa ovalis is demonstrated. Panel C: a single application of radiofrequency energy was delivered. Panel D: the tip of the needle can be seen in the left atrium (LA) immediately after radiofrequency energy delivery and the needle crossed the septum.



**Figure 9:** Screen shot of the CARTO (Biosense Webster, Inc., Diamond Bar, Calif.) electroanatomical mapping system. The ostium of the left superior PV, identified by ICE, is used as single landmark point (red circle on the ICE image right on the top). On the left the endocardial landmark point is marked on the imported 3-D CT image, thus creating a landmark pair, with one landmark point on the real-time electroanatomical map and the other on the 3-D CT image. Landmark registration approximates the electroanatomical map to the 3D CT surface reconstruction by matching the landmark pair



ous “real time” imaging provided by ICE yields a significant advantage, since both CT scan and MRI have the drawback of time intervals between the imaging and the ablative procedure itself, during which changes in anatomical conditions and shape of LA may occur, potentially due to changes in intravascular fluid volume, patient position and underlying cardiac rhythm.<sup>6</sup> Furthermore MRI has shortcomings associated with availability and costs, while CT causes additional radiation exposure for the patient and- requires contrast medium administration. Recreating LA anatomy with ICE is advantageous as it minimizes chamber deformity with contact mapping, permits detailed visualization of the LA and its adjacent structures, and reduces radiation exposure.<sup>33,34</sup>

Since the first reports of its use in humans, several studies have demonstrated the safety and efficacy of CARTOSound system for guiding ablation procedures, including AF catheter ablation.<sup>35</sup> A

good alignment between the reconstructed electroanatomical map and the 3D image of the heart is crucial for a proper merge; this process is then carried out by a mathematical algorithm (Figure 9).<sup>36</sup> A recent study showed that ICE-guided landmark registration with a new technique of ICE-guided focused endocardial surface registration resulted in a superior accuracy as compared to traditional landmark registration in achieving a better alignment between the CT/MR image and the electroanatomical map. (Figure 10).<sup>37</sup>

In a recent randomized study the impact of different modalities of image integration with CARTO system on procedural and fluoroscopy times was evaluated: CARTOSound-guided PV isolation with preprocedural MRI only or with the combination of MRI and/or ICE was studied. Total procedural time was similar in the three groups, but MRI integration required more fluoroscopy time and a longer dwell time spent in the LA. Intracardiac ultrasound image integration significantly



reduces fluoroscopy time and dwell in the LA, a parameter linked to the procedure-associated risk of cerebrovascular complications, in comparison to MRI integration alone.<sup>38</sup>

### Visualization and Navigation of Catheters

The position of the PV circular mapping catheter can be monitored with ICE to determine the precise location close to the ostium of PVs (Figure 11). A helpful tool of ICE integration with CARTO system is the possibility to display the tip of the ablation catheter in the ultrasound viewer of the CARTO monitor: a green coloured electronic representation of the catheter tip appears in the ultrasound real time image whenever the ultrasound fan intersects it (Figure 12). This feature allows to locate the exact position of the mapping catheter and to ensure adequate catheter tissue contact. Furthermore it can provide imaging of lesion morphologic changes including swelling, dimpling, crater formation, accelerated bubbles before popping.<sup>21</sup> Recently the impact of catheter tip/tissue contact in RA and LA in five dogs who underwent atrial ablation guided by the Sensei™ robotic catheter remote control system, using a 3.5-mm irrigated-tip ablation catheter has

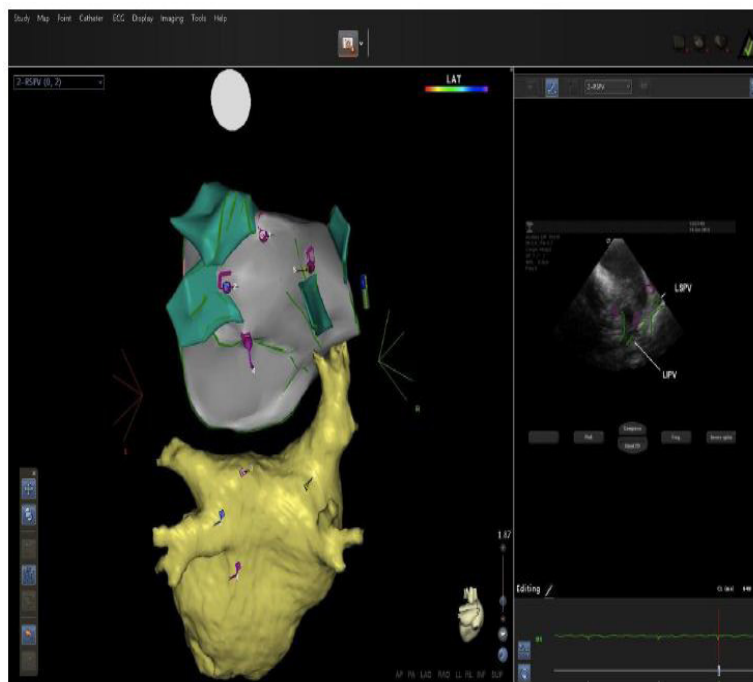
been evaluated (Celsius Thermocool, Biosense Webster, Inc., Diamond Bar, CA, USA). Simultaneous 2D ICE and fluoroscopic images were obtained to establish catheter tip/tissue orientation, catheter shaft curve angles and tissue contact. A correlation between 2D ICE/fluoroscopy visualized catheter tip/tissue contact and the measured contact force was found.<sup>39</sup>

### Monitoring for Complications

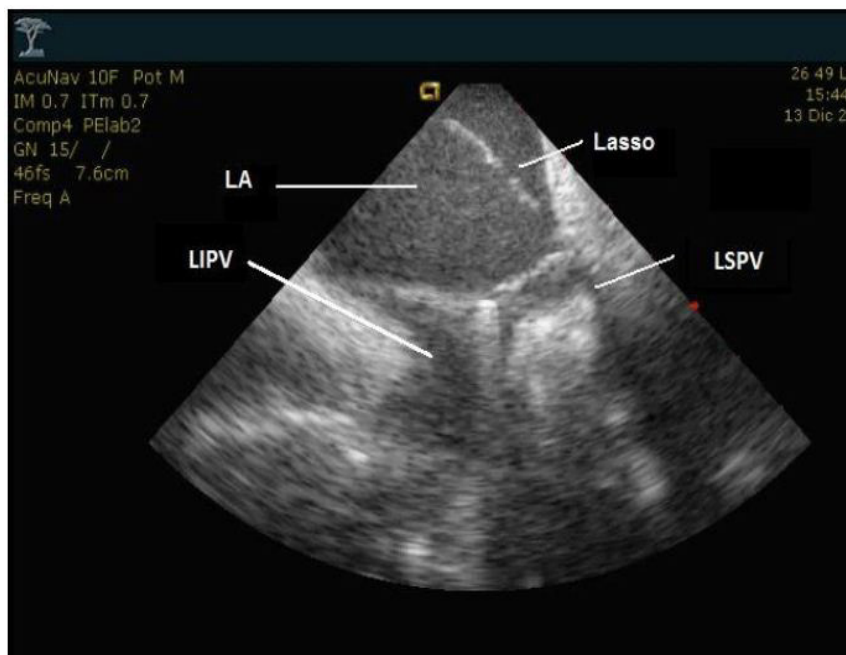
Even if it has been shown that the rate of major complications associated with AF catheter ablation has decreased from 11.1% in 2002 to 1.6% in 2010, it still represents a major concern for the electrophysiologists.<sup>40</sup> The use of ICE through different stages of the procedure can help to reduce complications such as pericardial effusion, tamponade, thrombus formation, pulmonary veins stenosis or atrial-esophageal fistulas (Figure 13).<sup>41,42</sup>

A recent study showed a significant lowering of complications of cardiac origin in procedures ICE-guided as compared to traditional approaches (0.25% vs 1.3%  $p=0,002$ ).<sup>41</sup> These findings can be easily explained by the capability of ICE to detect in real time even small pericardial effu-

**Figure 10:** Screen shot of the CARTO (Biosense Webster, Inc., Diamond Bar, Calif.) electroanatomical mapping system. Using more landmark points increases the accuracy of the registration process. On the right, the ICE 2-D image shows landmark points (red circles). The left panel shows landmarks points on the real time electroanatomical map and on the 3-D CT image



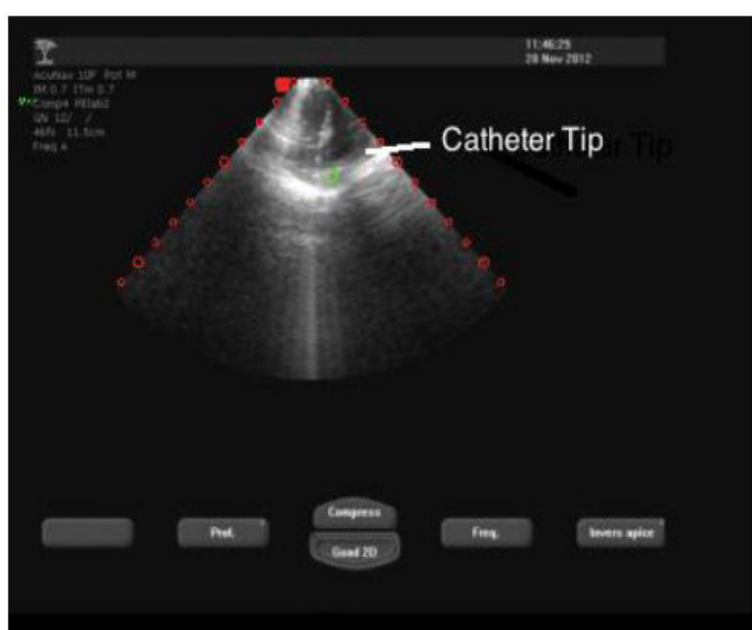
**Figure 11:** Intracardiac echocardiography (ICE)-derived 2D image of the left atrium (LA). A circular mapping catheter can clearly be visualized in the antrum of the LSPV



sions, at their very early stage, prior to hemodynamic changes.<sup>5</sup> Moreover, it has been proven that ICE can reduce thromboembolic events by providing serial assessment, multiple views and detailed imaging of the LAA to diagnose the presence of thrombus, most of all when equivocal TEE findings require confirmation.<sup>44</sup> It was also discussed the role of ICE in the early de-

tection of thrombus formation in the LA during catheter ablation, especially at the edge of the transseptal sheath or along the circular mapping catheter. An unexpected high incidence (10.3%) of thrombus formation despite correct anticoagulation with heparin was recorded. This underlines the possibility of being able

**Figure 12:** Intracardiac echocardiography (ICE)-derived 2D image of the left atrium (LA). Activating the function “show mapping catheter tip”, a green colored electronic representation of the catheter tip appears in the ultrasound real time image when the ultrasound fan intersects it



to perform a successful withdrawn into the right atrium of left atrial thrombi under ICE monitoring without any complication, preventing systemic embolic consequences.<sup>45</sup> ICE imaging can also help to set temperature, impedance and power during RF delivery, due to the early detection of microbubbles resulting from overheating that can even precede increased impedance, thus allowing a prompt termination of RF delivery. This can prevent tissue damage and scar formation which can lead to pulmonary veins stenosis and perforation.<sup>46,21</sup> Furthermore, this risk could be reduced by monitoring pulmonary vein ostial narrowing with Doppler color flow.<sup>47</sup>

Atrial-esophageal fistula is a rare but feared complication of AF catheter ablation. Esophagus can be easily identified by ICE. Precise measurements of the distance between the endocardium of the posterior wall and the outer layers of the esophagus at the site of ablation can be obtained, in order to select the safest location for the ablation catheter tip.<sup>48</sup> ICE can also be helpful in visualizing the location of luminal esophageal temperature probe, thus allowing its optimal placement, as close as possible to the ablation catheter, and performing a real-time monitoring of esophageal temperature.<sup>49</sup>

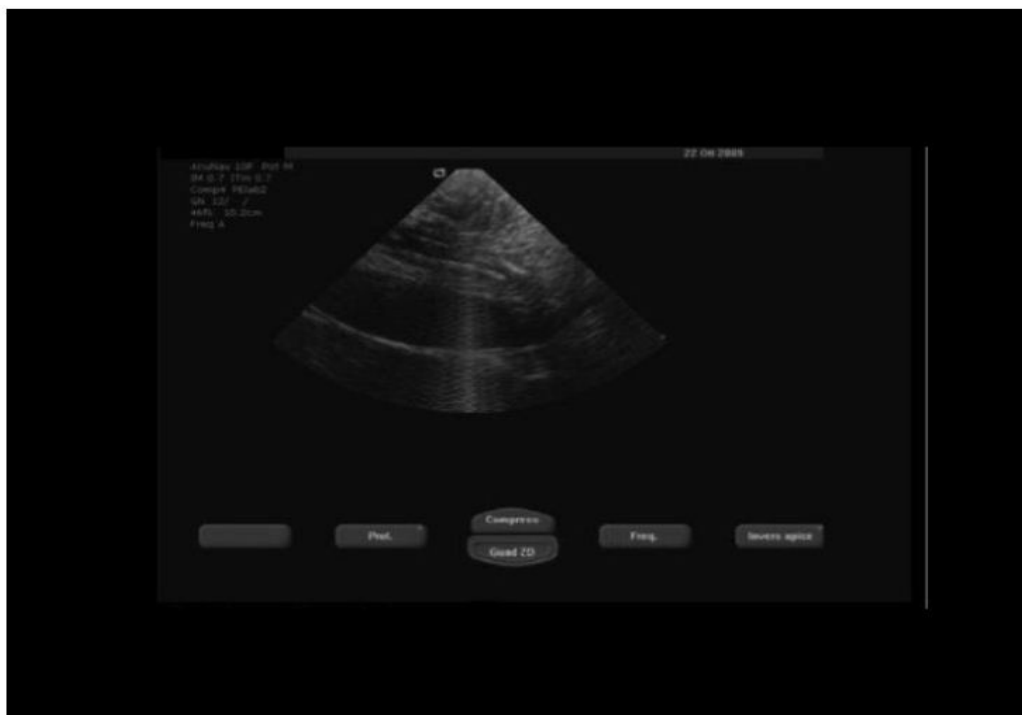## ICE and New Technologies in Atrial Fibrillation Ablation

In the last years new technologies in AF ablation have been developed in order to overcome some shortcomings associated with point to point ablation using a standard RF catheter.<sup>50</sup> Balloon-based and multielectrode ablation catheters as well as remote navigation system have been developed in an attempt to perform PV isolation in a shorter time and with a minimum number of lesions, to standardize its completeness and steadiness and to partly obviate the need for manual dexterity.

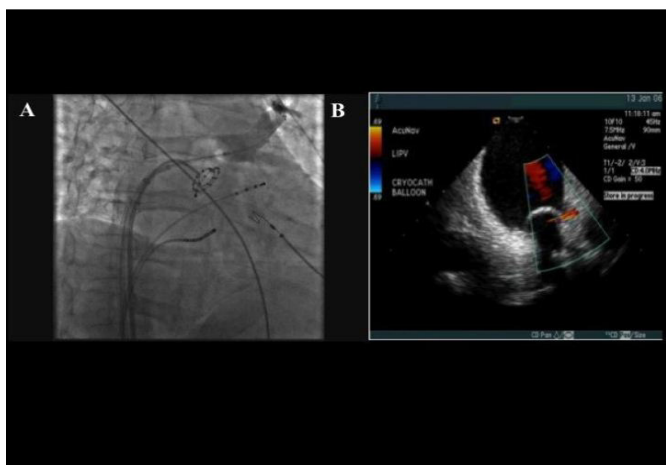
Balloon-based catheter ablation systems allow PVI with a single or few shots of energy delivery and a minimum number of lesions.<sup>51,13</sup> Currently balloon-based ablation systems allows to deliver different ablation sources such as cryothermal energy, laser, and high-frequency ultrasound.

ICE might be useful in cryo-ablation AF procedure –for the following reasons: to identify the relevant anatomic structures; to measure the PV ostium dimension in order to -choose the appropriate balloon size; to guide the placement and movement of the cryo-balloon catheter at the ostial and antral level of the PVs, thus improving both safety and

**Figure 13:** Intracardiac echocardiography (ICE) 2D image showing a large pericardial effusion (PE) surrounding the left ventricular wall.



**Figure 14:** Pulmonary vein occlusion guided by angiography and intracardiac echocardiography (ICE). Panel A: left anterior oblique fluoroscopic view showing the cryoballoon already inflated and placed in front of the left superior pulmonary vein (LSPV). Angiography shows complete occlusion. Panel B: intracardiac echocardiographic view of the LSPV antrum, displaying the whole left atrial antrum and the PV itself, as well as the balloon that has been placed in front of it. Color Doppler shows the absence of reflux to the left atrium



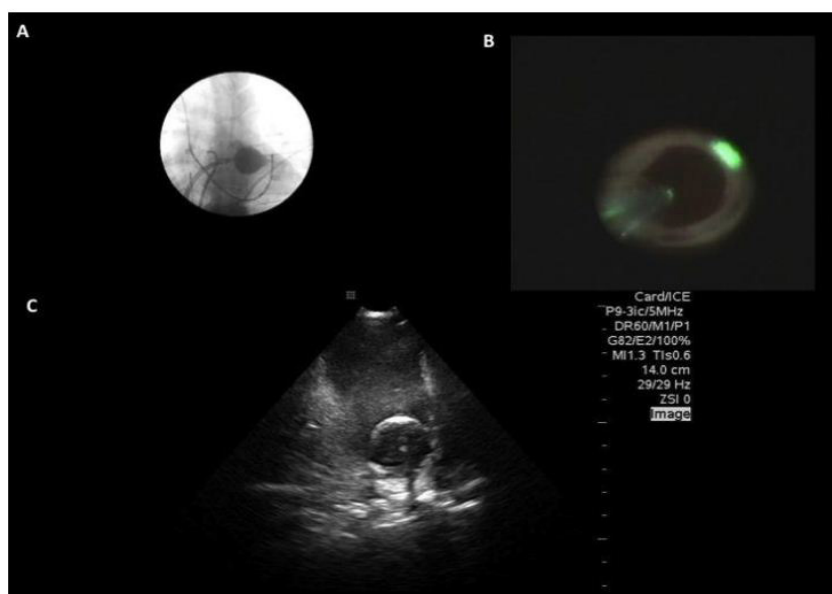
efficacy.<sup>52,53</sup> Using color Doppler information, the whole PV antrum can be visualized to optimize Doppler alignment for each PV during freezing and, subsequently, the position of the cryoballoon can be optimized to occlude gaps during the freezing cycle, documented by a loss of Doppler-coded reflux to the left atrium (Figure 14). Furthermore color Doppler information can be used for real-time monitoring of the PV occlusion level to avoid a too distal PV occlusion and prevent ostial PV narrowing. The use of ICE in this setting has also proved to be associated with lower fluo-

roscopy, contrast and procedural time.<sup>54-55</sup>

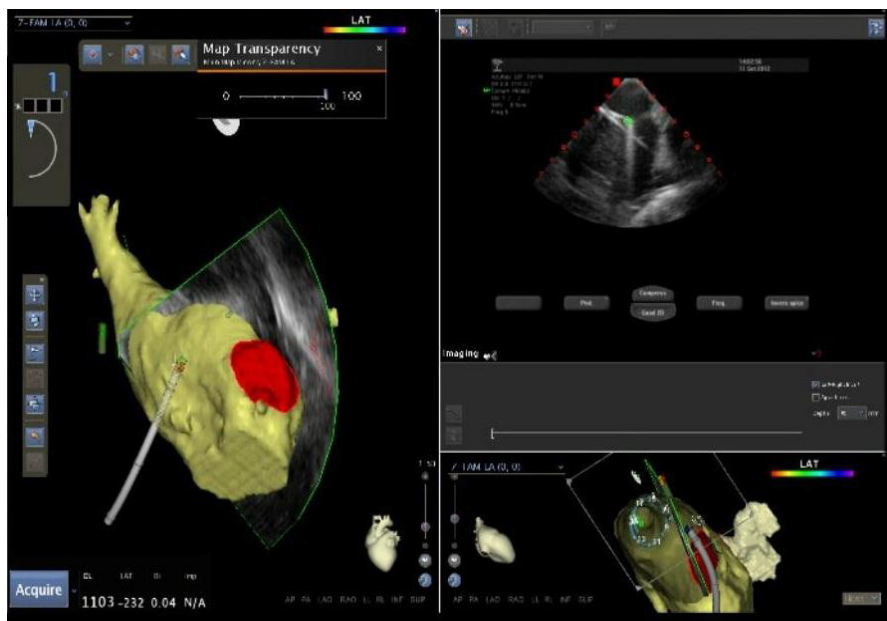
A recent study has shown that the PV occlusion during cryo-ablation can be easily predicted by intracardiac saline echocontrastography. This approach has reduced procedural time, radiological exposure and contrast medium use.<sup>56</sup>

ICE can also be helpful in the setting of other types of balloon catheters. One study has evaluated the role of ICE combined with laser-balloon ablation in 27 dogs. ICE has proved to be useful for leak

**Figure 15:** Panel A: pulmonary vein (PV) isolation using the laser balloon technology. The laser balloon is inflated in the left superior pulmonary vein (LSPV). Panel B: endoscopic view shows LSPV antrum. Panel C: intracardiac echocardiography (ICE)-derived 2D image of the left atrium with the Zonare technology. The laser balloon catheter can be visualized in the antrum of LSPV



**Figure 16 A:** Screen shot of the CARTO (Biosense Webster, Inc., Diamond Bar, Calif.) electroanatomical mapping system. On the right, in the ICE 2-D image, the green colored electronic representation of the catheter tip in left atrial chamber shows no contact to endocardial tissue (also confirmed by low contact force in left panel)

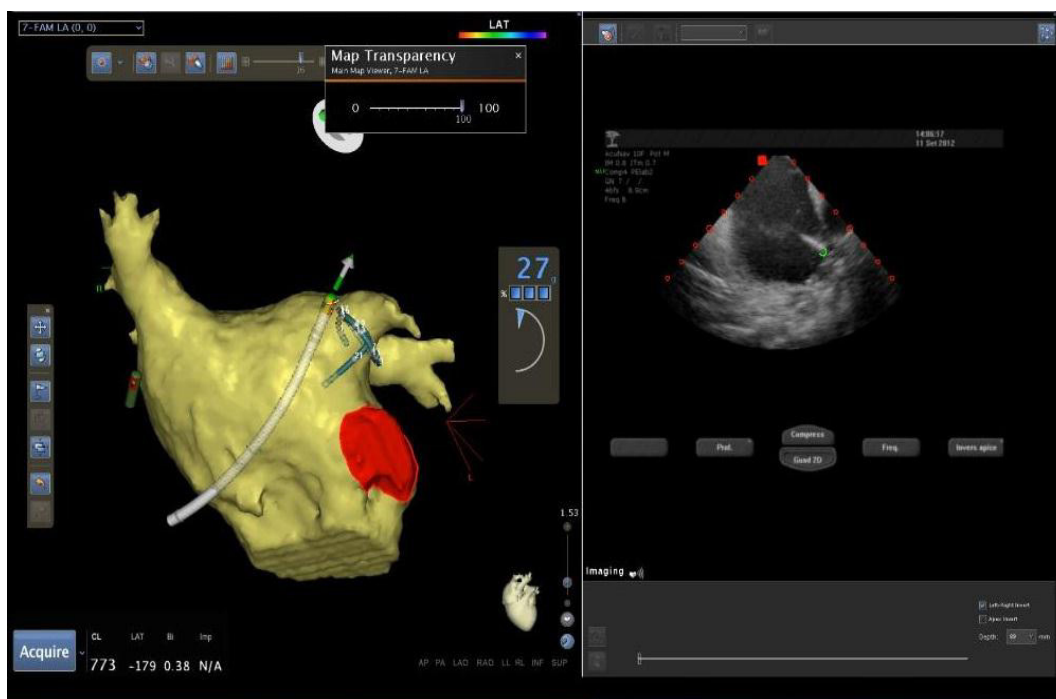

detection to avoid ineffective energy application.  
<sup>57</sup> The laser-balloon ablation system (EAS, Cardiofocus) is a catheter equipped with an endoscopic probe to assist the visualization of balloon-tissue contact. This feature could render redundant the use of ICE, although in previous small studies

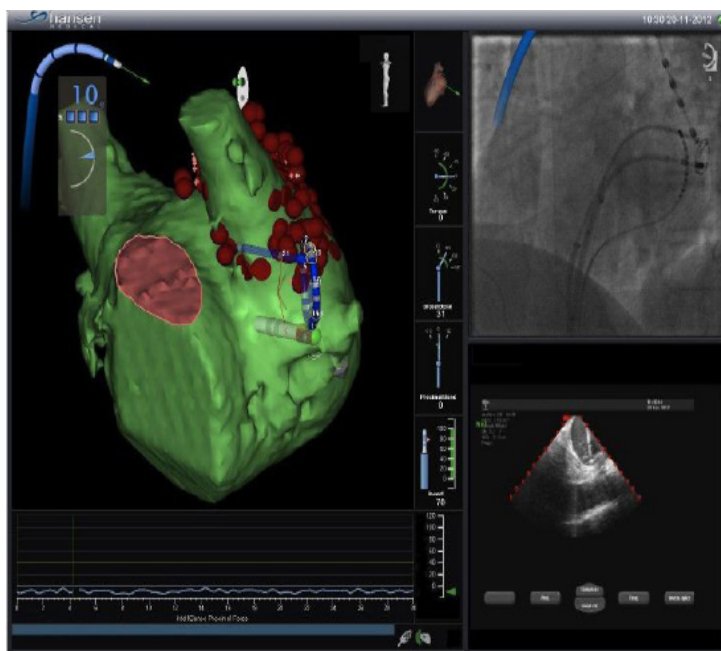
and in our experience the endoscope and ICE are complementary for positioning of the balloon at the LA-PV junction and for monitoring complications<sup>58-60</sup> (Figure 15).

Another important issue represented by the tissue

**Figure 16B:** Screen shot of the CARTO (Biosense Webster, Inc., Diamond Bar, Calif.) electroanatomical mapping system. On the right, in the ICE 2-D image, the green colored electronic representation of the catheter tip in left atrial chamber shows good contact to endocardial tissue. In the left panel high contact force confirmed good catheter tip-tissue contact

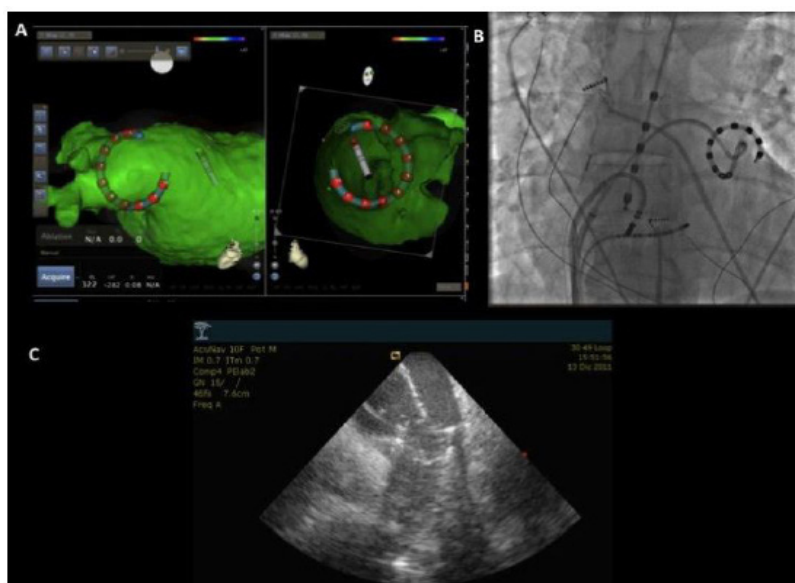


**Figure 17:** Screen shot of the Sensei robotic navigation system (Hansen Medical, Mountain View, Calif.) with CARTO system (Biosense Webster, Inc., Diamond Bar, Calif.) and the novel Smarttouch catheter (Biosense Webster, Inc., Diamond Bar, Calif.). Bottom right panel, in the ICE 2-D image, the ablation catheter and circular mapping catheter can be visualized in the antrum of LIPV. Top right panel, a left anterior oblique fluoroscopic view of the SmartTouch catheter catheter guided by Sensei robotic navigation system in the left atrium. Multipolar circular mapping and coronary sinus catheters are also shown. Left panel, 3-D CT image view showing left pulmonary veins. Radiofrequency applications (small red circles) were deployed at the posterior aspect of the ostium of the left superior pulmonary vein (LSPV). The ablation catheter tip is positioned at the ridge of the left inferior pulmonary vein (LIPV). The intelisense force and smarhtouch force in grams are similar

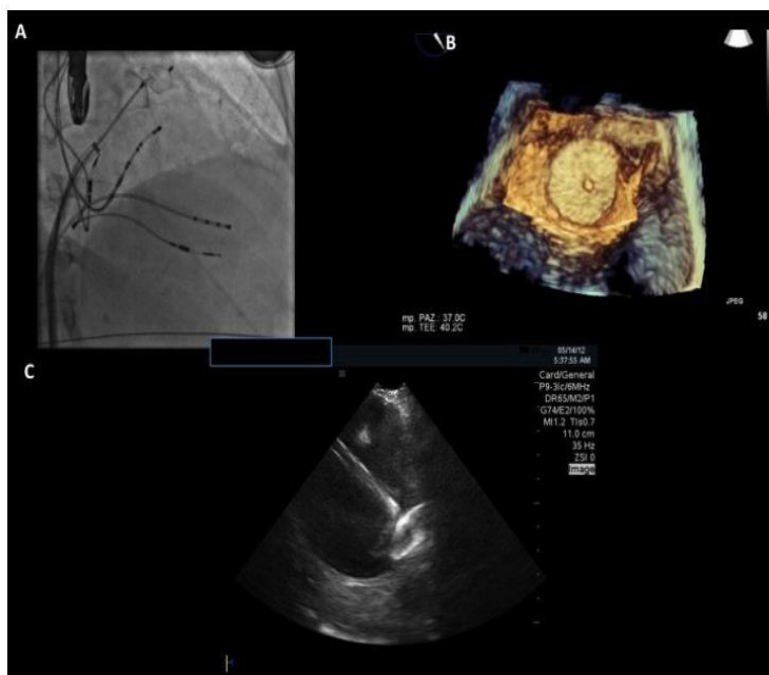


contact has been recently investigated: some Companies developed a reliable technology which can measure the contact force (CF) between the catheter tip and the target myocardium. Evidences from animal studies have shown that there is a strong correlation between CF and 2D ICE images of

**Figure 18:** Panel A: screen shot of the CARTO electroanatomical mapping system showing the nMARQ circular catheter (Biosense Webster, Inc., Diamond Bar, Calif.) in the antrum of the left pulmonary veins (LPVs). Panel B: anteroposterior fluoroscopic view with the nMARQ circular catheter in LPVs. Panel C: the intracardiac echocardiography (ICE)-derived 2D image of the left atrium confirms the position of the multielectrode ablation catheter.



**Figure 19:** Panel A: right anterior oblique view shows placement of a percutaneous left atrial appendage (LAA) device closure (Amplatzer Cardiac Plug, AGA Medical, SJM). Panel B: three dimensional transesophageal echocardiography reconstruction of left atrium and LAA orifice after device positioning. Panel C: intracardiac echocardiography 2D image showing the device placed in LAA



catheter tip/tissue contact.<sup>39</sup> In our experience ICE is very useful to validate appropriate contact and good orientation of these new ablation catheters, to monitor in real time the catheter-tissue interface during RF delivery and also to reduce fluoroscopy time (Figure 16a, 16b).

Another method of tackling the challenge of the dexterity required for AF ablation is remote navigation. Remote navigation technologies (Sensei Hansen robotic system) use standard ablation catheter technologies and deliver them in a unique way. The system equipped with a force-sensing technology, appears to be limited when the catheter is not perpendicular to the tissue. In our experience, the use of ICE with remote navigation system is helpful to confirm the catheter tip-to-tissue contact, since the contact force in this case is estimated by a sensor installed in the robotic arm, and detecting the resistance of the catheter sheath (Figure 17).

New technologies are rapidly becoming available to simplify AF ablation by allowing energy delivery in a circumferential fashion around PV ostia. Multielectrode ablation catheters (MACs), which have an array of electrodes, allow the operator to deliver

lesions throughout much of the circumference of each pulmonary vein during a single RF application. In this setting ICE could be used to properly position the MAC proximal to the anatomic PV ostia.<sup>61</sup> The additional use of ICE with MAC is associated with significantly lower fluoroscopy duration and RF delivery time.<sup>61,62</sup> Furthermore, a novel multielectrode irrigated ablation catheter (nMARQ Biosense Webster, Diamond Bar, Cal) integrated with an anatomical mapping system (CARTO 3 Biosense Webster, Diamond Bar, Cal), is being evaluated in a multicenter study (Revolution, ClinicalTrials.gov: NCT01353586). In our personal experience the combination of this technology with ICE has provided additional criteria for choosing correct position of the circular catheter in relation to PV ostia and to critical structures i.e carina region or ridge. (Figure 18)

A final important mention has to be dedicated to novel approaches for stroke prevention in Pts with AF, i.e. the left atrial appendage occlusion devices, which have provided a huge impact in the management of Pts with conflicting clinical patterns concerning the anticoagulation management. The two main systems are: 1) Watchman

(Boston Scientific; Natick MA) ; 2) Amplatzer Cardiac Plug (St Jude Inc.)

In both cases the International Guidelines as well as the recommendations of the Companies suggest the TEE-guidance as a gold standard technique for a correct device positioning<sup>63</sup> even if also alternative approaches have been described.<sup>64</sup> Our personal experience (evaluation of ICE performance in parallel with TEE) indicate the ICE as a useful and effective tool for: detection of LAA morphology and dimension; exclusion of thrombi; device measure choice; identification of criteria for a correct positioning including absence of leak, stability during tug test and absence of interference with the mitral leaflets (Figure 19). It is likely that in Pts with major contraindications to TEE this technology could represent a valid alternative for this promising approach to Pts with AF

## Conclusions

Based on a plenty of different applications, ICE is now a well-established technology in complex electrophysiological procedures, in particular in AF ablation. Catheter ablation has become very attractive and safe treatment modality with a potential benefit of definitive elimination of the arrhythmia. ICE contributes to improve the efficacy and safety of such procedures defining the anatomical structures involved in ablation procedures and monitoring in real time possible complications.

## Disclosures

- Dr. Di Biase is a consultant for Hansen Medical and Biosense Webster.
- Dr. Tondo is a member of the advisory boards of Medtronic and Biotronik; and receives lecture fees from St. Jude Medical, Medtronic and Biotronik.

## References

1. Calkins H, Kuck KH, Cappato R, Brugada J, Camm AJ, Chen SA, et al. HRS/EHRA/ECAS expert consensus statement on catheter and surgical ablation of atrial fibrillation: recommendations for patient selection, procedural techniques, patient management and follow-up, definitions, endpoints, and research trial design: a report of the Heart Rhythm Society (HRS) Task Force on Catheter and Surgical Ablation of Atrial Fibrillation. *Heart Rhythm*

2012; 9:632-696.

2. Wilber DJ, Pappone C, Neuzil C De Paola A, Marchlinski F, Natale A, et al., Comparison of antiarrhythmic drug therapy and radiofrequency catheter ablation in patients with paroxysmal atrial fibrillation: a randomized controlled trial, *JAMA* 2010; 4:333-340.

3. Wazni OM, Marrouche NF, Martin DO, Verma A, Bhargava M, Saliba W, et al., Radiofrequency ablation versus antiarrhythmic drugs as first-line treatment of symptomatic atrial fibrillation: a randomized trial, *JAMA* 2005; 21:2634-2640.

4. Pappone C, Augello G, Sala S, Gugliotta F, Vicedomini G, Gulletta S, et al. A randomized trial of circumferential pulmonary vein ablation versus antiarrhythmic drug therapy in paroxysmal atrial fibrillation: the APAF Study, *JACC* 2006;11:2340-7.

5. Biermann J, Bode C, Asbach S. Intracardiac Echocardiography during Catheter-Based Ablation of Atrial Fibrillation. *Cardiol Res Pract* 2012.

6. Issa Z, Miller JM, Zipes DP. Advanced Mapping and Navigation Modalities. In: Issa Z, Miller JM, Zipes DP. *Clinical Arrhythmology and Electrophysiology: A Companion to Braunwald's Heart Disease*. 2nd Ed., Saunders W.B. 2012; 133-136.

7. Banchs JE, Patel P, Naccarelli GV, Gonzalez MD. Intracardiac echocardiography in complex cardiac catheter ablation procedures. *JICE* 2010;3:167-84

8. Saad EB, Costa IP, Camanho LE. Use of intracardiac echocardiography in the electrophysiology laboratory. *Arq Bras Cardiol* 2011;1:e11-7.

9. Khaykin Y, Skanes A, Champagne J, Themistoclakis S, Gula L, Rossillo A, et al. A randomized controlled trial of the efficacy and safety of electroanatomic circumferential pulmonary vein ablation supplemented by ablation of complex fractionated atrial electrograms versus potential-guided pulmonary vein antrum isolation guided by intracardiac ultrasound. *Circ Arrhythm Electrophysiol* 2009;5:481-7.

10. Pratola C, Baldo E, Artale P, Marcantoni L, Toselli T, Perco G, et al. Different image integration modalities to guide AF ablation: impact on procedural and fluoroscopy times. *PACE* 2011;4:422-30.

11. Dello Russo A, Casella M, Pelargonio G, Bonelli F, Santangeli P, Fassini G, et al. Intracardiac echocardiography in electrophysiology. *Minerva Cardioangiol* 2010;3:333-42.

12. Catanzariti D, Maines M, Angheben C, Centonze M, Cemin C, Vergara G, et al. Usefulness of Contrast Intracardiac Echocardiography in Performing Pulmonary Vein Balloon Occlusion during Cryo-ablation for Atrial Fibrillation. *Indian Pacing Electrophysiol. J.* 2012 Epub.

13. Nölker G, Heintze J, Gutleben KJ, Muntean B, Pütz V, Yalda A, et al. Cryoballoon pulmonary vein isolation supported by intracardiac echocardiography: integration of a nonfluoroscopic imaging technique in atrial fibrillation ablation. *JCE* 2010;12:1325-30.

14. Schmidt M, Daccarett M, Marschang H, Ritscher G, Turschner O, Brachmann J, et al. Intracardiac echocardiography improves procedural efficiency during cryoballoon ablation for atrial fibrillation: a pilot study. *J Cardiovasc Electrophysiol* 2010;11:1202-7.



15. Ferguson JD, Helms A, Mangrum JM, Mahapatra S, Mason P, Bilchick K, et al. Catheter ablation of atrial fibrillation without fluoroscopy using intracardiac echocardiography and electroanatomic mapping. *Circ Arrhythm Electrophysiol* 2009;6:611-9
16. Reddy VY, Morales G, Ahmed H, Neuzil P, Dukkipati S, Kim S, et al. Catheter ablation of atrial fibrillation without the use of fluoroscopy. *Heart Rhythm* 2010;11:1644-53.
17. Ren J, Marchlinski F: Intracardiac echocardiography: basic concepts. In Ren JF, Marchlinski FE, Callans DJ, Schwartzman S, editors: *Practical intracardiac echocardiography in electrophysiology*, Malden, Mass., 2006, Blackwell Futura, 1-4.
18. McLaughlin G. ZONE Sonography™: What It Is and How It's Different. <http://cdn.zonare.com/0d87056c5a4bae2587f9710a5d669d33.pdf>
19. Mark J Earley. How to perform a transseptal puncture. *Heart* 2009; 95: 85-92.
20. De Ponti R, Cappato R et al. Transseptal catheterization in the electrophysiology laboratory: data from a multicenter survey spanning 12 years. *JACC* 2006; 47: 1037-42
21. Saliba W, Thomas J. Intracardiac echocardiography during catheter ablation of atrial fibrillation. *Europace*. 2008; 10 (Suppl 3).
22. Biermann J, Bode C, Asbach S. Intracardiac echocardiography during catheter-based ablation of atrial fibrillation. *Cardiol Res Pract* 2012; 1-8.
23. Lakkireddy D, Rangisetty U, Prasad S, Verma A, Biria M, Berenbom L et al. Intracardiac echo-guided radiofrequency catheter ablation of atrial fibrillation in patients with atrial septal defect or patent foramen ovale repair: a feasibility, safety, and efficacy study. *JCE* 2008;11:1137-42.
24. Santangeli P, Di Biase L, Burkhardt JD, Horton R, Sanchez J, Bailey S, et al. Transseptal access and atrial fibrillation ablation guided by intracardiac echocardiography in patients with atrial septal closure devices. *Heart Rhythm*. 2011;11:1669-75.
25. Bhatia NL, Humphries J, Chandrasekaran K, Srivathsan K. Atrial fibrillation ablation in cor triatriatum: value of intracardiac echocardiography. *JICE* 2010;2:153-5.
26. Peichl P, Kautzner J, Gebauer R. Ablation of atrial tachycardias after correction of complex congenital heart diseases: utility of intracardiac echocardiography. *Europace*. 2009;1:48-53.
27. Mitchell-Heggs L, Lellouche N, Deal L, Elbaz N, Hamdaoui B, Castanié JB, et al. Transseptal puncture using minimally invasive echocardiography during atrial fibrillation ablation. *Europace*. 2010;10:1435-8.
28. Ferguson JD, Helms A, Mangrum JM, Mahapatra S, Mason P, Bilchick K, Catheter ablation of atrial fibrillation without fluoroscopy using intracardiac echocardiography and electroanatomic mapping. *Circ Arrhythm Electrophysiol* 2009;6:611-9.
29. Winkle RA, Mead RH, Engel G, Patrawala RA. The use of a radiofrequency needle improves the safety and efficacy of transseptal puncture for atrial fibrillation ablation. *Heart Rhythm*. 2011;9:1411-5.
30. Casella M, Dello Russo A, Pelargonio G, Martino A, De Paulis S, Zecchi P et al. Fossa ovalis radiofrequency perforation in a difficult case of conventional transseptal puncture for atrial fibrillation ablation. *JICE* 2008;3:249-53.
31. De Ponti R, Marazzi R, Picciolo G, Salerno-Uriarte JA. Use of a novel sharp-tip, J-shaped guidewire to facilitate transseptal catheterization. *Europace* 2010;5:668-73.
32. Fagundes RL, Mantica M, De Luca L, Forleo G, Pappalardo A, Avella A, Fraticelli A, Dello Russo A, Casella M, Pelargonio G, Tondo C. "Safety of single transseptal puncture for ablation of atrial fibrillation: retrospective study from a large cohort of patients". *J Cardiovasc Electrophysiol* 2007;18:1277-1281.
33. Singh SM, Heist EK, Donaldson DM, Collins RM, Chevalier J, Mela T, et al. Image integration using intracardiac ultrasound to guide catheter ablation of atrial fibrillation. *Heart Rhythm*. 2008;11:1548-55.
34. den Uijl DW, Tops LF, Tolosana JM, Schuijff JD, Trines SA, Zeppenfeld K, et al. Real-time integration of intracardiac echocardiography and multislice computed tomography to guide radiofrequency catheter ablation for atrial fibrillation. *Heart Rhythm*. 2008;10:1403-10.
35. Khaykin Y, Klemm O, Verma A. First human experience with real-time integration of intracardiac echocardiography and 3D electroanatomical imaging to guide right free wall accessory pathway ablation. *Europace* 2008;1:116-7.
36. Zhong H, Lacomis JM, Schwartzman D: On the accuracy of CartoMerge for guiding posterior left atrial ablation in man. *Heart Rhythm* 2007;4:595-602.
37. Rossillo A, Indiani S, Bonso A, Themistoclakis S, Corrado A, Raviele A. Novel ICE-guided registration strategy for integration of electroanatomical mapping with three-dimensional CT/MR images to guide catheter ablation of atrial fibrillation. *J Cardiovasc Electrophysiol*. 2009;4:374-8.
38. Pratola C, Baldo E, Artale P, Marcantoni L, Toselli T, Percoco G et al. Different image integration modalities to guide AF ablation: impact on procedural and fluoroscopy times. *PACE* 2011;4:422-30.
39. Okumura Y, Johnson SB, Bunch TJ, Henz BD, O'Brien CJ, Packer DL, A systematical analysis of in vivo contact forces on virtual catheter tip/tissue surface contact during cardiac mapping and intervention. *JCE* 2008;6:632-40.
40. Hoyt H, Bhonsale A, Chilukuri K, Alhumaid F, Needleman M, Edwards D, et al. Complications arising from catheter ablation of atrial fibrillation: temporal trends and predictors. *Heart Rhythm* 2011; 8: 1869-1874
41. Aldhoon B, Wichterle D, Peichl P, Cihák R, Kautzner J. Complications of catheter ablation for atrial fibrillation in a high-volume center with the use of intracardiac echocardiography. *Europace* 2012. [Epub ahead of print]
42. Baman TS, Jongnarangsin K, Chugh A, Suwanagool A, Guiot A, Madenci A et al. Prevalence and predictors of complications of radiofrequency catheter ablation for atrial fibrillation. *JCE* 2011;6:626-31.
43. Dagues N, Hindricks G, Kottkamp H, Sommer P, Gaspar T, Bode K, et al. Complications of atrial fibrillation ablation in a high-volume center in 1,000 procedures: still cause for concern? *J Cardiovasc Electrophysiol*. 2009;9:1014-9
44. Ren JF, Marchlinski FE, Supple GE, Hutchinson MD, Garcia FC, Riley MP et al. Intracardiac Echocardiographic Diagnosis of Thrombus Formation in the Left Atrial Appendage: A Comple-

mentary Role to Transesophageal Echocardiography. *Echocardiography* 2012; [Epub ahead of print]

45. Ren JF, Marchlinski FE, Callans DJ. Left atrial thrombus associated with ablation for atrial fibrillation: identification with intracardiac echocardiography. *JACC* 2004;10:1861-7.

46. Dravid SG, Hope B, McKinnie JJ. Intracardiac echocardiography in electrophysiology: a review of current applications in practice. *Echocardiography* 2008;10:1172-5.

47. Ren JF, Marchlinski FE. Utility of intracardiac echocardiography in left heart ablation for tachyarrhythmias. *Echocardiography*. 2007;5:533-40.

48. Helms A, West JJ, Patel A, Mounsey JP, DiMarco JP, Mangrum JM et al. Real-time rotational ICE imaging of the relationship of the ablation catheter tip and the esophagus during atrial fibrillation ablation. *JCE* 2009;2:130-7.

49. Leite LR, Santos SN, Maia H, Henz BD, Giuseppin F, Oliveira A, et al. Luminal esophageal temperature monitoring with a deflectable esophageal temperature probe and intracardiac echocardiography may reduce esophageal injury during atrial fibrillation ablation procedures: results of a pilot study. *Circ Arrhythm Electrophysiol* 2011;2:149-56.

50. Verma A, Kilicaslan F, Pisano E, Marrouche NF, Fanelli R, Brachmann J, et al. Response of atrial fibrillation to pulmonary vein antrum isolation is directly related to resumption and delay of pulmonary vein conduction. *Circulation*. 2005;5:627-35.

51. Koller ML, Schumacher B. Cryoballoon ablation of paroxysmal atrial fibrillation: bigger is better and simpler is better. *Eur Heart J* 2009;6:636-7.

52. Marrouche NF, Martin DO, Wazni O, Gillinov AM, Klein A, Bhargava M, et al. Phased-array intracardiac echocardiography monitoring during pulmonary vein isolation in patients with atrial fibrillation: impact on outcome and complications. *Circulation*. 2003;21:2710-6.

53. Verma A, Marrouche NF, Natale A. Pulmonary vein antrum isolation: intracardiac echocardiography-guided technique. *J Cardiovasc Electrophysiol*. 2004;11:1335-40.

54. Schmidt M, Daccarett M, Marschang H, Ritscher G, Turschner O, Brachmann J et al. Intracardiac echocardiography improves procedural efficiency during cryoballoon ablation for atrial fibrillation: a pilot study. *J Cardiovasc Electrophysiol*. 2010;11:1202-7

55. Nölker G, Heintze J, Gutleben KJ, Muntean B, Pütz V, Yalda A, et al. Cryoballoon pulmonary vein isolation supported by intracardiac echocardiography: integration of a nonfluoroscopic imaging technique in atrial fibrillation ablation. *J Cardiovasc Electrophysiol*. 2010;12:1325-30.

56. Catanzariti D, Maines M, Angheben C, Centonze M, Cemin C, Vergara G. Usefulness of Contrast Intracardiac Echocardiography in Performing Pulmonary Vein Balloon Occlusion during Cryo-ablation for Atrial Fibrillation. *Indian Pacing Electrophysiol. J.* 2012. [Epub ahead of print]

57. Leite L, Su W, Johnson SB, Milton M, Henz B, Sarabanda A, et al. Utility of intracardiac ultrasound imaging to guide pulmonary vein ablation using laser balloon catheter. *Arq Bras Cardiol*. 2009;6:616-21,

58. Themistoclakis S, Wazni OM, Saliba W, Schweikert RA, Bonso A, Rossillo A, et al. Endoscopic fiberoptic assessment of bal-

loon occlusion of the pulmonary vein ostium in humans: comparison with phased-array intracardiac echocardiography. *Heart Rhythm*. 2006;1:44-9.

59. Phillips KP, Schweikert RA, Saliba WI, Themistoclakis S, Raviele A, Bonso A et al. Anatomic location of pulmonary vein electrical disconnection with balloon-based catheter ablation. *J Cardiovasc Electrophysiol*. 2008;1:14-8

60. Reddy VY, Neuzil P, d'Avila A, Laragy M, Malchano ZJ, Kralovec S, et al. Balloon catheter ablation to treat paroxysmal atrial fibrillation: what is the level of pulmonary venous isolation? *Heart Rhythm*. 2008;3:353-60.

61. Khaykin Y, Zarnett L, Friedlander D, Wulffhart ZA, Whaley B, Giewercer D et al. Point-by-point pulmonary vein antrum isolation guided by intracardiac echocardiography and 3D mapping and duty-cycled multipolar AF ablation: effect of multipolar ablation on procedure duration and fluoroscopy time. *JICE* 2012;3:303-10.

62. Herrera Siklódy C, Deneke T, Hocini M, Lehrmann H, Shin DI, Miyazaki S. et al. Incidence of asymptomatic intracranial embolic events after pulmonary vein isolation: comparison of different atrial fibrillation ablation technologies in a multicenter study. *JACC* 2011 9;7:681-8.

63. Landmesser U, Holmes Jr DR. Left atrial appendage closure: a percutaneous transcatheter approach for stroke prevention in atrial fibrillation. *Eur Heart J* (2012) 33 (6): 698-704.

64. Guérios E, Schmid M, Gloekler S, Khattab A A, Wenaweser P, Windecker S, Meier B. Left atrial appendage closure with the Amplatzer Cardiac Plug in patients with atrial fibrillation. *Arq Bras Cardiol*. 2012 (online, ahead of print).