

Retrospective Study

Reporting rotator cuff tears on magnetic resonance arthrography using the Snyder's arthroscopic classification

Alberto Aliprandi, Carmelo Messina, Paolo Arrigoni, Michele Bandirali, Giovanni Di Leo, Stefano Longo, Sandro Magnani, Chiara Mattiuz, Filippo Randelli, Silvana Sdao, Francesco Sardanelli, Luca Maria Sconfienza, Pietro Randelli

Alberto Aliprandi, Michele Bandirali, Giovanni Di Leo, Silvana Sdao, Francesco Sardanelli, Servizio di Radiologia, IRCCS Policlinico San Donato, 20097 San Donato Milanese, Italy

Carmelo Messina, Sandro Magnani, Chiara Mattiuz, Scuola di Specializzazione in Radiodiagnostica, Università degli Studi di Milano, 20122 Milano, Italy

Paolo Arrigoni, Unità Operativa di Ortopedia e Traumatologia II, IRCCS Policlinico San Donato, 20097 San Donato Milanese, Italy

Stefano Longo, Francesco Sardanelli, Luca Maria Sconfienza, Pietro Randelli, Dipartimento di Scienze Biomediche per la Salute, Università degli Studi di Milano, 20139 Milano, Italy

Filippo Randelli, Unità Operativa di Ortopedia e Traumatologia V, IRCCS Policlinico San Donato, 20097 San Donato Milanese, Italy

Luca Maria Sconfienza, Unità Operativa di Radiologia/Diagnostica per Immagini con Servizio di Radiologia Interventistica, IRCCS Istituto Ortopedico Galeazzi, 20161 Milano, Italy

Pietro Randelli, Unità Operativa Complessa, I Divisione, Istituto Ortopedico Gaetano Pini, 20122 Milano, Italy

Author contributions: Aliprandi A, Arrigoni P, Randelli F, Sardanelli F and Randelli P designed the research and substantially contributed to study conception; Messina C, Bandirali M, Magnani S, Mattiuz C and Sdao S acquired the data and performed the research; Di Leo G and Longo S contributed to study design and data interpretation/analysis; Messina C, Bandirali M, Magnani S, Mattiuz C and Sdao S drafted the article; Aliprandi A, Arrigoni P, Randelli F, Sardanelli F and Sconfienza LM made critical revision related to important content of the manuscript; all authors approved the final version of the manuscript to be published.

Institutional review board statement: The study was

reviewed and approved by the Comitato Etico ASL Milano Due Institutional Review Board.

Informed consent statement: Informed consent was waived from Institutional Review Board.

Conflict-of-interest statement: All authors declare no conflicts of interest.

Data sharing statement: Technical appendix, statistical code, and dataset available from the corresponding author at (io@lucasconfienza.it). Consent was not obtained but the presented data are anonymized and risk of identification is low.

Open-Access: This article is an open-access article which was selected by an in-house editor and fully peer-reviewed by external reviewers. It is distributed in accordance with the Creative Commons Attribution Non Commercial (CC BY-NC 4.0) license, which permits others to distribute, remix, adapt, build upon this work non-commercially, and license their derivative works on different terms, provided the original work is properly cited and the use is non-commercial. See: <http://creativecommons.org/licenses/by-nc/4.0/>

Manuscript source: Invited manuscript

Correspondence to: Dr. Luca Maria Sconfienza, Dipartimento di Scienze Biomediche per la Salute, Università degli Studi di Milano, Via Mangiagalli 31, 20139 Milano, Italy. io@lucasconfienza.it
Telephone: +39-02-66214497

Received: August 24, 2016

Peer-review started: August 24, 2016

First decision: October 20, 2016

Revised: December 12, 2016

Accepted: January 2, 2017

Article in press: January 3, 2017

Published online: March 28, 2017

Abstract

AIM

To determine diagnostic performance of magnetic resonance arthrography (MRA) in evaluating rotator cuff tears (RCTs) using Snyder's classification for reporting.

METHODS

One hundred and twenty-six patients (64 males, 62 females; median age 55 years) underwent shoulder MRA and arthroscopy, which represented our reference standard. Surgical arthroscopic reports were reviewed and the reported Snyder's classification was recorded. MRA examinations were evaluated by two independent radiologists (14 and 5 years' experience) using Snyder's classification system, blinded to arthroscopy. Agreement between arthroscopy and MRA on partial- and full-thickness tears was calculated, first regardless of their extent. Then, analysis took into account also the extent of the tear. Interobserver agreement was also calculated the quadratically-weighted Cohen kappa statistics.

RESULTS

On arthroscopy, 71/126 patients (56%) had a full-thickness RCT. The remaining 55/126 patients (44%) had a partial-thickness RCT. Regardless of tear extent, out of 71 patients with arthroscopically-confirmed full-thickness RCTs, 66 (93%) were correctly scored by both readers. All 55 patients with arthroscopic diagnosis of partial-thickness RCT were correctly assigned as having a partial-thickness RCT at MRA by both readers. Interobserver reproducibility analysis showed total agreement between the two readers in distinguishing partial-thickness from full-thickness RCTs, regardless of tear extent ($k = 1.000$). With regard to tear extent, in patients in whom a complete tear was correctly diagnosed, correct tear extent was detected in 61/66 cases (92%); in the remaining 5/66 cases (8%), tear extent was underestimated. Agreement was $k = 0.955$. Interobserver agreement was total ($k = 1.000$).

CONCLUSION

MRA shows high diagnostic accuracy and reproducibility in evaluating RCTs using the Snyder's classification for reporting. Snyder's classification may be adopted for routine reporting of MRA.

Key words: Arthroscopy; Magnetic resonance imaging; Shoulder; Arthrography; Supraspinatus tendon; Rotator cuff tear

© The Author(s) 2017. Published by Baishideng Publishing Group Inc. All rights reserved.

Core tip: In the present study we determined the diagnostic performance of magnetic resonance arthrography (MRA) in evaluating rotator cuff tears (RCTs) using Snyder's classification for reporting. One hundred and twenty-six patients underwent MRA and arthroscopy, which represented our reference standard. Agreement between arthroscopy and MRA on partial- and full-

thickness tears was calculated. Arthroscopy findings: 71/126 patients (56%) had a full-thickness RCTs, while 55/126 patients (44%) had a partial-thickness RCTs. MRA showed high diagnostic accuracy and reproducibility in evaluating RCTs using the Snyder's classification for reporting. Snyder's classification may be adopted for routine reporting of MRA.

Aliprandi A, Messina C, Arrigoni P, Bandirali M, Di Leo G, Longo S, Magnani S, Mattiuz C, Randelli F, Sdao S, Sardanelli F, Sconfienza LM, Randelli P. Reporting rotator cuff tears on magnetic resonance arthrography using the Snyder's arthroscopic classification. *World J Radiol* 2017; 9(3): 126-133 Available from: URL: <http://www.wjgnet.com/1949-8470/full/v9/i3/126.htm> DOI: <http://dx.doi.org/10.4329/wjr.v9.i3.126>

INTRODUCTION

The shoulder joint is a complex anatomic structure consisting of static and dynamic stabilizers, which confers functional stability and high degree of mobility at the same time^[1]. Rotator cuff (RC) acts as a dynamic stabilizer contributing to shoulder stability: It consists of four muscles (supraspinatus, subscapularis, infraspinatus and teres minor), which tendons fuse to form a continuous structure near their insertions. Together with long head of biceps tendon, RC tendons create an ideal configuration to actively compress the humeral head into the glenoid's cavity^[2]. Nevertheless, due to the glenohumeral joint high-grade of mobility, RC tears (RCTs) are commonly encountered, implying shoulder pain and dysfunction, often associated with loss of biomechanical balance and instability and subacromial impingement^[3,4]. The prevalence of full-thickness RCTs is almost 25% of individuals in their 60s and 50% of individuals in their 80s, with the supraspinatus being the most frequently involved tendon^[5].

Both ultrasound and magnetic resonance imaging (MRI) are accurate techniques in identifying shoulder pathologic conditions and RCTs^[6,7]. Magnetic resonance arthrography (MRA) has been shown to improve diagnostic performance of conventional MRI, as contrast material distends the joint capsule and outlines intra-articular structures; thus, MRA is particularly useful for RC partial-thickness tears as well as labrum and glenohumeral ligament tears and degeneration^[7,8].

Several orthopaedic classifications of RCTs were proposed throughout years. In 1934, Codman^[9] described the development of supraspinatus partial-thickness tears. In 1983, Neer^[10] classified RCTs into three progressive stages of impingement. In 1984, DeOrio and Cofield^[11] used the length of the greatest diameter of the tear to categorize the tear in four degrees. In 1990, Ellman^[12] further developed the classification of Neer, popularizing for the first time a system to classify partial thickness tears based on intra-operative findings. Recently, Davidson and Burkhart^[13] developed a geometric classification system

Table 1 Snyder's classification of rotator cuff tears

Location	
A	Articular side
B	Bursal side
C	Full-thickness tears, connecting A and B sides
Severity of partial tears (A and B side)	
0	Normal cuff, with smooth coverings of synovium and bursa
1	Minimal, superficial bursal or synovial irritation or slight capsular fraying in a small, localized area; usually < 1 cm
2	Actually fraying and failure of some rotator cuff fibres in addition to synovial, bursal, or capsular injury; usually < 2 cm
3	More severe rotator cuff injury, including fraying and fragmentation of tendons fibers, often involving the whole surface of a cuff tendon; usually < 3 cm
4	Very severe partial rotator cuff tear that usually contains, in addition to fraying and fragmentation of tendon tissue, a sizable flap tear and often encompasses more than a single tendon
Severity of complete tears (C)	
1	Small, complete tear, such as a puncture wound
2	Moderate tear, (usually < 2 cm) that still encompasses only one of the rotator cuff tendons with no retraction of the torn ends
3	Large, complete tear involving an entire tendon with minimal retraction of the torn edge; usually 3 to 4 cm
4	Massive rotator cuff tear involving two or more rotator cuff tendons, frequently with associated retraction and scarring of the remaining tendon

Modified from Millstein and Snyder^[16].

based on pre-operative (MRI)^[14]. At our institution, shoulder orthopaedic surgeons use the Snyder's arthroscopic classification of RCTs, which includes three parameters: The location of the lesion, the extent of the lesion, *i.e.*, partial-thickness or full-thickness - and the number of involved tendons (Table 1)^[15,16]. In particular, Snyder's classification separates RCTs into articular-sided, bursal-sided, and complete tears.

Despite many orthopaedic classifications, these never entered into radiological practice and radiologists still descriptively report tears of the RC^[17]. A recent study from Bosmans *et al*^[18] showed that, although radiology report remains an indispensable tool for medical practice, there is still a consistent percentage of referring physicians that remains unsatisfied with them. In fact, communication is a critical aspect when providing medical care, and a discrepancy in the language used between physicians (*i.e.*, radiologists and orthopaedic surgeons) may not convey the correct message and generate confusion^[19]. Thus, the aim of our study was to evaluate the diagnostic performance of MRA in evaluating RCTs using the Snyder's classification system for reporting MRA findings, having arthroscopy as reference standard.

MATERIALS AND METHODS

Study population and design

This retrospective study was reviewed and approved by the Institutional Review Board (Comitato Etico ASL Milano Due) and patients' informed consent was waived. Between June 2006 and December 2013, a series of 1324 consecutive shoulder MRA were performed at our institution in patients presenting with pain and functional limitation of the shoulder. From this database, we selected all patients who underwent arthroscopic surgery at our Institution, for a total of 126 patients (64 males and 62 females; age range 15-79 years; median age 55

years; 25th-75th percentile 38-63 years). Inclusion criteria for the study were: (1) MRA performed at our Institution following a standardised protocol; and (2) surgery performed at our Institution.

MRA - ultrasound-guided intra-articular injection of contrast material

Intra-articular injection of contrast agent was performed under ultrasound-guidance using a high frequency probe with anterior approach, as described by Sconfienza *et al*^[20] and Messina *et al*^[21]. Patients were positioned supine with the shoulder under investigation slightly extra-rotated, with the arm outstretched along the body. After careful skin disinfection, a 19-G needle was introduced in the joint and contrast material was injected. The procedure ended after injection of up to 20 mL of 0.0025 mmol/mL of gadoterate meglumine (Gd-DOTA, Dotarem pre-filled syringes; Guerbet, Paris, France). After injection, patient's arm was gently intra and extra-rotated for better contrast distribution into the joint capsule.

MRA - image acquisition

MRA was performed within 10 min from contrast agent injection using a 1.5-T system (Magnetom Sonata Maestro Class, Siemens Medical Solution, Erlangen, Germany) equipped with a 40 mT/m gradient power and a dedicated phased-array surface coil. The following imaging protocol was acquired: 3 plane (axial, coronal oblique and sagittal oblique) turbo spin-echo T1-weighted fat-saturated sequences (TR/TE = 763/15 ms; slice thickness = 4 mm; FOV = 190 mm × 190 mm; matrix = 256 × 256); oblique coronal turbo spin-echo T2-weighted fat-saturated sequences (TR/TE = 4000/74 ms; slice thickness = 4 mm with 0.8-mm interslice gap; FOV = 240 mm × 240 mm; matrix = 256 × 256); three-dimensional dual echo steady state (3D-DESS, TR/TE = 17/6 ms, slice thickness = 0.8 mm, voxel = 0.8 mm × 0.8

Table 2 Adaptation to magnetic resonance arthrography of arthroscopic Snyder's classification of rotator cuff partial tears

Lesion's grade	Severity of partial tears (A or B lesion)
1	Subtle irregularities of the tendon surface with preserved thickness
2	Major irregularities of the tendon surface with preserved thickness
3	Lesions involve less than 50% of tendon diameter and lesion extension is less than 3 cm
4	Lesions involve more than 50% of tendon's diameter with an extension of more than 3 cm or the lesion involves two tendons

A: Articular side; B: Bursal side.

Table 3 Distribution of lesion severity degree on articular and bursal sides of 55 patients with a partial rotator cuff tear at the arthroscopic assessment

		Articular side tear				
		A0	A1	A2	A3	A4
Bursal side tear	B0	-	1	1	2	1
	B1	3	8	0	0	0
	B2	4	5	5	3	1
	B3	0	0	1	5	2
	B4	0	0	0	1	12

A: Articular side; B: Bursal side.

mm × 0.8 mm).

Imaging evaluation and RCTs classification

As a pilot attempt to classify RCTs using Snyder's classification, in the present study we only considered RCTs involving the supraspinatus tendon. The Snyder's arthroscopic classification (Table 1) was used as reference for evaluating complete tears. For partial-thickness tears, the Snyder's classification was modified according to what reported in Table 2. Images were reviewed by two independent radiologists with 14 (reader 1) and 5 years' (reader 2) experience in musculoskeletal MRA, respectively, blinded to arthroscopic findings.

Surgical classification of RCTs

Arthroscopy was performed by one of three orthopaedic surgeons with 5 to 17 years' experience in shoulder arthroscopy. Surgical reports were reviewed and the reported Snyder's classification was recorded.

Statistical analysis

For analysis of lesion extent accuracy, data obtained by the most experienced reader (reader 1) was used and compared to reference standard. We calculated first the agreement between arthroscopy and MRA on partial- and full-thickness tears, regardless of their extent. Then, we performed a deeper analysis taking into account also the extent of the tear, still separately for partial- and full-thickness tears. Interobserver agreement was also calculated the quadratically-weighted Cohen kappa statistics was used.

RESULTS

Reference standard

Arthroscopy was performed after a median of 137 d

Table 4 Data regarding the 5 patients with a complete tear at the reference standard assigned with a partial score at the magnetic resonance arthrography by the most experienced reader (reader 1)

Reader 1		Reference standard
Articular side	Bursal side	Complete tear
A 2	B 1	C 1
A 3	B 4	C 1
A 2	B 3	C 1
A 4	B 4	C 1
A 4	B 4	C 1

A: Articular side; B: Bursal side.

from MRA (25th-75th percentile 72-211 d). At arthroscopic assessment, 71/126 patients (56%) had a full-thickness RCT with different severity grade: C1, $n = 27$; C2, $n = 25$; C3, $n = 15$; C4, $n = 4$. The remaining 55/126 patients (44%) had a partial-thickness RCT. Distribution of the articular and bursal location of the tear is reported in Table 3 according to the most experienced reader (reader 1).

Accuracy vs the reference standard regardless of tear extent

Out of 71 patients with arthroscopically-confirmed full-thickness RCTs, 66 (93%) were correctly scored by both readers; in the remaining 5 patients (7%), both readers assigned a partial-thickness tear instead of a full-thickness tear. Table 4 shows data about the 5 patients with a complete tear at arthroscopy who were assigned with a partial score by the most experienced reader (reader 1). Figures 1-3 show MRA findings and corresponding arthroscopic confirmation.

All 55 patients with arthroscopic diagnosis of partial-thickness tear were correctly assigned as having a partial-thickness tear at MRA by both readers (Figure 3).

Interobserver reproducibility analysis showed total agreement between the two readers in distinguishing partial-thickness from full-thickness RCTs, regardless of tear extent ($k = 1.000$).

Accuracy vs the reference standard considering tear extent

In patients in whom a complete tear was correctly diagnosed, correct tear extent was detected in 61/66 cases (92%); in the remaining 5/66 cases (8%), tear extent was underestimated, as both readers assigned C1 instead of C2. Agreement with arthroscopy was $k = 0.955$.

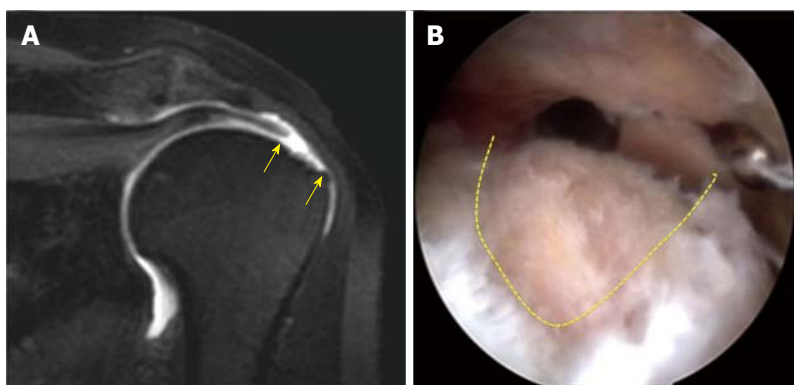


Figure 1 Magnetic resonance arthrography of a C2 lesion of the supraspinatus tendon. A: MRA, coronal TSE T1w fat sat. Full tear with fiber retraction of supraspinatus tendon. Yellow arrows show the bare area of foot print lesion (C2 lesion according to Snyder classification); B: Arthroscopic view. Dotted line shows the crescent shape lesion. MRA: Magnetic resonance arthrography.

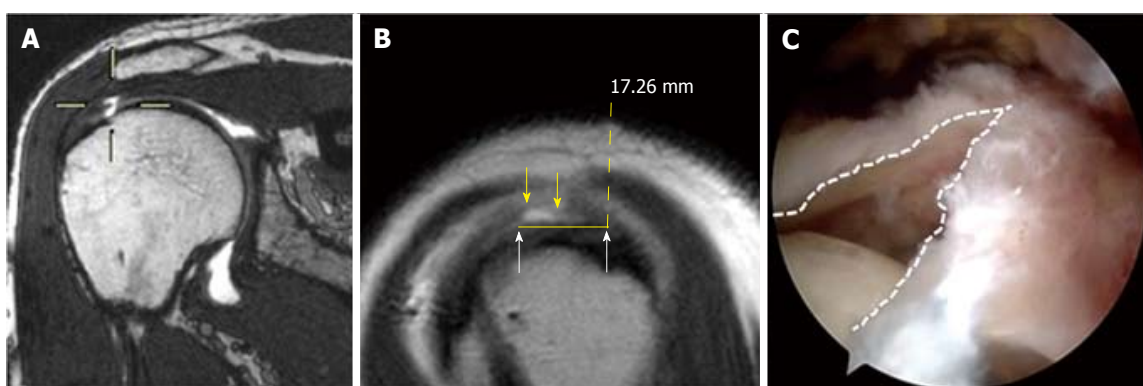


Figure 2 Magnetic resonance arthrography of a C1 tear of the supraspinatus tendon. A: MRA coronal, double echo steady state. Viewfinder shows the hyperintense signal in supraspinatus tendon, expression of full tear (C1 lesion according to Snyder classification); B: MRA Sagittal TSE T1w. Yellow arrows show the full tear (C1 lesion according to Snyder classification). White arrows show the degenerative tendon matrix, later removed by the surgeon; C: Arthroscopic view. White dotted line show a full, V-shape, tear of supraspinatus tendon completed to C2 according to Snyder classification by the surgeon. MRA: Magnetic resonance arthrography.

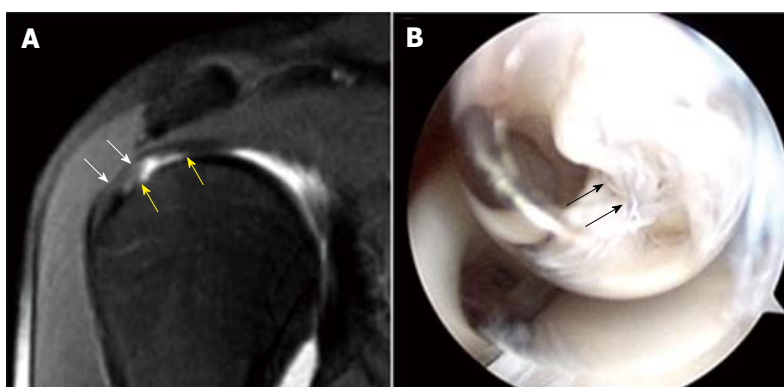


Figure 3 Magnetic resonance arthrography and arthroscopy of an A4 tear of the supraspinatus tendon. A: MRA, coronal TSE T1w fat sat. The yellow arrows show the articular asymmetric profile, expression of erosion and partial tear of supraspinatus tendon (A4 lesion according to Snyder classification). White arrows show the regular bursal profile; B: Arthroscopic view. The black arrows show the mangy and flap of supraspinatus tendon. MAR: Magnetic resonance arthrography.

Interobserver agreement was total ($k = 1.000$).

In 55 patients in whom a partial-thickness tear was diagnosed, agreement in terms of tear extent was $k = 0.878$ for the articular side and $k = 0.837$ for the bursal side, respectively. Full data are reported in Tables 5 and 6, respectively. Regarding interobserver agreement, the two readers disagreed at maximum for 1 degree

for either articular or bursal side of the supraspinatus tendon, with $k = 0.947$ and $k = 0.969$, respectively.

DISCUSSION

When managing a patient affected with a RCT, both clinical and imaging evaluation play a crucial role^[22].

Table 5 Data on agreement of the severity degree assigned on the articular side for partial tear between magnetic resonance arthrography (according to the most experienced reader) and arthroscopy

		Reader 1				
		A0	A1	A2	A3	A4
Arthroscopy	A0	7	0	0	0	0
	A1	8	6	0	0	0
	A2	2	2	3	0	0
	A3	0	0	4	7	0
	A4	0	0	0	8	8

Quadratically weighted Cohen kappa = 0.878. A: Articular side.

The role of diagnostic imaging is to help in the choice between surgical or nonsurgical treatment. Ultrasound, unenhanced MR and MRA have become the most common imaging techniques by which a RCT is diagnosed. Ultrasound is as accurate as unenhanced MR, but MRA remains the most sensitive and specific technique and is generally performed in cases in which ultrasound and unenhanced MR are not definitive^[7].

The use of a common RCTs classification by radiologists and orthopaedists may allow for a more direct comparison, leading to better clinical diagnosis and letting the patient to decide a treatment option with clearer information. Snyder proposed a classification system for the evaluation of RCTs measuring both their extent and number of tendons involved, providing indications for surgery or conservative treatment on the basis of the obtained score^[16]. In the present study we adopted the Snyder's classification as it was already successfully used by orthopaedics surgeons at our Institution, as a tentative to achieve a better communication with them.

In our study we found a high agreement in diagnosing RCTs for both radiologists having arthroscopy as reference standards. These results are in line with what is already reported in a recent systematic review about the accuracy of MRA in diagnosing RCTs using conventional descriptive reporting systems^[23]. Moreover, we found a very high interobserver reproducibility between the two readers, with a perfect agreement for full-thickness RCTs; regarding partial-thickness RCTs, the two readers rarely disagreed. This means that also the less experienced reader showed a very good diagnostic performance. As a consequence, we can think that the Snyder's classification system may have a value also when used in reporting MRA, even though originally created for arthroscopy.

A deeper analysis of the results showed that radiologists tend to underestimate the damage of the tendon, for both full-thickness and partial-thickness RCTs. This data deserves some considerations. The margins of a tendon tear are usually made by degenerated tendon matrix. During arthroscopy, the orthopaedic surgeon debrides the degenerated area to have more consistent margins for repair^[24]. Thus, final evaluation of tear extent by the orthopaedic surgeon may be larger compared to

Table 6 Data on agreement of the severity degree assigned on the bursal side for partial lesions between magnetic resonance arthrography and arthroscopic assessment

		Reader 1				
		B0	B1	B2	B3	B4
Arthroscopy	B0	5	0	0	0	0
	B1	7	4	0	0	0
	B2	4	7	7	0	0
	B3	0	0	3	5	0
	B4	0	0	0	3	10

Quadratically weighted Cohen kappa = 0.837. B: Bursal side.

what previously seen on MRA.

Regarding partial-thickness RCTs, reproducibility of MRA is still high but lower than for full-thickness RCTs. This was expected, as it is known that both MRI and MRA have higher performance in assessing the full-thickness RCTs rather than partial-thickness RCTs^[25-27]. However, the difference between the radiologist and the arthroscopy was only 1 degree in the majority of cases and 2 degrees in a few patients: These discrepancies are expected to not affect significantly the patients' management^[28]. Moreover, similarly to what happens for full-thickness RCTs, the radiologist always tends to underestimate the lesion degree of partial RCTs. Again, the main reason for this underestimation may be related to the fact that partial-tear tendon debridement procedure could be performed by the surgeon on wider area of the tendon, with a consequent extension of the Snyder's arthroscopic score^[28]. Overall, we should also consider the time elapsed from MRA to surgery (median delay 137 d) which could represent a factor for progression of mild damage of the tendon. It is known that tendon injuries, if left untreated, can progress by determining the transition from small partial injury to a greater degree and from partial to complete tears^[29].

This study has some limitations. First, it was performed retrospectively. Second, arthroscopy was performed by several orthopaedic surgeons with different experience in RCTs repair. Thus, certain degree of variability in RCTs scoring at the reference standard may be expected and may have slightly influenced our results. The same can be said for the delay between MRA and arthroscopy, which limited the reliability of the reference standard. In fact, the median delay of 137 d between MRA and arthroscopy could be seen as a long time between the two exams; nevertheless, this kind of delays may be common in everyday hospital practice, as patients usually attempt conservative treatments before undergoing surgery.

In conclusion, our study demonstrates high reproducibility of MRA in evaluating RCTs using the Snyder's classification as a method for reporting. This allows to conclude that not only MRA but also the Snyder's classification has an intrinsic high diagnostic value. Even though originally created for arthroscopy, Snyder's classification is well suitable and may be adopted for routine reporting of

MRA.

COMMENTS

Background

The shoulder joint is a complex anatomic structure consisting of static and dynamic stabilizers, which confers functional stability and high degree of mobility at the same time. Rotator cuff acts as a dynamic stabilizer contributing to shoulder stability. Rotator cuff tears (RCTs) are commonly encountered, implying shoulder pain and dysfunction, often associated with loss of biomechanical balance and instability and subacromial impingement.

Research frontiers

Magnetic resonance arthrography (MRA) is particularly useful for rotator cuff partial-thickness tears as well as labrum and glenohumeral ligament tears and degeneration. Several orthopaedic classifications of RCTs were proposed throughout years; At the authors' institution, shoulder orthopaedic surgeons use the Snyder's arthroscopic classification of RCTs, which includes three parameters: The location of the lesion, the extent of the lesion - and the number of involved tendons.

Innovations and breakthroughs

Despite many orthopaedic classifications, these never entered into radiological practice and radiologists still descriptively report tears of the RC, with referring physicians that may remains unsatisfied with them. The authors evaluated the diagnostic performance of MRA in evaluating RCTs using the Snyder's classification system for reporting MRA findings, evaluating its accuracy using arthroscopy as reference standard.

Applications

MRA showed high diagnostic accuracy and reproducibility in evaluating RCTs using the Snyder's classification for reporting. Snyder's classification may be adopted for routine reporting of MRA.

Terminology

MRA is an examination of magnetic resonance imaging that is performed after the injection of contrast material (gadolinium) into the joint, with the aim to increase its diagnostic performance. RCTs may involve the articular or bursal side, and can be classified as partial or complete according to thickness tendon involvement.

Peer-review

The authors evaluate the diagnostic performance of MRA in evaluating RCTs using the Snyder's classification system for reporting MRA findings, evaluating its accuracy using arthroscopy as reference standard. They demonstrated high reproducibility of MRA in evaluating RCTs using the Snyder's classification as a method for reporting.

REFERENCES

- Huegel J, Williams AA, Soslowsky LJ. Rotator cuff biology and biomechanics: a review of normal and pathological conditions. *Curr Rheumatol Rep* 2015; **17**: 476 [PMID: 25475598 DOI: 10.1007/s11926-014-0476-x]
- Longo UG, Berton A, Papapietro N, Maffulli N, Denaro V. Biomechanics of the rotator cuff: European perspective [Internet]. In: Rotator Cuff Tear. 2011. [cited 2016 Aug 17]. Available from: URL: <http://www.ncbi.nlm.nih.gov/pubmed/21986041>
- Gombera MM, Sekiya JK. Rotator cuff tear and glenohumeral instability : a systematic review. *Clin Orthop Relat Res* 2014; **472**: 2448-2456 [PMID: 24043432 DOI: 10.1007/s11999-013-3290-2]
- Longo S, Corradi A, Michielon G, Sardanelli F, Sconfienza LM. Ultrasound evaluation of the subacromial space in healthy subjects performing three different positions of shoulder abduction in both loaded and unloaded conditions. *Phys Ther Sport* 2016 Aug 12; Epub ahead of print [PMID: 27776926 DOI: 10.1016/j.pts.2016.08.007]
- Tashjian RZ. Epidemiology, natural history, and indications for treatment of rotator cuff tears. *Clin Sports Med* 2012; **31**: 589-604 [PMID: 23040548 DOI: 10.1016/j.csm.2012.07.001]
- Corazza A, Orlandi D, Fabbro E, Ferrero G, Messina C, Sartoris R, Perugin Bernardi S, Arcidiacono A, Silvestri E, Sconfienza LM. Dynamic high-resolution ultrasound of the shoulder: how we do it. *Eur J Radiol* 2015; **84**: 266-277 [PMID: 25466650 DOI: 10.1016/j.ejrad.2014.11.007]
- de Jesus JO, Parker L, Frangos AJ, Nazarian LN. Accuracy of MRI, MR arthrography, and ultrasound in the diagnosis of rotator cuff tears: a meta-analysis. *AJR Am J Roentgenol* 2009; **192**: 1701-1707 [PMID: 19457838 DOI: 10.2214/AJR.08.1241]
- Hodler J, Kursunoglu-Brahme S, Snyder SJ, Cervilla V, Karzel RP, Schweitzer ME, Flannigan BD, Resnick D. Rotator cuff disease: assessment with MR arthrography versus standard MR imaging in 36 patients with arthroscopic confirmation. *Radiology* 1992; **182**: 431-436 [PMID: 1489363 DOI: 10.1148/radiology.182.2.1489363]
- Codman EA. The shoulder: rupture of the supraspinatus tendon and other lesions in or about the subacromial bursa. Boston, United States: Thomas Todd, 1934: 123-177
- Neer CS. Impingement lesions. *Clin Orthop Relat Res* 1983; **(173)**: 70-77 [PMID: 6825348 DOI: 10.1097/00003086-198303000-00010]
- DeOrto JK, Cofield RH. Results of a second attempt at surgical repair of a failed initial rotator-cuff repair. *J Bone Joint Surg Am* 1984; **66**: 563-567 [PMID: 6707035 DOI: 10.2106/00004623-198466040-00011]
- Ellman H. Diagnosis and treatment of incomplete rotator cuff tears. *Clin Orthop Relat Res* 1990; **(254)**: 64-74 [PMID: 2182260 DOI: 10.1097/00003086-199005000-00010]
- Davidson J, Burkhart SS. The geometric classification of rotator cuff tears: a system linking tear pattern to treatment and prognosis. *Arthroscopy* 2010; **26**: 417-424 [PMID: 20206053 DOI: 10.1016/j.arthro.2009.07.009]
- Sconfienza LM, Orlandi D, Fabbro E, Ferrero G, Martini C, Savarino E, Silvestri E. Ultrasound assessment of the rotator cuff cable: comparison between young and elderly asymptomatic volunteers and interobserver reproducibility. *Ultrasound Med Biol* 2012; **38**: 35-41 [PMID: 22104526 DOI: 10.1016/j.ultrasmedbio.2011.10.010]
- Snyder S. Arthroscopic classification of rotator cuff lesions and surgical decision making. In: Wilkins LW. Philadelphia: Shoulder Arthroscopy, 2003: 201-207
- Millstein ES, Snyder SJ. Arthroscopic management of partial, full-thickness, and complex rotator cuff tears: indications, techniques, and complications. *Arthroscopy* 2003; **19** Suppl 1: 189-199 [PMID: 14673438 DOI: 10.1016/j.arthro.2003.10.033]
- Robertson PL, Schweitzer ME, Mitchell DG, Schlesinger F, Epstein RE, Frieman BG, Fenlin JM. Rotator cuff disorders: interobserver and intraobserver variation in diagnosis with MR imaging. *Radiology* 1995; **194**: 831-835 [PMID: 7862988 DOI: 10.1148/radiology.194.3.7862988]
- Bosmans JM, Weyler JJ, De Schepper AM, Parizel PM. The radiology report as seen by radiologists and referring clinicians: results of the COVER and ROVER surveys. *Radiology* 2011; **259**: 184-195 [PMID: 21224423 DOI: 10.1148/radiol.10101045]
- Larson DB, Froehle CM, Johnson ND, Towbin AJ. Communication in diagnostic radiology: meeting the challenges of complexity. *AJR Am J Roentgenol* 2014; **203**: 957-964 [PMID: 25341133 DOI: 10.2214/AJR.14.12949]
- Sconfienza LM, Serafini G, Silvestri E. Ultrasound-guided musculoskeletal procedures - the upper limb. Milan, Italy: Springer-Verlag Mailand, 2012
- Messina C, Banfi G, Aliprandi A, Mauri G, Secchi F, Sardanelli F, Sconfienza LM. Ultrasound guidance to perform intra-articular injection of gadolinium-based contrast material for magnetic resonance arthrography as an alternative to fluoroscopy: the time is now. *Eur Radiol* 2016; **26**: 1221-1225 [PMID: 26253260 DOI: 10.1007/s00330-015-3945-3]
- Lansdown DA, Feeley BT. Evaluation and treatment of rotator

- cuff tears. *Phys Sportsmed* 2012; **40**: 73-86 [PMID: 22759608 DOI: 10.3810/psm.2012.05.1967]
- 23 **Lenza M**, Buchbinder R, Takwoingi Y, Johnston RV, Hanchard NC, Faloppa F. Magnetic resonance imaging, magnetic resonance arthrography and ultrasonography for assessing rotator cuff tears in people with shoulder pain for whom surgery is being considered. *Cochrane Database Syst Rev* 2013; (9): CD009020 [PMID: 24065456 DOI: 10.1002/14651858.CD009020.pub2]
- 24 **Castagna A**, Borroni M, Garofalo R, Rose GD, Cesari E, Padua R, Conti M, Gumina S. Deep partial rotator cuff tear: transtendon repair or tear completion and repair? A randomized clinical trial. *Knee Surg Sports Traumatol Arthrosc* 2015; **23**: 460-463 [PMID: 23689964 DOI: 10.1007/s00167-013-2536-6]
- 25 **Aliprandi A**, Sdao S, Cannaò PM, Khattak YJ, Longo S, Sconfienza LM, Sardanelli F. Imaging of shoulder pain in overhead throwing athletes. *Sport Sci Health* 2013; **9**: 81-88 [DOI: 10.1007/s11332-013-0151-z]
- 26 **Waldt S**, Bruegel M, Mueller D, Holzapfel K, Imhoff AB, Rummeny EJ, Woertler K. Rotator cuff tears: assessment with MR arthrography in 275 patients with arthroscopic correlation. *Eur Radiol* 2007; **17**: 491-498 [PMID: 16969638 DOI: 10.1007/s00330-006-0370-7]
- 27 **Magee T**, Shapiro M, Williams D. Comparison of high-field-strength versus low-field-strength MRI of the shoulder. *AJR Am J Roentgenol* 2003; **181**: 1211-1215 [PMID: 14573405 DOI: 10.2214/ajr.181.5.1811211]
- 28 **Fukuda H**. The management of partial-thickness tears of the rotator cuff. *J Bone Joint Surg Br* 2003; **85**: 3-11 [PMID: 12585570 DOI: 10.1302/0301-620X.85B1.13846]
- 29 **Yamanaka K**, Matsumoto T. The joint side tear of the rotator cuff. A followup study by arthrography. *Clin Orthop Relat Res* 1994; (304): 68-73 [PMID: 8020236]

P- Reviewer: Gao BL, Li YZ **S- Editor:** Gong XM **L- Editor:** A
E- Editor: Li D





Published by **Baishideng Publishing Group Inc**

8226 Regency Drive, Pleasanton, CA 94588, USA

Telephone: +1-925-223-8242

Fax: +1-925-223-8243

E-mail: bpgoffice@wjgnet.com

Help Desk: <http://www.wjgnet.com/esps/helpdesk.aspx>

<http://www.wjgnet.com>

