

Anatomical variants of sphenoid sinuses pneumatization: a CT scan study on a Northern Italian population

Daniele Gibelli, ^{1,*}

Email daniele.gibelli@unimi.it

Michaela Cellina, ²

Stefano Gibelli, ³

Antonio Giancarlo Oliva, ²

Giovanni Termine, ³

Chiarella Sforza, ¹

¹ Dipartimento di Scienze Biomediche per la Salute, Università degli Studi di Milano, V. Mangiagalli 31, Milan, Italy

² Reparto di Radiologia, Ospedale Fatebenefratelli, ASST Fatebenefratelli Sacco, Milan, Italy

³ Reparto di Otorinolaringoiatria, Ospedale Fatebenefratelli, ASST Fatebenefratelli Sacco, Milan, Italy

Abstract

Sphenoid bone may be affected by different variants of pneumatization, which have a relevant importance from a clinical and surgical point of view. The description of such variants in different populations may give useful information. However, few articles describe the variability of sphenoid pneumatized structures and none of them focuses on Northern Italian population. Variants of pneumatization of sphenoid bone were described in a sample of 300 Northern Italian patients who underwent a CT scan. ~~Fifty-~~

three More than fifty-seven percent of patients showed a form of anatomical variant: the most common form was the pneumatized pterygoid processes (39.6%), followed by dorsum sellae (32.9%) and clinoid processes (20.3%), without statistically significant differences between males and females ($p > 0.01$). In 26.3% of patients, a combined pneumatization of these three structures was observed, being the combination pterygoid processes-dorsum sellae the most frequent (11.3%). In 9.3%, all the three sphenoid structures were affected. This article is the first description of the prevalence of different variants of pneumatization in a Northern Italian population: the occurrence of such forms has to be acknowledged for their possible clinical and surgical consequences.

AQ1

AQ2

Keywords

Anatomical variants
Sphenoid sinuses
Radiology
CT scan
Otorhinolaryngology

Introduction

Sphenoid sinuses are considered the most variable structures in the human body [1]; the assessment of anatomical variants of sphenoid bone and sphenoid sinuses has acquired with time a growing importance in different fields of application of clinical anatomy. A first example is provided by the improvement of transsphenoidal surgery, first developed in 1907, which represents a standard procedure for the treatment of intrasellar pathologies [2] and the exploration of cranial base according to the degree of pneumatization. In fact, sphenoid sinuses may vary in shape and size, sometimes with accessory septa further segmenting the air spaces [3]. In addition, the pneumatization of sphenoid sinuses may range from absent to extensive [4], sometimes extending into anterior clinoid processes, pterygoid processes, greater wings, clivus, as well as also into other bones such as vomer, palatine and occipital bone [5, 6]. Therefore, the analysis

of pneumatised structures in patients has a relevant importance for a correct planning of surgical procedures [7], as shown also by recent publications concerning the use of extended transsphenoidal approach not only to suprasellar and parasellar lesions [8, 9], but also to the floor of the middle cranial fossa [10] and the petrous apex [11].

However, the variable morphology of pneumatised structures of sphenoid bone may also represent a risk for iatrogenic lesions: in fact the degree of pneumatisation is linked with the probability of exposition of important structures, namely internal carotid artery, maxillary nerve and optic nerve into the sinuses [4, 7]. In addition, pneumatisation of greater wings increases the risk of penetration into the middle cranial fossa, with consequent leakage of liquor [12].

For what concerns otorhinolaryngology, pneumatised structures may represent a risk for chronic sinusitis [12], as well as possible involvement of maxillary and optic nerves exposed into the sphenoid sinuses, with respectively trigeminal neuralgia and visual deficit [12, 13, 14]. The epidemiological assessment of different variants in general population is crucial: literature has already explored the prevalence in different ethnic groups [4, 14, 15, 16, 17, 18, 19], but no study has so far analysed the Italian population in depth. Yet the exact knowledge of these variants may have relevant consequences in clinical and surgical practice.

This study aims at verifying the prevalence of main anatomical variants of pneumatisation of sphenoid sinuses: the results will add a contribution to the epidemiological data already existing in the literature.

Materials and methods

The study took into consideration 300 patients (150 males and 150 females) aged between 25 and 99 years who underwent a CT scan in a hospital of Milan (Northern Italy). The most frequent clinical requests concerned screening for possible cranial fractures in cases of trauma (57.3%), sinusitis or nasal and paranasal symptoms (20.0%) or ~~for~~ neurological symptoms (12.7%), without differences between males and females. CT scans were anonymized to meet the local and international ethic rules. All CT scans were performed on a second-generation dual-source scanner, Somatom Definition Flash (Siemens,

Forchheim, Germany); parameters of acquisition: kV: 120, mAs: 320, collimation: 40×0.6 mm, tube rotation: 1 s; reconstruction thickness: 3 mm; reconstruction filters: H21s smooth for soft tissues and H60 sharp for bone.

The analysis focused on the assessment of the type of sphenoid sinuses (conchal, presellar, sellar and postsellar) [7], morphologically appreciable prevalence of the right or left side, possible accessory septa, pneumatization of pterygoid processes, anterior clinoid processes, and dorsum sellae. Statistically significant differences in prevalence of each characteristic between males and females and association between different forms of aberrant pneumatization were assessed by Chi square test ($p < 0.01$).

Results

For what concerns the classification of sphenoidal sinuses, 77.3% of subjects showed a sellar type, followed by postsellar (14.7%) and presellar one (8.0%), without relevant differences between males and females (Fig. 1). In both males and females, prevalence in size of the left sinus was observed with a mean percentage of 56.7%. In addition, septa could be found in 62.7%; in 50.5% they were bilateral, in 26.6% they were limited to the left sinus, and in 22.9% to the right sinus (Figs. 2, 3).

Fig. 1

Sagittal multiplanar images reconstructed with bone algorithm of different types of sella turcica: **a** presellar: the sphenoid sinus ends anteriorly to the anterior edge of sella turcica; **b** sellar: sphenoid sinus extends under sella turcica; **c** retrosellar: sphenoid sinus extends posteriorly to the posterior edge of sella turcica

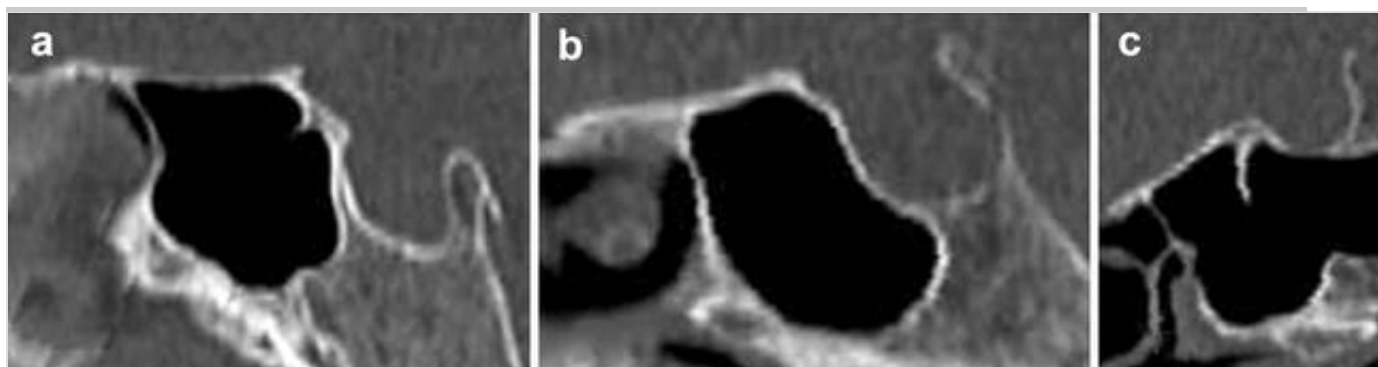


Fig. 2

Axial CT acquisition reconstructed with bone algorithm of sphenoid sinuses: the presence of three accessory septa on the right sinus (*white arrow*)

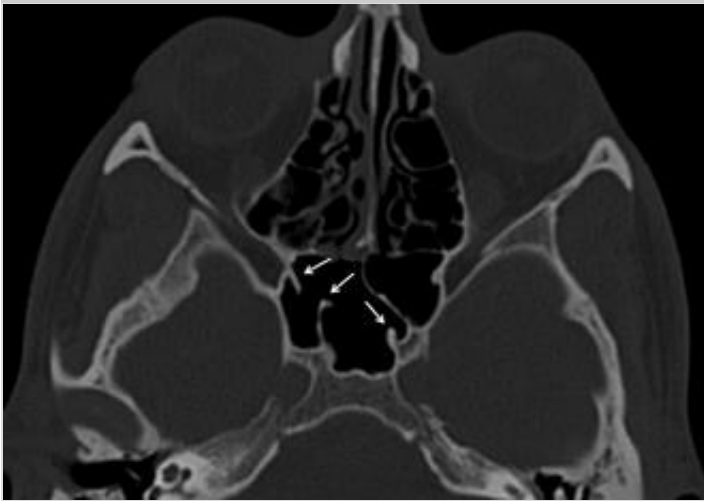
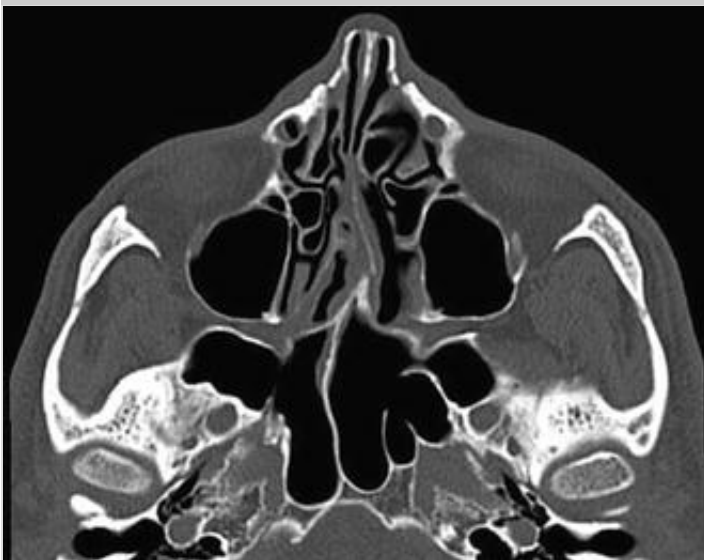

Fig. 3

Axial CT acquisition reconstructed with bone algorithm showing hypertrophic sphenoid sinuses extending up to the greater wings, with a predominance on the left side: the left sinus is segmented by three accessory septa



In the entire population, 57.3% of patients showed a form of aberrant pneumatization: the most common form was the presence of pneumatized pterygoid processes (39.6%, Fig. 4), followed by dorsum sellae (32.9%, Fig. 5) and clinoid processes (20.3%) (Fig. 6).

Fig. 4

Axial CT acquisition reconstructed with bone algorithm showing an example of aberrant pneumatization extending to the right pterygoid process

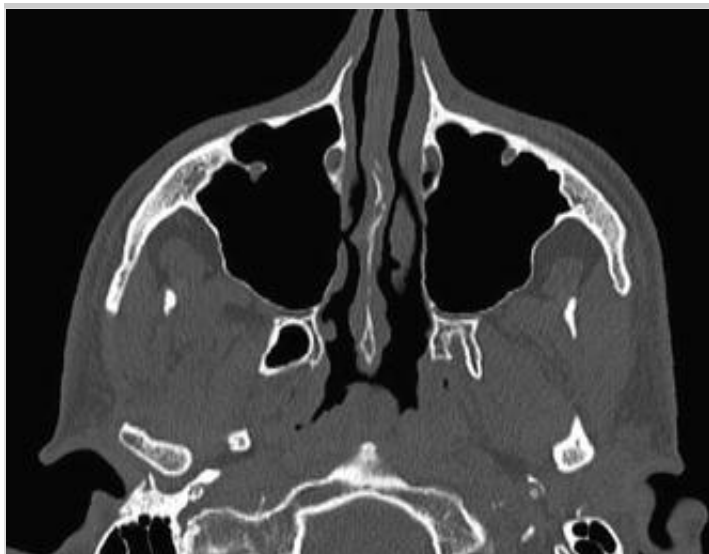

Fig. 5

Axial CT acquisition reconstructed with bone algorithm showing an example of pneumatization of dorsum sellae: in addition, the air space included in the posterior edge of sella turcica is divided by a septum

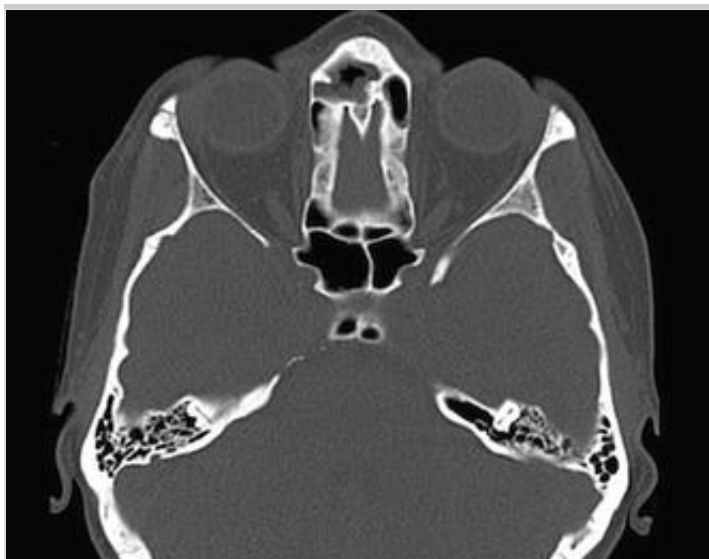
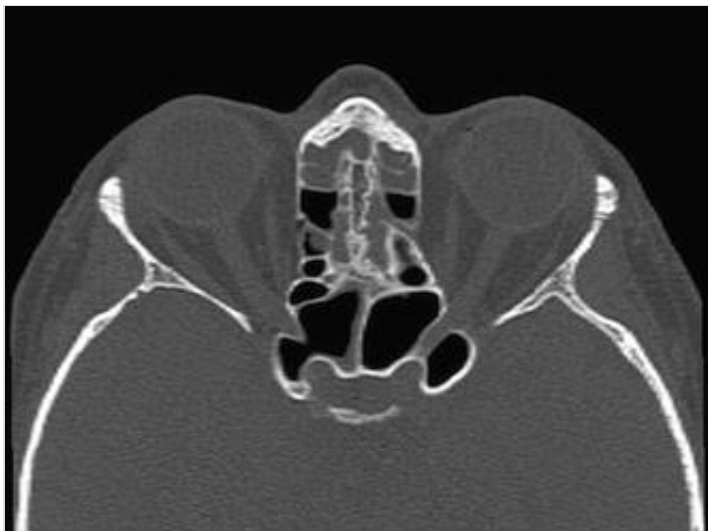
Fig. 6

Axial CT acquisition reconstructed with bone algorithm showing an example of pneumatization of anterior clinoid processes: on the right side, the pneumatised space surrounds the optic nerve superiorly



Pneumatised pterygoid processes were most frequently bilateral (62.2%, Fig. 7), without differences between males and females: on the other hand, pneumatised clinoid processes were bilateral in 51.7% of males, and only in 37.5% of females (Fig. 8). No statistically significant differences in prevalence of different types of pneumatisation between males and females were observed ($p > 0.01$).

Fig. 7

Axial CT acquisition reconstructed with bone algorithm showing example of bilateral pneumatisation of pterygoid processes: both the structures are affected by an aberrant pneumatisation

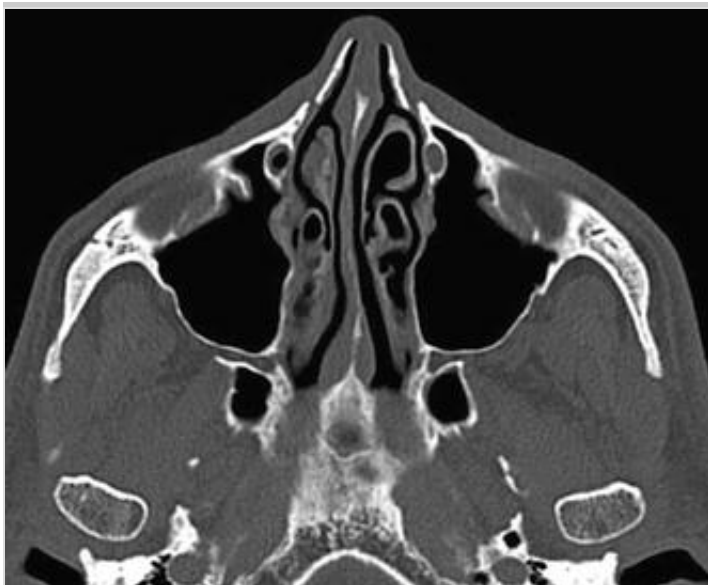
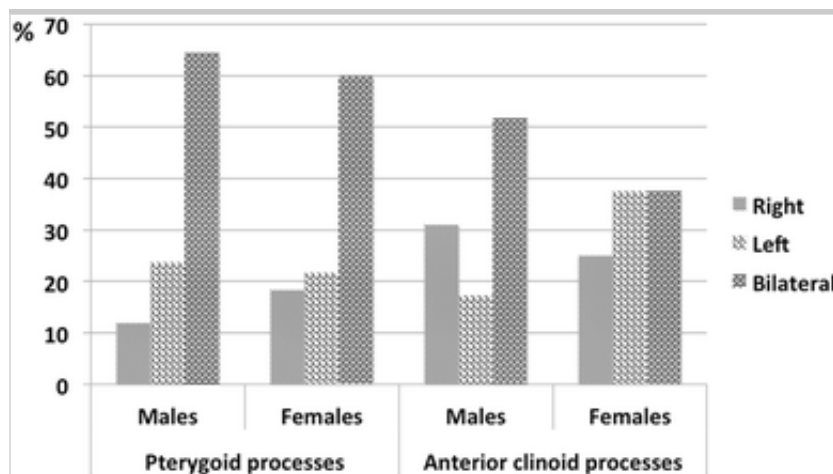


Fig. 8

Side of pneumatised forms of pterygoid processes and anterior clinoid processes in males and females

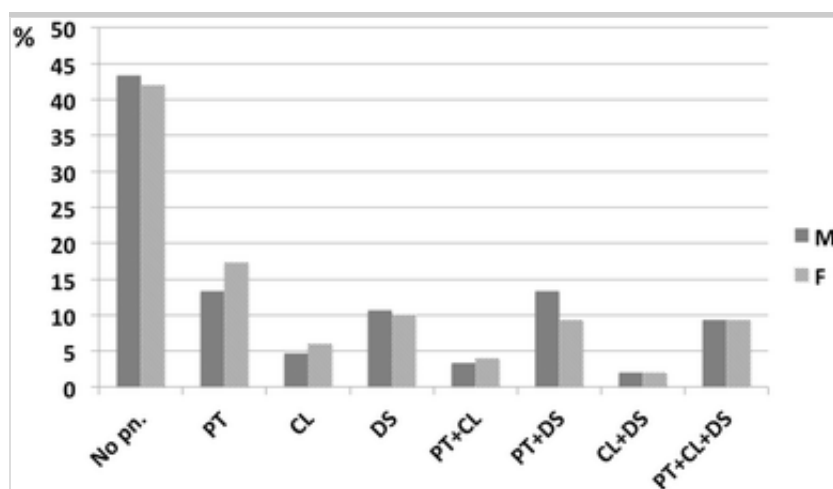


In cases of pneumatised dorsum sellae, a septum was found in 18.2%, without appreciable differences between males and females.

In 26.3% of patients, a combined pneumatisation was observed: the most frequent type was the concurrent observation of pneumatised pterygoid processes and dorsum sellae (11.3%). In 9.3% of patients, all the three sphenoid structures were affected (Fig. 9).

Fig. 9

Prevalence of **single** and **isolated** and combined forms of pneumatisation of sphenoid bone: *PT* pterygoid processes; *CL* anterior clinoid processes; *DS* dorsum sellae; *no pn.* no other pneumatised structures



Type of sphenoidal sinuses influenced the prevalence of different variants: in postsellar type 89.6% of individuals were affected by aberrant pneumatization, whereas the same percentage amounted up to 17.2% in presellar type.

In addition, differences in prevalence of single pneumatized structures in comparison with the combined forms were statistically assessed: in detail, both male and female patients with a pneumatization variant were more prone to show other forms ($p < 0.01$).

Discussion

The study of anatomical variants of paranasal sinus region has acquired a growing importance with the advent of procedures based on endoscopic sinus surgery [20]. As other paranasal sinuses, sphenoid sinuses develop from an invagination of nasal mucosa within the bone structures between the third and fourth fetal month. Beginning points of invagination later become the opening of paranasal sinuses. Sphenoid sinuses usually reach the final morphology during the adolescence [21].

Iperpneumatization is known in ~~the~~ literature, with extension into other structures close to the sphenoid body and other bones, with possible inclusion of internal carotid artery, maxillary, vidian and optic nerves [14]. Variants in pneumatization of sphenoid bones are symptomless although literature reports a case of swelling in temporal region and slight degree of axial proptosis of the left eye in a subject with high-degree pneumatized sphenoid sinuses [22].

The epidemiologic study of variants of pneumatization of sphenoid bone has a relevant importance to verify the possible ethnically based differences. A characteristic of sphenoid sinuses which seems to be strongly related to the ethnic variability is the type of sinus: from this point of view, several classifications have been proposed; for example, Hammer and Radberg described three anatomic types of sphenoid sinus, conchal, presellar and sellar, being the sellar the most represented (86%) [23]. Wang et al. proposed another classification limited to the sellar category, with six types of sinuses based on the direction of pneumatization (sphenoid body, lateral type, clival type, lesser wing type, anterior type, combined type); in their population, sellar type was represented by 98%, and among them 59.2% showed a combined type [24].

However, the classification by Hammer and Radberg is widely accepted and is still the most used in practice [25]. Sellar type seems to be predominant in different populations [7, 17, 26, 27, 28, 29] among which Asians [26, 27] Malaysians [17] and Croatians [7], as also observed in the Northern Italian sample analysed in the present article. However, other types are prevalent in different ethnic contexts: for example, Madiha et al. reported 76% of presellar type in an Egyptian population [30], whereas in the Iranian population postsellar type is the most prevalent [19]. Type of sphenoid sinus is crucial as it proved to have a relevant impact on the possible development of aberrant forms of pneumatization, as they are more frequently observed in highly pneumatized types. The review of the existing literature confirms that the prevalence of each type of sinus is widely influenced by ethnic variability [25].

AQ3

In addition, also the left prevalence of sphenoidal sinuses is confirmed by the existing reviews [16]. On the contrary, accessory septa were more frequently observed in the present study than by other authors [7, 28]. Accessory septa could represent a limit for transsphenoidal procedures and, therefore, need to be ascertained for a correct planning of surgical intervention.

However, the most relevant variations can be found in the assessment of prevalence of different aberrant forms of pneumatization (Table 1): for what concerns pterygoid processes, literature highlights a prevalence ranging between 16.0 and 39.644% with a relevant variability, also within the same ancestry groups. The same is valid also for the anterior clinoid processes, whose prevalence ranges between 6.0 and 33.1%. Less information is available for the pneumatization of dorsum sellae, although again the existing data show discordances with the present results. This comparison stresses again the importance of population studies for a more precise description of such variants to obtain more information concerning their distribution and origin.

Table 1

Prevalence of the main anatomical variants of sphenoid bone in different ethnic groups compared with the existing literature

Source	Population	No. of recruited patients	Pneumatization of pterygoid processes (%)	Pneumatization of anterior clinoid	Pneumatization of dorsum sellae (%)
--------	------------	---------------------------	---	------------------------------------	-------------------------------------

				processes (%)	
Hewaidi and Omami [4]	Lybian	300	29.0	15.3	–
Sirikci et al. [14]	Turkish	92	29.3	29.3	–
Arslan et al. [15]	Turkish	200	16.0	6.0	–
Rereddy et al. [16]	USA	100	44.0	–	–
Lu et al. [18]	Chinese	200	22.3	5.0	12.4
Rahmati et al. [19]	Iranian	103	38.9	33.1	–
Present study	Northern Italian	300	39.6	32.9	20.3

In addition, the present study provides other points of discussion which are worth being analysed in depth by further population analyses, first of all the coexistence of different forms of pneumatisation in the same individual: in detail, the statistical analysis highlighted that subjects with a pneumatisation variant are likely to show other forms. This indication may suggest a common origin of different variants of pneumatisation, probably linked to the development of sphenoid sinuses. In addition, surgeons have to expect that probably patients may be affected by different forms of pneumatisation.

Secondarily, no differences were found according to sex.

The importance and limits of the present study need to be discussed: in surgical procedures, the importance of pneumatisation variants of sphenoid sinus is widely recognized, and they are accurately assessed on each patient. However, the epidemiological study of these variants within the general population may provide interesting data, especially for what concerns the existence of ethnic

variability and the relative diffusion of different types of morphology within different populations. In addition, the increase of data concerning the prevalence of different forms of pneumatisation may help in formulating hypotheses concerning their origin and development.

Finally, epidemiological data of pneumatisation variants in healthy population are fundamental for next studies concerning their possible role in pathological condition, such as chronic sinusitis: most of the literature in fact highlights that variant forms of pneumatisation are usually asymptomatic and cases of clinically evident symptoms are very rare [22]. The few data concerning this issue derive from Kazkayasi et al. who analysed the probability of finding aberrant pneumatisation in patients treated for chronic or recurrent sinusitis: prevalence of pneumatisation of pterygoid processes and anterior clinoid processes was, respectively, 39.7 and 17.2%, ~~similarly to the present results~~ [31]. ~~The present data are not sufficient to provide conclusive indications concerning the possible role of pneumatisation variants in chronic sinusitis.~~ Clearly, the most relevant matters of concern linked to pneumatised structures of sphenoid bone are represented by possible damages caused by transsphenoidal surgical approaches: however, this does not exclude that such forms may modify the aeration of pneumatised structures of cranium and, therefore, have a relation with chronic sinusitis. Further studies on the affected patients may provide additional data.

Another point for future analyses concerns the possible relation of pneumatisation variants with other air cells and paranasal sinuses: for example, several authors observed a positive correlation between the pneumatisation of sphenoid sinus and mastoid air cells [32, 33]. Further studies concerning this topic may provide additional information concerning the incompletely known origin of pneumatised cranial bones.

AQ4

In conclusion, this article first provides a description of variants of pneumatised sphenoid structures in a Northern Italian population. Further studies are needed to obtain a more precise description of ~~such~~these variants in different populations.

Compliance with ethical standards

Conflict of interest None.

Ethical standards All procedures performed in studies involving human participants were in accordance with the ethical standards of the institutional and national research committee and with the 1964 Helsinki declaration and its later amendments or comparable ethical standards. All radiological examinations were previously anonymized.

References

1. Teatini G, Simonetti G, Salvolini U, Masala W, Meloni F, Rovasio S, Dedola GL (1987) Computed tomography of the ethmoid labyrinth and adjacent structures. *Ann Otol Rhinol Laryngol* 96:239–250
2. Perondi GE, Isolan GR, de Aguiar PH, Stefani MA, Falcetta EF (2013) Endoscopic anatomy of sellar region. *Pituitary* 16:251–259
3. Bonneville JF, Dietemann JL (1981) *Radiology of the sella turcica*. Springer, Berlin
4. Hewaidi GH, Omami GM (2008) Anatomical variation of sphenoid sinus and related structures in Libyan population: CT scan study. *Libyan J Med* 3(3):128–133
5. Yune H, Holden R, Smith J (1975) Normal variations and lesions of the sphenoid sinus. *Am J Roentgenol* 124:129–138
6. Fujoka M, Yung L (1978) The sphenoid sinuses: radiographic patterns of normal development and abnormal findings in infants and children. *Radiology* 129:133–139
7. Stokovic N, Trkulja V, Dumic-Cule I, Cukovic-Bagic I, Lauc T, Vukicevic S, Grgurevic L (2016) Sphenoid sinus types, dimensions and relationship with surrounding structures. *Ann Anat* 203:69–76
8. Abuzayed B, Tanriover N, Gazioglu N, Ozlen F, Cetin G, Akar Z (2010)

Endoscopic anatomy and approaches of the cavernous sinus: cadaver study. *Surg Radiol Anat* 32:499–508

9. Kim EH, Ahn JY, Kim SH (2011) Technique and outcome of endoscopy-assisted microscopic extended transsphenoidal surgery for suprasellar craniopharyngiomas. *J Neurosurg* 114(5):1338–1349
10. Ceylan S, Koc K, Anik I (2009) Extended endoscopic approaches for midline skull-base lesions. *Neurosurg Rev* 32:309–319
11. Zanation AM, Snyderman CH, Carrau RL, Gardner PA, Prevedello DM, Kassam AB (2009) Endoscopic endonasal surgery for petrous apex lesions. *Laryngoscope* 119(1):19–25
12. Hamid O, El Fiky L, Hassan O, Kotn A, El Fiky S (2008) Anatomical variations of the sphenoid sinus and their impact of trans-sphenoid pituitary surgery. *Skull Base* 18:9–15
13. Chong VF, Fan YF, Lau DP (1994) Imaging the sphenoid sinus. *Australas Radiol* 29:47–54
14. Sirikci A, Bayazit YA, Bayram M, Mumbuc S, Gungor K, Kanlikama M (2000) Variations of sphenoid and related structures. *Eur Radiol* 10:844–848
15. Arslan H, Aydinoglu A, Bozkurt M, Egeli E (1999) Anatomical variations of the paranasal sinuses: CT examination for endoscopic sinus surgery. *Auris Nasus Larynx* 26:39–48
16. Reredy SK, Johnson DM, Wise SK (2014) Markers of increased aeration in the paranasal sinuses and along the skull base: association between anatomical variants. *Am J Rhinol Allergy* 28:477–482
17. Anusha B, Baharudin A, Philip R, Harvinder S, Shaffie BM, Ramiza RR (2015) Anatomical variants of surgically important landmarks in the sphenoid sinus: a radiologic study in Southeast Asian patients. *Surg Radiol Anat* 37:1183–1190

AQ5

18. Lu Y, Qi S, Shi J, Zhang X, Wu K (2011) Pneumatization of the sphenoid sinus in Chinese: the differences from Caucasian and its application in the extended transsphenoidal approach. *J Anat* 219:132–142
19. Rahmati A, Ghafari R, AnjomShoa MA (2016) Normal variations of sphenoid sinus and the adjacent structures detected in cone beam computed tomography. *J Dent Shiraz Univ Med Sci* 17(1):32–37
20. Kantarci M, Karasen RM, Alper F, Onbas O, Okur A, Karaman A (2004) Remarkable variations in paranasal region and their clinical importance. *Eur J Radiol* 50:296–302
21. Terra ER, Guedes FR, Manzi FR, Boscolo FN (2006) Pneumatization of the sphenoid sinus. *Dentomaxillofac Surg* 35:47–49
22. Morton ME (1983) Excessive pneumatisation of the sphenoid sinus: a case report. *J Maxillofac Surg* 11:236–238
23. Hammer G, Radberg C (1961) The sphenoidal sinus. An anatomical and roentgenologic study with reference to transsphenoid hypophysectomy. *Acta Radiol* 56:401–422
24. Wang J, Bidari S, Inoue K, Yang H, Rhoton A Jr (2010) Extensions of the sphenoid sinus: a new classification. *Neurosurgery* 66(4):797–816
25. Anusha B, Baharudin A, Philip R, Harvinder S, Shaffie BM (2014) Anatomical variations of the sphenoid sinus and its adjacent structures: a review of existing literature. *Surg Radiol Anat* 36(5):419–427
26. Tan HK, Ong YK (2007) Sphenoid sinus: an anatomic and endoscopic study in Asian cadavers. *Clin Anat* 20(7):745–750
27. Cho JH, Kim JK, Lee JG, Yoon JH (2010) Sphenoid sinus pneumatization and its relation to bulging of surrounding neurovascular structures. *Ann Otol Rhinol Laryngol* 119(9):645–650
28. Banna M, Olutola PS (1983) Patterns of pneumatisation and septation of

the sphenoidal sinus. *J Can Assoc Radiol* 34(4):291–293

29. Idowu OE, Balogun BO, Okoli CA (2009) Dimensions, septation, and pattern of pneumatization of the sphenoidal sinus. *Folia Morphol (Warsz)* 68(4):228–232

30. Madiha AES, Raouf AA (2007) Endoscopic anatomy of the sphenoid air sinus. *Bull Alex Fac Med* 43:1021–1026

31. Kazkayasi M, Karadeniz Y, Arikan OK (2005) Anatomic variations of the sphenoid sinus on computed tomography. *Rhinology* 43(2):109–114

32. Hindi K, Alazzawi S, Raman R, Prepageran N, Rahmat K (2014) Pneumatization of mastoid air cells, temporal bone, ethmoid and sphenoid sinuses. Any correlation? *Indian J Otolaryngol Head Neck Surg* 66(4):429–436

33. Kim J, Song SW, Cho JH, Chang KH, Jun BC (2010) Comparative study of the pneumatization of the mastoid air cells and paranasal sinuses using three-dimensional reconstruction of computed tomography scans. *Surg Radiol Anat* 32(6):593–599