

## Case Report

# Guillain-Barré syndrome: report of two rare clinical cases occurring after allergenic bone grafting in oral maxillofacial surgery

Marco Ciccì<sup>1</sup>, Alan Scott Herford<sup>2</sup>, Ennio Bramanti<sup>3</sup>, Carlo Maiorana<sup>4</sup>

<sup>1</sup>Department of Human Pathology, University of Messina University of Messina School of Dentistry, ME, IT;

<sup>2</sup>Department of Oral and Maxillofacial Surgery Loma Linda University Loma Linda, CA, USA; <sup>3</sup>Department of Medical Surgical Disciplines and Odontostomatology, University of Messina, ME, IT; <sup>4</sup>Department of Implantology, Fondazione Policlinico IRCCS Cà Granda, University of Milan University of Milan School of Dentistry, MI, IT

Received March 26, 2015; Accepted May 20, 2015; Epub June 1, 2015; Published June 15, 2015

**Abstract:** Guillain-Barré Syndrome (GBS), also known as post-infectious polyneuropathy or acute idiopathic polyneuritis, is an infrequent disorder of the peripheral nervous system. The cause of GBS is unknown. It has been associated in the past with microbial infections, vaccinations, surgical procedures and debilitation of the patient. The classic signs of GBS occurring in the two patients being reported here are muscle weakness, motor and sensory impairment and ascending paralysis with respiratory involvement. The documented cases involved GBS syndrome following oral and maxillofacial surgery in which allogeneic-banked freeze-dried bone have been utilized along with autogenous grafting. There were no incidents of viral infection, vaccination or the other prodromal incidents involved in these cases. It is believed that the description of these two cases would be of interest in that it may stimulate the reporting of similar anecdotal occurrences by other surgeons. Both patients fully recovered from the GBS and are presently alive and well.

**Keywords:** Guillain-Barré Syndrome, allogeneic-banked freeze-dried bone, oral surgery

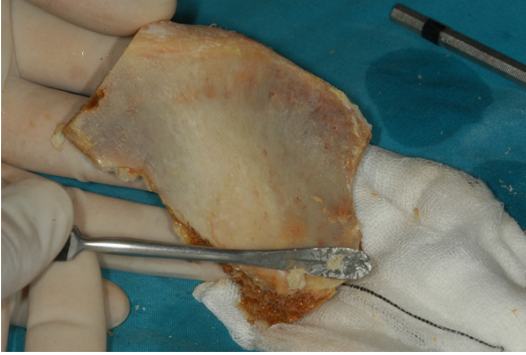
### Introduction

Guillain-Barré syndrome (GBS) is a disease of unknown, but presumably immunologic aetiology. GBS frequently is marked by an ascending paralysis leading to acute respiratory malfunctioning necessitating heroic measures to preserve the life of the patient. It has been reported that there is multi-focal loss of myelin throughout the peripheral nervous system with relative preservation of the axons. The disease is characterized by progressive motor weakness of limbs with absence of neurologic reflexes such as the knee jerk reaction. Preceding antecedent infections, mostly viral, are seen in half of the cases. One third of patients required ventilatory support in the past with about ten per cent mortality [1-5]. GBS has been reported following acute respiratory episodes of flu and encephalitis and also following membranous glomerulo-nephritis (MGN). In addition, Guillain-Barré can follow any debilitating disease and may occur at any age, but is more commonly seen after the third or fourth decade of life [1].

In the literature it has been cited as following a viral infection, which produces a characteristic mononuclear cell, infiltrate [4]. Commonly, as in the case of the two cases to be reported here, the disease begins with a severe weakness of the limbs producing a sudden problem in walking in a patient who previously has been ambulating without difficulty. Motor weakness is usually progressive, frequently producing the necessity of endotracheal intubation and artificial respiratory support. In review of the history of the two patients being reported here, the only common factor that could be elicited in the immediate patient past history was a bone graft consisting of banked decalcified and non-decalcified allograft material in reconstruction of the mandible and maxilla for prosthetic rehabilitation.

### Case descriptions

A 55-year-old female, Caucasian patient was admitted for oral and maxillofacial surgical procedure for the treatment of an atrophic completely edentulous mandible and maxilla.



**Figure 1.** Sample of iliac bone graft from cadaver, used for recovering large bone defect in the jaw.

The patient had a history of hypertension but was not taking any medication at the time of admission. In her family, there was no known history of clinical, muscular weakness, paralysis, and neurologic or cardiovascular disease. A bone graft, consisting of an autogenous iliac crest particulate bone from the left ilium mixed with freeze-dried allogeneic bone, was used to restore the height and the width of the atrophic mandible and maxilla. The immediate post-operative course was uneventful. One week post-operatively, the patient developed episodes of muscular weakness with some “tripping and falling”. During the following five days the symptoms of muscular paralysis worsen with development of lower limb paralysis and walking impairment. The weakness increased in severity during the following week. A diagnosis of Guillain-Barré Syndrome was made. She subsequently was transferred by air to Houston, Texas to the M.D. Anderson Hospital, where the lower and upper extremity weakness progressed followed by weakness and ascending paralysis of the respiratory muscles. On the 18th post-op day, the patient was placed on a respirator for a period of two weeks.

After approximately six weeks, the patient had no respiratory difficulties, and was advanced to a full diet. Other than a minimal paraesthesia, no sequel of symptoms was clinically present. The patient’s remaining clinical course was uneventful. Four months after surgery the clinical examination revealed an excellent post-operative healing of the maxillary and mandibular sites. She seemed to have complete return of her strength, but still complained of some numbness of her feet and toes. A plastic surgery of the buccal gingiva was performed and conventional full prostheses were inserted.

The patient continued to be seen by our service for the following 5 years. She exhibited no signs of residual paralysis and had no neurological deficiencies. From an OMS standpoint, she was functioning extremely well with the prosthesis and she retained the post grafting bony bases.

A 72-year-old partial edentulous Caucasian female was wearing a prosthesis inserted in the nasal floor to hold the upper denture. Moreover the patients have vertical and horizontal bone defect localized in the posterior mandible area. The patient’s past history was negative except for a reported period of 5 years previously having received psychiatric care. The surgical history of the patient included several mandibular surgical reconstructions with autogenous rib bone grafts in 1999 and with autogenous iliac crest bone graft in 2010 (**Figure 1**). Using a mix of autogenous bone, harvested from the right iliac crest, and freeze-dried demineralized bone, the surgeon performed the bone graft procedure.

The patient was noted to refer nausea on post-operative day 1, and was unable to ambulate adequately. At this time, the patient was given bed rest. The following day the nausea had subsided. Continuous IV hydration and IV antibiotics were given and, on day 3 postoperatively, the patient was able to utilize the walker with assistance. She was no longer nauseated. On day 4, the patient was able to ambulate without assistance of the nursing staff. The patient’s vital signs remained stable. She was afebrile throughout the entire course of the hospitalization and was discharged on post-op day 7 to be followed on an outpatient basis.

Approximately 4 months post-operatively, the patient presented at a nearby hospital with complaint of inability to walk and with generalized muscular weakness. At this point she was diagnosed as having a peripheral neurogenic disease, specifically GBS. The patient was hospitalized briefly at the Pasadena Hospital and then transferred to San Antonio Rehabilitating Center, where she remained for several weeks. She returned to our clinic 1 week after she was released from the rehabilitation center for further prosthodontic reconstruction. The patient was ambulating well and was without complaint. The prosthesis was constructed and the patient was restored to oral health.

## Discussion

GBS is a disease characterized by nerve demyelination developing progressively over the course of a few days, or several weeks. It may occur in all age groups, but it is more frequent in those over 40 years of age [1]. The incidence of Guillain-Barré syndrome in the United States is about 1.3/100,000 populations per year [3-5].

Care involves use of general supportive measures for the paralyzed patients, and also methods specifically designed to speed recovery, especially for those patients with major pre-existing clinical problems. The use of steroid therapy has also been tried as a way to reduce the severity of Guillain-Barré, but controlled clinical trials have demonstrated that this treatment not only is not effective, but also may even have a deleterious effect on the disease process itself [3-5].

The prognosis is good provided that respiratory function is maintained. Full recovery can usually be expected in young patients, whereas persistent disability is more likely to occur in the older patient, depending on the patient's general health, the rate of disease progression and the nerve involvement.

The two cases of Guillain-Barré syndrome reported were following OMS techniques in which banked freeze-dried allogeneic bone had been used in reconstructive procedures, with no prodromal infectious or vaccination incidents reported. Since donor selection and sterilizing techniques have demonstrated that many existing banking processing procedures do not inactivate particles, it seems appropriate to use alternative graft materials for this type of surgery.

## Acknowledgements

Author thank to Professor Phil J Boyne for great job made in the field of the bone graft and neurodegenerative disease.

## Disclosure of conflict of interest

None.

**Address correspondence to:** Dr. Marco Cicciù, Department of Oral Surgery, Dental School, Messina University Via Consolare Valeria 98100, Messina, Italy. Tel: 0039-90 221 6920; E-mail: acromarco@yahoo.it

## References

- [1] Waldock E. The pathophysiology of Guillain-Barré syndrome. *Br J Nurs* 1995; 4: 818-821.
- [2] McMahon-Parkes K, Cornock MA. Guillain-Barre syndrome: biological basis, treatment and care. *Intensive Crit Care Nurs* 1997; 13: 42-48.
- [3] Winer JB, Gray IA, Gregson NA, Hughes RA, Leibowitz S, Shepherd P, Taylor WA, Yewdall V. A prospective study of acute idiopathic neuropathy. III. Immunological studies. *J Neurol Neurosurg Psychiatry* 1988; 51: 619-25.
- [4] Achamkin I, Engberg J, Gutacker M, Meinersman RJ, Li CY, Arzate P, Teeple E, Fussing V, Ho TW, Asbury AK, Griffin JW, McKhann GM, Pifaretti JC. Molecular population genetic analysis of *Campylobacter jejuni* HS: 19 associated with Guillain-Barré syndrome and gastroenteritis. *J Infect Dis* 2001; 184: 221-6.
- [5] Sheikh KA, Ramos-Alvarez M, Jackson AC, Li CY, Asbury AK, Griffin JW. Overlap of pathology in paralytic rabies and axonal Guillain-Barre syndrome. *Ann Neurol* 2005; 57: 768-72.