

Role of autofluorescence bronchoscopy in evaluation of bronchial mucosa after lung transplantation

R. Carrinola MD, L. Rosso MD, A. Palleschi MD, D. Tosi MD, M. Montoli MD, M. Nosotti MD

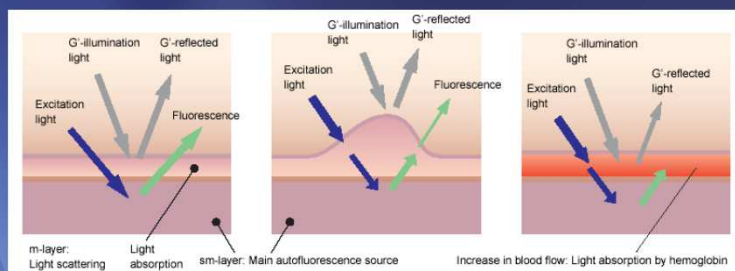
Department of Thoracic Surgery and Lung Transplantation Fondazione IRCCS Ca' Granda Ospedale Maggiore Policlinico Milan Italy

Background

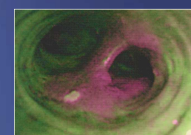
Airway complications are a significant and persistent source of morbidity and mortality after lung transplantation; the incidence of these complications is around 15% with a mortality rate of 2- 3%. Airway complications arise, typically, the first two years post-transplant, and of these almost half are identified prior to discharge; their pathogenesis, as well as to opportunistic infections, appear to be related to the difficult revascularization of the bronchi resulting in chronic ischemia

Objectives

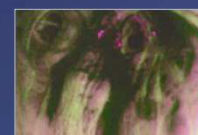Aim of this study is to find a relationship between the degree of vascularization of graft bronchial mucosa and the onset of complications of airway with the use of **autofluorescence bronchoscopy**. This method is currently used in oncology: the different blood supply of healthy mucosa from the pathological can identify precancerous lesions due to the different capacity of absorption of ultraviolet light. The increase in thickness of the mucosa precancerous, such as ischemia, prevent the absorption of frequencies of the red light by hemoglobin, and therefore the mucosa presents a bright red color as opposed to the "normal" color green



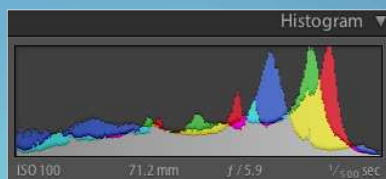
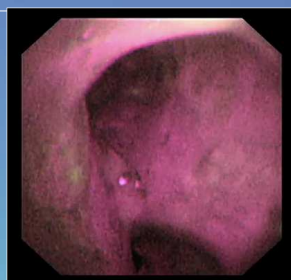
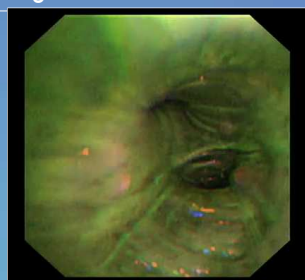
Normal mucosa



Dysplastic mucosa



Bleeding

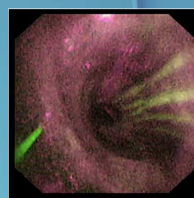


Methods

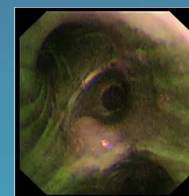
All consecutive patients transplanted in 2014 underwent to routine transbronchial lung biopsies: all procedures were performed with autofluorescence bronchoscopy (Olympus EVIS Lucera Spectrum AFI) weekly during the first month and next quarterly up to the first year of follow-up. All procedures was recorded on a USB storage device. The degree of fluorescence was measured using an histogram. The magenta color identifies the ischemic mucosa and the green color the normal vascularized mucosa. Results, in terms of intensity ratio (R/V ratio), were correlated with ischemia time of the graft and with the onset of complications of airways

Results

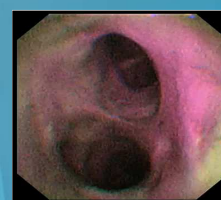
We enrolled 31 patients. In the face of an appearance substantially "normal" of the mucosa in white light, in the immediate postoperative period was recorded the highest percentage of ischemic mucosa (R/V= 1.66; normal value = 0.87), with a return to normal vasculature (green) which amounted on average to 30 days post transplant. It was noted a relationship trend between high time of cold ischemia of the graft and high R/V. A patient at six months after transplantation still had ischemic mucosa has developed a stenosis of the bronchus intermedius, treated with resorbable endobronchial stent placement



Intraoperative image
R/V 1,81



30 days control
R/V 0,98



6 months control
R/V 1,57

Conclusions

Autofluorescence bronchoscopy allows to evaluate the vascularity of the bronchial mucosa graft and provides a valuable tool in the prevention and control of the onset of endobronchial complications