

Stenosis of bronchus intermedius:

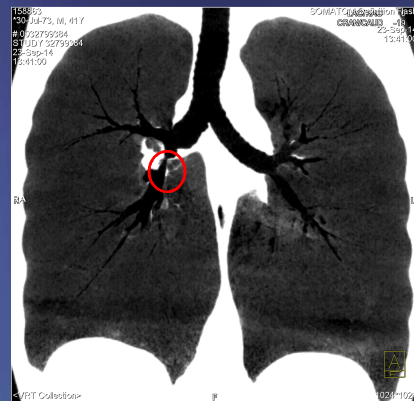
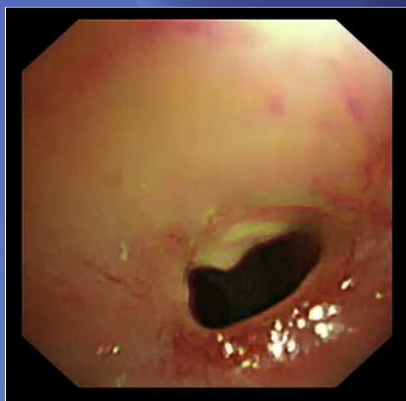
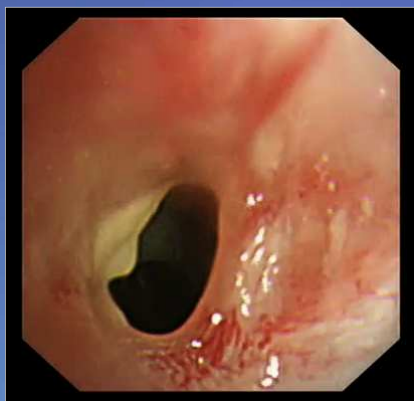
an unusual complication after transplantation and its treatment.

R. Carrinola MD, L. Rosso MD, I. Righi MD, P. Mendogni MD, F. Damarco MD, M. Nosotti MD

Department of Thoracic Surgery and Lung Transplantation Fondazione IRCCS Ca' Granda Ospedale Maggiore Policlinico Milan Italy

Background

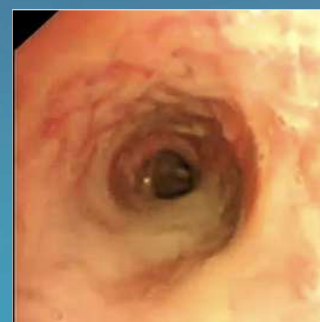
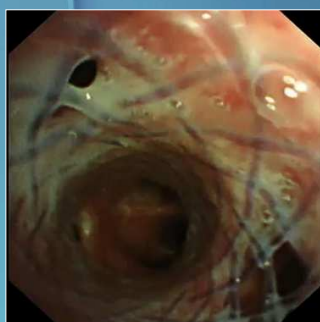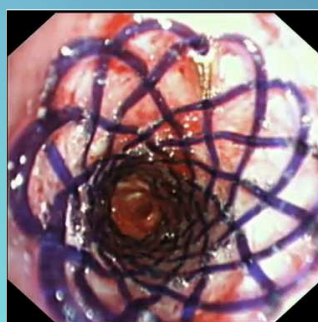Complications related to ischemia are the most important cause of morbidity and mortality after lung transplantation. Ischemia suffered by large bronchi during topical cooling and transplantation of the graft is considered the possible pathogenic noxa for late stenosis as well as a possible cause of anastomotic leak or ulceration of the mucosa. It seems to emerge from the literature that the bronchus intermedius may be particularly prone to ischemia and may undergo stenosis late after transplantation.



Pulmonary Function Tests before treatment FVC 4.99 L, 102%; FEV1 3.47 L, 86%

Case Report

Two patients, underwent bilateral lung transplantation for cystic fibrosis in 2014, developed in the first six months after transplantation stenosis of the bronchus intermedius. During routine endoscopic and radiologic examinations there was evidence of ischemic bronchial mucosa with stenosis of the lumen of the bronchus intermedius with normal patency of the anastomosis. One of the two patients underwent two sessions of pneumatic dilations with immediate good result. At time of the next endoscopic control for surveillance transbronchial lung biopsy, also a decline of FEV1 was present. Bronchoscopy revealed a recurrence of bronchial stenosis. It was therefore decided to place a bronchial resorbable uncoated stent (ELLA-CS, Kralove, Czech R.). The other patient was treated directly with both pneumatic dilatation and resorbable stent placement. There was an immediate recovery of the respiratory function (increase 20% of FEV1) in both patients that was maintained at five months after placement. There was no evidence of infections or bronchial obstructions due to secretions. There was no need of further pneumatic dilations. Five months after positioning, the stent was completely absorbed and bronchial lumen diameter preserved.



resorbable uncoated stent

stenting

1 month after stenting

3 months after stenting

Pulmonary Function Tests post treatment FEV1 4,51 L, 112% FVC 6,05 L, 124% FEV1/FVC 75, 93%

Conclusions

Stenosis of the bronchus intermedius is a late complication after transplantation that is beginning to be recognized in the literature as an autonomous entity. It is likely that the revascularization of this long bronchial segment can be delayed or deficient in certain peculiar anatomical situations. The prompt diagnosis of this complication and its aggressive treatment can be the basis of optimal recovery of respiratory function.