

Clinical Study

Zirconia Implants in Esthetic Areas: 4-Year Follow-Up Evaluation Study

Andrea Enrico Borgonovo,¹ Rachele Censi,² Virna Vavassori,¹ Oscar Arnaboldi,³
Carlo Maiorana,³ and Dino Re⁴

¹School of Oral Surgery, University of Milan, Department of Oral Rehabilitation, Istituto Stomatologico Italiano, 20122 Milan, Italy

²Department of Implantology and Periodontology, Istituto Stomatologico Italiano, 20122 Milan, Italy

³Department of Implantology, Dental Clinic, Fondazione IRCCS Cà Granda Ospedale Maggiore Policlinico, School of Oral surgery, University of Milan, 20122 Milan, Italy

⁴Head Department of Oral Rehabilitation, Istituto Stomatologico Italiano, 20122 Milan, Italy

Correspondence should be addressed to Virna Vavassori; virna.vavassori@hotmail.it

Received 16 April 2014; Revised 24 August 2014; Accepted 7 September 2014

Academic Editor: Burak Demiralp

Copyright © 2015 Andrea Enrico Borgonovo et al. This is an open access article distributed under the Creative Commons Attribution License, which permits unrestricted use, distribution, and reproduction in any medium, provided the original work is properly cited.

Objectives. The aim is to evaluate the survival and success rates, as well as the marginal bone loss (MBL) and periodontal indexes of zirconia implants positioned in the esthetic jaw areas. **Materials and Method.** 13 patients were selected and 20 one-piece zirconia implants were used for the rehabilitation of single tooth or partially edentulous ridge in the esthetic jaw areas. Six months after surgery and then once a year, a clinical-radiographic evaluation was performed in order to estimate peri-implant tissue health and marginal bone loss. **Results.** The survival and success rates were 100%. The average marginal bone loss from baseline to 48 months after surgery was +2.1 mm. Four years after surgery, the median and the mode for visible Plaque Index and Bleeding On Probing resulted 1 whereas Probing Pocket Depth amounted to 3 mm (SD = ±0.49 mm). **Conclusion.** One-piece zirconia dental implants are characterized by high biocompatibility, low plaque adhesion, and absence of microgap that can be related to the clinical success of these implants even in the esthetic areas.

1. Introduction

The original concept of implant surgery as described by Branemark [1] is that the fixture is placed in the bone and completely covered by mucoperiosteal flaps. After the healing period of at least 3 months in the mandible and up to 6 months in the maxilla, the implant is exposed and a healing abutment is connected.

Since the material composition and the surface topography of the implants play a fundamental role in osseointegration, various chemical and physical surface modifications have been developed in order to reduce the time of osseous healing, and it was observed that increased surface roughness of dental implants resulted in greater bone apposition [2] and reduced healing time [3]. However, even if the original protocol by Branemark was modified by modern works

of research, patients expect a rehabilitation to be finalized within the shortest time span possible especially if the edentulism involves the esthetic regions. Moreover, patients require implants that are esthetic as well as functional and, for this reason, more recently higher interest is directed towards the esthetic of the prosthetic rehabilitations.

The use of ceramic components based on alumina or yttrium-stabilized zirconium oxide in conjunction with all-ceramic restorations allows to achieve implant osseointegration, which was examined in several animal experiments [4–6], and to solve esthetic problems. In fact, even if several studies reported high success rates for titanium dental implants [7], it is important to consider that bone resorption of the vestibular cortical bone and recession of the peri-implant soft tissue can occur over time [8]. Consequently, the titanium components may be visible and cause discoloration

of the gingiva, particularly in cases of thin biotype and high smile line [9]. The first ceramic material that was used in the past for dental implants was aluminium oxide. This material showed good osseointegration but it did not have sufficient mechanical properties for long-term loading [10]. More recently, new generation ceramic materials such as zirconia were introduced. Zirconia is characterized by more favorable mechanical properties (high flexural strength (900–1200 Mpa), hardness (1200 Vickers), and Weibull modulus (10–12)) than aluminium oxide. In addition, this biomaterial has a high biocompatibility and low plaque adhesion [11], and several animal studies showed bone-to-implant contact similar to titanium [5, 6, 12]

The aim of this study is to evaluate the survival and success rates, the marginal bone loss (MBL), radiographic measurements, and periodontal indexes (Plaque Index (PI), Bleeding On Probing (BOP), Probing Pocket Depth (PPD), and implant mobility) of zirconia dental implants positioned in the maxillary and mandibular esthetic areas.

2. Materials and Methods

At the Department of Implantology, Dental Clinic, Fondazione IRCCS Cà Granda Policlinico, University of Milan, the authors did a retrospective study of patients treated using monocomponent endosseous zirconia dental implants for the rehabilitation of esthetic areas.

22 one-piece endosseous dental implants made of sintered and yttrium-stabilized zirconium oxide were used for the rehabilitation of single tooth or partially edentulous ridge in the esthetic areas in the maxilla or the mandible. It was considered that the esthetic zone of the jaw includes the central and lateral incisors, the canines, and the first premolars.

The implants used in the clinical study are made of sintered and yttrium-stabilized zirconium oxide (WhiteSky, Bredent, Senden, Germany) and are featured by a conical implant body and a double, cylindrical thread. The endosteal portion has a sandblasted surface, whereas, transmucosally, the implant includes a machined neck with a height of 2 mm. The implant surface is treated with a sanding process. The microscopical surface characteristics of medium rugosity (Ra 0.9-1 μm) are similar to the surface of last-generation machine-finished titanium implants.

The abutment surface is smooth and it has a length of 6.8 mm which can be modified by grinding after implant positioning.

For this study, 14 patients in need of a single or multiple teeth replacements in the maxillary esthetic areas were selected (Figures 1, 2, and 3). All sites should present adequate bone volume (minimum bone height and thickness, respectively, of 8 and 5.5 mm). Implants positioned in regenerated bone were excluded from this protocol because the regenerative procedures associated with implant rehabilitation can influence the results in terms of marginal bone loss. In fact, it has been demonstrated that the marginal bone loss is greater in the regenerated bone than in the native bone [13]. Moreover, patients with oral problems such as

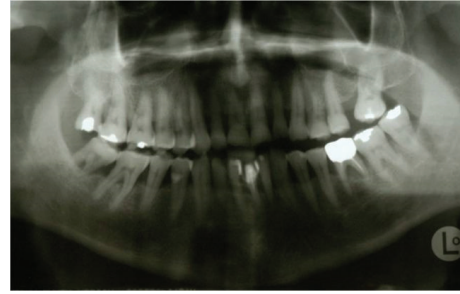


FIGURE 1: Preoperative orthopantomography.

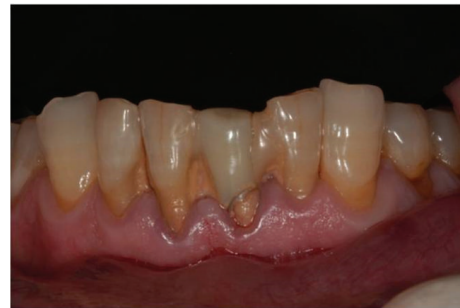

FIGURE 2: Preoperative clinical view.

active periodontal disease or parafunctions, bisphosphonates treatment, smoking more than 10 cigarettes per day, poor oral hygiene, and low compliance and patients with previous or concomitant systemic diseases such as immunodeficiency, head and neck radiotherapy, metabolic disorders, and hematological diseases, together with patients under 18 years of age were not included in this study.

All patients were previously informed about zirconia implants and possible alternatives and gave a written consent. Seven days before surgery, the patients underwent professional oral hygiene and they were instructed to start rinsing mouth twice a day with chlorhexidine 0.2% (Corsodyl, Glaxo, UK) until two weeks after surgery. Antibiotic prophylaxis with 2 gr of Amoxicillin and Clavulanic Acid (Laboratori Eurogenerici, Milan, Italy) was prescribed 1 hour prior to surgery.

The surgical procedure has involved the positioning of implants according to the protocol suggested by Bredent Medical, which is similar to the standard surgical protocol for titanium dental implants. All implants were inserted using a guide device prepared on a diagnostic wax-up (Figure 4). Mucoperiosteal flaps were elevated avoiding vertical releasing incisions in order to reduce the risk of blemishes. After preparing the implant sites, fixture insertion was performed by a surgical microengine. The fixtures were screwed until the rough surface of the implant body was positioned completely inside the bone, whereas implant abutment with smooth neck performed the function of the transmucosal element (Figure 5). All the implants were placed in the correct three-dimensional positioning according to esthetic protocol by Tarnow et al. [14]. Flaps were released through periosteal incisions to attain primary wound closure, and, at the end,

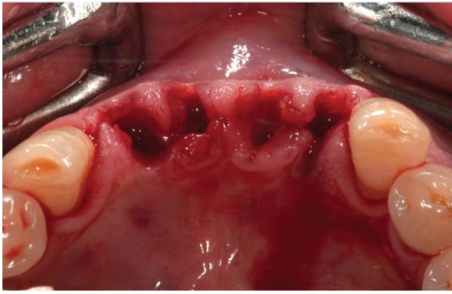


FIGURE 3: Dental extractions.

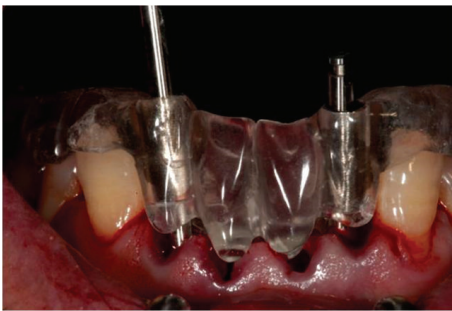


FIGURE 4: Surgical guide.

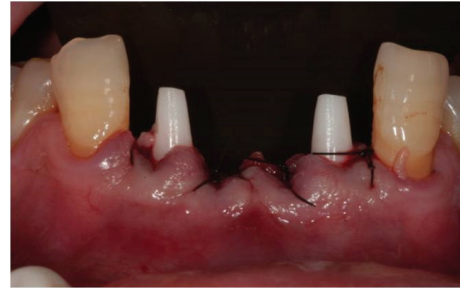

FIGURE 5: Two monocomponent zirconia implants are placed in the areas 3.2 and 4.2.

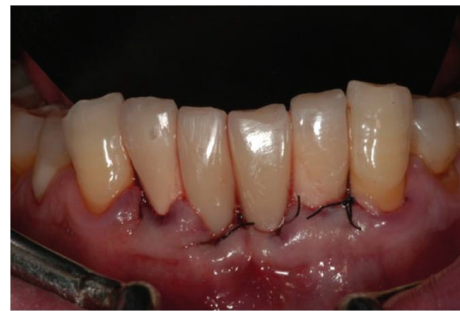

FIGURE 6: Immediate temporary restoration.

flaps were sutured with 4/0 monofilament suture (Premilene, Braun Melsungen, Germany).

After implant insertion, standardized periapical radiography using the Rinn alignment system (Dentsply, Konstanz, Germany) with customized silicon bites (Orthogum Zermack, Badia Polesine, Rovigo, Italy) was obtained. The radiographic control was permitted to evaluate the correct positioning of implants.

Immediately after surgery, considering that zirconium oxide ceramics are bad thermal conductors, implant abutments were refined in order to correct their axis, length, or undercuts if present, using double diamond burs suited for zirconia (ETERNA Bredent, Senden, Germany) and water cooling. Temporary restorations obtained from diagnostic wax-up were relined with acrylic resin and luted with temporary cement (TEMPBOND, Kerr West Collins Orange, CA, USA). Single restorations were attached to the adjacent teeth by means of composite bonding, whereas multiple implants were connected together by provisional restoration in order to reduce the risk of implant mobility or extra occlusal load (in particular, tongue and lips movements) (Figure 6).

Patients were given oral hygiene suggestions and were instructed not to chew or eat on implant site until healing was completed. Antibiotic therapy (1 gr every 8 hours) and chlorhexidine mouth rinses were continued for 7 days, and Paracetamol 500 mg (Tachipirina, Angelini, Rome, Italy) was prescribed to use if necessity was felt. Sutures were removed 7 days after surgery and follow-up controls were programmed after 1 week, 2 weeks, and, subsequently, once a month for the following 6 months.

Six months after the surgery (Figures 7 and 8), definitive impressions (IMPREGUM, 3M, ESPE, St Paul, MN, USA)

were taken using a retraction cord (Ultrapak Cord, Ultradent, South Jordan, UT, USA) or an impression cap to register implant shoulder margins. The definitive restorations were made with CAD-CAM system (LAVA, 3M, ESPE, St Paul, MN, USA) (Figure 9) and cemented with glass ionomer cement (GC Fuji CEM, GC America, Alsip, IL, USA) (Figure 10).

One week after definitive restorations delivery and, subsequently, every year after implants placement, clinical-radiographic evaluation was performed. The periodontal evaluation was performed using a calibrated probe (Hu-Friedy, N. Rockwell Chicago, IL, USA) and the following periodontal indexes were investigated: Plaque Index (PI), Bleeding On Probing (BOP), Probing Pocket Depth (PPD), and implant mobility.

Moreover, the follow-up protocol included the radiographic control examination (Figures 10 and 11). The radiographs were taken using the customized silicon bite record prepared immediately after surgery. The radiographs were converted in digital images with a scanner (Epson 1680 Pro, Seiko Epson Cooperation, Nagano, Japan) and saved in JPG format. Each image was processed with a specific piece of software (CorelDraw 10.0; Corel Corp and Coral Ltd., Ottawa, Canada) and analyzed at $\times 20$ magnification in order to calculate marginal bone loss. Mesial and distal marginal bone levels of all the implants were measured at baseline and on recall evaluations. The known length of the implant (measured from the implant shoulder to the implant apex) according to the manufacturer was used as a reference point. The distance from implant shoulder to crestal bone level was measured on the magnified images. To analyze the variability,

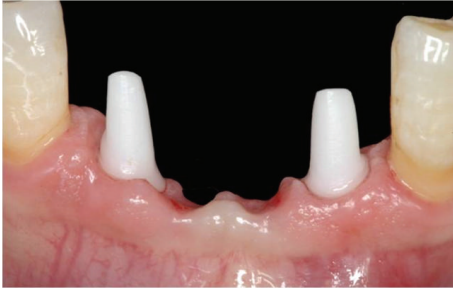

FIGURE 7: Soft tissue health 6 months after surgery.

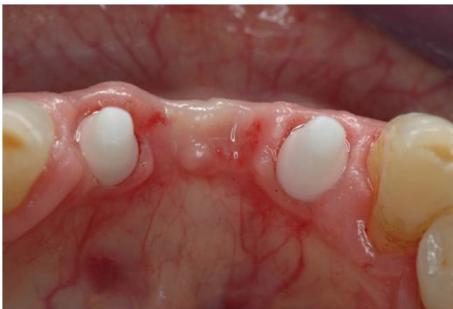

FIGURE 8: Occlusal view.

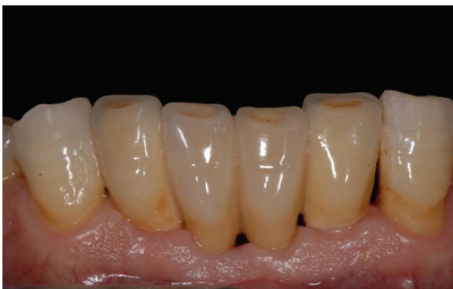

FIGURE 9: Definitive restoration.

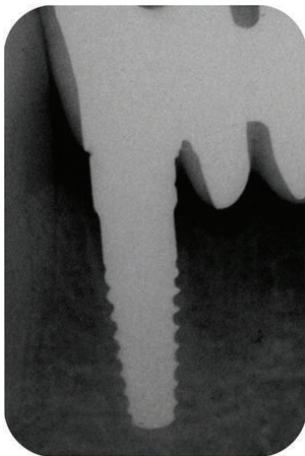


FIGURE 10: X-ray image of the zirconia implant placed in area 4.2, six months after surgery.

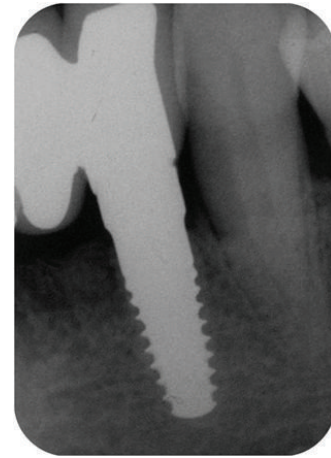


FIGURE 11: X-ray picture of the zirconia implant placed in area 3.2, six months after surgery.

the implant dimension (length) on the magnified X-ray was measured and compared to the real dimension, and ratios were calculated to adjust for distortion. Bone level changes were calculated at the distal and mesial surfaces of all implants by applying the distortion coefficient.

Data analysis was performed with descriptive statistics and the arithmetic mean; the median and the standard deviations were calculated. Clinical and radiographic control examination was repeated every year (Figures 12, 13, and 14).

At the end, success criteria and survival criteria were formulated in accordance with Albrektsson criteria for implants success [15]. Survival criteria were identified as the survival of loaded functionalized asymptomatic implants, whereas success criteria refer to four parameters, absence of implant mobility, absence of self-reported pain or paresthesia, absence of peri-implant radiolucency, and marginal bone loss inferior to 1.5 mm in the first year and to 0.2 mm in the following years.

3. Results

At the Department of Implantology, Dental Clinic, IRCCS Fondazione Cà Granda Ospedale Maggiore Policlinico, University of Milan, 14 patients were treated for the rehabilitation of the esthetic jaw areas. Average age was 60 years (ranging from 38 to 75 years), 13 male patients and one female. Starting from January 2007 and recruited in a period of one year, 14 patients were included in the study. The data were recorded to July 2012 when the implants had a minimal observation period of 4 years.

17 implants were placed in the maxilla, whereas 5 implants were placed in the mandible.

Considering the maxillary implants, 10 zirconia dental implants were used for the rehabilitation of single or multiple cases of edentulism in the incisor region; 3 implants replaced the canines, and the other 4 maxillary implants were placed in place of the missing first premolars. All mandibular implants were used for the rehabilitation of edentulism in the incisor

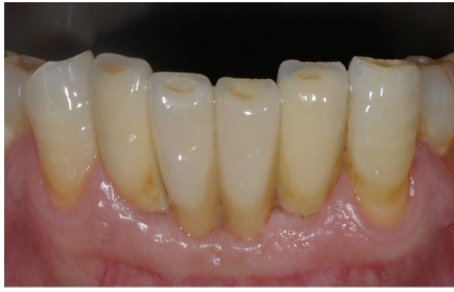

FIGURE 12: Clinical control 4 years after surgery.

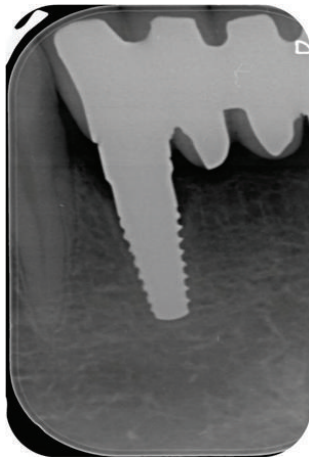


FIGURE 13: Radiographic control 4 years after implant insertions.

region, except 2 implants that were positioned in area of the missing right mandibular first premolar.

Considering patients' selection criteria, one patient with two implants placed in places of the upper right canine and the first premolar was excluded from this protocol because regenerative procedures were performed. For this reason, the data reported in this study refer exclusively to 20 implants. The follow-up period ranged from 6 to 48 months after implant insertion.

During the 48 months of follow-up, no implant failure was reported, with no pain or paresthesia, and, at the radiographic evaluation, peri-implant radiolucency was not detected. Thus, the cumulative survival rate was 100% after 4 years.

At follow-up controls, the median for PI and BOP was 1 and 0, respectively, and the mean values of PI and BOP were 0.54 and 0.23, respectively.

48 months after surgery, the median and the mode for visible Plaque Index (PI) and Bleeding On Probing (BOP) resulted 1. Overall Probing Pocket Depth (PPD) amounted to 3 mm (SD = ± 0.49 mm). Mobility was not present at any site, and no pain (spontaneous or on percussion) or paresthesia was reported.

The mean marginal bone level after 4 years was +2,1045 mm, without a difference between mesial and distal sites. In particular, mean marginal bone loss was +1.50 mm

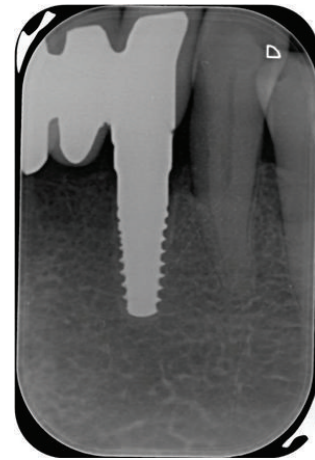


FIGURE 14: Radiographic control 4 years after implant insertions.

(SD = ± 1.03) 6 months after implant insertion and +0.446 mm (SD = ± 0.64) 6 months after prosthetic finalization.

From 1 year up to 2 years after implant positioning, an improvement of peri-implant bone level value was observed probably due to the formation of new bone trabeculae as a result of maturation of bone (-0.198 ± 0.50 mm).

A minimal bone remodeling with a further marginal bone loss of +0.18 mm (SD = ± 0.28) and +0.17 mm (SD = ± 0.11), respectively, was also observed at 3 and 4 years follow-up.

For implants placed in the maxilla, the average marginal bone loss from baseline to 6 months after surgery was +1.50 \pm 1.03 mm, from 6 months to 1 year was +0.65 \pm 0.7 mm, from 1 year to 2 years was -0.12 ± 0.57 mm, from 2 years to 3 years was +0.12 \pm 0.25 mm, and from 3 years to 4 years was -0.17 ± 0.11 mm.

Four patients were treated for multiple cases of edentulism with 8 zirconia dental implants, and, after surgery, all multiple implants were splinted together by provisional restoration. Considering the marginal bone loss adjacent to free-standing implants and multiple implants, it was observed that there is a statistically significant difference between the two groups ($P = 0.799$).

The success rate was 100%.

4. Discussion

The clinical success of the implant rehabilitation is in connection with the interface between bone tissue and implants surface. Several studies showed successful osseointegration of zirconia dental implants in different animal models [5–7, 12]. In the work by Thomsen et al. [16], the interface between the rabbit tibia bone tissue and the surfaces of gold, titanium, and zirconia implants was investigated, and the histological examination disclosed that the bone-implant contact ratio (BIC) is similar for zirconia and titanium implants, whereas gold implants had a lower degree of BIC. In the study by Scarano et al. [17], a great amount of newly formed bones was observed in close contact with the surfaces of zirconia implants positioned in rabbits, and the BIC ratio was 68%. Furthermore, the BIC ratio was better investigated by

Akagawa et al. [18] who demonstrated that the bone-implant contact ratio ranged from 54% to 69.8% at 12 months and from 66.2% to 67.7% at 24 months.

The bone-implant contact ratio is the result of bone formation, and it is related to the characteristics of implant surface. Sennerby et al. [19] evaluated the bone tissue reaction to titanium implants and zirconia dental implants with and without different surface modifications. The titanium implants and the zirconia implants with the surface modifications showed the highest surface roughness in comparison to the nonmodified zirconia implants, and, consequently, machined implants presented a lower degree of BIC than titanium and modified zirconia implants.

The reported studies demonstrate a bone-implant contact for zirconia dental implants, similar to those of titanium implants, and these findings suggest that zirconia dental implants can reach firm stability in bones.

More recently, the osseointegration of zirconia dental implants was histologically demonstrated in one human patient [20]. In this study, a two-piece zirconia implant was placed in the maxilla of a healthy woman and 6 months after surgery, the retrieval of the dental implant was performed. The surrounding soft and hard tissues were harvested and processed for histological evaluation. The processed sample of zirconia dental implant provided the histological evidence of osseointegration. Moreover, the scanning electron microscopic analyses showed a good maintenance of the crestal bone level; in fact, it was possible to evaluate that the first bone-to-implant contact was occlusal to the implant-abutment junction.

This finding can be related to the excellent characteristics of zirconia dental implants which present high biocompatibility and low plaque adhesion [17, 21]. In fact, it is important to note that a bacterial adhesion to implant surfaces is the first stage of peri-implant mucositis and peri-implantitis with the resulting loss of the supporting bone in the tissues surrounding the implants [22]. On the contrary, the reduction of bacterial adhesion on the surface of zirconia dental implants promotes early formation of the biological width and, therefore, the formation of a mucosal seal that stops early marginal bone resorption. As demonstrated by Scarano et al. [23], zirconium oxide surfaces showed a significant reduction of the presence of bacteria, and this fact is probably important for the health of the peri-implant soft tissues.

Moreover, the implant system adopted in our study is characterized by monocomponent dental implants. Several studies have shown that bone resorption around the implant neck is related to the presence of the microgap between implant and abutment [14, 24, 25]. This microgap leads to bacterial leakage and a microbial colonization of the gap at the bone level. Peri-implant soft tissues develop an inflammatory response which promotes osteoclast formation and activation to result in alveolar bone loss. According to the authors, the reduction of marginal bone loss is mainly due to the one-piece morphology of zirconia dental implants, through which there is no implant-abutment microgap and its microbial contamination; there are no micromovements of the prosthetic component and repeated screwing and unscrewing [26, 27].

For these reasons, it has been proposed that peri-implant marginal bone loss is more extended around two-piece implants than around one-piece implants as a result of the location of the microgap [28–30].

Another retrospective study suggests that zirconia endosseous implants can achieve a survival rate similar to that of titanium implants with healthy and stable soft and hard tissues. In the work by Brüll et al. [31] 121 zirconia implants (66 two-piece implants and 55 one-piece implants) were inserted in 74 patients. After a mean observation period of 18 months, the cumulative implant survival rate was of 96.5%. The clinical examination revealed that PPD and BOP were statistically significantly lower around implants than around teeth (mean PPD of 1.8 ± 0.4 mm – mean BOP scores of $4.1\% \pm 4.2\%$), whereas the radiographic evaluation demonstrated that peri-implant marginal bone levels were stable (mean bone loss of 0.1 ± 0.6 mm) after 3-year follow-up.

Even if the results regarding the rehabilitation of the esthetic areas with zirconia monocomponent implants are encouraging, further scientific information concerning the clinical use of zirconia dental implants is needed, as well as prospective long-term clinical studies in order to understand whether zirconia implants may represent a valid alternative to titanium implants.

5. Conclusion

In this study, it was evaluated that there is a preservation of the crestal bone adjacent to zirconia dental implants. In particular, the radiographic measurements of marginal bone loss showed values below 0.9–1.6 mm during the first year in function and not exceeding 0.2 mm 1 year up to 4 years after surgery in accordance with Albrektsson implant success criteria [15]. This finding can be related to some properties which characterize zirconia dental implants. These properties are the high biocompatibility of zirconia surfaces, the low plaque adhesion on zirconia dental implants, and the absence of microgap between fixture and abutment [32, 33].

Conflict of Interests


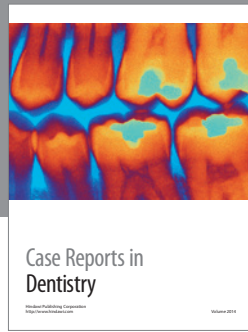
All the authors declare that they do not have any conflict of interests regarding the publication of the current work.

References

- [1] P. I. Brånemark, B. O. Hansson, R. Adell et al., “Osseointegrated implants in the treatment of the edentulous jaw. Experience from a 10-year period,” *Scandinavian Journal of Plastic and Reconstructive Surgery. Supplementum*, vol. 16, pp. 1–132, 1977.
- [2] D. Buser, N. Broggini, M. Wieland et al., “Enhanced bone apposition to a chemically modified SLA titanium surface,” *Journal of Dental Research*, vol. 83, no. 7, pp. 529–533, 2004.
- [3] D. L. Cochran, D. Buser, C. M. Ten Bruggenkate et al., “The use of reduced healing times on ITI implants with a sandblasted and acid-etched (SLA) surface: early results from clinical trials on ITI SLA implants,” *Clinical Oral Implants Research*, vol. 13, no. 2, pp. 144–153, 2002.

- [4] R. J. Kohal, D. Weng, M. Bächle, and J. R. Strub, "Loaded custom-made zirconia and titanium implants show similar osseointegration: an animal experiment," *Journal of Periodontology*, vol. 75, no. 9, pp. 1262–1268, 2004.
- [5] L. Sennerby, A. Dasmah, B. Larsson, and M. Iverhed, "Bone tissue responses to surface-modified zirconia implants: a histomorphometric and removal torque study in the rabbit," *Clinical Implant Dentistry and Related Research*, vol. 7, no. 1, pp. S13–S20, 2005.
- [6] M. Gahlert, T. Gudehus, S. Eichhorn, E. Steinhauser, H. Kniha, and W. Erhardt, "Biomechanical and histomorphometric comparison between zirconia implants with varying surface textures and a titanium implant in the maxilla of miniature pigs," *Clinical Oral Implants Research*, vol. 18, no. 5, pp. 662–668, 2007.
- [7] P. I. Brånemark, B. O. Hansson, R. Adell et al., "Osseointegrated implants in the treatment of the edentulous jaw. Experience from a 10-year period," *Scandinavian journal of plastic and reconstructive surgery. Supplementum*, vol. 16, pp. 1–132, 1977.
- [8] G. Heydecke, R. Kohal, and R. Gläser, "Optimal esthetics in single-tooth replacement with the Re-Implant system: a case report," *International Journal of Prosthodontics*, vol. 12, no. 2, pp. 184–189, 1999.
- [9] A. Wohlwend, S. Studer, and P. Schärer, "The zirconium oxide abutment—a new all-ceramic concept for esthetically improving suprastructures in implantology," *Quintessenz Zahntechnik*, vol. 22, pp. 364–381, 1996 (German).
- [10] W. Schulte and B. d'Hoedt, "Thirteen years of the Tubigen implant system made by Frialit—additional results," *Zeitschrift für Zahnärztliche Implantologie*, vol. 3, pp. 167–172, 1988 (German).
- [11] A. Scarano, F. Di Carlo, M. Quaranta, and A. Piattelli, "Bone response to zirconia ceramic implants: an experimental study in rabbits," *The Journal of Oral Implantology*, vol. 29, no. 1, pp. 8–12, 2003.
- [12] R. Depprich, H. Zipprich, M. Ommerborn et al., "Osseointegration of zirconia implants: an SEM observation of the bone-implant interface," *Head and Face Medicine*, vol. 4, no. 1, article 25, 2008.
- [13] N. U. Zitzmann, P. Schärer, and C. P. Marinello, "Long-term results of implants treated with guided bone regeneration: a 5-year prospective study," *International Journal of Oral and Maxillofacial Implants*, vol. 16, no. 3, pp. 355–366, 2001.
- [14] D. P. Tarnow, S. C. Cho, and S. S. Wallace, "The effect of inter-implant distance on the height of inter-implant bone crest," *Journal of Periodontology*, vol. 71, no. 4, pp. 546–549, 2000.
- [15] T. Albrektsson, G. Zarb, P. Worthington, and A. R. Eriksson, "The long-term efficacy of currently used dental implants: a review and proposed criteria of success," *The International Journal of Oral & Maxillofacial Implants*, vol. 1, no. 1, pp. 11–25, 1986.
- [16] P. Thomsen, C. Larsson, L. E. Ericson, L. Sennerby, J. Lausmaa, and B. Kasemo, "Structure of the interface between rabbit cortical bone and implants of gold, zirconium and titanium," *Journal of Materials Science: Materials in Medicine*, vol. 8, no. 11, pp. 653–665, 1997.
- [17] A. Scarano, F. Di Carlo, M. Quaranta, and A. Piattelli, "Bone response to zirconia ceramic implants: an experimental study in rabbits," *The Journal of oral implantology*, vol. 29, no. 1, pp. 8–12, 2003.
- [18] Y. Akagawa, R. Hosokawa, Y. Sato, and K. Kamayama, "Comparison between freestanding and tooth-connected partially stabilized zirconia implants after two years' function in monkeys: a clinical and histologic study," *The Journal of Prosthetic Dentistry*, vol. 80, no. 5, pp. 551–558, 1998.
- [19] L. Sennerby, A. Dasmah, B. Larsson, and M. Iverhed, "Bone tissue responses to surface-modified zirconia implants: a histomorphometric and removal torque study in the rabbit," *Clinical Implant Dentistry and Related Research*, vol. 7, supplement 1, pp. S13–S20, 2005.
- [20] M. Nevins, M. Camelo, M. L. Nevins, P. Schupbach, and D. M. Kim, "Pilot clinical and histologic evaluations of a two-piece zirconia implant," *The International journal of periodontics & restorative dentistry*, vol. 31, no. 2, pp. 157–163, 2011.
- [21] M. G. Doyle, C. J. Goodacre, C. A. Munoz, and C. J. Andres, "The effect of tooth preparation design on the breaking strength of Dicor crowns: 3," *The International Journal of Prosthodontics*, vol. 3, no. 4, pp. 327–340, 1990.
- [22] L. W. Lindquist, G. E. Carlsson, and T. Jemt, "A prospective 15-year follow-up study of mandibular fixed prostheses supported by osseointegrated implants: clinical results and marginal bone loss," *Clinical Oral Implants Research*, vol. 7, no. 2, pp. 329–336, 1996.
- [23] A. Scarano, M. Piattelli, S. Caputi, G. A. Favero, and A. Piattelli, "Bacterial adhesion on commercially pure titanium and zirconium oxide disks: an in vivo human study," *Journal of Periodontology*, vol. 75, no. 2, pp. 292–296, 2004.
- [24] J. S. Hermann, D. L. Cochran, P. V. Nummikoski, and D. Buser, "Crestal bone changes around titanium implants. A radiographic evaluation of unloaded nonsubmerged and submerged implants in the canine mandible," *Journal of Periodontology*, vol. 68, no. 11, pp. 1117–1130, 1997.
- [25] N. Brogгинi, L. M. McManus, J. S. Hermann et al., "Persistent acute inflammation at the implant-abutment interface," *Journal of Dental Research*, vol. 82, no. 3, pp. 232–237, 2003.
- [26] G. Rasperini, M. Maglione, P. Cocconcelli, and M. Simion, "In vivo early plaque formation on pure titanium and ceramic abutments: a comparative microbiological and SEM analysis," *Clinical Oral Implants Research*, vol. 9, no. 6, pp. 357–364, 1998.
- [27] T.-J. Oh, J. Yoon, C. E. Misch, and H.-L. Wang, "The causes of early implant bone loss: myth or science?" *Journal of Periodontology*, vol. 73, no. 3, pp. 322–333, 2002.
- [28] A. E. Borgonovo, A. Fabbri, V. Vavassori, R. Censi, and C. Maiorana, "Multiple teeth replacement with endosseous one-piece yttrium-stabilized zirconia dental implants," *Medicina Oral, Patologia Oral y Cirugia Bucal*, vol. 17, no. 6, pp. 981–987, 2012.
- [29] A. E. Borgonovo, V. Vavassori, R. Censi, J. L. Calvo, and D. Re, "Behavior of endosseous one-piece yttrium stabilized zirconia dental implants placed in posterior areas," *Minerva Stomatologica*, vol. 62, no. 7-8, pp. 247–257, 2013.
- [30] A. Borgonovo, R. Censi, M. Dolci, V. Vavassori, A. Bianchi, and C. Maiorana, "Use of endosseous one-piece yttrium-stabilized zirconia dental implants in premolar region: a two-year clinical preliminary report," *Minerva Stomatologica*, vol. 60, no. 5, pp. 229–241, 2011.
- [31] F. Brüll, A. J. van Winkelhoff, and M. S. Cune, "Zirconia dental implants: a clinical, radiographic and microbiologic evaluation up to 3 years," *The International Journal of Oral & Maxillofacial Implants*, vol. 29, no. 4, pp. 914–920, 2014.

- [32] A. E. Borgonovo, O. Arnaboldi, R. Censi, M. Dolci, and G. Santoro, "Edentulous jaws rehabilitation with yttrium-stabilized zirconium dioxide implants: two years follow-up experience," *Minerva stomatologica*, vol. 59, no. 7-8, pp. 381-392, 2010.
- [33] A. E. Borgonovo, R. Censi, V. Vavassori et al., "Evaluation of the success criteria for zirconia dental implants: a four-year clinical and radiological study," *International Journal of Dentistry*, vol. 2013, Article ID 463073, 7 pages, 2013.



Hindawi
Submit your manuscripts at
<http://www.hindawi.com>

