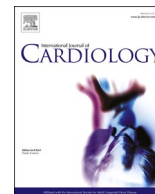




Contents lists available at ScienceDirect

International Journal of Cardiology

journal homepage: www.elsevier.com/locate/ijcard

Interpretation and management of premature ventricular beats in athletes: An expert opinion document of the Italian Society of Sports Cardiology (SICSPORT)

Alessandro Zorzi ^a, Flavio D'Ascenzi ^b, Daniele Andreini ^{c,d}, Silvia Castelletti ^e, Michela Casella ^{f,o}, Elena Cavarretta ^{g,h}, Alberto Cipriani ^a, Paolo Compagnucci ^{f,i}, Pietro Delise ^j, Antonio Dello Russo ^{f,i}, Francesca Graziano ^a, Zefferino Palamà ^{k,l}, Antonio Pelliccia ^m, Patrizio Sarto ⁿ, Domenico Corrado ^{a,*}, Luigi Sciarra ^l

^a Department of Cardiac, Thoracic and Vascular Sciences and Public Health, University of Padua, Italy

^b Department of Medical Biotechnologies, Sports Cardiology Unit, University of Siena, Italy

^c Division of University Cardiology, IRCCS Ospedale Galeazzi Sant'Ambrogio, Milan, Italy

^d Department of Biomedical and Clinical Sciences, University of Milan, Milan, Italy

^e Department of Cardiology, Istituto Auxologico Italiano IRCSS, Milan, Italy

^f Cardiology and Arrhythmology Clinic, Marche University Hospital, Ancona, Italy

^g Department of Medical-Surgical Sciences and Biotechnologies, Sapienza University of Rome, Latina, Italy

^h Mediterranea Cardiocentro, Napoli, Italy

ⁱ Department of Biomedical Sciences and Public Health, Marche Polytechnic University, Ancona, Italy

^j U.O. di Cardiologia, Ospedale P. Pederzoli, Peschiera del Garda and Centro di Medicina, Poliambulatorio di Mestre e Conegliano, Italy

^k Cardiology Department, Casa di Cura "Villa Verde", Taranto, Italy

^l Department of Life, Health and Environmental Sciences, University of L'Aquila, L'Aquila, Italy.

^m Institute of Sport Medicine and Science, Rome, Italy

ⁿ UO Sports Medicine, Regional Center for Exercise Prescription in Young Patients with Heart Diseases, ULSS2 Marca Trevigiana, Treviso, Italy

^o Department of Clinical Specialistic and Dental Sciences, Marche Polytechnic University, Ancona, Italy

ARTICLE INFO

Keywords:

Athletes
Electrocardiogram
Pre-participation screening
Sports cardiology
Ventricular arrhythmias
Sudden death

ABSTRACT

Premature ventricular beats (PVBs) are recorded in a sizeable proportion of athletes during pre-participation screening, especially if the evaluation includes both resting and exercise ECG. While in the majority of cases no underlying heart disease is present, in others PVBs may be the sign of a condition at risk of sudden cardiac death, including cardiomyopathies, congenital, coronary artery, heart valves and ion channels diseases. In this expert opinion document of the Italian Society of Sports Cardiology, we propose a multiparametric interpretation approach to PVBs in athletes and a stepwise diagnostic algorithm. The clinical work-up should include the assessment of the probable site of origin based on the ECG pattern of the ectopic QRS and of the arrhythmia behavior (including the number of different PVB morphologies, complexity, response to exercise and reproducibility), as well as first-line tests such as echocardiography. Based on this initial evaluation, most athletes can be reassured of the benign nature of PVBs and cleared for competition under periodical follow-up. However, when the clinical suspicion is high, further investigations with non-invasive (e.g. cardiac magnetic resonance, cardiac computed tomography, genetic testing) and, in very selected cases, invasive (e.g. endocardial voltage mapping and endomyocardial biopsy) tests should be carried out to rule out a high-risk condition. Importantly, such advanced tests should be performed in centers with a consolidated experience not only in the technique, but also in evaluation of athletes.

Abbreviations: ACM, arrhythmogenic cardiomyopathy; CCTA, coronary computed tomography angiography; CMR, cardiac magnetic resonance; CPVT, catecholaminergic polymorphic ventricular tachycardia; EMB, endomyocardial biopsy; ECG, electrocardiogram; EVM, endocardial voltage mapping; IVF, idiopathic ventricular fibrillation; LBBB, left bundle branch block; LV, left ventricular; LVOT, left ventricular outflow tract; NILVS, non-ischemic left ventricular scar; PVB, premature ventricular beat; RBBB, right bundle-branch-block; RV, right ventricle; RVOT, right ventricular outflow tract; SCD, sudden cardiac death; VA, ventricular arrhythmias; 24 h-ECG, 24-h ambulatory ECG monitoring.

* Corresponding author at: Department of Cardiac, Thoracic and Vascular Sciences and Public Health, University of Padua, Via Giustiniani 2, 35128 Padova, Italy.

E-mail address: domenico.corrado@unipd.it (D. Corrado).

<https://doi.org/10.1016/j.ijcard.2023.131220>

Received 24 June 2023; Received in revised form 18 July 2023; Accepted 26 July 2023

Available online 28 July 2023

0167-5273/© 2023 The Author(s). Published by Elsevier B.V. This is an open access article under the CC BY-NC-ND license (<http://creativecommons.org/licenses/by-nc-nd/4.0/>).

1. Introduction

Premature ventricular beats (PVBs) are not infrequent in the athlete and they may result from the activity of a benign automatic focus or may be the sign of an underlying heart disease at risk of sudden cardiac death (SCD) [1,2]. For this reason, the presence of PVBs on resting or exercise electrocardiogram (ECG) in an athlete requires a careful clinical assessment to rule out potentially dangerous conditions. Clinical tests that can be used for differential diagnosis range from non-invasive and largely available tools to invasive and expensive tests. Because PVBs are quite common in the setting of pre-participation screening of athletes including exercise testing (5–10%) [3–8], risk stratification is essential for a cost-effective diagnostic work-up. This document addresses mechanisms and substrates of PVBs in the athlete as well as the characteristics that increase the probability of an underlying disease at-risk of SCD. Moreover, the clinical use of the main clinical tests in the diagnostic work-up of athletes with PVBs is discussed.

2. Mechanisms of premature ventricular beats

Three main mechanisms can cause PVBs: 1) enhanced automaticity (increase of the spontaneous depolarization rate or triggered activity); 2) re-entry; 3) focal re-excitation (phase 2 re-entry) [9].

Enhanced automaticity is the most common mechanism of PVBs. It occurs when a cell or a group of cells can depolarize spontaneously before the normal sinus rhythm. This may occur because of an *increase in the spontaneous depolarization rate* of a group of cells that becomes higher than that of the sinus node: a typical example is the so-called accelerated idioventricular rhythm [9]. Alternatively, a group of cardiomyocytes may have an unstable action potential during the diastolic phase, usually because calcium ions exit from the sarcoplasmic reticulum, which increases the intracellular voltage (late-potential). When the depolarization threshold is reached, a PVB occurs. This phenomenon is called *triggered activity* and is very common: for instance, this is the mechanism of outflow tract PVBs [10], but may also occur in pathological conditions such as arrhythmogenic cardiomyopathy (ACM) because of altered electrophysiological properties of cardiomyocytes that lay in the scar border zone [11].

The mechanism of *re-entry* is shared by many supraventricular and ventricular tachycardia. It occurs when the depolarization wavefront proceeds through two different pathways with common entry and exit points and different electrophysiological properties (in terms of conduction speed and refractoriness). If an impulse reaches the entry point when one of the two pathways is still refractory, it will proceed only through the other (unidirectional block). Upon reaching the exit point, the electrical impulse will continue to depolarize the rest of the heart, but, if the once-refractory pathway is now available for conduction, it will also travel retrogradely, reaching the entry point again and giving rise to a new and premature ventricular depolarization (i.e. a PVB) [9].

Finally, phase-2 re-entry (focal re-excitation) occurs when the refractoriness is inhomogeneous across different heart regions. In this case, at a certain point of the cardiac cycle, a region of the heart is still depolarized while another is already repolarized and ready to be excited again. The electrical impulse transmission from the still-depolarized to the already-repolarized area can give rise to a PVB that typically occurs at the peak of the T-wave (R-on-T phenomenon) and may trigger ventricular fibrillation. Phase 2-reentry PVBs are typically observed during acute myocardial infarction but can also occur in ion channel diseases such as Brugada syndrome or Long QT syndrome.

3. Substrates of premature ventricular beats

3.1. Association between premature ventricular beats and sports

Recording one or more PVBs during the pre-participation screening that includes both resting and exercise ECG is a quite common finding,

occurring in 5–10% of athletes, with an incidence increasing with age [3–8]. The question arises whether exercise training may favor the occurrence of PVBs.

Sports practice, particularly endurance sports, causes the increase of cardiac mass that may be potentially responsible for an increased propensity to ventricular arrhythmias (VA), similar to hypertension. In the early 2000s, Biffi et al. reported that frequent/complex PVBs in elite athletes tend to disappear or decrease after detraining, and for this reason, the authors hypothesized that PVBs might be a manifestation of the “athlete’s heart” [12]. However, the same authors failed to demonstrate the reappearance of PVBs with re-training and any association between the degree of exercise-induced left ventricular (LV) hypertrophy and the burden of PVBs [13,14]. Moreover, Delise et al. evaluated the behavior of PVBs during follow-up in a group of athletes with no underlying disease: they found that PVBs can persist/increase or reduce/disappear regardless of detraining [15]. More recently, Zorzi et al. compared the prevalence and burden of PVBs on 24-h ECG monitoring in healthy athletes and sedentary volunteers. They found that both in young and in veteran athletes, there were no differences correlated to training. Importantly, even in highly-trained endurance athletes, the prevalence of individuals showing frequent or complex VA was low, with no differences according to the training volume [6,7].

Another controversial issue is the influence of sport type and intensity on the right ventricle (RV). According to one theory, some individuals engaged in high-intensity endurance sports activities (such as cycling or running) may develop RV dysfunction and propensity to VA over time, mimicking the genetically-determined ACM, so-called exercise-induced ACM [16]. However, this hypothesis is not supported by data on Olympic athletes who were followed up for a long period (12 years) and did not show any evidence of pathological RV remodeling [17]. Moreover, in a recent study including a group of former Olympic athletes engaged in endurance disciplines, no signs of long-term pathological remodeling were observed 10 years after the cessation of competitions [18].

In summary, the potential association between sports practice, adverse ventricular remodeling, and VA is conflicting, and there is no solid evidence linking the “athlete’s heart” to an increased PVB burden. For this reason, athletes with PVBs require a careful assessment to rule out an underlying cardiac disease at risk for SCD, similarly to the general population.

3.2. Premature ventricular beats in normal hearts

Athletes with structurally normal hearts may present with frequent PVBs defined as “idiopathic” which do not generally confer an increased risk of major adverse cardiac events [1,4]. Typically, these PVBs are the results of enhanced automaticity [9]. Although several structures of the heart may give rise to idiopathic PVBs, two common sites of origin in healthy athletes are the right and left ventricular outflow tract (infundibular PVBs) and the specialized cardiac conduction system (fascicular PVBs) [8,19]. The ventricular outflow tracts are anatomically predisposed to arrhythmogenesis due to the complex three-dimensional arrangement of these cardiac structures, in which valve tissue, myocardium, and smooth muscle tissue lie in close proximity. Furthermore, myocardial fibers are interspersed with fibrous tissue in outflow tracts and have a heterogeneous three-dimensional arrangement. This anatomic complexity, associated with the presence of an endocardial Purkinje network (which is capable of automaticity), and autonomic innervation, facilitates arrhythmogenicity and we speculate that the increased wall stress that athletes face during exercise may also contribute to this pathophysiological process [10,20,21]. Purkinje cells are capable of spontaneous depolarization, similar to sinoatrial nodal cells; furthermore, due to their long action potential duration, they are also predisposed to early afterdepolarizations, which are facilitated by sympathetic stimulation (as occurs during competition or training-associated catecholaminergic surges) [20].

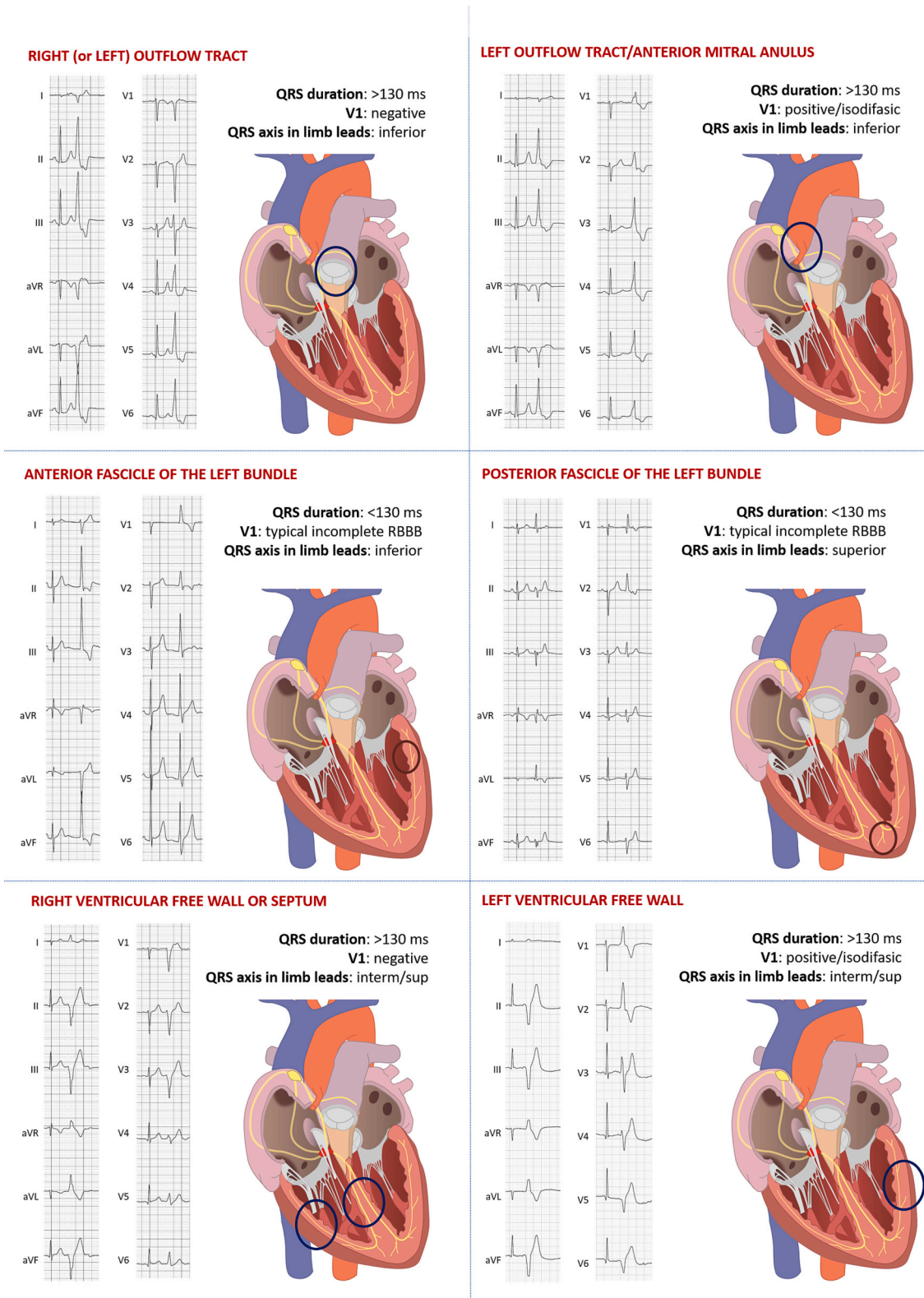


Fig. 1. Representative examples of the six main premature ventricular beat types that a sports cardiologist or a sports medicine physician should be able to recognize. They include i) right ventricular outflow tract (RVOT) PVBs, characterized by a negative QRS complex in V1, precordial transition beyond V3 and inferior QRS axis in the limb leads; 2) left ventricular outflow tract (LVOT)/anterior mitral annulus PVBs, characterized by a negative QRS complex only in V1-V2, only in V1 or a positive QRS complex in all six precordial leads and inferior axis in the limb leads; 3) fascicular PVBs, that have an incomplete RBBB/superior axis if the originates from the inferior fascicle of the left bundle (C), an incomplete RBBB/inferior axis if they originate from the anterior fascicle (D). These are PVB types that carry a low probability of an underlying disease. PVBs with an intermediate/superior axis, either with a LBBB pattern or a RBBB pattern in V1 originate from other ventricular structures and may be a sign of heart disease.

Although idiopathic PVBs usually have a good prognosis, some complications may occur: very frequent PVBs (>10–20% burden) may lead to LV dilation/systolic dysfunction and heart failure, the so-called PVB-induced cardiomyopathy [22]: for this reason, athletes with benign but very frequent idiopathic PVBs should remain under echocardiographic surveillance to rule out progressive LV dysfunction over time.

3.3. Premature ventricular beats in structural heart abnormalities

All structural cardiac diseases can be associated to PVBs, including inherited, congenital, heart valves, ischemic and hypertensive cardiac diseases. For this reason, careful evaluation of PVBs is important as they can be the sign of a disease at risk of SCD, such as cardiomyopathies or arrhythmic mitral valve prolapse [1,2]. PVBs are recorded in a sizeable proportion of athletes: while in the majority no underlying heart disease is present, in some cases PVBs may be the only sign of a serious disease at risk of SCD [3–8]. Many of these conditions can be suspected based on the high-risk PVBs characteristics (see below) and confirmed by echocardiography, while others require advanced diagnostic techniques.

Recently, non-ischemic left ventricular scar (NILVS) has been recognized as a leading cause of SCD in relation to exercise [23–25]. Clinically, the term NILVS scar refers to the cardiac magnetic resonance (CMR) finding of late gadolinium enhancement in the subepicardial/midmyocardial layers of the LV. As gadolinium concentrates in areas of increased interstitial tissue, this sign indicates replacement-type myocardial fibrosis. Echocardiography is often unremarkable, particularly in a non-extended LV scar, because subepicardial myocytes contribute less than subendocardial fibers to myocardial thickening. The ECG is also often negative, although low QRS voltages in the peripheral limb leads or inverted T-waves can be present, even if in a minority of cases [23]. Usually, the condition may be suspected based on PVBs with a right bundle-branch-block (RBBB), wide QRS, and superior axis configuration, particularly when elicited by exercise and reproduced at repeated exercise testing [3,26–28].

3.4. Premature ventricular beats in catecholaminergic polymorphic ventricular tachycardia and idiopathic ventricular fibrillation

Catecholaminergic polymorphic ventricular tachycardia (CPVT) is characterized by a normal resting ECG. Many people with CPVT have a family history of SCD at a young age and/or stress-induced syncope or presyncope. The clinical suspicion of CPVT should arise whenever an athlete shows the appearance or worsening of VA during an exercise stress testing. In CPVT, there is usually a specific level of heart rate (typically >120 bpm) at which PVBs begin to occur, and they tend to increase in number and complexity with increasing heart rate. PVBs are usually polymorphic, and the typical VA of CPVT is the so-called “bidirectional ventricular tachycardia” (180° rotation of the QRS axis from beat to beat) or a transition over the exercise testing from multifocal isolated PVBs to couplets or polymorphic non-sustained ventricular tachycardia [8,9]. Recording a training session by 24-h ECG monitoring can be particularly useful for some athletes who cannot achieve their maximal heart rate during exercise testing [29]. When the disease is suspected, genetic testing must be performed. The disease is most often caused by mutations in genes responsible for intracellular calcium handling, such as the ryanodine receptor 2 gene and, less frequently, the calsequestrin and triadin genes [30].

Idiopathic ventricular fibrillation (IVF) is diagnosed when no structural abnormalities or typical ECG features of ion channel diseases are observed. In some series, IVF accounts for nearly half of cases of SCD in the young [31]. It is well established that in a subset of patients, IVF is triggered by short-coupled PVBs falling on the T wave (R-on-T phenomenon), mostly originating from the Purkinje system (up to 93% of the cases) and less frequently from the ventricular myocardium including the right ventricular outflow tract (RVOT) or the papillary

muscles [32,33]. Genetic testing also plays a role in the IVF setting, with dipeptidyl peptidase-like protein-6 (DPP6) gene that encodes for a component of the transient outward current mostly involved, although in the majority of cases no mutations are identified [34]. Up to 9% of patients originally diagnosed with IVF may carry clinically-relevant genetic variants on genes associated with channelopathies and cardiomyopathies, the majority of which are associated with CPVT [35].

4. Risk stratification of premature ventricular beats in the athlete

4.1. Identification of the site of origin based on the 12-lead ECG pattern

Numerous algorithms help to identify the site of origin of PVBs based on the ectopic QRS features on surface ECG [36,37]. However, it has to be remembered that the variable position of the heart in relation to the ECG electrodes and the different ways the electrical impulse propagates through the heart (particularly in the presence of diseases) make these algorithms inherently imprecise.

For the purpose of this manuscript, it is important to differentiate PVBs that carry a low probability of an underlying disease from those that may be associated with structural substrates, although benign (idiopathic) PVBs may arise in any part of the heart (Fig. 1).

The RVOT/pulmonary valve, the left ventricular outflow tract (LVOT)/aortic valve and the anterior mitral valve annulus are common sites of origin of idiopathic PVBs. Because these structures lie in the superior part of the base of the ventricles, PVBs are characterized by an inferior QRS axis in the limb leads. In the precordial leads, the ectopic QRS is negative in V1-V3, i.e. it shows a left bundle branch block (LBBB) pattern when the PVB arises from the RVOT, while PVBs arising from LVOT/anterior mitral valve annulus show a negative QRS complex only in V1-V2, only in V1, or all precordial leads show a positive QRS complex (RBBB pattern) [38]. These PVBs may be very numerous per hour, they usually suppress with exercise and are mainly isolated. The probability of an underlying disease in the absence of other abnormal features on first-line tests (see below for details) is very low [10,20,21].

Fascicular PVBs are common in children and often disappear with pubertal development [39]. They typically occur in normal hearts. The QRS pattern is identical to that of an atrial ectopic beat conducted with an incomplete RBBB/anterior fascicular block (origin from the posterior fascicle of the left bundle) or incomplete RBBB/posterior fascicular block (origin from the anterior fascicle of the left bundle).

PVBs with other morphologies arise from different structures of the RV free wall (LBBB pattern in V1 usually with a QS configuration), the interventricular septum (usually LBBB pattern in V1 with a rS configuration) or the LV free wall (RBBB pattern in V1) [36,37]. These ectopic QRS patterns are more likely to be associated with a cardiac disease than infundibular or fascicular PVBs. Among them, the most concerning pattern is the one suggesting the origin from the lateral LV wall (positive QRS pattern in V1 and aVR, and negative in aVF) because this is the typical site of NILVS [23,27,28].

4.2. Multiparametric approach to risk stratification of premature ventricular beats

Parameters that can be useful for risk stratification of athletes with PVBs are shown in the Table 1. Regardless of PVBs morphology, other features that increase or decrease the probability of an underlying condition include whether PVBs are monomorphic or not, their behavior during exercise, presence of complex patterns (couplets with short RR interval, non-sustained ventricular tachycardia, “R on T” phenomenon) and reproducibility on repeated exercise testing or 24-h ambulatory ECG monitoring (24 h-ECG) including a training session [40]. None of these features alone shows high diagnostic accuracy. Usually, athletes with idiopathic RVOT PVBs show a suppression of the arrhythmias with increasing heart rate during exercise testing, but some do not. On the

Table 1

Clinical and premature ventricular beats (PVBs) characteristics that increase or reduce the probability of an underlying heart disease.

	High-risk ("uncommon") features	Low-risk ("common") features
Clinical characteristics		
Family history of cardiomyopathies, ion channel diseases or premature sudden death	+	-
Syncope or pre-syncope of possible arrhythmic origin	+	-
Physical examination	Abnormal (e.g. cardiac murmur, syndromic features)	Normal
ECG abnormalities*	+	-
PVBs characteristics		
QRS pattern	Other patterns (see Fig. 1)	Fascicular and infundibular (see Fig. 1)
Number of morphologies	Multiple (polymorphic)	Single (monomorphic)
Behavior during exercise	Increase or persistence	Reduction or suppression
Complex patterns (couplets with short RR interval, "R on T")	+	-
Reproducibility on repeated exercise testing or 24 h-ECG	+	-

* Interpretation of the ECG in athletes should be based on the 2017 International Criteria [42], with some amendments: i) even a single PVB (and not ≥ 2) on the resting ECG and ii) the presence of low QRS voltages (peak to peak amplitude < 0.5 mV in all limb leads) should be considered as "red flags".

other hand, patients with ACM may show exercise-suppressed PVBs [41]. However, when high-risk features are present, the chance of an underlying condition increases, and the prescription of second-line tests becomes justified, particularly when other first-line tests (such as history or resting ECG) are still abnormal.

5. Diagnostic work-up of athletes with premature ventricular beats

5.1. First-line investigations

All athletes with newly-diagnosed PVBs, even if the burden is low, should undergo first-line tests, including detailed family and personal history, physical examination, blood tests including blood cell count, electrolytes, inflammatory markers and thyroid hormones, resting ECG, exercise testing, 24-h ECG monitoring and echocardiography. *Family history* should be focused on cardiomyopathies, ion channel diseases or premature SCD (< 40 -year-old in males and < 50 in females). Particular attention should be paid to athletes reporting a family history of "myocardial infarction" or "heart attack", as those terms are usually used as synonyms for SCD. *Personal history* should address symptoms suggesting potentially malignant VA, such as pre-syncope or syncope of presumed cardiac origin as well as the use of stimulants that may favor PVBs. Interpretation of the ECG in athletes should be based on the 2017 International Criteria [42], with some amendments: i) even a single PVB (and not ≥ 2) on the resting ECG and ii) the presence of low QRS voltages (peak to peak amplitude < 0.5 mV in all limb leads) should be considered as "red flags". There is no evidence to prefer a specific *exercise testing* protocol, but the test should be maximal, i.e. targeted to the athlete's exhaustion rather than a specific maximum heart rate. The 24H-ECG should always include a high-intensity exercise session, preferentially of the same sport the athlete usually practices. A 12-lead recording system should be preferred because it allows to evaluate PVBs morphologies. The report should include a detailed description of PVB

number, circadian distribution, relation to exercise, complexity and number of morphologies. Finally, a thorough echocardiographic examination should be performed by operators with adequate experience in evaluation of athlete's heart and cardiomyopathies and must include: i) evaluation of global RV function, regional RV wall motion with dedicated off-axis views, particularly for athletes with PVBs suggesting a RV origin; ii) evaluation of global LV function, regional wall motion abnormalities and thickness of the different segments; iii) evaluation of the coronary artery origin. Although strain analysis may potentially increase the sensitivity of echocardiography for detecting regional LV scarring, there is currently no evidence to support its systematic use in this setting.

5.2. Cardiac magnetic resonance

Among second-level tests for athletes with PVBs, CMR plays a crucial role because it allows: i) precise evaluation of ventricular size, thickness, regional and global function; ii) evaluation of potential heart valves disease and shunt; iii) myocardial tissue characterization. Since echocardiography cannot provide tissue characterization and may miss important arrhythmic substrates such as myocarditis or NILVS, athletes with high-risk PVBs (Table 1) should be referred for CMR even when echocardiography is normal [40]. CMR is also useful for confirming echocardiographic abnormalities. A proposal of CMR protocol for the evaluation of athletes with PVBs is shown in Fig. 2.

Despite these undoubted advantages, CMR has two main limitations. The first is its limited availability and costs, which makes the referral of many athletes with PVBs unfeasible. The second is that performing and interpreting CMR requires significant expertise, particularly when the patient is an athlete showing features of cardiac remodeling secondary to exercise that may be misinterpreted as pathological. For this reason, athletes with high-risk PVB features should ideally be referred to experienced CMR centers. Moreover, when abnormalities evidenced by CMR are mild/borderline, the sports cardiologist should verify the concordance between PVB characteristics and the CMR finding (a typical mismatch is the presence of a small inferolateral LV scar in an athlete with monomorphic isolated PVBs originating from the RVOT).

5.3. Coronary computed tomography

In the last decade, an impressive technical development allowed coronary computed tomography angiography (CCTA) to become a reliable and accurate non-invasive, low-risk and lower-cost alternative to invasive coronary angiography to assess coronary arteries also in subjects with VA [43]. Compared to functional tests, the major strengths of CCTA as an initial diagnostic strategy are both the ability to effectively rule out obstructive CAD and to determine the atherosclerosis burden, which plays a pivotal role in improving risk stratification and guiding risk-based patient management [44]. The two indications of CCTA in athletes with PVBs are suspected CAD in master athletes and to rule out congenital coronary anomalies (CCA) in younger subjects [45,46]. CCTA should be performed in master athletes (> 40 -year-old in males and > 50 -year-old in females) with high-risk PVBs (Table 1) and a high probability of an underlying CAD based on risk factors, suspicious symptoms and/or ST-segment depression on exercise testing. In younger athletes with PVBs, initial screening for CCA should be performed with echocardiography, and CCTA should be used to confirm the suspicion; however, if the clinical probability is high based on symptoms, ST-segment depression or complex arrhythmic burden (exercise-induced nonsustained or sustained ventricular tachycardia), CCTA in addition to echocardiography may be justified. It is mandatory to look for and characterize the presence of a "clinically malignant" forms of CCA, such as the origin of a coronary artery from the opposite sinus of Valsalva with interarterial/intramural path and a long (> 1 cm) and deep (≥ 3 mm) intramyocardial bridge of the left anterior descending artery [47,48]. Finally, CCTA is emerging as a tool for the detection of an

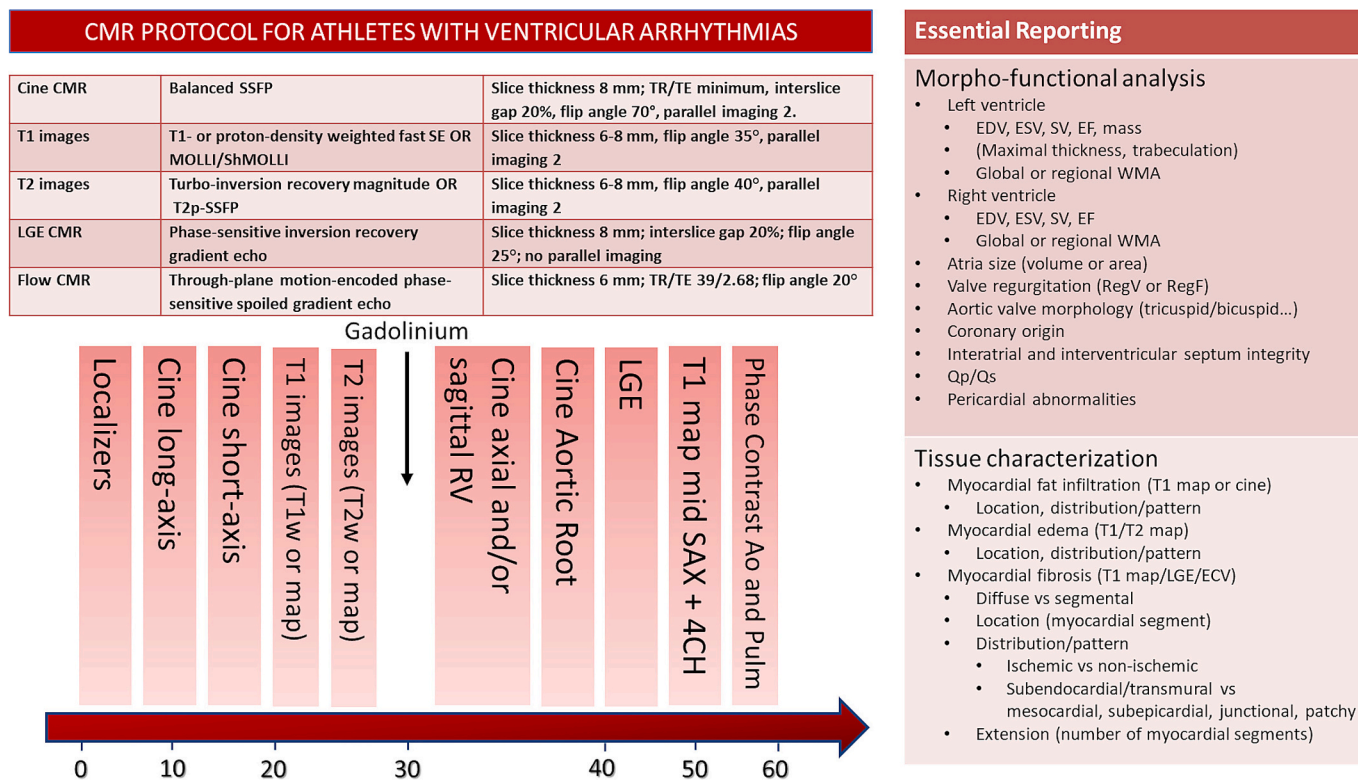


Fig. 2. Proposal of protocol of cardiac magnetic resonance acquisition and reporting in athletes referred for ventricular arrhythmias. The sequence protocol should comprise: (1) planning stage including localizer images and general anatomy, (2) cine imaging in long-axis (2Ch, 4Ch, 3Ch) and SAX, (3) T1 and (4) T2 images, cine imaging in axial and/or sagittal view for evaluation for RV kinetics, (6) cine imaging in aortic root, (7) LGE imaging and (8) phase-contrast images. Reference values for evaluation of chamber volumes and T1/ECV in athletes should be used. Abbreviations: CMR = cardiac magnetic resonance; LGE = late gadolinium enhancement; SSFP = steady-state free precession; SE = spin-echo; MOLLI = modified Look-Locker inversion recovery; shMOLLI = shortened modified Look-Locker inversion recovery; T1w = T1-weighted; T2w = T2weighted; SAX = short-axis; 4CH = 4-chamber; Ao = Aorta; Pulm = Pulmonary Artery; RV = right ventricle; EDV = end-diastolic volume; ESV = end-systolic volume; SV = stroke volume; EF = ejection fraction; WMA = wall motion abnormalities; RegV = regurgitant volume; RegF = regurgitant fraction; ECV = extracellular volume.

arrhythmic substrate (myocardial scar or fat infiltration) in subjects with contraindication to CMR [49]. The proposed protocol for evaluating athletes with PVBs by CCTA is shown in Fig. 3.

5.4. Genetic testing

The development of new techniques able to perform a low-cost rapid screening of multiple genes has increased the use of genetic testing. The yield of genetic testing varies according to the condition, ranging from 30% in Brugada syndrome to 80% in Long QT syndrome [50]. Unfortunately, at the current state of the art, genetic testing does not always provide a definitive answer, and a positive genetic test result does not always indicate a disease because some genetic variants are benign or have unclear significance. All these factors, including the impact of genetic testing on sports recommendations, should be balanced before performing a genetic screening. A position statement from the Italian Society of Sports Cardiology on how and when to perform genetic testing on athletes has recently been published [30].

In athletes with VA, genetic testing should be performed only following comprehensive clinical phenotyping when the probability of an inherited cardiac disorder is considered reasonably high. In particular, genetic testing should be performed in athletes with VA who fulfill the criteria for a clinical diagnosis of a cardiomyopathy or ion channel disease (particularly long QT syndrome or CPVT) if it can provide prognostic information or be useful for family screening. It is also mandatory when PVBs features suggest possible CPVT, as the diagnostic yield is high (>70%) [29]. Genetic testing may also be useful to confirm the diagnosis in athletes with “grey zone” abnormalities (e.g. borderline

LV hypertrophy, wall motion abnormalities of the RV, borderline QT interval prolongation...) and when the PVBs characteristics suggest possible CPVT. On the other hand, molecular genetic testing for athletes with VA and no other clinical disease features is not recommended because of the lack of specificity of the findings: close clinical surveillance is recommended in this case. Any genetic testing result should be disclosed to the athlete along with the necessary post-test genetic counseling and support in a specialized center.

5.5. Endocardial voltage mapping

Endocardial voltage mapping (EVM) is an invasive technique that allows the identification of diseased myocardial regions, which can be then directly sampled by endomyocardial biopsy (EMB), with a low risk of adverse events in experienced hands [51]. During recent years, EVM-guided EMB has shown high diagnostic yield for the definite diagnosis of myocardial diseases with focal/regional involvement (such as myocarditis or arrhythmogenic cardiomyopathies), allowing diagnostic reclassification and/or the identification of concealed cardiomyopathies, thus providing relevant information for prognostic assessment and determination of sports eligibility [51–54].

An expert opinion paper by the Italian Society of Sports Cardiology on the use of EVM in the diagnostic work-up of athletes with PVBs to rule out a concealed structural myocardial substrate has recently been published [55]. To summarize, the main clinical indications for EVM and EVM-guided EMB in athletes presenting with PVBs can be resumed as follows:

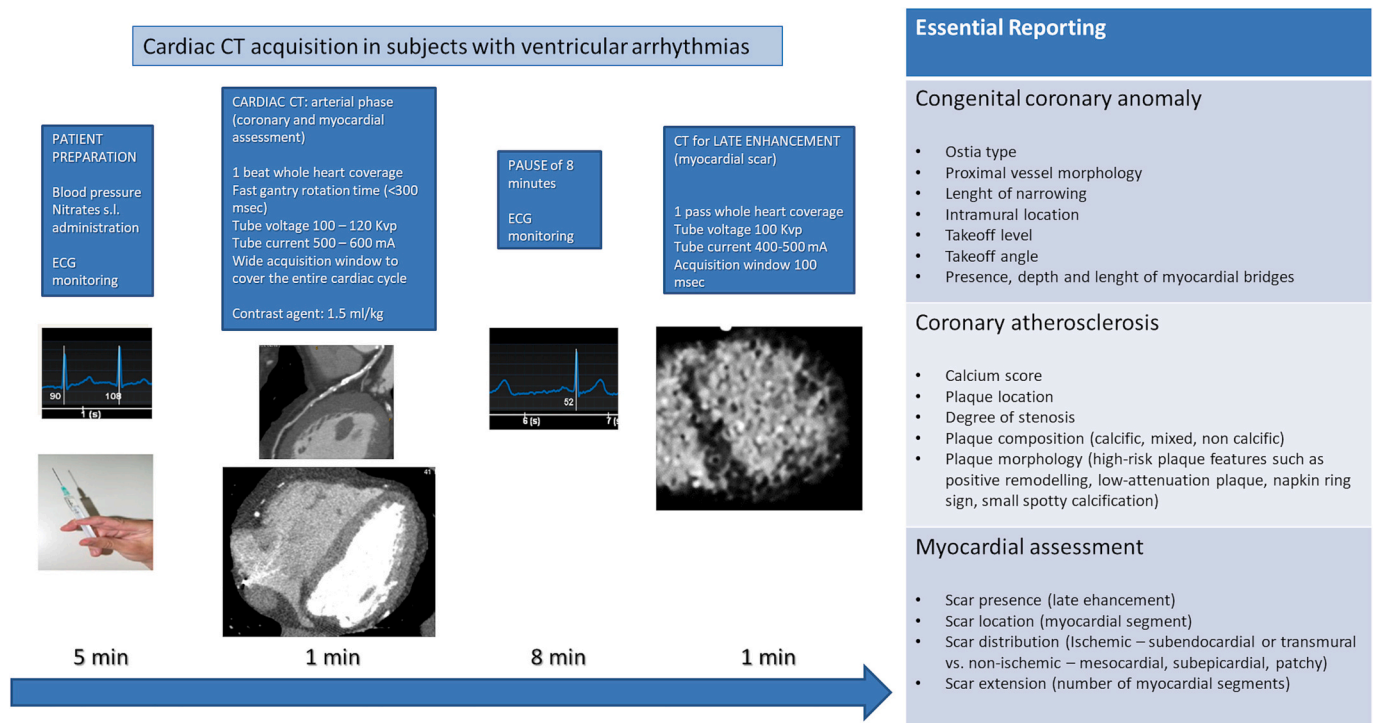


Fig. 3. Protocol of cardiac computed tomography acquisition and reporting in athletes referred for ventricular arrhythmias. Note that modern technologies may allow the evaluation of coronary arteries and myocardial assessment for late enhancement, although a second scan is required.

- high-risk PVBs and morpho-functional or structural abnormalities at non-invasive cardiac imaging suggesting structural cardiomyopathy (particularly ACM or NILVS) (Fig. 4). In the subgroup of athletes with VA and without a definite diagnosis after a comprehensive non-invasive diagnostic workup, EVM-guided EMB allowed diagnostic reclassification in 87% of cases [56].
- frequent/complex PVBs and clinically-suspected myocarditis. In this case, EMB may allow to reach a definite diagnosis of myocarditis and differentiate viral from autoimmune myocarditis, which is a prerequisite for etiology-tailored treatments. In a recent observational study including patients with virus-negative myocarditis with VA at presentation, immunosuppressive treatment was associated with reduced long-term risk of major VAs [57].
- indications to catheter ablation for RV PVBs. In this circumstance, it may be reasonable to perform an EVM of the whole RV (and possibly also perform LV EVM, in case CMR shows NILVS), and proceed to EVM-guided EMB if low-voltage regions are identified to inform the differential diagnosis of ACM [52,58].

6. Treatment, sports eligibility and follow-up

The fundamental goals of every medical treatment are twofold: to improve survival and/or to increase the quality of life. Antiarrhythmic drugs (with the only exception of beta blockers in some conditions) and catheter ablation have not been demonstrated to improve survival, and therefore, treatments should be mainly considered in symptomatic patients and in asymptomatic individuals with high PVBs burden and signs of PVBs-induced ventricular dysfunction (tachycardiomyopathy). In the presence of an underlying structural or genetic heart disease, therapy should focus on the main clinical condition, potentially including ICD implantation [59].

Drug therapy for young athletes may be challenging because antiarrhythmic drugs may be either ineffective or non-tolerated (e.g. because of low heart rate and blood pressure) [60]. For example, beta-blockers may reduce performance particularly in endurance sports, due to the detrimental effect of lowering peak heart rate during effort, in

addition, their use must be declared in the athlete's therapeutic plan because they are banned as doping in certain skill sports, as shooting or archery [61]. It should also be considered that many anti-arrhythmic drugs (particularly class IC) are contraindicated in the presence of a significant underlying structural heart disease and that an antiarrhythmic treatment targeted at arrhythmia suppression may be correlated to several side effects, thus sometimes impairing prognosis. When there is a treatment indication, ablation is generally preferable to antiarrhythmic drugs in terms of efficacy, particularly in monomorphic PVBs, and is associated with a low rate of complications in experienced hands. However, the risk is not zero and the benefits of a procedure aimed only at relieving symptoms should be balanced against possible complications [59]. It must be taken into consideration that in many junior athletes PVBs will subside with pubertal development and for this reason a wait-and-see approach is reasonable [19].

Eligibility to competitive sports activity in athletes with PVBs is discussed in details in the 2023 Italian guidelines for cardiovascular eligibility to competitive sports [62]. In general, competitive sport is not contraindicated if an underlying disease has been ruled out after careful clinical assessment, although in case of complex VA (R-on-T PVBs, couplets with short RR interval, numerous or fast non-sustained ventricular tachycardia, exercise-induced PVBs...) with silent instrumental findings a case-by-case decision is required. Athletes with PVBs should remain under clinical surveillance, particularly if they are young, because a disease may become overt later or if the burden is high because of the (remote) risk of tachycardiomyopathy [22].

7. Conclusions

A proposed protocol for the evaluation of athletes with PVBs is shown in Fig. 5. In the Italian setting, where preparticipation screening is mandatory and includes both resting and exercise ECG, PVBs are recorded in a sizeable proportion of athletes. While in the majority no underlying heart disease is present, in some cases PVBs may be the only sign of a serious disease at risk of SCD. The diagnostic work-up aimed to exclude such conditions should be careful and always include first line-

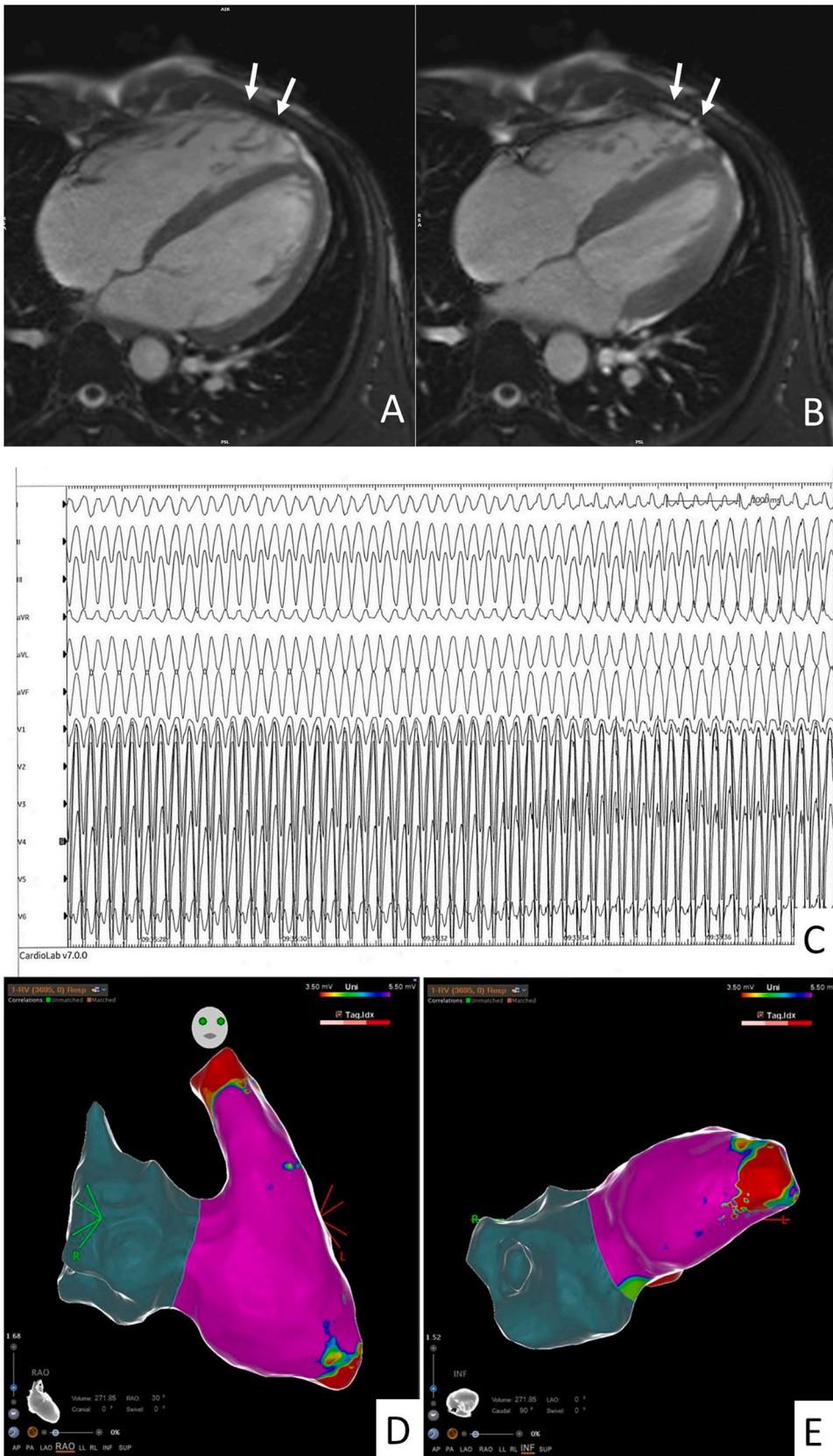


Fig. 4. Representative case illustrating the potential use of endocardial voltage mapping in an athlete with premature ventricular beats. An endurance athlete was referred for consultation for palpitations followed by pre-syncope during a training session, which lasted for several minutes. A cardiac magnetic resonance raised the suspicion of right ventricular cardiomyopathy based on the presence of apical wall motion diastolic bulgings (A) and systolic wall motion abnormalities (B). The patient was referred for an electrophysiological study with programmed ventricular stimulation and electroanatomical voltage mapping. The study was positive for sustained ventricular tachycardia induction, with a morphology suggesting the origin from the right ventricular apex (C). Endocardial voltage mapping confirmed the presence of low voltages area (D, E), supporting the diagnosis of segmental arrhythmogenic cardiomyopathy (images courtesy of Federico Migliore, Padua).

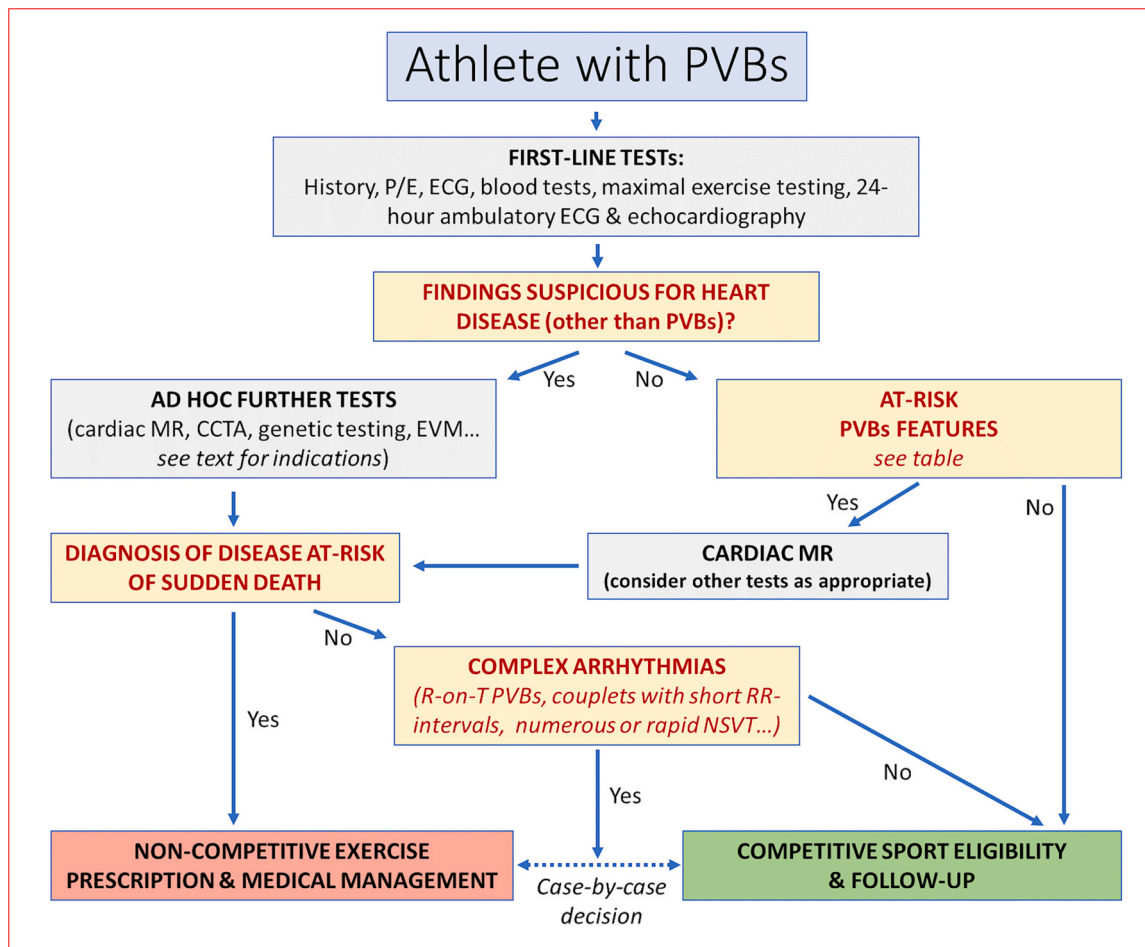


Fig. 5. Proposed diagnostic flow-chart for evaluating an athlete with premature ventricular beats at resting and/or exercise ECG.

CCTA = coronary computed tomography angiography; ECG = electrocardiogram; EVM = endocardial voltage mapping; MR = magnetic resonance; P/E = physical examination; PVBs = premature ventricular beats.

tests (history, physical examination, resting ECG, blood tests, 24H-ECG (possibly 12-lead), maximal exercise testing and echocardiography). Further tests such as CMR, CCTA, genetic testing and invasive electrophysiological study with endocardial voltage mapping are expensive and poorly available, and their interpretation requires significant expertise. For this reason, they should be reserved for the small subset of athletes with abnormal first-line tests or high-risk PVBs features and should be performed in experienced centers.

Financial disclosures

This article was supported by the Fondazione Giorgio Castelli Onlus, Rome.

Declaration of Competing Interest

None.

References

- [1] D. Corrado, J.A. Drezner, F. D'Ascenzi, A. Zorzi, How to evaluate premature ventricular beats in the athlete: critical review and proposal of a diagnostic algorithm, *Br. J. Sports Med.* 54 (19) (2020) 1142–1148.
- [2] F. D'Ascenzi, A. Zorzi, F. Alvino, M. Bonifazi, D. Corrado, S. Mondillo, The prevalence and clinical significance of premature ventricular beats in the athlete, *Scand. J. Med. Sci. Sports* 27 (2) (2017) 140–151.
- [3] A. Zorzi, T. Vessella, M. De Lazzari, et al., Screening young athletes for diseases at risk of sudden cardiac death: role of stress testing for ventricular arrhythmias, *Eur. J. Prev. Cardiol.* 27 (2020) 311–320.
- [4] L. Verdile, B.J. Maron, A. Pelliccia, A. Spataro, M. Santini, A. Biffi, Clinical significance of exercise-induced ventricular tachyarrhythmias in trained athletes without cardiovascular abnormalities, *Heart Rhythm* 12 (2015) 78–85.
- [5] G. Modica, F. Sollazzo, M. Bianco, et al., Bicuspid aortic valve and premature ventricular beats in athletes, *Int. J. Environ. Res. Public Health* 19 (19) (2022) 12188.
- [6] A. Zorzi, G. Mastella, A. Cipriani, et al., Burden of ventricular arrhythmias at 12-lead 24-hour ambulatory ECG monitoring in middle-aged endurance athletes versus sedentary controls, *Eur. J. Prev. Cardiol.* 25 (18) (2018) 2003–2011.
- [7] A. Zorzi, M. De Lazzari, G. Mastella, et al., Ventricular arrhythmias in young competitive athletes: prevalence, determinants, and underlying substrate, *J. Am. Heart Assoc.* 7 (12) (2018), e009171.
- [8] A. Pelliccia, L. De Martino, C. Borrazzo, et al., Clinical correlates and outcome of the patterns of premature ventricular beats in Olympic athletes: a long-term follow-up study, *Eur. J. Prev. Cardiol.* 28 (10) (2021) 1038–1047.
- [9] P. Delise, *Aritmie - Fisiopatologia e diagnosi: dall'ecg al mappaggio tridimensionale*, CESI, Rome, 2008.
- [10] B.B. Lerman, Mechanism, diagnosis, and treatment of outflow tract tachycardia, *Nat. Rev. Cardiol.* 12 (2015) 597–608.
- [11] B. Philips, S. Madhavan, C. James, et al., High prevalence of catecholamine-facilitated focal ventricular tachycardia in patients with arrhythmogenic right ventricular dysplasia/cardiomyopathy, *Circ. Arrhythm. Electrophysiol.* 6 (2013) 160–166.
- [12] A. Biffi, B.J. Maron, L. Verdile, et al., Impact of physical deconditioning on ventricular tachyarrhythmias in trained athletes, *J. Am. Coll. Cardiol.* 44 (2004) 1053–1058.
- [13] A. Biffi, B.J. Maron, B. Di Giacinto, et al., Relation between training-induced left ventricular hypertrophy and risk for ventricular tachyarrhythmias in elite athletes, *Am. J. Cardiol.* 101 (2008) 1792–1795.
- [14] A. Biffi, B.J. Maron, F. Culasso, et al., Patterns of ventricular tachyarrhythmias associated with training, deconditioning and retraining in elite athletes without cardiovascular abnormalities, *Am. J. Cardiol.* 107 (2011) 697–703.
- [15] P. Delise, E. Lanari, N. Sitta, M. Centa, G. Allocca, A. Biffi, Influence of training on the number and complexity of frequent VPBs in healthy athletes, *J. Cardiovasc. Med.* 12 (2011) 157–161.

- [16] A. La Gerche, G. Claessen, S. Dymarkowski, et al., Exercise-induced right ventricular dysfunction is associated with ventricular arrhythmias in endurance athletes, *Eur. Heart J.* 36 (2015) 1998–2010.
- [17] V.L. Aengevaeren, S. Caselli, C. Pisicchio, et al., Right heart remodeling in Olympic athletes during 8 years of intensive exercise training, *J. Am. Coll. Cardiol.* 72 (2018) 815–817.
- [18] F. D'Ascenzi, C. Pisicchio, S. Caselli, F.M. Di Paolo, A. Spataro, A. Pelliccia, RV remodeling in Olympic athletes, *JACC Cardiovasc. Imaging* 10 (2017) 385–393.
- [19] A. Di Florio, C. Fusi, F. Anselmi, et al., Clinical management of young competitive athletes with premature ventricular beats: a prospective cohort study, *Int. J. Cardiol.* 330 (2021) 59–64.
- [20] R.K. Sung, P.A. Boyden, M. Scheinman, Cellular physiology and clinical manifestations of fascicular arrhythmias in normal hearts, *JACC Clin. Electrophysiol.* 3 (2017) 1343–1355.
- [21] K. Aras, A. Gams, N.R. Faye, et al., Electrophysiology and arrhythmogenesis in the human right ventricular outflow tract, *Circ. Arrhythm. Electrophysiol.* 15 (2022), e010630.
- [22] G.M. Marcus, Evaluation and Management of Premature Ventricular Complexes, *Circulation* 141 (2020) 1404–1418.
- [23] A. Zorzi, M.P. Marra, I. Rigato, et al., Nonischemic left ventricular scar as a substrate of life-threatening ventricular arrhythmias and sudden cardiac death in competitive athletes, *Circ. Arrhythm. Electrophysiol.* 9 (7) (2016), e004229.
- [24] C.R.T. di Gioia, C. Giordano, B. Cerbelli, et al., Nonischemic left ventricular scar and cardiac sudden death in the young, *Hum. Pathol.* 58 (2016) 78–89.
- [25] F. Schnell, G. Claessen, A. La Gerche, et al., Subepicardial delayed gadolinium enhancement in asymptomatic athletes: let sleeping dogs lie? *Br. J. Sports Med.* 50 (2016) 111–117.
- [26] A. Cipriani, A. Zorzi, P. Sarto, et al., Predictive value of exercise testing in athletes with ventricular ectopy evaluated by cardiac magnetic resonance, *Heart Rhythm.* 16 (2019) 239–248.
- [27] C. Crescenzi, A. Zorzi, T. Vessella, et al., Predictors of left ventricular scar using cardiac magnetic resonance in athletes with apparently idiopathic ventricular arrhythmias, *J. Am. Heart Assoc.* 10 (2021), e018206.
- [28] G. Brunetti, F. Graziano, L. Cavigli, et al., Reproducibility of ventricular arrhythmias at exercise testing for prediction of non-ischaemic left ventricular scar in athletes, *Eur. J. Prev. Cardiol.* 30 (2023) 107–116.
- [29] C.W. Kim, W.S. Aronow, T. Dutta, D. Frenkel, W.H. Frishman, Catecholaminergic polymorphic ventricular tachycardia, *Cardiol. Rev.* 28 (2020) 325–331.
- [30] S. Castelletti, A. Zorzi, E. Ballardini, et al., Molecular genetic testing in athletes: why and when a position statement from the Italian Society of Sports Cardiology, *Int. J. Cardiol.* 364 (2022) 169–177.
- [31] G. Finocchiaro, M. Papadakis, J.L. Robertus, et al., Etiology of sudden death in sports insights from a United Kingdom regional registry, *J. Am. Coll. Cardiol.* 67 (2023) 2108–2115.
- [32] B. Belhassen, O. Tovia-Brodie, Short-coupled idiopathic ventricular fibrillation: a literature review with extended follow-up, *JACC Clin. Electrophysiol.* 8 (2022) 918–936.
- [33] M. Haïssaguerre, J. Duchateau, R. Dubois, et al., Idiopathic ventricular fibrillation: role of Purkinje system and microstructural myocardial abnormalities, *JACC Clin. Electrophysiol.* 6 (2020) 591–608.
- [34] J.N. Ten Sande, P.G. Postema, S.M. Boekholdt, et al., Detailed characterization of familial idiopathic ventricular fibrillation linked to the DPP6 locus, *Heart Rhythm.* 13 (2016) 905–912.
- [35] J.T. Leinonen, L. Crotti, A. Djupsjöbacka, et al., The genetics underlying idiopathic ventricular fibrillation: a special role for catecholaminergic polymorphic ventricular tachycardia? *Int. J. Cardiol.* 250 (2018) 139–145.
- [36] T. Yamada, Twelve-lead electrocardiographic localization of idiopathic premature ventricular contraction origins, *J. Cardiovasc. Electrophysiol.* 30 (2019) 2603–2617.
- [37] A. Enriquez, A. Baranchuk, D. Briceno, L. Saenz, F. Garcia, How to use the 12-lead ECG to predict the site of origin of idiopathic ventricular arrhythmias, *Heart Rhythm.* 16 (2019) 1538–1544.
- [38] R.D. Anderson, S. Kumar, R. Parameswaran, et al., Differentiating right- and left-sided outflow tract ventricular arrhythmias: classical ECG signatures and prediction algorithms, *Circ. Arrhythm. Electrophysiol.* 12 (2019), e007392.
- [39] G.C.M. Beaufort-Krol, S.S.P. Dijkstra, M.T.E. Bink-Boelkens, Natural history of ventricular premature contractions in children with a structurally normal heart: does origin matter? *Europace* 10 (2008) 998–1003.
- [40] G. Brunetti, A. Cipriani, M. Perazzolo Marra, et al., Role of cardiac magnetic resonance imaging in the evaluation of athletes with premature ventricular beats, *J. Clin. Med.* 11 (2022) 426.
- [41] J. Novak, A. Zorzi, S. Castelletti, et al., Electrocardiographic differentiation of idiopathic right ventricular outflow tract ectopy from early arrhythmogenic right ventricular cardiomyopathy, *Europace* 19 (2017) 622–628.
- [42] S. Sharma, J.A. Drezner, A. Baggish, et al., International recommendations for electrocardiographic interpretation in athletes, *Eur. Heart J.* 39 (2018) 1466–1480.
- [43] D. Andreini, G. Pontone, S. Mushtaq, et al., Atrial fibrillation: diagnostic accuracy of coronary CT angiography performed with a whole-heart 230- μ m spatial resolution CT scanner, *Radiology* 284 (2017) 676–684.
- [44] SCOT-HEART Investigators, D.E. Newby, P.D. Adamson, et al., Coronary CT angiography and 5-year risk of myocardial infarction, *N. Engl. J. Med.* 379 (2018) 924–933.
- [45] M.K. Cheezum, R.R. Liberthson, N.R. Shah, et al., Anomalous aortic origin of a coronary artery from the inappropriate sinus of Valsalva, *J. Am. Coll. Cardiol.* 69 (2017) 1592–1608.
- [46] J. Knuuti, W. Wijns, A. Saraste, et al., 2019 ESC guidelines for the diagnosis and management of chronic coronary syndromes, *Eur. Heart J.* 41 (2020) 407–477.
- [47] G. Ciliberti, R. Laborante, M. Di Francesco, et al., Comprehensive functional and anatomic assessment of myocardial bridging: unlocking the Gordian knot, *Front. Cardiovasc. Med.* 9 (2022), 970422.
- [48] P. Zeppilli, M. Bianco, S.F. Gervasi, et al., Congenital coronary artery anomalies in sports medicine. Why to know them, *Clin. Cardiol.* (2023), <https://doi.org/10.1002/clc.24084> (Online ahead of print).
- [49] D. Andreini, E. Conte, S. Mushtaq, et al., Comprehensive evaluation of left ventricle dysfunction by a new computed tomography scanner: the E-PLURIBUS study, *JACC Cardiovasc. Imaging* 16 (2023) 175–188.
- [50] S. Castelletti, B. Gray, C. Basso, et al., Indications and utility of cardiac genetic testing in athletes, *Eur. J. Prev. Cardiol.* 29 (2022) 1582–1591.
- [51] M. Bergonti, M. Casella, P. Compagnucci, Russo A. Dello, C. Tondo, Electroanatomic mapping system and Intracardiac-Echo to guide endomyocardial biopsy, *Card Electrophysiol. Clin.* 13 (2021) 381–392.
- [52] M. Casella, M. Bergonti, A. Dello Russo, et al., Endomyocardial biopsy: the forgotten piece in the Arrhythmogenic cardiomyopathy puzzle, *J. Am. Heart Assoc.* 10 (2021), e021370.
- [53] M. Casella, A. Dello Russo, M. Bergonti, et al., Diagnostic yield of Electroanatomic voltage mapping in guiding endomyocardial biopsies, *Circulation* 142 (2020) 1249–1260.
- [54] A. Dello Russo, M. Pieroni, P. Santangeli, et al., Concealed cardiomyopathies in competitive athletes with ventricular arrhythmias and an apparently normal heart: role of cardiac electroanatomical mapping and biopsy, *Heart Rhythm.* 8 (2011) 1915–1922.
- [55] A. Dello Russo, P. Compagnucci, A. Zorzi, et al., Electroanatomic mapping in athletes: why and when. An expert opinion paper from the Italian society of sports cardiology, *Int. J. Cardiol.* 383 (2023) 166–174.
- [56] A. Dello Russo, P. Compagnucci, M. Casella, et al., Ventricular arrhythmias in athletes: role of a comprehensive diagnostic workup, *Heart Rhythm.* 19 (2022) 90–99.
- [57] G. Peretto, F. Barzaghi, M.P. Cicalese, et al., Immunosuppressive therapy in childhood-onset arrhythmogenic inflammatory cardiomyopathy, *Pacing Clin. Electrophysiol.* 44 (2021) 552–556.
- [58] D. Corrado, C. Basso, L. Leoni, et al., Three-dimensional electroanatomic voltage mapping increases accuracy of diagnosing arrhythmogenic right ventricular cardiomyopathy/dysplasia, *Circulation* 111 (2005) 3042–3050.
- [59] K. Zeppenfeld, J. Tfelt-Hansen, M. de Riva, et al., 2022 ESC guidelines for the management of patients with ventricular arrhythmias and the prevention of sudden cardiac death, *Eur. Heart J.* 43 (2022) 3997–4126.
- [60] A. Zorzi, A. Cipriani, D. Corrado, Anti-arrhythmic therapy in athletes, *Pharmacol. Res.* 144 (2019) 306–314.
- [61] P.E. Adami, N. Koutianos, A. Baggish, et al., Cardiovascular effects of doping substances, commonly prescribed medications and ergogenic aids in relation to sports: a position statement of the sport cardiology and exercise nucleus of the European Association of Preventive Cardiology, *Eur. J. Prev. Cardiol.* 29 (2022) 559–575.
- [62] Comitato Organizzativo Cardiologico per l'Idoneità allo Sport, Protocolli Cardiologici Per Il Giudizio Di Idoneità Allo Sport Agonistico, 6th ed., CESI, Rome, 2023.