

Renal tumor biopsy in patients with cT1b-T4-M0 disease susceptible to radical nephrectomy: analysis of safety, accuracy and clinical impact on definitive management

Sebastiano Nazzani, Carlotta Zaborra, Davide BIASONI, Mario Catanzaro, Alberto Macchi, Silvia Stagni, Antonio Tesone, Tullio Torelli, Rodolfo Lanocita, Tommaso Cascella, Carlo Morosi, Carlo Spreafico, Maurizio Colecchia, Alfonso Marchianò, Emanuele Montanari, Roberto Salvioni, and Nicola Nicolai

QUERY SHEET

This page lists questions we have about your paper. The numbers displayed at left are hyperlinked to the location of the query in your paper.

The title and author names are listed on this sheet as they will be published, both on your paper and on the Table of Contents. Please review and ensure the information is correct and advise us if any changes need to be made. In addition, please review your paper as a whole for typographical and essential corrections.

Your PDF proof has been enabled so that you can comment on the proof directly using Adobe Acrobat. For further information on marking corrections using Acrobat, please visit <http://journalauthors.tandf.co.uk/production/acrobat.asp>; <https://author-services.taylorandfrancis.com/how-to-correct-proofs-with-adobe/>

The CrossRef database (www.crossref.org/) has been used to validate the references.

AUTHOR QUERIES

Q1 'Bhindi et al. [15] and Shapiro and Abel [20]?' Bhindi is not an author of ref [20].

ARTICLE

Renal tumor biopsy in patients with cT1b-T4-M0 disease susceptible to radical nephrectomy: analysis of safety, accuracy and clinical impact on definitive management

Sebastiano Nazzani^{a,b}, Carlotta Zaborra^a, Davide BIASONI^a, Mario Catanzaro^a, Alberto Macchi^a, Silvia Stagni^a, Antonio Tesone^a, Tullio Torelli^a, Rodolfo Lanocita^c, Tommaso Cascella^c, Carlo Morosi^c, Carlo Spreafico^c, Maurizio Colechia^d, Alfonso Marchianò^c, Emanuele Montanari^a, Roberto Salvioni^a and Nicola Nicolai^a

^aUrology Unit, Fondazione IRCCS Istituto Nazionale dei Tumori, Milan, Italy; ^bUniversità degli Studi di Milano, Milan, Italy; ^cRadiology Department, Fondazione IRCCS Istituto Nazionale dei Tumori, Milan, Italy; ^dPathology Department, Fondazione IRCCS Istituto Nazionale dei Tumori, Milan, Italy

ABSTRACT

Purpose: Renal tumor biopsy was provided in patients candidate to radical nephrectomy for a renal mass ≥ 4 cm, to evaluate treatment deviation.

Methods: Between 2008 and 2017, 102 patients with a solid renal mass ≥ 4 cm with no distant metastases underwent preliminary renal tumor biopsy. We investigated the proportion of patients who proceeded with radical nephrectomy, variables predicting non-renal cell carcinoma (RCC) and concordance between biopsy findings and definitive pathology.

Results: Median tumor size was 70 mm (IQR 55–110). Clinical stage was cT1b in 41, cT2 in 33, cT3 in 25 and cT4 in three patients. A median of three (IQR 2–3) renal tumor biopsies were taken with 16/18 Gauge needles in 97% of cases. Clavien grade I complications occurred in five cases. Malignant tumors were documented in 84 patients: 78 RCCs and six non-RCCs. Fifteen biopsies documented oncocytoma and three were non-diagnostic. Grade was reported in 50 RCCs: 42 (84%) were low and eight (16%) high grade. Eighty-three patients proceeded with radical nephrectomy; six non-RCC malignant tumors underwent combined and/or intensified treatment; 13 of 15 patients with oncocytoma did not undergo radical nephrectomy (eight underwent observation). Definitive pathology confirmed diagnosis in all cases. Grade concordance was 84%, considering two tiers (high vs low grade). No preoperative clinical variable predicted definitive pathology.

Conclusions: Renal tumor biopsy is a safe procedure that leads to radical nephrectomy in most tumors ≥ 4 cm. Nonetheless, 20% of patients exhibited non-RCC histology. Renal tumor biopsy should be considered in this setting.

Abbreviation: RCC: Renal cell carcinoma.

ARTICLE HISTORY

Received 25 March 2022

Revised 13 June 2022

Accepted 16 June 2022

KEYWORDS

Renal neoplasms; tumor biopsy; renal cell carcinoma; oncocytoma; radical nephrectomy

Introduction

Renal tumor biopsy can drive management of renal masses [1,2]. However, renal tumor biopsy is still under evaluation and it is not mandatory in all cases [3,4] as the technique has not been standardized [5], safety is debated and, finally, accuracy, which depends on variables including size and site of the tumor [6,7], reaches a high value only if careful execution methods are followed. Currently, renal tumor biopsy is indicated in patients with small renal masses or in patients with a metastatic renal tumor [8]. Little is known about the role of renal tumor biopsy in the case of larger (≥ 4 cm) renal masses and absence of metastatic deposits, prior to proceeding with radical nephrectomy. A common sentiment is that a renal tumor biopsy would not add meaningful information that may prevent surgery [3], but adds risk of complications that may delay surgery. In our multidisciplinary group, a

shared policy regarding the indications and modalities for renal tumor biopsy was established in 2008. These included patients with a renal mass and no distant deposits candidate to radical nephrectomy. The principle is that histologic characterization may modify decisions and re-direct toward pre-emptive treatments or non-invasive policies [6]. The present study focuses on this topic addressing modifications of indications, diagnostic accuracy and safety of a renal tumor biopsy in patients with a renal mass candidate to radical nephrectomy.

Patients and methods

Study population

Between 2008 and 2017, 102 patients with a renal mass ≥ 4 cm, showing a minimum of 20 HU gain in respect of

surrounding normal parenchyma with contrast enhancement computed tomography (CT)-scans [9] (cT1b-4, N 0–1, M0) [10], susceptible to radical nephrectomy underwent a renal tumor biopsy. All patients were staged with chest CT scans, laboratory exams and physical examination. Cystic lesions were excluded [11].

Intervention

Biopsy was performed with coaxial technique under either CT or ultrasound guide [7,12], according to mass location and size, by an experienced interventional radiologist. A minimum of two core-biopsies had to be taken for each lesion [13]. Patients remained under observation for 24 h after the procedure. Definitive management was confirmed following biopsy results. An experienced pathologist performed histological examinations of biopsies and surgical specimens.

Definition of variables for analyses

Patients were stratified according to biopsy histology. Covariates consisted of age, laterality and gender, clinical and pathological tumor stage, tumor size, actual biopsy needle size, samples number, tumor biopsy histology, tumor biopsy grade according to ISUP (i.e. nucleolar grade) (low grade, high grade or grade 1–4), surgical technique, definitive histology and definitive grade (low grade vs high grade or grade 1–4) [11].

Statistical analysis

Descriptive statistics focused on frequencies and proportions for categorical variables. The statistical significance of differences in medians and proportions was tested with the Kruskal-Wallis and chi-square tests. All statistical tests were two-sided with a significance level set at $p < 0.05$. First, the proportion of patients who maintained indication to radical nephrectomy was measured and the management of those who had a different treatment due to biopsy findings was described. Second, concordance analysis addressing histological type and grading was evaluated comparing the data of definitive pathology. Third, univariable and multivariable logistic regression models tested for predictors of definitive tumor grade. Fourth, univariable and multivariable logistic regression models tested for predictors of different malignant or benign histology.

Analyses were performed using the R software environment for statistical computing and graphics (version 3.6.9 [14]).

Results

General characteristics of the study populations

Among 102 patients (median age was 65 years [interquartile range (IQR) = 57–71]), 67 were male and 35 were female. Tumor side was right in 49 and left in 53 cases. Median axial larger diameter was 70 mm (IQR = 55–110 mm). Clinical (c)

Table 1. Descriptive characteristics of 102 patients with renal masses larger than 4 cm who underwent percutaneous renal biopsy.

	Total (n = 102)
Age	
Median (IQR)	64.5 (57.2–70.7)
Laterality	
Right	49 (48%)
Left	53 (52%)
Gender	
Female	35 (34%)
Male	67 (66%)
cT stage	
cT1b	41 (40%)
cT2	33 (32%)
cT3	25 (25%)
cT4	3 (3%)
cN stage	
cN0	83 (82%)
cN1	19 (18%)
Lesion size (mm)	
Median (IQR)	70 (55–100)
Biopsy type	
16 gauge	22 (26%)
18 gauge	59 (70%)
20 gauge	3 (4%)
Missing	18
Number of biopsy cores	
Median (IQR)	3 (2, 3)
Biopsy histology	
ccRCC	51 (50%)
Papillary RCC	8 (8%)
Chromophobe RCC	8 (8%)
RCC	11 (11%)
Oncocytoma	15 (15%)
Sarcoma	5 (5%)
Squamous UTUC	1 (1%)
Non-diagnostic	3 (3%)
Biopsy grade	
I	14 (28%)
I–II	3 (6%)
II	25 (50%)
>II	5 (10%)
III	3 (6%)
Unknown	52
Complications	
No	97 (95%)
Yes	5 (5%)

T-stage was cT1b in 41, cT2 in 33, cT3 in 25 and cT4 in three patients, respectively. cN stage was cN0 in 83 patients, cN1 in 19 (Table 1).

Renal biopsies characteristics and findings

Renal core-biopsies were performed in the vast majority of patients with 18 Gauge needles (70%) or 16 Gauge needles (26%). Only three underwent core-biopsy with 20 Gauge needle. Median samples number was 3 (IQR 2–3). Eighty-four biopsies documented malignant histology. Specifically, 51 consisted of clear cell (cc) RCCs, eight papillary RCCs, 11 unspecified RCCs, eight chromophobe RCCs, five retroperitoneal sarcomas and one upper urinary tract squamous carcinoma. Finally, 15 biopsies documented oncocytoma while three were non-diagnostic. Grade was specified in 50 patients: 42 (84%) were low grade and eight were high grade (16%), or 14 (28%) were grade I, three (6%) were grade I–II, 25 (50%) were grade II, five (10%) were grade > II and three (6%) were grade III. After stratification according to low and high malignant potential [15], 50 patients harbored

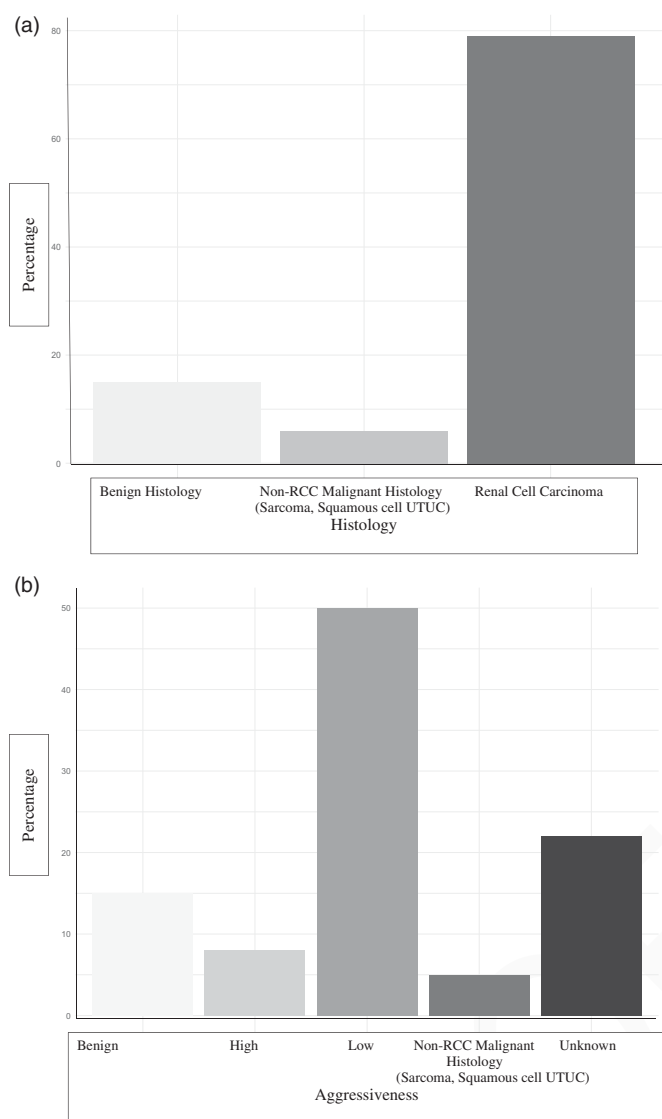


Figure 1. (a) Histological distribution of renal biopsy findings. (b) Histological distribution of renal biopsy findings.

non-aggressive malignant histology. Conversely, aggressive malignant histology was present in eight and remained undefined in 23 (Figure 1(a and b)). Grade 1 Clavien-Dindo complications were recorded in five patients (Table 1).

Surgery characteristics and findings

Eighty-one patients with a diagnosis of RCC or with non-diagnostic biopsy underwent radical nephrectomy, *via* laparoscopy in 45 and open access in 36. Patients harboring sarcoma had compartmental open surgical radical resection (which included bowel and/or muscle resection) with or without neoadjuvant chemotherapy, whilst the patient with an upper urinary tract squamous carcinoma underwent open nephroureterectomy with bladder cuff excision. Finally, seven patients with oncocytoma underwent surgery: five patients had their planning changed in open or laparoscopic partial nephrectomy, while two, after thorough discussion with the patients, underwent radical nephrectomy due to symptomatic disease (Table 2).

At definitive pathology, biopsy histological subtype was confirmed in 93% of patients. Unspecified RCCs resulted in six ccRCCs, two collecting duct RCCs, two papillary RCCs and one adult Wilms tumor (Table 2). Grade was confirmed in 82% of cases according to two tiers (low vs. high) and in 54% according to four tiers (1–4) classification (Table 3). The three cases with non-diagnostic biopsy had ccRCC in two and type II papillary RCC in one at definitive pathology.

Eight patients with oncocytoma did not undergo surgery and were followed. All of them are alive with no progression of disease after a median follow-up of 30 months (Supplementary Table S1). No seeding in the biopsy channel was recorded. Respectively, five, two and five patients had distant, local and both distant and local relapse. All patients had open or laparoscopic radical nephrectomy.

Predictors of different malignant or benign histology

Univariable and multivariable logistic regression models tested for predictors of definitive tumor grade, specifically, tumor size, cT stage and needle size (16, 18 and 20 gauge) (Supplementary Table S2). Tumor size (OR = 0.98; CI = 0.97–0.99, p -value = 0.03) showed an association in univariable logistic regression models. However, in multivariable logistic regression models, no significant association was found between any variable and prediction of definitive grading.

Predictors of different malignant or benign histology

Univariable and multivariable logistic regression models tested for predictors of non-RCC or benign histology, specifically, tumor size, cT stage, age and gender. However, no significant association was found between tumor, patients characteristics and biopsy histology (Figure 2(a and b)).

Discussion

According to the most recent recommendations, renal tumor biopsy is not mandatory and is rarely performed in cases of large (≥ 4 cm) renal masses [1,3,4,6,12]. In this setting, the management of renal masses is actually being driven by imaging, due to the high sensitivity and specificity of MRI [16,17] and CT scan [9] in diagnosing RCC. Nonetheless, accuracy and the added clinical information that renal tumor biopsy can warrant might crucially support its use also in large renal masses, in order to obtain a pre-surgical diagnosis. Moreover, biopsy prior to treatment in large renal masses allows histological verification of a malignant tumor, which does represent a stronger element to proceed with radical nephrectomy, which reinforces the process of a conscious and complete patient informed consent.

In the present study we analyzed patients with renal masses >4 cm and no distant metastases who underwent systematically renal tumor biopsy before proceeding with radical nephrectomy. The accuracy of our series compares with other experiences [11]. Biopsy histology was confirmed in 93% of patients at definitive pathology, while the tumor

Table 2. Descriptive characteristics of 102 patients with renal masses larger than 4 cm according to surgical treatment and definitive pathology.

	Total (n = 102)
Surgery type	
Laparoscopic radical nephrectomy	47 (53%)
Laparoscopic partial nephrectomy	1 (1%)
Open radical nephrectomy	36 (41%)
Open partial nephrectomy	4 (5%)
Other [Observation (n = 8), Nephroureterectomy with bladder cuff excision or compartmental surgery (n = 6)]	14
Definitive histology	
Clear cell RCC	58 (62%)
Papillary RCC	10 (10%)
Chromophobe RCC	9 (10%)
Collecting duct RCC	2 (2%)
MiT family translocation RCC	1 (1%)
Oncocytoma	7 (8%)
Sarcoma	5 (5%)
Squamous upper urinary tract urothelial carcinoma	1 (1%)
Adult Wilms tumor	1 (1%)
Observation	8
Definitive grade	
I	12 (18%)
I–II	1 (2%)
II	27 (40%)
II–III	1 (2%)
III	12 (18%)
III–IV	1 (11%)
IV	13 (20%)
Pathological T stage	
pT1b	29 (33%)
pT2	14 (16%)
pT3	39 (44%)
pT4	6 (7%)
Other (Observation, Nephroureterectomy with bladder cuff excision or compartmental surgery)	14

Table 3. Histology and grade concordance (missing are related to absence of expression of tumor grade at renal biopsy or absence of definitive pathological report).

	Total (n = 102)
Concordance histology	
False	6 (7%)
True	85 (93%)
No biopsy histology	3
No definitive pathological report	8
Concordance grade (High grade–Low grade)	
False	9 (18%)
True	41 (82%)
No biopsy grade	44
No definitive pathological report	8
Concordance Grade (I–IV)	
False	23 (46%)
True	27 (54%)
No biopsy grade	44
No definitive pathological report	8

grade concordance was 54% when four tiers were used, and 82% when two tiers were used (high vs low grade). Safety of renal tumor biopsy in our experience compared with the most recent data. Few and mild side-effects (all grade 1) occurred. Malignant tumors were documented in 84 (82%) cases. These consisted in RCCs in 76% and non-RCC malignant tumors in 6% of cases (Figure 1(a and b)). The latter included sarcoma subtypes in five and in upper tract urothelial cancer in one case, who needed and eventually received a different and intensified surgical and/or medical treatment other than radical nephrectomy. This represents an important and new question, indicating how renal tumor biopsy can prevent insufficient treatment and steer towards intensification in a small but not negligible percentage of patients with large renal masses.

On the other side of the spectrum, renal tumor biopsy documented a benign histology in 15 patients.

Eventually, although an association between mass size and cancer is known, gross size alone is not an absolute predictor of a more aggressive histology. According to a pool-analysis of American studies, as many as 9.2% of 2,193 renal masses between 4 and 7 cm and 6.3% of 1,983 renal masses >7 cm eventually were benign lesions [18]. The proportion of benign histology in our series is similar to the report of Richard et al. [6] in renal masses <4 cm. Very interestingly, they reported a significant decrease (5% vs 16%, $p < 0.001$) of histologically benign tumors at the definitive pathology in centers where preoperative renal tumor biopsy was performed. Only two out of 15 patients with benign histology underwent radical nephrectomy in our series. Conversely, 13 underwent either kidney-sparing surgery (5) or observation (8), and all of them remained alive and progression-free.

Not unexpectedly, no significant association was found between tumor and patients characteristics and biopsy histology at univariable and multivariable logistic regression models. The unpredictable nature of even larger renal masses leads us to consider renal tumor biopsies as a possible tool in their characterization. This preoperative information, joined with other clinical information, including patient's characteristics, may actually lead to alternative treatment other than radical nephrectomy even in patients with large renal masses, including a less extensive surgery.

The low rate (3%) of non-diagnostic biopsy could partially reflect the role of tumor size as a predictor of diagnostic core biopsy [7,12]. Accuracy in predicting definitive grade stands as a crucial issue. In our series tumor size was inversely associated with grade expression in univariable

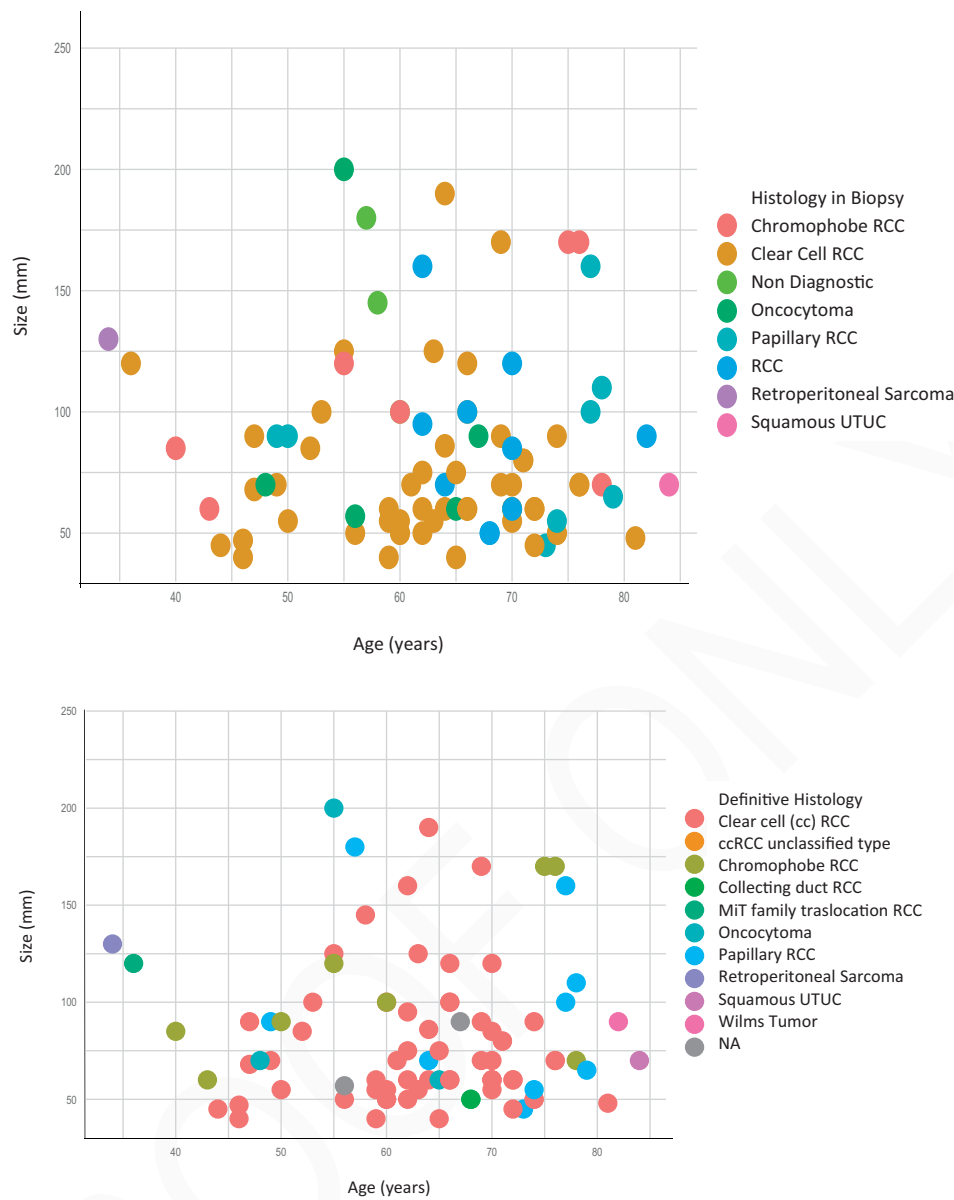

Figure 2. (a) and (b) Distribution of histological subtypes of renal biopsy and definitive specimen findings according to age and tumor size.

logistic regression models. The evolution of renal tumor biopsy techniques has shown how the increase in the number and supply of multi-quadrant samples allow the elimination of inconclusive histological cases and a crucial improvement in the characterization of grade in large renal masses [19]. In fact, a stratification of RCCs according to indolent and aggressive malignant behaviour, as previously described by Bhindi et al. [15,20], may permit a better tailored treatment even in larger renal masses. In our series, this stratification resulted in 50 cases of non-aggressive malignant histology and in eight of aggressive malignant histology, while, unfortunately, it remained undefined in 23. Unfortunately, neither size, stage nor core-biopsy needle (18 vs 16 gauge) associated with a better accuracy in definitive grade identification in multivariable logistic regression models.

A growing interest in nephron-sparing surgery has shifted to highly complex kidney masses (including size). The data

from RECORD-2, a multicenter collection of cases with complex renal masses undergoing nephron-sparing surgery, favorably centered on the question of the feasibility, safety and efficacy of nephron-sparing surgery in renal masses larger than 4 cm [21]. Pre-operative knowledge of aggressiveness may better guide type of definitive surgery, favoring nephron sparing resections when less aggressive tumors have been documented.

Taken together, our findings may support the role of renal tumor biopsy not only for patients with metastatic or small renal tumors. This information can outline the scenario in which accurate preoperative histology can justify a better decision, which may include conservative or less aggressive treatment in selected patients or intensified management in those with aggressive non-RCC tumors. It is not intended to support the debate on the minimum percentage of patients who, following the biopsy, could be subjected to a treatment other than radical nephrectomy. A figure like ours, with two

out of 10 patients having a diagnosis involving a deviation from the radical nephrectomy, may justify renal tumor biopsy in patients with renal masses ≥ 4 cm.

Our study is not without limitations, other than an amendable accuracy in determining grade and aggressiveness of renal tumors. Our institute is a comprehensive cancer center and a selection bias due to the effect of seeking for a second opinion in many of our cases is possible. This may have increased the percentage of patients with a histology other than RCC. Furthermore, we did not systematically perform renal tumor biopsy in patients in whom nephron-sparing surgery was planned following imaging only, regardless of tumor volume. This implies that we may not have a complete overview of our target population, as a proportion of patients with T1b or T2 tumors have actually undergone partial nephrectomy, without cross-referencing a renal tumor biopsy in their care path. Finally, the apparently high local recurrence rate is due to patients' disease characteristics. Specifically, four of those patients had nodal disease with, respectively, 6, 12, 6 and 10 positive nodes. Another two patients had pT3a disease (one papillary type II RCC and one ccRCC grade III). Finally, one patient had pT1b ccRCC grade III disease. Moreover, we also considered psoas and nodal recurrences as local recurrence. The relapsing disease in the renal fossa or in the perinephric fat is limited to two cases.

Conclusions

Renal tumor biopsy in patients with a renal mass ≥ 4 cm is a safe procedure. Renal tumor biopsy confirms an indication to radical nephrectomy in the vast majority of cases, but also allows us to modulate definitive treatment towards less intensive treatment – up to surgical omission – or more intensive management in a minority but clinically relevant proportion of patients. With the limitation due to possible selection biases, we believe that renal tumor biopsy should be considered in this setting.

Author contributions

SN and NN had full access to all the data in the study and take responsibility for the integrity of the data and the accuracy of the data analysis.

Disclosure statement

NN certifies that all conflicts of interest, including specific financial interests and relationships and affiliations relevant to the subject matter or materials discussed in the manuscript (e.g. employment/affiliation, grants or funding, consultancies, honoraria, stock ownership or options, expert testimony, royalties, or patents filed, received, or pending), are the following: None.

References

- [1] Shannon BA, Cohen RJ, de Bruto H, et al. The value of preoperative needle core biopsy for diagnosing benign lesions among small, incidentally detected renal masses. *J Urol.* 2008;180(4):1257–1261; discussion 1261.
- [2] Maturen KE, Nghiem HV, Caoili EM, et al. Renal mass core biopsy: accuracy and impact on clinical management. *AJR Am J Roentgenol.* 2007;188(2):563–570.
- [3] Professionals S-O. EAU guidelines: renal cell carcinoma. Uroweb n.d.; [cited 2021 Jan 8]. Available from: <https://uroweb.org/guideline/renal-cell-carcinoma/>.
- [4] NCCN Clinical Practice Guidelines in Oncology n.d.; [cited 2020 Oct 16]. Available from: https://www.nccn.org/professionals/physician_gls/default.aspx.
- [5] Veltri A, Garetto I, Tosetti I, et al. Diagnostic accuracy and clinical impact of imaging-guided needle biopsy of renal masses: retrospective analysis on 150 cases. *Eur Radiol.* 2011;21(2):393–401.
- [6] Richard PO, Lavallée LT, Pouliot F, et al. Is routine renal tumor biopsy associated with lower rates of benign histology following nephrectomy for small renal masses? *J Urol.* 2018;200(4):731–736.
- [7] Leveridge MJ, Finelli A, Kachura JR, et al. Outcomes of small renal mass needle core biopsy, nondiagnostic percutaneous biopsy, and the role of repeat biopsy. *Eur Urol.* 2011;60(3):578–584.
- [8] Motzer RJ, Barrios CH, Kim TM, et al. Phase II randomized trial comparing sequential first-line everolimus and second-line sunitinib versus first-line sunitinib and second-line everolimus in patients with metastatic renal cell carcinoma. *J Clin Oncol.* 2014;32(25):2765–2772.
- [9] Israel GM, Bosniak MA. How I do it: evaluating renal masses. *Radiology.* 2005;236(2):441–450.
- [10] TNM Classification of Malignant Tumours, 8th Edition | Wiley n.d.; [cited 2022 April 20]. Available from: <https://www.wiley.com/en-nt/TNM+Classification+of+Malignant+Tumours%2C+8th+Edition-p-9781119263562>.
- [11] Marconi L, Dabestani S, Lam TB, et al. Systematic review and meta-analysis of diagnostic accuracy of percutaneous renal tumour biopsy. *Eur Urol.* 2016;69(4):660–673.
- [12] Volpe A, Mattar K, Finelli A, et al. Contemporary results of percutaneous biopsy of 100 small renal masses: a single center experience. *J Urol.* 2008;180(6):2333–2337.
- [13] Neuzillet Y, Lechevallier E, Andre M, et al. Accuracy and clinical role of fine needle percutaneous biopsy with computerized tomography guidance of small (less than 4.0 cm) renal masses. *J Urol.* 2004;171(5):1802–1805.
- [14] Nazzani S, Bandini M, Preisser F, et al. Postoperative paralytic ileus after major oncological procedures in the enhanced recovery after surgery era: a population based analysis. *Surg Oncol.* 2019;28:201–207.
- [15] Bhindi B, Thompson RH, Lohse CM, et al. The probability of aggressive versus indolent histology based on renal tumor size: implications for surveillance and treatment. *Eur Urol.* 2018;74(4):489–497.
- [16] Rosenkrantz AB, Hindman N, Fitzgerald EF, et al. MRI features of renal oncocytoma and chromophobe renal cell carcinoma. *AJR Am J Roentgenol.* 2010;195(6):W421–427.
- [17] Pedrosa I, Sun MR, Spencer M, et al. MR imaging of renal masses: correlation with findings at surgery and pathologic analysis. *Radiographics.* 2008;28(4):985–1003.
- [18] Johnson DC, Vukina J, Smith AB, et al. Preoperatively misclassified, surgically removed benign renal masses: a systematic review of surgical series and United States population level burden estimate. *J Urol.* 2015;193(1):30–35.
- [19] Abel EJ, Heckman JE, Hinshaw L, et al. Multi-quadrant biopsy technique improves diagnostic ability in large heterogeneous renal masses. *J Urol.* 2015;194(4):886–891.
- [20] Shapiro DD, Abel EJ. Predicting aggressive behavior in small renal tumors prior to treatment. *Ann Transl Med.* 2018;6:46.
- [21] Perioperative and Mid-term Oncological and Functional Outcomes After Partial Nephrectomy for Complex (PADUA Score ≥ 10) Renal Tumors: A Prospective Multicenter Observational Study (the RECORD2 Project) – European Urology Focus n.d.; [cited 2021 Jan 12]. Available from: [https://www.eu-focus.europanurology.com/article/S2405-4569\(20\)30210-8/fulltext](https://www.eu-focus.europanurology.com/article/S2405-4569(20)30210-8/fulltext).