

## REVIEW ARTICLE

# Ultrasonography in inflammatory bowel disease – So far we are?

Maaser Christian<sup>1</sup>  | Maconi Giovanni<sup>2</sup> | Kucharzik Torsten<sup>3</sup>  | Allocca Mariangela<sup>4</sup> 

<sup>1</sup>Outpatients' Clinic of Gastroenterology, University Teaching Hospital Lueneburg, Lueneburg, Germany

<sup>2</sup>Gastroenterology Unit – Department of Biomedical and Clinical Science - 'L.Sacco' University Hospital, University of Milan, Milan, Italy

<sup>3</sup>Department of Gastroenterology, University Teaching Hospital Lueneburg, Lueneburg, Germany

<sup>4</sup>Gastroenterology and Endoscopy, IRCCS Ospedale San Raffaele and University Vita-Salute San Raffaele, Milan, Italy

## Correspondence

Maaser Christian, Outpatients' clinic of Gastroenterology, University Teaching Hospital Lueneburg, Lueneburg, Germany. Email: [christian.maaser@klinikum-lueneburg.de](mailto:christian.maaser@klinikum-lueneburg.de)

## Abstract

Intestinal ultrasound (IUS) is a non-invasive and accurate tool to assess inflammatory bowel disease. The ECCO-ESGAR guideline recommends the use of IUS for the assessment of disease activity and complications in Crohn's disease (CD). In addition, an increasing body of evidence suggests the use of IUS as alternative to colonoscopy in monitoring CD and in assessing disease activity of ulcerative colitis. Early responsiveness of IUS findings by the first weeks of treatment and the advantage to perform the procedure in real time may dramatically change frequency of the assessment of treatment response in the future and speed up the clinical decision-making process. Development of validated and reproducible sonographic scores to measure disease activity and therapeutic response and spread of knowledge of IUS remain relevant issues for the future in which current researchers and the International Bowel Ultrasound (IBUS) Group are actively engaged.

## KEYWORDS

Crohn's disease, ibd, inflammatory bowel disease, intestinal ultrasound, perineal ultrasound, ulcerative colitis

## CLINICAL CASE A

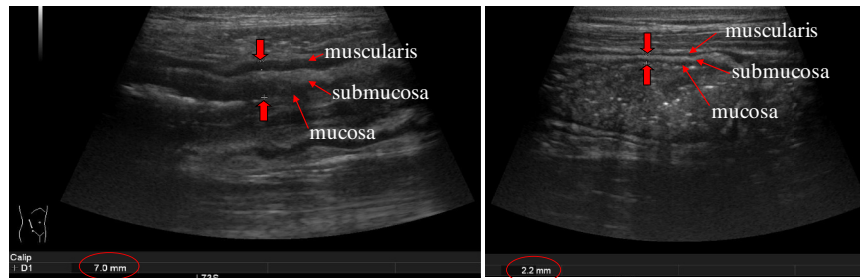
A 25-year-old patient with known ileal Crohn's disease (CD) is presenting with an acute steroid-refractory flare with abdominal cramping and increased stool frequency, slightly increased C reactive protein and fecal calprotectin. On intestinal ultrasound (IUS) (Figure 1) the terminal ileum appears inflamed over a length of more than 20 cm with reduced peristalsis, but no signs of complication such as stricture, fistula/abscess. An anti-TNF therapy is started.

Following the ECCO/ESGAR guideline on diagnostics in inflammatory bowel disease (IBD), endoscopic or transmural response to therapy in CD should be evaluated within 6 months following initiation of therapy.<sup>1</sup> Current evidence suggests that this recommendation does not reflect on when to expect relevant IUS changes.

In the prospective, non-interventional, multicentre TRUST study performed in 47 German IBD centres with 234 patients studying the change of defined IUS parameters in response to therapy, a highly significant proportion of patients showed normalization of bowel wall thickness (BWT) as early as 3 months following initiation of treatment.<sup>2</sup> In addition, at the same timepoint a highly significant proportion of patients demonstrated normalization of other IUS parameters, such as bowel wall stratification, Doppler signal and mesenteric proliferation. These findings were recently confirmed in another multicentre prospective trial performed in 16 Italian IBD centres by Calabrese et al., showing a significant improvement of BWT at 3 months from baseline in response to various anti-inflammatory drugs.<sup>3</sup> While both trials did not assess earlier timepoints, in the Stardust IUS substudy significant response rates

This is an open access article under the terms of the Creative Commons Attribution-NonCommercial-NoDerivs License, which permits use and distribution in any medium, provided the original work is properly cited, the use is non-commercial and no modifications or adaptations are made.

© 2022 The Authors. United European Gastroenterology Journal published by Wiley Periodicals LLC on behalf of United European Gastroenterology.



**FIGURE 1** Inflamed terminal ileum with increased bowel wall thickness (BWT) and intact stratification (left), normal BWT terminal ileum (right)

defined as a reduction in BWT of >25% compared to baseline were detected as early as 4 weeks following initiation of ustekinumab treatment.<sup>4</sup> The data from these three multicentre trials suggest that an IUS examination at an even earlier timepoint than the 6-month as recommended in the ECCO-ESGAR guideline might be more feasible to differentiate responders from non-responders leading to an earlier optimization of therapy and potentially better long-term outcome.

### What is the current evidence for modifying disease course in relation to IUS findings?

Zorzi F et al. demonstrated that patients showing IUS transmural remission to anti-TNF treatment after 18 months did not require surgery, needed less steroids and showed reduced hospitalization rates during a follow up.<sup>5</sup> Similar evidence comes from Spanish studies.<sup>6,7</sup> In particular, Paredes et al., found that patients with transmural healing after 1 year of biological therapy, as defined by  $BWT \leq 3$  mm and absent or barely visible vascularization at color Doppler, had better outcomes in the follow-up, in terms of less need for corticosteroids, change of therapy or surgery.<sup>7</sup> While a definitive definition of transmural healing has not yet been established, some evidence suggests that it may be a better target than mucosal healing.<sup>8</sup> Allocca et al. could recently demonstrate that patients with endoscopic healing (as defined by a SES-CD  $\leq 2$ ), but still showing residual ultrasound activity (defined by a bowel ultrasound score [BUSS] > 3.52), have an increased risk of a negative disease course including increased rates of surgery, hospitalization and need of treatment escalation.<sup>9</sup> Based on these findings, adjusting therapeutic approaches on ultrasound parameters appear to be a reasonable approach. However, interventional randomized multicentre trials with IUS endpoints that show an improved long-term outcome in patients where treatment is adjusted based on IUS findings only are currently still lacking.

### CLINICAL CASE CONTINUED

*The patient responds well to anti-TNF therapy and reaches clinical remission and IUS transmural healing within 12 weeks (example for response see Figure 2).*

This leads to the question regarding the evidence for follow-up examinations in the asymptomatic CD patient.

Currently there is no scientifically sound trial on the relevance of follow-up IUS in the asymptomatic CD patient. However, it is a well-known fact that clinical remission often does not equal transmural healing (Figure 3). This has been demonstrated by Castiglione et al. who compared rates of clinical, mural and transmural remission.<sup>10</sup> In particular transmural inflammation in ileal disease often does not lead to clinical symptoms until the stricturing component becomes relevant. In daily clinical practice, we suggest performing IUS in the asymptomatic CD patient depending on the severity of the past disease course and the use of biologic/immunosuppressive therapy every 3–6 months in order to determine early progression of disease and to prevent development of complications such as strictures and fistulas. IUS monitoring may require shorter intervals in patients with higher disease burden.

### CLINICAL CASE CONTINUED

*Six months later the patient in clinical remission under anti-TNF therapy presents with acute perineal pain.*

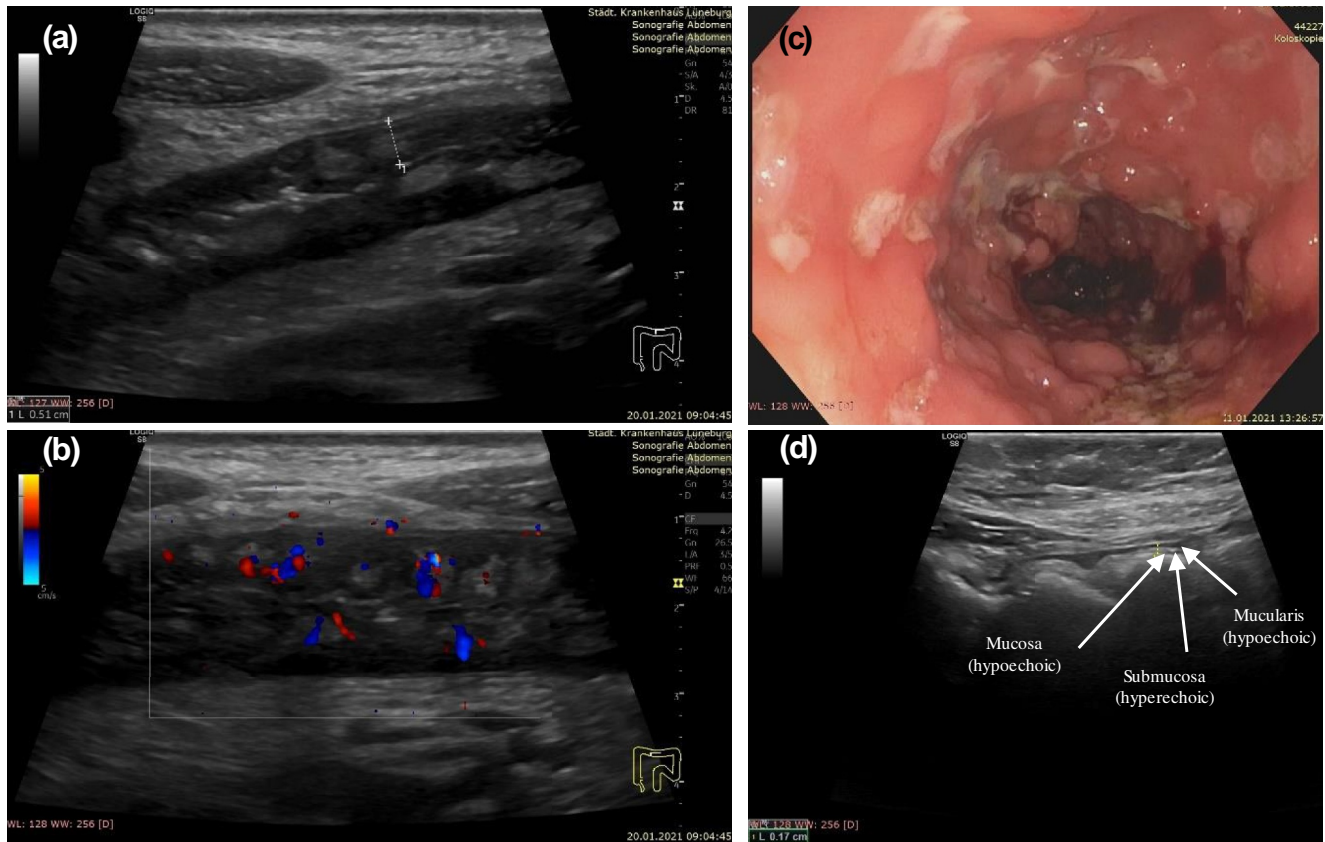
*Because of clinically suspected perineal abscess the patient underwent transperineal ultrasound (TPUS), which revealed a perineal abscess (Figure 4), while clinical inspection did not show any suspicious swelling.*

A systematic review of the literature shows that TPUS has good overall accuracy in the assessment of perianal fistulae and abscesses.<sup>11</sup> Furthermore, Gastroenterologists and IBD experts particularly value IUS because of real-time and direct assessment of disease activity and complications that allow rapid treatment decisions, avoiding delays incurred from further testing.

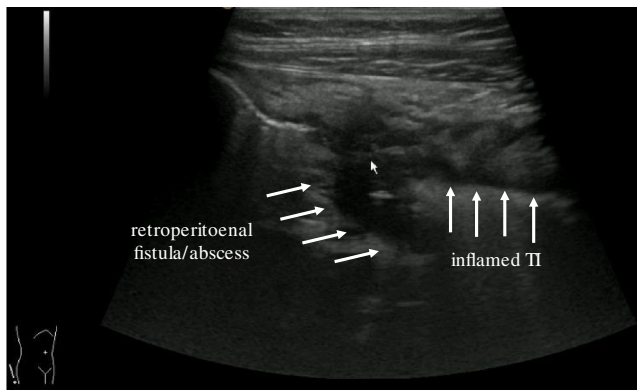
In addition to rapid detection or exclusion of abscesses, perianal fistulas can be detected by using TPUS with the potential for follow-up (Figure 5).<sup>12,13</sup>

### IUS for detecting CD complications

Strictures, fistula and abscess development are common complications in CD. One relevant advantage of IUS compared to other cross



**FIGURE 2** Inflamed transverse colon with increased bowel wall thickness (BWT), loss of stratification, loss of haustration and mesenteric proliferation (a), increased vascularization (b), corresponding endoscopic finding (c), transmural healing with normalization of BWT and stratification, normal haustration and no mesenteric proliferation (d)



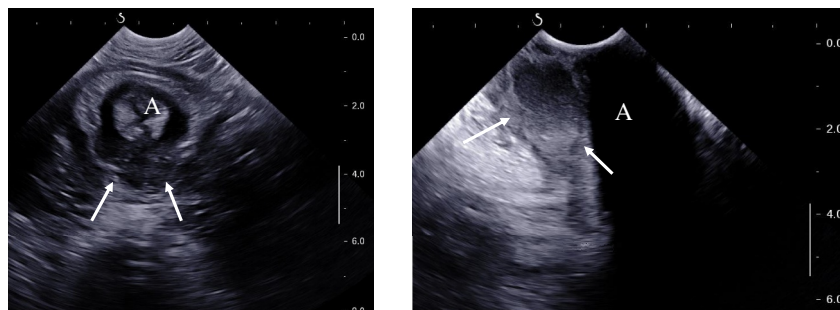
**FIGURE 3** Inflamed terminal ileum with loss of bowel wall stratification (BWS), retroperitoneal fistula with abscess in a patient being in clinical remission

sectional imaging methods is the real-time observation of motility. Assessing motility allows to monitor whether a stricture is just a functional contraction or a fixed stricture with a prestenotic dilatation (Figure 6). However, it has to be noted that the assessment of motility lacks a standard assessment and is more subjective than other markers such as the measurement of BWT, which is more objective

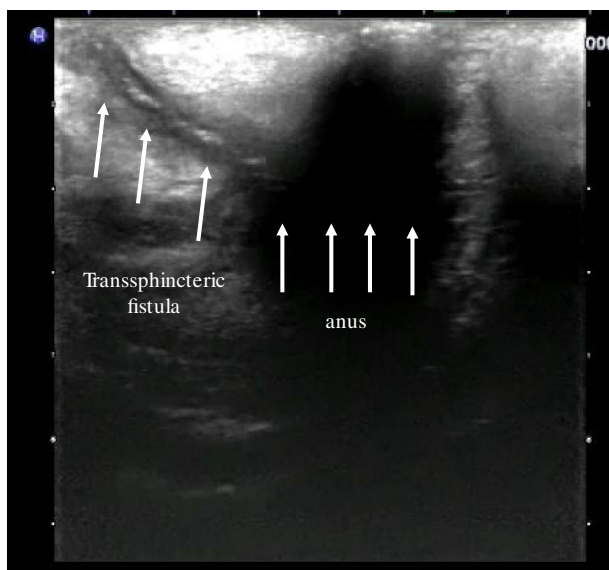
and reproducible. Furthermore, abscesses can be detected as hypoechoic mass with hyperechoic gaseous signals (Figure 7). Sometimes, differentiation between an inflammatory mass and an abscess can be challenging. This challenge can be easily overcome by using i.v. contrast medium to perform a contrast enhanced ultrasonography either showing no perfusion in an abscess or perfusion as sign of an inflammatory mass. Fistula, for example, retroperitoneal, entero-vesical or entero-cutaneous can be detected by IUS as hypoechoic tracts containing hyperechoic signals within the tract as sign for air. Though there are no multi-centre prospective trials on the detection of these complications and will most likely never be performed, IUS is generally accepted as an equivalent option to determine fistulizing CD in comparison to MRI.<sup>1,14</sup>

### IUS in ulcerative colitis

The rationale of using IUS in CD being a transmural disease often involving the terminal ileum, which would require a complete colonoscopy to reach the involved segment, is now broadly accepted. In contrast, the use of IUS in ulcerative colitis (UC) often referred to as a mucosal disease and due to its involvement starting in the rectum, easy to be reached by sigmoidoscopy, is often questioned.



**FIGURE 4** Transversal (left) and sagittal (right) scans of a large posterior intersphincteric abscess (arrows), A anus



**FIGURE 5** Transsphincteric fistula in a patient with Crohn's disease

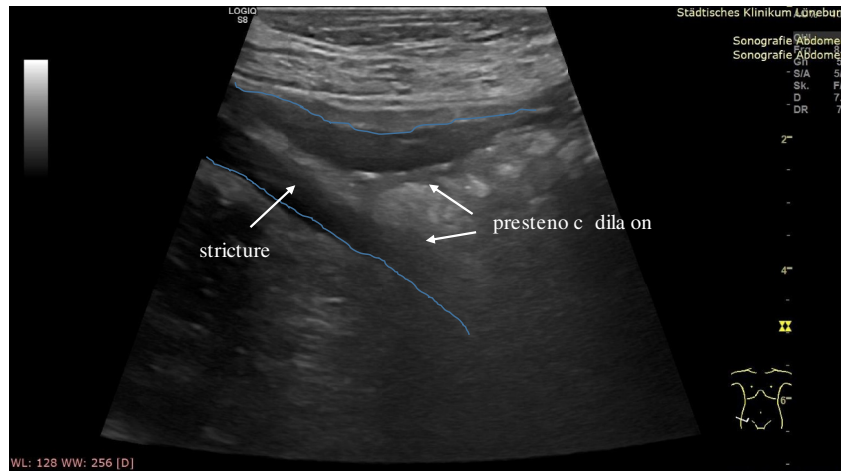
However, several recent trials could demonstrate significant IUS findings in UC with BWT to be the most relevant parameter (Figure 8). In a prospective multicentre trial performed in 156 UC patients in 5 Japanese IBD centres, IUS showed a moderate concordance with colonoscopy for all colonic segments except the rectum.<sup>15</sup> Allocca et al. found by logistic regression that bowel wall thickening and presence of vascularization at color Doppler are two relevant criteria that correlate well with endoscopic activity in UC. These criteria have been structured and validated as the Milan Ultrasound Criteria (MUC) and can be used to score disease activity in a non-invasive manner. In particular, a MUC > 6.2 has been shown to be an indicator of endoscopic activity with a specificity of 100%.<sup>16,17</sup> IUS in UC thereby has been shown to be a reliable tool with an almost perfect inter-observer agreement for BWT and substantial for color Doppler signal.<sup>18</sup> In the multicentre TRUST-UC trial involving 42 German IBD centres prospectively evaluating IUS response in a total of 224 UC patients with a clinical flare requiring medical therapy, clinical response and

normalization of BWT showed a high correlation.<sup>19</sup> Even more intriguing already at 2 weeks after initiation of an anti-inflammatory treatment the percentage of patients with an increased BWT at baseline in the sigmoid and descending colon decreased significantly and remained low at week 6 and 12. As the rectum is the only area of the colon that often cannot be evaluated by transabdominal intestinal ultrasound, Sagami et al. have explored the use of perineal ultrasound in detecting proctitis. In 53 UC patients requiring colonoscopy TPUS has been performed simultaneously. In this study, rectal BWT as well as the Limberg score for vascularization correlated well with rectal Mayo endoscopic subscore and histological indices.<sup>20</sup> In a multivariable logistic regression analysis, BWT in TPUS was a significant independent predictor for rectal endoscopic and histologic healing and the predictability was better than for fecal calprotectin.

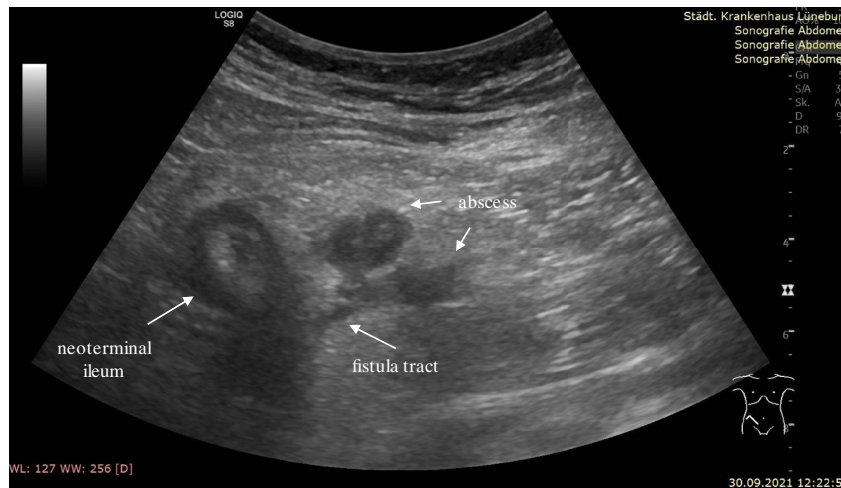In summary, IUS in UC has been shown to be a reliable non-invasive option to detect inflammatory activity as well as the extend of involved bowel in the symptomatic UC patient. In addition, IUS has been demonstrated a valuable tool for monitoring response to therapy at timepoints as early as 2 weeks after treatment initiation with BWT appearing the most relevant parameter showing good correlation with endoscopic activity. Transperineal ultrasound might be added to assess rectal inflammation and used as an alternative diagnostic tool in patients with isolated proctitis.

### Teaching and implementation

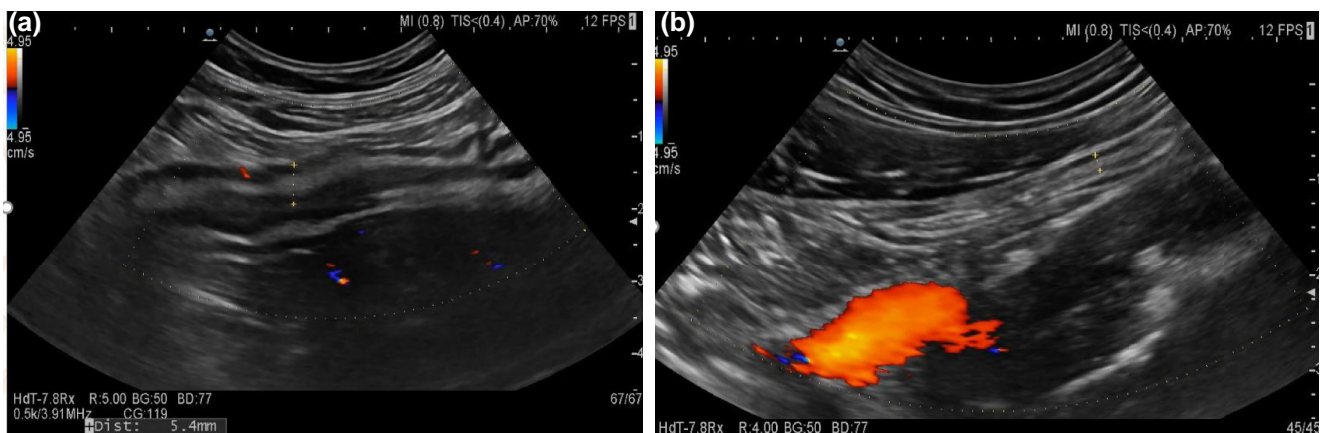
Intestinal ultrasound until very recently has only been performed by gastroenterologists in very few countries around the world and various recommendations on the use have been published.<sup>21-24</sup> Rising interest in the past years has created a demand for an IUS training curriculum which would enable a local implementation as well as help with acceptance by local authorities. The most established IUS-in-IBD training curriculum which since its start has trained IBD gastroenterologists from more than 50 countries around the world is offered by the International Bowel Ultrasound Group (IBUS; [www.ibus-group.org](http://www.ibus-group.org)), a non-profit organization. Success stories of



**FIGURE 6** Prestenotic dilation in a patient with Crohn's disease with an anastomotic stricture after ileo-coecal resection with increased bowel wall thickness (BWT) and loss of stratification



**FIGURE 7** Inflamed neoterminal ileum in a patient with Crohn's disease. Fistula tract starting from the neoterminal ileum ending with an abscess. Mesenteric proliferation around the abscess



**FIGURE 8** Inflamed sigmoid with increased Bowel wall thickness (BWT), intact stratification with a prominent submucosa in a patient with ulcerative colitis (left), transmural healing in response to therapy (right)

this training curriculum are for example, Australia now having a local IUS network (GENIUS; <https://genius.health>) and Denmark. The other challenge besides learning the technique is the local implementation, which includes acquisition of an ultrasound machine, convincing colleagues e.g., surgeons, often negotiations with radiologists and integration into the routine of an IBD clinic as well as optimal documentation of images and loops in the hospital picture archiving and communication system. Furthermore, reimbursement as well as legal issues need to be solved country-specific.

### Areas of uncertainty

While IUS parameters to detect and monitor inflammation are clearly defined and agreed on by expert consensus (Table 1),<sup>21,22</sup> validated activity scores are warranted especially for clinical trials to quantify inflammation and measure response. Various scores, most recently the BUSS and IBUS-SAS score for CD<sup>9,25</sup> and the MUC for UC,<sup>26</sup> have been published and systematically reviewed.<sup>17</sup> However, as summarized in this review reliability and responsiveness data are still limited and most studies have at least one unclear or high risk of bias rating leading to the recommendation that future research should focus on fully validating scoring systems for both diseases. Furthermore, up to date studies prospectively comparing ultrasound to endoscopy in regard to the treat-to-target approach are lacking.

Continuous inflammation in both CD and UC leads to the development of fibrosis for example, in CD causing clinically relevant strictures. This then leads to the question whether continuous medical treatment or rather surgery would be the better option.

However, up to date there is no valid methodology to measure fibrosis. IUS with special applications such as elastography and contrast enhanced ultrasound appears to be promising, but solid data from prospective multi-centre trials are an unmet need especially considering that new anti-fibrotic drugs are in the development pipeline.<sup>27-30</sup>

### CONCLUSION

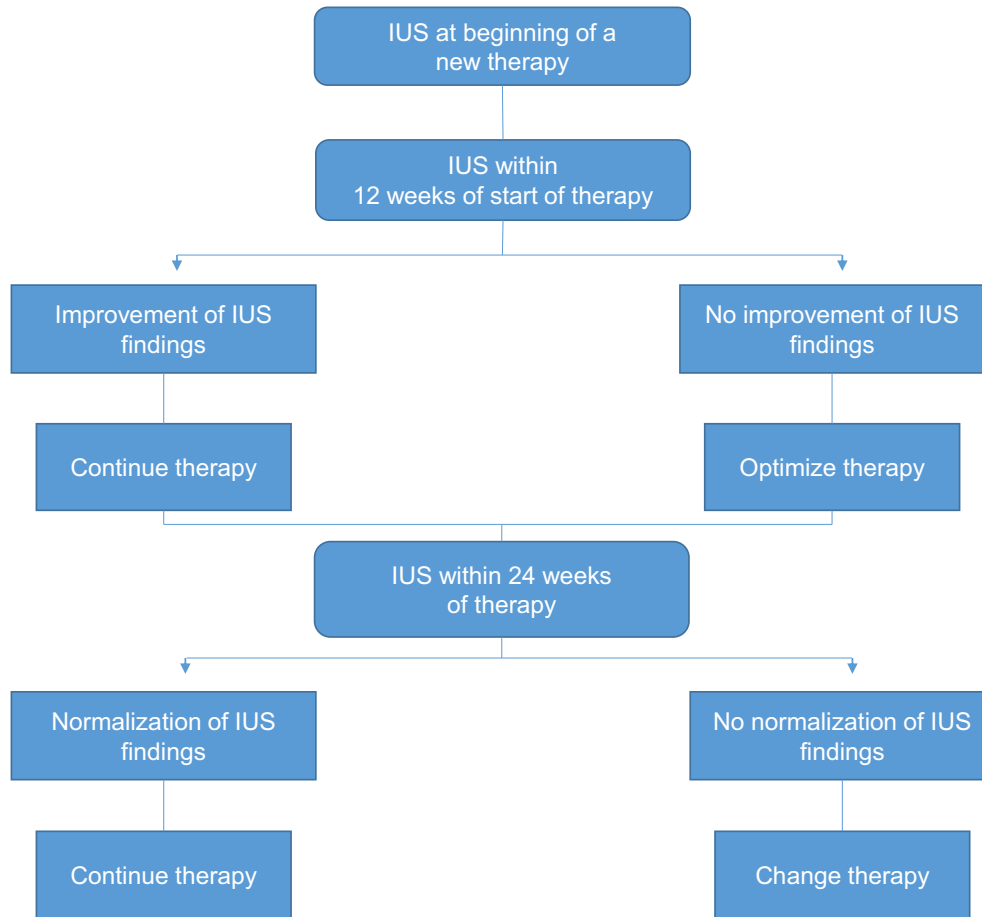
Evidence as well as expertise on the use of IUS in CD as well as UC show a steep increase within the last years and have become an integral part of monitoring IBD patients in IBD centres throughout the world. First interventional multi-centre trials have started to use IUS parameters for secondary endpoints allowing detection of transmural response at much earlier timepoints and more frequent than it would be acceptable for endoscopy. Current evidence and personal experience already suggests the regular use of IUS for close monitoring of IBD patients as outlined in Figure 9. However, interventional trials on the use of IUS to predict treatment response are still required to broadly introduce IUS for follow up of IBD patients and to replace endoscopies in the future.

### CONFLICT OF INTERESTS

Christian Maaser received consulting fees from Abbvie, Arena, Biogen, Dr. Falk Pharma GmbH, Ferring, Galapagos, Gilead, Janssen, MSD Sharp & Dome GmbH, Pfizer, Takeda Pharma GmbH, Vifor. Giovanni Maconi Received consulting fees and/or Advisory Board from Alfa-Sigma, Arena Pharmaceuticals, Fresenius-Kabi, Gilead, Janssen-Cilag, Roche. Torsten Kucharzik received consulting fees

**TABLE 1** Intestinal ultrasound (IUS) parameters

Bowel wall thickness (BWT)	Normal values up to 3 mm, both for colon and ileum. BWT should be measured as the mean of 4 measurements: 2 in longitudinal (at least 1 cm apart) and 2 in transverse section (more than 90° apart), from the interface between the mucosa and the lumen to the interface between the muscle layer and serosa layer (with calipers perpendicular to the wall)
Bowel wall flow (BWF)	0 = no blood flow on colour Doppler imaging; 1 = small, circular intramural vascular signal on colour Doppler imaging; 2 = longer linear intramural vascular signal on colour Doppler imaging; 3 = longer stretches of vascular signal with extension into mesentery on colour Doppler imaging
Bowel wall stratification (BWS)	Defined as normal echostratification (0); focal ( $\leq 3$ cm) disruption (1); extensive ( $> 3$ cm) disruption (2)
Mesenteric inflammatory fat	White hyperechoic zone surrounding the inflamed bowel, classified as: absent (0); present (1)
Mesenteric lymph nodes	Mesenteric lymphadenopathy should be defined as lymph nodes greater than 4.0 mm in short axis diameter that are located in the mesentery adjacent to an affected segment and should be classified as: absent (0); present (1)
Small bowel peristalsis	Small bowel peristalsis should be scored within the context of inflammatory intestinal segment as absent, reduced, present or increased
Colonic haustra coli	Colonic haustra coli should be scored as absent (0); present (1)
Ulcers	Defined as depressions in the mucosal layer
Stricture	Wall thickening with a narrowed lumen with or without a dilatation of a proximal loop
Fistula	Hypoechoic tract with or without hyperechoic content
Abscess	Roundish anechoic lesion with an irregular wall, without signs of blood flow



**FIGURE 9** Suggested algorithm for the use of Intestinal ultrasound(IUS) in guiding inflammatory bowel disease therapy

from Abbvie, Amgen, Arena, Biogen, BMS, Boehringer, Celgene, Celltrion, Hospira, Mundipharma, Dr. Falk Pharma GmbH, Ferring, Galapagos, Gilead, Janssen, MSD Sharp & Dome GmbH, Novartis, Pfizer, Takeda Pharma GmbH, Vifor. Mariangela Allocca received consulting fees from Nikkiso Europe, Mundipharma, Janssen, Abbvie, Ferring and Pfizer.

#### DATA AVAILABILITY STATEMENT

Data sharing not applicable to this article as no datasets were generated or analysed during the current study.

#### ORCID

Maaser Christian  <https://orcid.org/0000-0002-3889-405X>

Kucharzik Torsten  <https://orcid.org/0000-0002-0183-4483>

Allocca Mariangela  <https://orcid.org/0000-0002-7204-1739>

#### REFERENCES

1. Maaser C, Sturm A, Vavricka SR, Kucharzik T, Fiorino G, Annese V, et al. European crohn's and colitis organisation [ECCO] and the European society of gastrointestinal and abdominal radiology [ESGAR]. ECCO-ESGAR guideline for diagnostic assessment in IBD Part 1: initial diagnosis, monitoring of known IBD, detection of complications. *J Crohns Colitis*. 2019;13(2):144–64.
2. Kucharzik T, Wittig BM, Helwig U, Börner N, Rössler A, Rath S, et al. Use of intestinal ultrasound to monitor Crohn's disease activity. *Clin Gastroenterol Hepatol*. 2017;15(4):535–42.
3. Calabrese E, Rispo A, Zorzi F, De Cristofaro E, Testa A, Costantino G, et al. Ultrasonography tight control and monitoring in Crohn's disease during different biological therapies: a multicentre study. *Clin Gastroenterol Hepatol*. 2021;S1542-3565(21):00340–2.
4. Kucharzik T, Wilkens R, Maconi G, D'Agostino M-A, Le Bars M, Lahaye M, et al. Intestinal ultrasound response and transmural healing after 48 weeks of treatment with ustekinumab in Crohn's disease: STARDUST trial substudy. Abstract LB12. *UEG Week Virtual*. 2020;58(05):11–3.
5. Zorzi F, Ghosh S, Chiaramonte C, Lolli E, Ventura M, Onali S, et al. Response assessed by ultrasonography as target of biological treatment for Crohn's disease. *Clin Gastroenterol Hepatol*. 2020;18(9):2030–7.
6. Ripollés T, Paredes JM, Martínez-Pérez MJ, Rimola J, Jauregui-Amezaga A, Bouzas R, et al. Ultrasonographic changes at 12 Weeks of anti-TNF drugs predict 1-year sonographic response and clinical outcome in Crohn's disease: a multicentre study. *Inflamm Bowel Dis*. 2016;22(10):2465–73.
7. Paredes JM, Moreno N, Latorre P, Ripollés T, Martinez MJ, Vizueté J, et al. Clinical impact of sonographic transmural healing after anti-TNF antibody treatment in patients with Crohn's disease. *Dig Dis Sci*. 2019;64(9):2600–6.
8. Castiglione F, Imperatore N, Testa A, De Palma GD, Nardone OM, Pellegrini L, et al. One-year clinical outcomes with biologics in

- Crohn's disease: transmural healing compared with mucosal or no healing. *Aliment Pharmacol Ther.* 2019;49(8):1026–39.
9. Allocca M, Craviotto V, Bonovas S, Furfaro F, Zilli A, Peyrin-Biroulet L, et al. Predictive value of bowel ultrasound in Crohn's disease: a 12-month prospective study. *Clin Gastroenterol Hepatol.* 2021; S1542-3565(21):00463–8.
  10. Castiglione F, Testa A, Rea M, De Palma GD, Diaferia M, Musto D, et al. Transmural healing evaluated by bowel sonography in patients with Crohn's disease on maintenance treatment with biologics. *Inflamm Bowel Dis.* 2013;19(9):1928–34.
  11. Maconi G, Greco MT, Asthana AK. Transperineal ultrasound for perianal fistulas and abscesses - a systematic review and meta-analysis. *Ultraschall der Med.* 2017;38(3):265–72.
  12. Nuernberg D, Saftoiu A, Barreiros AP, Burmester E, Ivan ET, Clevert DA, et al. EFSUMB recommendations for gastrointestinal ultrasound Part 3: endorectal, endoanal and perineal ultrasound. *Ultrasound Int Open.* 2019;5(1):E34–51.
  13. Lavazza A, Maconi G. Transperineal ultrasound for assessment of fistulas and abscesses: a pictorial essay. *J Ultrasound.* 2019;22(2): 241–9.
  14. Panés J, Bouzas R, Chaparro M, García-Sánchez V, Gisbert JP, Martínez de Guereño B, et al. Systematic review: the use of ultrasonography, computed tomography and magnetic resonance imaging for the diagnosis, assessment of activity and abdominal complications of Crohn's disease. *Aliment Pharmacol Ther.* 2011;34(2):125–45.
  15. Kinoshita K, Katsurada T, Nishida M, Omotehara S, Onishi R, Mabe K, et al. Usefulness of transabdominal ultrasonography for assessing ulcerative colitis: a prospective, multicentre study. *J Gastroenterol.* 2019;54(6):521–9.
  16. Allocca M, Filippi E, Costantino A, Bonovas S, Fiorino G, Furfaro F, et al. Milan ultrasound criteria are accurate in assessing disease activity in ulcerative colitis: external validation. *United European Gastroenterol J.* 2021;9(4):438–42.
  17. Goodsall TM, Nguyen TM, Parker CE, Ma C, Andrews JM, Jairath V, et al. Systematic review: gastrointestinal ultrasound scoring indices for inflammatory bowel disease. *J Crohns Colitis.* 2021;15(1):125–42.
  18. De Voogd F, Wilkens R, Gecse K, Allocca M, Novak K, Lu C, et al. A reliability study: strong inter-observer agreement of an expert panel for intestinal ultrasound in ulcerative colitis. *J Crohns Colitis.* 2021;15(8):1284–90.
  19. Maaser C, Petersen F, Helwig U, Fischer I, Roessler A, Rath S, et al. German IBD Study Group and the TRUST&UC study group; German IBD Study Group and TRUST&UC study group. Intestinal ultrasound for monitoring therapeutic response in patients with ulcerative colitis: results from the TRUST&UC study. *Gut.* 2020;69(9):1629–36.
  20. Sagami S, Kobayashi T, Aihara K, Umeda M, Morikubo H, Matsubayashi M, et al. Transperineal ultrasound predicts endoscopic and histological healing in ulcerative colitis. *Aliment Pharmacol Ther.* 2020;51(12):1373–83.
  21. Goodsall TM, Jairath V, Feagan BG, Parker CE, Nguyen TM, Guizzetti L, et al. Standardisation of intestinal ultrasound scoring in clinical trials for luminal Crohn's disease. *Aliment Pharmacol Ther.* 2021;53(8):873–86.
  22. Maconi G, Nylund K, Ripolles T, Calabrese E, Dirks K, Dietrich CF, et al. EFSUMB recommendations and clinical guidelines for intestinal ultrasound (GIUS) in inflammatory bowel diseases. *Ultraschall der Med.* 2018;39(3):304–17.
  23. Calabrese E, Maaser C, Zorzi F, Kannengiesser K, Hanauer SB, Bruining DH, et al. Bowel Ultrasonography in the Management of Crohn's Disease. A Review with Recommendations of an International Panel of Experts. *Inflamm Bowel Dis.* 2016;22(5):1168–83.
  24. Allocca M, Furfaro F, Fiorino G, Peyrin-Biroulet L, Danese S. Point-of-Care Ultrasound in Inflammatory Bowel Disease. *J Crohns Colitis.* 2021;15(1):143–51.
  25. Novak KL, Nylund K, Maaser C, Petersen F, Kucharzik T, Lu C, et al. Expert consensus on optimal acquisition and development of the international bowel ultrasound segmental activity score [IBUS-SAS]: a reliability and inter-rater variability study on intestinal ultrasonography in Crohn's disease. *J Crohns Colitis.* 2021;15(4):609–16.
  26. Allocca M, Fiorino G, Bonovas S, Furfaro F, Gilardi D, Argollo M, et al. Accuracy of humanitas ultrasound criteria in assessing disease activity and severity in ulcerative colitis: a prospective study. *J Crohns Colitis.* 2018;12(12):1385–91.
  27. Vestito A, Marasco G, Maconi G, Festi D, Bazzoli F, Zagari RM. Role of Ultrasound Elastography in the Detection of Fibrotic Bowel Strictures in Patients with Crohn's Disease: Systematic Review and Meta-Analysis. *Ultraschall Med.* 2019;40(5):646–54.
  28. Allocca M, Fiorino G, Bonifacio C, Peyrin-Biroulet L, Danese S. Noninvasive Multimodal Methods to Differentiate Inflamed vs Fibrotic Strictures in Patients With Crohn's Disease. *Clin Gastroenterol Hepatol.* 2019;17(12):2397–415.
  29. Wilkens R, Hagemann-Madsen RH, Peters DA, Nielsen AH, Nørager CB, Glerup H, et al. Validity of Contrast-enhanced Ultrasonography and Dynamic Contrast-enhanced MR Enterography in the Assessment of Transmural Activity and Fibrosis in Crohn's Disease. *J Crohns Colitis.* 2018;12(1):48–56.
  30. Ferretti F, Cannatelli R, Ardizzone S, Maier JA, Maconi G. Ultrasonographic Evaluation of Intestinal Fibrosis and Inflammation in Crohn's Disease. The State of the Art. *Front Pharmacol.* 2021;12: 679924.

**How to cite this article:** Christian M, Giovanni M, Torsten K, Mariangela A. Ultrasonography in inflammatory bowel disease – So far we are? *United European Gastroenterol J.* 2022;10(2):225–32. <https://doi.org/10.1002/ueg2.12196>