

Are dental implants the first option in case of severely compromised teeth associated with radicular cyst? A critical case report

► **C. MAIORANA¹, P. P. POLI², F. SIGNORINO³, L. RUNZA⁴, M. BERETTA⁵**

Implant Center for Edentulism and Jawbone Atrophies, Maxillofacial Surgery and Odontostomatology Unit, Fondazione IRCCS Cà Granda Ospedale Maggiore Policlinico, University of Milan, Milan, Italy

¹MD, DDS, MSc. Full Professor and Chairman

²DDS, MSc, PhD. Research assistant

³DDS, MSc. Attending physician

⁴MD. Pathologist. Division of Pathology, Fondazione IRCCS Cà Granda Ospedale Maggiore Policlinico, Milan, Italy

⁵DDS, MSc, PhD. Clinical assistant professor

TO CITE THIS ARTICLE

Maiorana C, Poli PP, Signorino F, Runza L, Beretta M. Are dental implants the first option in case of severely compromised teeth associated with radicular cyst? A critical case report. *J Osseointegr* 2020;12(2):177-180.

DOI 10.23805 /JO.2020.12.02.16

ABSTRACT

Background Nowadays, dental implants are frequently used to replace teeth judged as hopeless, even if other treatments should be primarily considered to save them. The reason lies in the fact that extracting a tooth and placing an implant is erroneously considered by many to be easier, faster, and more predictable. This trend of reduced willingness to save compromised teeth is strengthened by the concomitant presence of periapical tooth pathologies, such as radicular cyst. In such cases, affected teeth are condemned prematurely in favour of implant rehabilitations. This case report aims to illustrate a case where compromised teeth were maintained following the enucleation of a radicular cyst,

Case report After enucleation of the radicular cyst, retrograde endodontic treatment of the affected teeth was performed. The residual bone defect was then treated with guided bone regeneration to assist and promote healing and improve the prognosis of adjacent teeth.

Conclusion The technique proved to be effective and, most importantly, biologically friendly.

KEYWORDS Bone augmentation; Bone defect; Radicular cyst; Oral pathology; Oral surgery.

INTRODUCTION

Although diagnostic and surgical procedures have evolved, radicular cyst still represents the most frequent odontogenic cyst observed in the tooth-bearing area. A meticulous clinical and radiological assessment, together with a local and systemic medical history, should address the clinician to the ideal treatment plan. The main parameters to consider include the size, localization, and the radiographic aspects of the lesion and its border, the relationship with adjacent teeth responsive or not to vitality tests, the onset time, the age of the patient, and eventually the evolution of the lesion from the comparison with previous radiographic exams. Once planned the correct conservative or surgical treatment, the clinician must evaluate the possibility to maintain or extract the tooth connected to the lesion. When extraction is indicated, after the lesion enucleation and bone defect healing, dental implant placement could be an option to rehabilitate the missing tooth. Despite dental implants are considered a reliable and predictable solution, implant treatment is an invasive procedure and generally it is not the only option available.

CASE REPORT

In view of the above, the aim of the present letter was to report a case where compromised teeth were maintained following the enucleation of a radicular cyst, associated with retrograde endodontic treatment of the affected teeth and bone regeneration of the residual defect. A 46-year-old female patient presented to the authors' attention referring a swelling in the interforaminal region. The medical history was non-contributory. The peri-apical radiograph showed endodontically treated

lower central incisors surrounded by a radiolucent lesion localized in close proximity with the apex of the teeth (Fig. 1A). From the computed-tomography scans it was possible to appreciate the complete resorption of the buccal cortical plate and the extension of the lesion being approximately 15 mm mesio-distally and 10 mm apico-coronally (Fig. 1B, 1C). The intraoral clinical examination revealed a tumefaction deep in a redness vestibular fornix below the mucogingival junction. A fine needle-aspiration of the lesion revealed straw-

coloured fluid, rich in cholesterol crystals, typical of cystic fluid. Pulp vitality test of the two central incisors was negative, while both lateral incisors were vital. The clinical and radiological findings led to a diagnostic hypothesis of radicular inflammatory cyst. Two weeks before surgery, the patient underwent professional oral hygiene session and received home oral healthcare instructions. One day before the appointed surgical procedure, the patient was given antibiotic therapy consisting of amoxicillin clavulanate 1 g twice

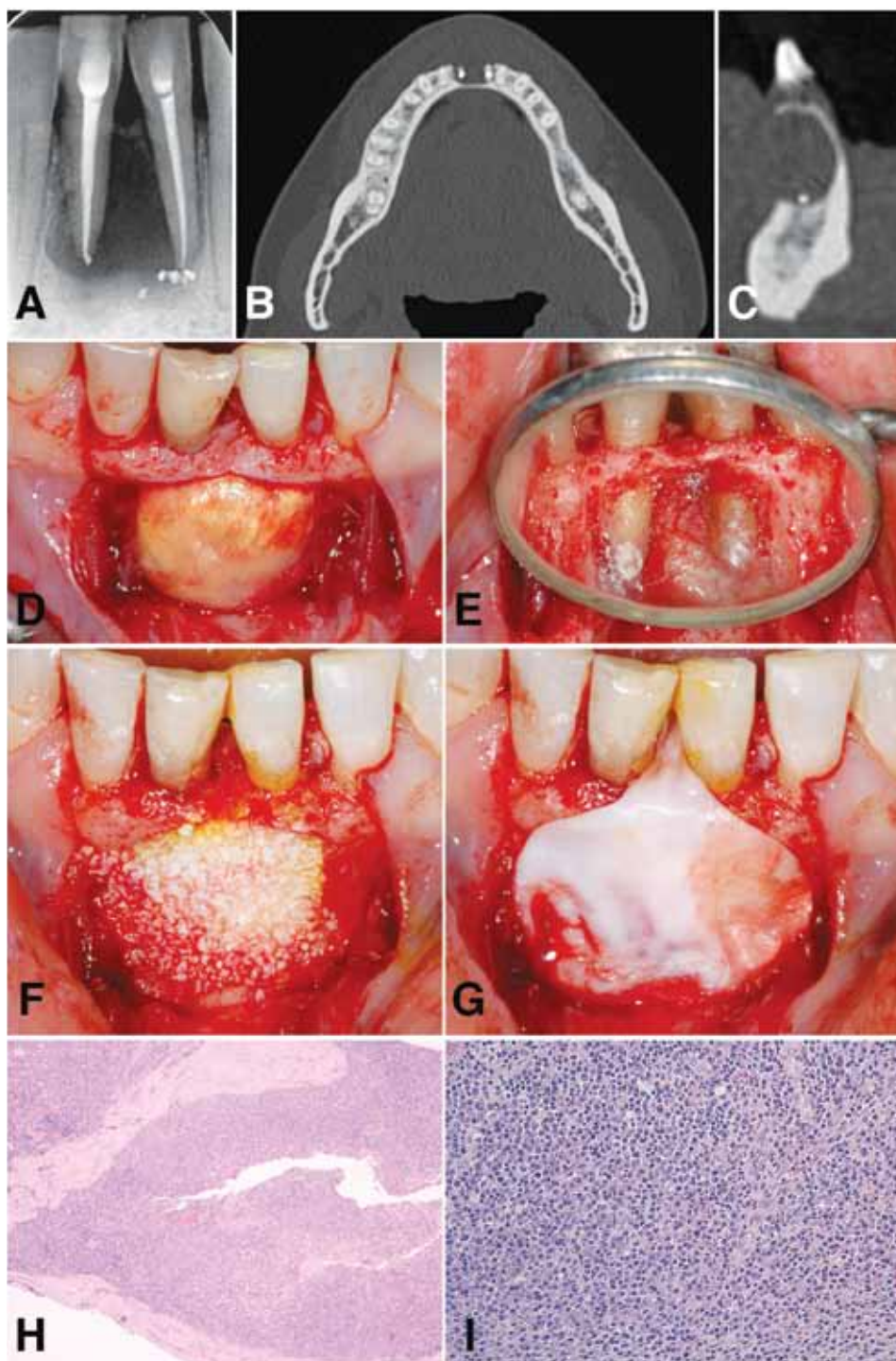


FIG. 1

A: Peri-apical radiograph of the mandibular central incisors showing a radiolucent area.
 B-C: Axial and sagittal view of the lesion showing complete resorption of the buccal cortical plate.
 D: Intraoral frontal view of the lesion.
 E: Lingual view of the retrograde cavity preparation sealed with Super-EBA.
 F: Deproteinized bovine bone mineral grafted to fill the bone defect.
 H: Bioabsorbable collagen membrane covering the grafting material.
 H-I: Histopathological microscopic view of the lesion characterized by a cystic wall coated with non-keratinized stratified squamous epithelium delimiting a stroma containing inflammatory infiltrate including plasma cells, histiocytes, granulocytes, and fibrotic tissue (Hematoxylin and eosin staining, magnification 20x and 40x respectively).

daily for six days. In the immediate pre-operative phase, the patient was instructed to rinse with 0.2% chlorhexidine digluconate for 1 min, and a perioral skin antiseptics was accomplished with benzalkonium chloride. The surgical procedure was performed under local anesthesia with mepivacaine hydrochloride 20 mg/ml with epinephrine 1:100.000. Paramarginal and vertical releasing incisions were made to elevate a full-thickness flap and expose the lesion (Fig. 1D). The cystic membrane was carefully detached from the inner portion of the flap, the surrounding bone, and the roots of the involved teeth, and the lesion was finally enucleated in toto. The resultant bone defect was rinsed vigorously with sterile 0.9% sodium chloride solution. At this point, the affected teeth underwent apicoectomy and endodontic canal treatment by means of retrograde cavity preparation with ultrasonic tips sealed with zinc oxide eugenol cement reinforced with ethoxy-benzoic acid (Super-EBA, Harry J. Bosworth Co., Skokie, IL, USA) (Fig. 1E). A regenerative approach was carried out in accordance with GBR principles to promote bone healing. In brief, the bone defect was filled with pre-hydrated deproteinized bovine bone mineral particles (Bio-Oss®, Geistlich AG, Wolhusen, Switzerland) (Fig. 1F), and a resorbable collagen membrane (Bio-Gide®, Geistlich AG, Wolhusen, Switzerland), shaped according to the surgical anatomy, was laid over the graft (Fig. 1G). Primary wound healing was obtained using resorbable 5-0 sutures (Safil®, B. Braun® Aesculap, Milan, Italy). In addition to the antibiotic therapy, medication prescribed for post-operative use by the patient included 600 mg ibuprofen twice daily for 2-3 days according to individual needs, and 0.2% chlorhexidine digluconate 15 ml mouthwash rinsing for 1 min 3 times daily up to suture removal, starting the day after the surgery.

The sutures were removed after 14 postoperative days. Histopathological microscopic examination of the excised lesion confirmed the diagnosis of radicular cyst of inflammatory origin (Fig. 1H, 1I).

The postoperative period was uneventful. During routine clinical and radiological examinations conducted every 6 months, neither complications nor recurrence of the lesion were observed. Clinical and radiological evaluations were performed after 12 months (Fig. 2A, 2B) and 7 years (Fig. 2C, 2D) from the surgical session. From both aspects, hard and soft tissues were healthy, the retrograde seals of the central incisors were adequate, and no signs of recurrence were noted. The intense radiopacity of the bone indicated good quality of the remodelled hard tissue. To conclude, the procedure was biologically friendly, effective, and promoted the regeneration of newly formed bone around the roots of the central incisors that were still in situ after 7 years.

Although implant dentistry may have represented an alternative solution, the treatment proposed herein allowed the maintenance of both natural teeth, which in turn led to high patient satisfaction from aesthetic, biological, and functional aspects.

This is noteworthy considering in today's dental implant era where implants are not supposed to replace natural teeth, but missing teeth.

DISCUSSION

When clinical and/or radiographic assessments together with vitality tests suggest a dental inflammatory origin of an osteolytic lesion, a correct endodontic treatment should be associated to the surgical phase. If the size of

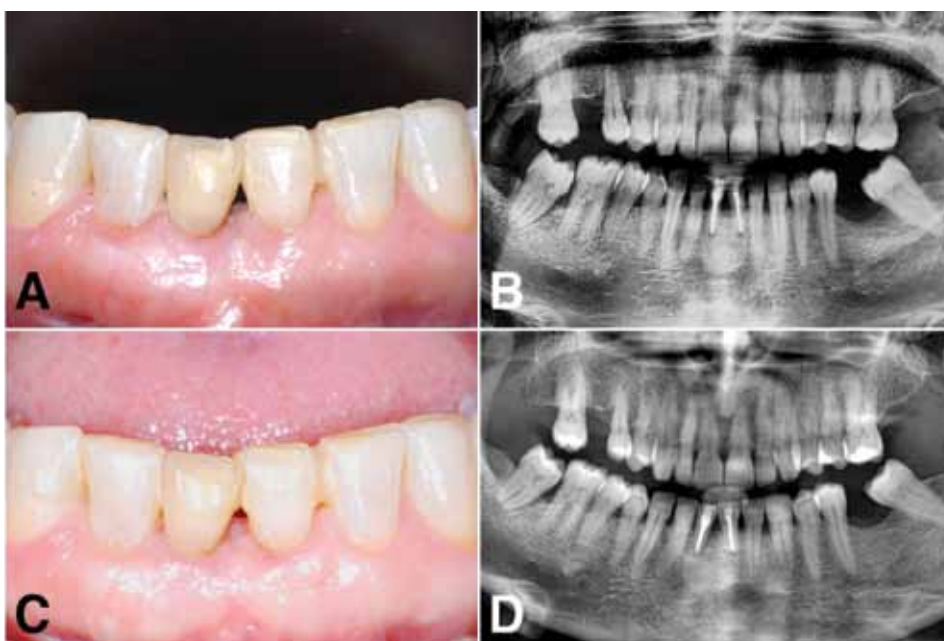

FIG. 2

A-B: Clinical and radiographic evaluation at the 1-year follow-up.

C-D: Clinical and radiographic evaluation at the 7-year follow-up.

the lesion is limited, the sole endodontic treatment may be resolutive. However, when the surgical intervention is required, apicoectomy and retrograde root canal treatment should be performed. The surgical plan ought to be aimed at the removal of the lesion with a one-step procedure when possible. Alternatively, the size of the lesion may be reduced with a preliminary marsupialization. Once the lesion is removed, the surgeon has to face the resultant bone defect, particularly if the lesion induced a significant resorption of the cortical plate.

The usefulness of a regenerative approach remains a controversial issue. Guided bone regeneration (GBR) technique has been originally applied in critical-size maxillary and mandibular animal bone defects with successful results (1,2). GBR principles have been applied also in the treatment of bone defects after removal of maxillary and mandibular cysts showing satisfactory results in humans (3-5).

On the other hand, a randomized clinical trial showed no statistically significant differences between GBR and non-GBR groups in terms of bone ingrowth after enucleation of radicular cysts, regardless the age of the patients, the type of affected teeth, the size of the buccal bone window and the type of dental treatment (6).

CONCLUSION

The outcome of the present case report shows that,

despite implant treatment is considered easy, fast, and predictable, the technique described proved to be effective and, most importantly, biologically friendly.

Authors contribution

CM designed the study and performed the surgery, MB managed the patient clinical phase, PPP edited text and photographs, FS edited text and coordinated the team, LR performed the histological analysis.

Conflict of interest

The authors declare no conflict of interest

REFERENCES

1. Dahlin C, Linde A, Gottlow J, et al. Healing of bone defects by guided tissue regeneration. *Plast Reconstr Surg* 1988;81:672-6.
2. Dahlin C, Gottlow J, Linde A, et al. Healing of maxillary and mandibular bone defects using a membrane technique. An experimental study in monkeys. *Scand J Plast Reconstr Surg Hand Surg* 1990;24:13-9.
3. Pradel W, Eckelt U, Lauer G. Bone regeneration after enucleation of mandibular cysts: comparing autogenous grafts from tissue-engineered bone and iliac bone. *Oral Surg Oral Med Oral Pathol Oral Radiol Endod* 2006;101:285-90.
4. Stoor P, Apajalahti S, Kontio R. Regeneration of Cystic Bone Cavities and Bone Defects With Bioactive Glass S53P4 in the Upper and Lower Jaws. *J Craniofac Surg* 2017;28:1197-205.
5. AboulHosn M, Noujeim Z, Nader N, et al. Decompression and Enucleation of a Mandibular Radicular Cyst, Followed by Bone Regeneration and Implant-Supported Dental Restoration. *Case Rep Dent* 2019;2019:9584235.
6. Santamaria J, Garcia AM, de Vicente JC, et al. Bone regeneration after radicular cyst removal with and without guided bone regeneration. *Int J Oral Maxillofac Surg* 1998;27:118-20.