

A 14-year multicentric follow-up study of atypical pemphigus variants in Italy: the VARIANT_P study

Lavinia Quintarelli¹, Irene Bonanni¹, Elena Biancamaria Mariotti¹, Laura Atzori², Clara De Simone³, Camilla Vassallo⁴, Giovanni Di Zenzo⁵, Stefano Caccavale⁶, Emanuele Cozzani⁷, Gianpiero Girolomoni⁸, Angelo Valerio Marzano⁹, Andrea Conti¹⁰, Pamela Vezzoli¹¹, Giovanni Damiani¹², Vito Di Lernia¹³, Riccardo Balestri¹⁴, Roberto Maglie¹⁵, Alberto Corrà¹, Alessandro Magnatta¹⁵, Marta Donati¹³, Valentina Ruffo di Calabria¹⁵, Alice Verdelli¹, Alessio Coi¹⁶, Emiliano Antiga¹⁵ and Marzia Caproni¹

¹Rare Skin Diseases Unit, Section of Dermatology, Department of Health Sciences, ERN-SKIN Member, University of Florence, Florence, Italy

²Dermatology Unit, Department Medical Sciences and Public Health, University of Cagliari, Cagliari, Italy

³Dermatology Unit, Fondazione Policlinico Universitario Agostino Gemelli IRCCS, Rome, Italy

⁴Institute of Dermatology, Fondazione IRCCS Policlinico San Matteo, Pavia, Italy

⁵Molecular and Cell Biology Laboratory, Istituto Dermopatico dell'Immacolata (IDI)-IRCCS, Rome, Italy

⁶Unit of Dermatology, University of Campania Luigi Vanvitelli, Naples, Italy

⁷Section of Dermatology, Department of Health Sciences (DISSAL), University of Genoa, IRCCS Ospedale Policlinico San Martino, Genoa, Italy

⁸Section of Dermatology and Venereology, Department of Medicine, University of Verona, Verona, Italy

⁹Dermatology Unit, Fondazione IRCCS Ca' Granda Ospedale Maggiore Policlinico, Milan, Italy

¹⁰Dermatologic Unit, Department of Surgery, Infermi Hospital of Rimini, auSL Romagna, Rimini, Italy

¹¹Dermatology Unit, ASST Papa Giovanni XXIII, Bergamo, Italy

¹²Clinical Dermatology, IRCCS Istituto Ortopedico Galeazzi-Sant'Ambrogio, Milan, Italy

¹³Dermatology Unit, Arcispedale Santa Maria Nuova, Azienda USL-IRCCS di Reggio Emilia, Reggio Emilia, Italy

¹⁴Division of Dermatology, Outpatient Consultation for Rare Diseases, APSS, Trento, Italy

¹⁵Section of Dermatology, Department of Health Sciences, University of Florence, Florence, Italy

¹⁶Institute of Clinical Physiology, National Research Council, Pisa, Italy

Correspondence: Marzia Caproni. Email: marzia.caproni@unifi.it

L.Q. and I.B. share first authorship.

Abstract

Background The clinical, epidemiological and immunopathological profiles of atypical forms of pemphigus remain only partially known.

Objectives To define the clinical, epidemiological and immunological characteristics, therapies and outcomes in patients with atypical pemphigus variants.

Methods This was a 14-year multicentre retrospective observational study (VARIANT_P) on atypical variants of pemphigus across Italy. We collected demographic, immunopathological and clinical data, as well as information on comorbidities and prescribed treatments.

Results We enrolled 61 patients [female/male sex ratio 1.77; 13 paraneoplastic pemphigus (PNP), 26 IgA pemphigus (PIgA), 22 pemphigus herpetiformis (PH)]. The median ages at onset and diagnosis were 70.6 (range 43.1–86.8) and 71.1 (range 46.9–86.9) for PNP; 62.2 (range 3.8–81.0) and 63.6 (range 4.0–82.4) for PIgA; and 49.4 (range 5.4–84.4) and 52.3 (range 5.9–85.9) for PH, respectively. The median diagnostic delay was 3.0 (range 0.0–45.6) months for PNP, 9.5 (range 1.0–140.0) months for PIgA and 2.0 (range 0–30.4) months for PH. The mortality rate was 55% (6/11) for PNP, 4% (1/26) for PIgA and 6% (1/17) for PH. Cutaneous involvement was present in all patients with PIgA and PH, and in 83% (10/12) of the patients with PNP. In contrast, oral mucosal involvement was observed in all patients with PNP with data ($n=12$), but only in 8% (2/26) of those with PIgA and 21% (4/19) of those with PH. Histology, direct immunofluorescence, indirect immunofluorescence and enzyme-linked immunosorbent assay data demonstrated variable concordance with previously known data. Comorbidities included mainly solid malignancies for people with PNP, whereas cardiovascular and metabolic diseases were the most prevalent for those with PIgA and PH. Treatment mostly relied on systemic steroids and rituximab.

Conclusions The VARIANT_P study contributes to data collection relating to atypical pemphigus variants in order to promote the development of specific therapeutical guidelines in the future.

Accepted: 2 October 2025

© The Author(s) 2025. Published by Oxford University Press on behalf of British Association of Dermatologists. This is an Open Access article distributed under the terms of the Creative Commons Attribution License (<https://creativecommons.org/licenses/by/4.0/>), which permits unrestricted reuse, distribution, and reproduction in any medium, provided the original work is properly cited.

What is already known about this topic?

- Although the clinical, epidemiological and pathogenic profiles of classical pemphigus variants are well characterized, less is known about atypical forms.

What does this study add?

- This is the first multicentric study, to our knowledge, to collect demographic, pathological, clinical, comorbidity and treatment data about atypical pemphigus variants.

Pemphigus is a rare life-threatening autoimmune blistering disorder characterized by the production of autoantibodies against desmosomes, critical adhesion structures in the epidermis, leading to acantholysis. Besides the more common forms, pemphigus vulgaris (PV) and pemphigus foliaceus (PF),^{1–10} other rarer entities collectively known as atypical variants are included in this group, namely paraneoplastic pemphigus (PNP), IgA pemphigus (PIgA) and pemphigus herpetiformis (PH).

PNP typically occurs in adults, although younger people may also be affected.^{1,11,12} Owing to its multiple pathogenetic mechanisms, it exhibits a wide range of targets.^{13–24} As its name suggests, it is believed to present almost invariably in patients with haematological or, less frequently, solid tumours;^{25,26} however, patients with cases not associated with underlying malignancies have also been reported.^{27,28} PNP is described as following an aggressive clinical course, including severe mucositis, extensive skin involvement and internal complications such as bronchiolitis obliterans (Figure 1).^{28–42} The complexity of the clinical features, combined with frequent resistance to treatments, usually results in a high mortality rate and poor prognosis.^{25,43,44}

PIgA belongs to the superficial neutrophilic dermatoses group, a heterogeneous group of inflammatory skin disorders characterized by neutrophilic skin infiltrate. Although lacking precise epidemiological data,^{45–49} PIgA is thought to follow a milder clinical course than IgG-mediated pemphigus,⁵⁰ with predominantly cutaneous lesions that heal without scarring (Figure 2a).^{50–53} It is reported in association with several disorders, most notably chronic inflammatory bowel diseases, along with monoclonal IgA-associated malignancies, including Waldenström disease and IgA-type multiple myeloma.^{53–60}

PH combines the clinical features of dermatitis herpetiformis with the immunopathological characteristics of pemphigus, resulting in pruritic cutaneous lesions and infrequent oral mucosa involvement (Figure 2b, c). As with other atypical variants, most cases of PH occur in adults, although paediatric cases have been sporadically reported.^{61–73} Whereas desmoglein 1 (Dsg-1) is the main immunological target, Dsg-negative PH is thought to involve autoantibodies against desmocollins (Dsc), specifically Dsc-1 and Dsc-3.^{74–78} Ultraviolet radiation and certain drugs are possible triggers,^{78–83} along with an association with malignancies, other autoimmune diseases and infections.^{51,65,72,84–102} PH has been described as having a milder clinical course and more favourable prognosis compared with other pemphigus variants; however, patients who have transitioned from PH to classical forms have been reported.^{47,86,89,103}

The clinical, epidemiological and pathogenic profiles of classical variants are well characterized; however, the atypical forms remain far less known. Owing to the scarce number of studies in the literature, an observational retrospective multicentric study was undertaken to define the clinical, epidemiological and immunological characteristics, as well as therapeutic management and outcome, of a cohort of patients diagnosed with atypical pemphigus variants in Italy.

Patients and methods

Patients

In total, 61 patients affected by atypical pemphigus variants were selected from 14 referral centres all over Italy from 2010 to 2024.

Inclusion and exclusion criteria

Patients with PNP were selected based on the diagnostic criteria outlined in the 2023 European Academy of Dermatology and Venereology (EADV) guidelines for PNP.¹⁰⁴ Diagnoses of PH and PIgA were confirmed through a comprehensive evaluation integrating clinical presentation, histopathology and immunopathological findings, including direct immunofluorescence (DIF), indirect immunofluorescence (IIF) and enzyme-linked immunosorbent assay (ELISA) tests, in accordance with standard diagnostic protocols. Tissue samples for DIF were obtained from perilesional skin or mucosa, while IIF and ELISA tests were performed on blood samples collected at diagnosis using commercially available kits (Figure 3).

Immunoblotting was only conducted on some patients' samples at the Immunopathology Laboratory of the University of Florence, serving as the coordinating centre, and at the Istituto Dermatologico dell'Immacolata in Rome. Participant enrolment was carried out following informed consent approval. Inclusion criteria were extended to encompass patients with atypical variants who were unavailable at the time of enrolment (for example, patients who were deceased), upon consent provided by their families.

In line with clinical practice, each patient underwent appropriate follow-up at their reference centre, consisting of quarterly clinical monitoring and 6-monthly blood sampling to assess autoantibody titres. Patients whose diagnosis of an atypical pemphigus variant could not be confirmed by the abovementioned criteria were excluded from the analysis.

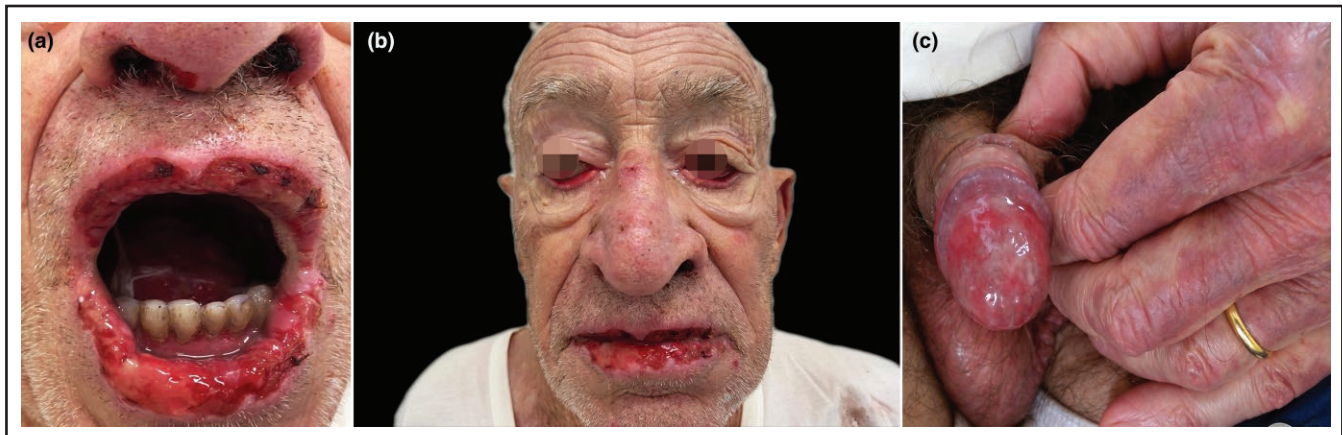

Figure 1 Clinical manifestations of paraneoplastic pemphigus. (a) Severe mucositis of labial mucosa, gingiva and nose. (b) Multiple severe mucosal involvement of the conjunctiva, nose, oral cavity and perioral area. (c) Erosions on penis mucosa and lichenoid-like skin lesions.

Demographic and clinical characteristics of the patients

Demographic data included date of birth, sex, age at disease onset, age at diagnosis and, when applicable, date and cause of death. Pathological characteristics comprised the dates of disease onset and diagnosis, the interval between these events, and time to remission, expressed in months. Clinical features were recorded based on cutaneous and mucosal involvement, with specification of the affected sites. Disease severity was assessed using the Pemphigus Disease Area Index.

Comorbidity and pharmaceutical prescriptions

Comorbidities were categorized according to the affected part of the body (e.g. cardiovascular disease, pulmonary disease). For patients with PNP, comorbidities were assessed in terms of associated malignancy, detailing their type and onset. Administered treatments were categorized into topical and systemic.

Statistical analysis

Data were analysed descriptively using Stata software (version 16).¹⁰⁵ In all analyses, a two-sided P value < 0.05 was considered statistically significant.¹⁰² Demographic, pathological and clinical characteristics were retrieved. Histological data included acantholysis, vacuolar degeneration, eosinophilic spongiosis, cell necrosis and cell infiltrate (lymphocytic, eosinophilic or neutrophilic). For DIF examinations, parameters included intercellular, junctional or mixed intracellular-junctional deposits, exclusive deposits of IgG, IgA, C3 and mixed ones (C3-IgA or IgG-IgA). IIF test data included the substrate used and the antibody class involved (IgA or IgG). Exclusive or combined positivity with antibodies targeting Dsg-1 and -3 was analysed by ELISA. For patients with PNP, additional markers such as BP180, BP230 and envoplakin were considered.

Treatments included topical steroids or systemic therapies [steroids, immunosuppressants, rituximab, dapsone, acitretin, colchicine and intravenous immunoglobulin (IVIg)]. For PlgA and PH, the study also evaluated the potential for

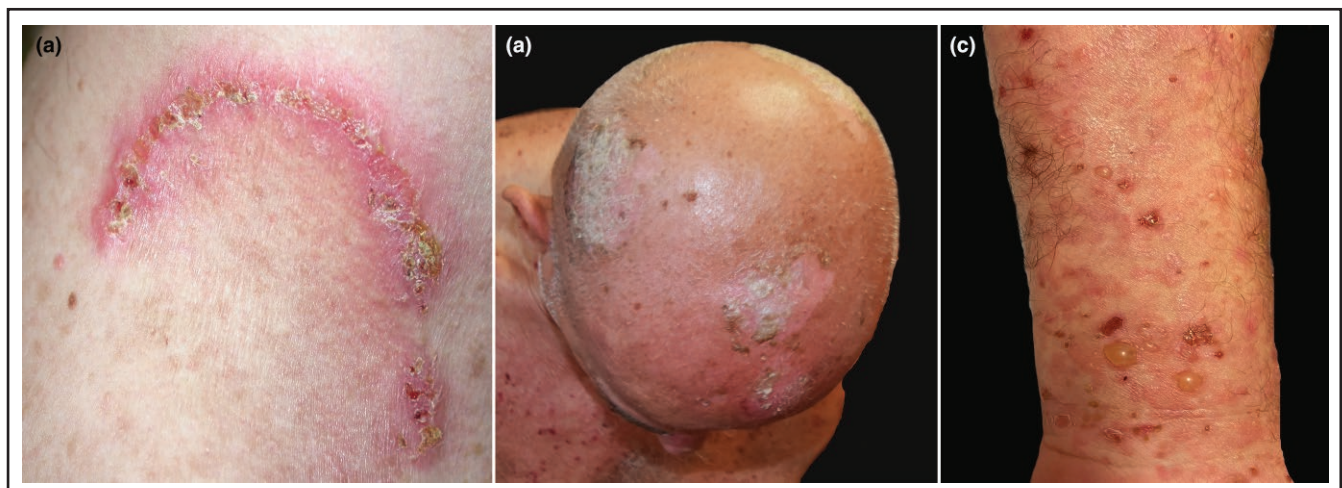


Figure 2 (a) Arc-shaped skin lesions in patients with IgA pemphigus localized on the dorsal region. (b) Crusted lesions on the scalp and the trunk in a patient with pemphigus herpetiformis (PH). (c) Multiple tiny intraepidermal blisters on an erythematous background localized on the arm in a patient with PH.

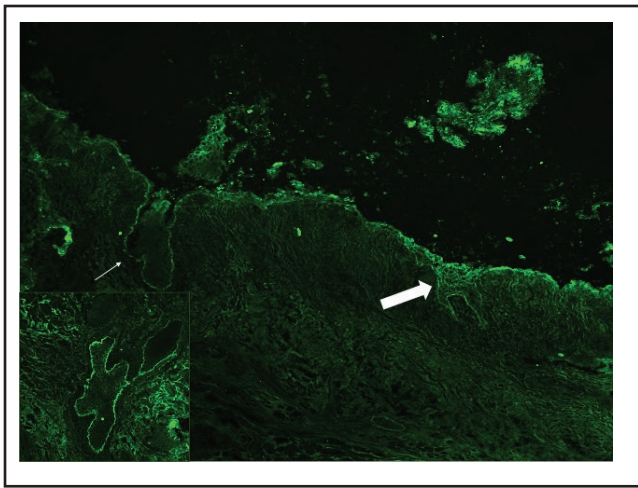


Figure 3 Immunofluorescence ($\times 10$) in a patient with paraneoplastic pemphigus showing both intercellular (thick arrow) and junctional deposits (thin arrow). Detail ($\times 20$) in the lower-left corner.

combined systemic steroids–dapsone treatment to reduce the average time to remission, and the time to remission related to exclusive steroid-based therapy. Differences in demographic and clinical features were evaluated in each subgroup using Fisher’s exact test for categorical variables. A Student’s *t*-test was used to evaluate the eventual association between combined systemic steroids–dapsone treatment and reduction of time to remission.

Results

Demographic and clinical characteristics

Collectively, 61 patients were selected; specifically, 13 patients were diagnosed with PNP, 26 with PlgA and 22 with PH (Table 1). Female patients were the most prevalent sex, comprising 39 of 61 patients (64%) compared with 22 male patients (36%), with an overall sex ratio of 1.77.

Laboratory findings

Laboratory findings are summarized in Table 2 and Figure 4. In patients with PNP, IIF consistently demonstrated IgG reactivity on rat bladder epithelium and only one patient also exhibited IgG positivity on both monkey oesophagus and salt-split skin (SSS) substrates. Within the PlgA group, IIF identified IgA deposits in 40% (4/10) of patients on monkey oesophagus and in 20% (2/10) on SSS. Among patients with PH, IgG was detected in eight patients on monkey oesophagus, in three on SSS and in one on both substrates. Owing to limited availability of specific antigen panels in our centre, antibodies such as anti-Dsc and antiperiplakin were not routinely assessed.

Immunoblotting was performed in a small subset of patients ($n=9$) exclusively for research purposes, and not as part of standard diagnostic evaluation. In four patients with PNP, it revealed reactivity against desmoplakin 1 and 2 ($n=3$), Dsg-1 and -3 ($n=1$) and alpha-2-macroglobulin-like protein 1 ($n=1$). In patients with PlgA, immunoblotting was

performed in four patients, demonstrating exclusive IgA reactivity in three and concurrent IgA and IgG positivity in one. In the patients with PH, immunoblotting was performed in a single case, yielding positivity for desmoplakin 1, envoplakin and periplakin.

Comorbidity

PNP-associated neoplasms included both haematological and solid tumours. Haematological malignancies comprised non-Hodgkin lymphoma ($n=3$), chronic lymphocytic leukaemia ($n=2$), and Castleman disease ($n=1$). Solid tumours included breast cancer ($n=3$), lung cancer ($n=2$) and single patients with melanoma, rectal carcinoma, Kaposi sarcoma, urothelial carcinoma and pancreatic cancer. Comorbidity data for PlgA and PH are summarized in Table 3.

Treatment

The great majority of the patients received both systemic and topical steroids. Regarding PNP, treatment was applied according to 2023 EADV guidelines for PNP.¹⁰⁴

The time-to-remission calculations did not yield meaningful results owing to the small sample size. For PlgA, combination therapy with systemic steroids and dapsone was administered in 35% (9/26) of patients, with no significant improvement in time to remission compared with the global median value of 19.3 months [interquartile range (IQR) 3.0–60.8, $P=0.68$]. Perhaps because of the small cohort, combined therapy in these nine patients did not significantly shorten time to remission compared with systemic steroids alone ($P=0.33$).

There was also no improvement in time to remission in patients with PH treated with combined therapy compared with the median time to remission (12.2 months, IQR 6.0–26.9, $P=0.54$). A direct comparison of time to remission between patients treated solely with systemic steroids and those receiving combination therapy was not performed owing to the small sample size. Treatment data are summarized in Table 1.

Discussion

To date, to the best of our knowledge, atypical variants of pemphigus have only been analysed in terms of their prevalence within the broader pemphigus population. For instance, in a recent study from our group, atypical variants accounted for 4% of 149 patients with pemphigus, including three patients each with PlgA and PNP.¹⁰⁶ Collectively, female patients predominated both overall and within single subtypes. As expected, disease onset at a young age is quite rare, with only three patients’ cases reported (one of PH and two of PlgA).^{1,84,85,107} Regarding therapies, the 2020 EADV guidelines on classical pemphigus variants introduced rituximab as a first-line treatment for classic forms.^{108,109} As a result of the publication of these guidelines and the mixed perspective–retrospective character of our series, rituximab was mainly used in those patients with severe/recalcitrant–relapsing disease, rather than as a first-line drug.

Looking first at our findings in the PNP group, the mean age of onset in the current study aligns with the literature,^{28,110}

Table 1 Baseline characteristics, clinical features and treatments of atypical variants

Baseline characteristics	Paraneoplastic pemphigus group (n = 13)	IgA pemphigus group (n = 26)	Pemphigus herpetiformis group (n = 22)
Female sex	7 (54)	16 (62)	16 (73)
Age at onset (years), median (range)	70.6 (43.1–86.8)	62.2 (3.8–81.0)	49.4 (5.4–84.4)
Age at diagnosis (years), median (range)	71.1 (46.9–86.9)	63.6 (4.0–82.4)	52.3 (5.9–85.9)
Diagnostic delay (months), median (range)	3.0 (0.0–45.6)	9.5 (1.0–140.0)	2.0 (0–30.4)
Mortality rate	6/11 (55)	1/26 (4)	1/17 (6)
Clinical features	12	26	19
Oral mucosa	12 (100)	2 (8)	4 (21)
Other mucosa involved			
Ocular	5 (42)	–	–
Genital	5 (42)	–	–
Pharyngeal/laryngeal	4 (33)	–	–
Digestive tract	2 (17)	–	–
Skin lesions	10 (83)	26 (100)	19 (100)
Skin + mucosa	10 (83)	26 (100)	19 (100)
Treatments	11	26	19
Topical steroids	10 (91)	25 (96)	17 (89)
Systemic steroids	11 (100)	22 (85)	19 (100)
Immunosuppressants	3 (27)	4 (15)	7 (37)
Rituximab	4 (36)	0	2 (11)
IVIg	4 (36)	1 (4)	0
Dapsone	–	9 (35)	4 (21)
Acitretin	–	4 (15)	–
Colchicine	–	2 (8)	–
Systemic steroids + dapsone	–	9 (35)	4 (21)

Data are *n* (%) unless otherwise specified. IVIg, intravenous immunoglobulin.

Table 2 Laboratory findings^a

Parameters	Paraneoplastic pemphigus group (n = 13)	IgA pemphigus group (n = 26)	Pemphigus herpetiformis group (n = 22)
Histology	11 (85) ^b	26 (100)	22 (100)
Acantholysis	4 (40)	14 (54)	16 (73)
Vacuolar degeneration	4 (40)	–	–
Spongiosis	–	5 (19)	12 (55)
Epidermal detachment	5 (50)	–	–
Necrosis	3 (30)	–	–
Bandlike lymphocytic infiltrate	7 (70)	–	–
Eosinophilic infiltrate	–	10 (38)	20 (91)
Neutrophilic infiltrate	–	19 (73)	8 (36)
Lymphocytic infiltrate	–	20 (77)	14 (64)
DIF (patients with positive results)	11 (100)	25 (96)	21 (100)
Exclusive intercellular deposit	6 (55)	20 (80)	19 (90)
Exclusive junctional deposit	3 (27)	1 (4)	0
Mixed intercellular–junctional deposit	2 (18)	4 (16)	2 (10)
IgG only	–	0	2 (10)
IgA only	–	16 (64)	0
C3 only	–	0	0
C3 + IgA	–	9 (36)	2 (10)
IgG + IgA	–	2 (8)	3 (14)
IIF (patients with positive results)	8/9 (89)	6/10 (60)	13/15 (87)
ELISA (patients with positive results)	10/11 (91)	7/24 (29)	16/21 (76)
Dsg-1 only	1 (10)	1 (14)	9 (56)
Dsg-3 only	2 (20)	0	0
Dsg-1 + Dsg-3	6 (60)	6 (86)	7 (44)
BP180 only	0	–	–
BP230 only	0	–	–
Envoplakin only	1 (10)	–	–

Data are *n* (%). BP bullous pemphigoid antigen; Dsg, desmoglein; DIF, direct immunofluorescence; ELISA, enzyme-linked immunosorbent assay; IIF, indirect immunofluorescence. ^aBlank cells indicate parameters that were not calculated for the respective variant, whereas a value of 'zero' denotes that no cases were identified in the analysis. ^bAlthough the total number of patients with positive histology cases is 11, specific data were available for only 10 patients.

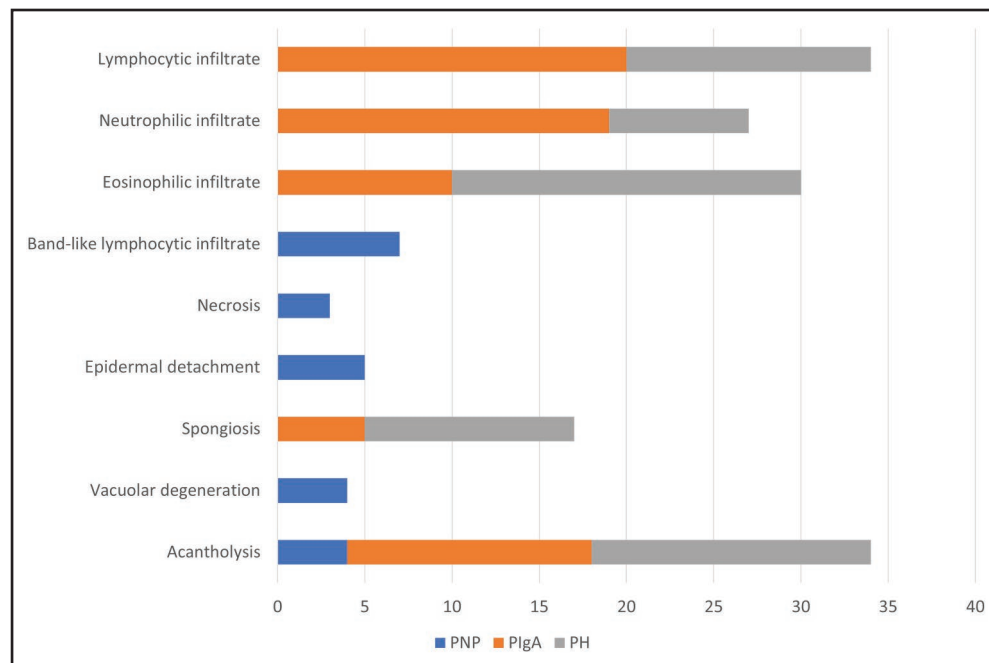


Figure 4 Graphical representation of the histological findings in the study population, stratified by subgroup. In this cohort, acantholysis was prominently represented in IgA pemphigus (PlgA) and pemphigus herpetiformis (PH) and correlated with a bullous phenotype. Necrosis and epidermal detachment were only seen in paraneoplastic pemphigus (PNP).

with the female patient predominance in our series agreeing with a Chinese study but contrasting with a French one (58.5% male patients).^{25,111} According to the literature, PNP was confirmed as the pemphigus variant associated with the poorest prognosis.^{25,44} Oral involvement was present in all patients with PNP, with the tongue being the main site of the erosions, followed by the lips and vermillion, resulting in extremely painful lesions and severe functional impairment. Consistent with the literature, the oral cavity is often one of the earliest sites of disease manifestation, and in some patients it may be the only one, with other mucosal areas becoming involved at a later stage.¹¹² In our series, patients with PNP showed a predominance of multiple mucosal involvement, with seven patients vs. five with exclusive oral involvement. The early presentation and marked severity of oral lesions underscore the need to consider PNP in the differential diagnosis and support a multidisciplinary diagnostic strategy. All patients had an associated neoplasm, and in line with some reports in the literature, solid tumours were more prevalent than haematological ones.^{113,114}

On histology our patients with PNP reported 40% (4/10) acantholysis and 30% (3/10) necrosis, whereas a recent review reported higher percentages (57% and 46%, respectively).²⁸ Aligning with most of the reviews, our patients with PNP exhibited intercellular deposits on DIF (55%, 6/11), followed by junctional (27%, 3/11) and mixed intercellular–junctional ones (18%, 2/11).^{104,115} Although mixed deposits have a specificity of 97% for the diagnosis of PNP, their sensitivity is relatively low, as this pattern is observed in fewer than half of the patients.^{112,115–117}

Among the substrates used for IIF, rat bladder proved the highest sensibility, showing positivity in 88% (7/8) of patients with PNP,^{104,118} whereas monkey oesophagus and SSS were positive in 25% (2/8) and 38% (3/8), respectively.

Consistent with most reviews, intercellular staining was predominant over junctional and intercellular–junctional staining.¹¹² Although this finding agrees with a Japanese study,²⁸ it differs from a French one, where mixed deposits at IIF were reported in 27% of patients.¹¹⁵ As expected, Dsg-1 and -3 were the main targets detected by ELISA (80%, 8/10, Dsg-1 or Dsg-3);¹⁰⁴ however, the predominance of Dsg-3 over Dsg-1 was minimal, differing by only 1 patient.^{113,119} Consistent with other studies, a positive response to BP230 and BP180 antigens was detectable in <40% of patients with PNP. Envoplakin was found in <30% of patients, despite several studies reporting positivity rates exceeding 60%.^{19,113}

A schematic summary of the main differential diagnosis is proposed in Table 4 to help clinicians in distinguishing clinical presentations resembling PNP. Following the EADV task force guidelines for PNP therapy,¹⁰⁴ all patients with PNP enrolled in this study received systemic steroids. Additionally, some patients required IVIG and nonsteroid immunosuppressants. Rituximab was administered to four patients (one affected by melanoma and Castleman disease; the second with breast and rectal cancer; the third with pancreatic and lung cancer; and the fourth with chronic lymphocytic leukaemia and non-Hodgkin lymphoma). Rituximab and ibrutinib were introduced later in the treatment course of the fourth patient, leading to a slow improvement in disease status before the patient's death.

Turning to our findings in the PlgA group, reviews about PlgA have indicated a slight female patient prevalence (sex ratio of 1.1); however, in our study the female patient prevalence was more pronounced (62%, 16/26).¹⁰⁷ Given PlgA rarity, estimations of mortality rates and comparison with the literature on age of onset could not be achieved. Clinically, PlgA typically presents with flaccid blisters on an

Table 3 Comorbidities in patients with IgA pemphigus (PIgA) and pemphigus herpetiformis (PH)

Comorbidities	n (%)
PIgA group (n=26)	
Cardiovascular	
Hypertension	5 (19)
Hypertrophic cardiomyopathy	1 (4)
Infarction	1 (4)
Digestive system	
Hepatitis C	1 (4)
Ascites	1 (4)
Pulmonary	
Chronic obstructive pulmonary disease	1 (4)
Endocrine	
Hypothyroidism	2 (8)
Thyroiditis	2 (8)
Autoimmune	
Polymyalgia rheumatica	1 (4)
Allergological	
Atopic dermatitis	1 (4)
Asthma	2 (8)
Allergic rhinoconjunctivitis	3 (12)
Metabolic	
Diabetes	5 (19)
Hypercholesterolaemia	3 (12)
Others	
Osteoporosis	1 (4)
Anaemia	1 (4)
Spherocytosis	1 (4)
Post-traumatic tetraplegia	1 (4)
Past hepatitis B infection	2 (8)
Endometriosis	1 (4)
Glaucoma	1 (4)
Seronegative arthritis and hyperuricaemia	1 (4)
Cryoglobulinaemia	1 (4)
Monoclonal IgA gammopathy	1 (4)
PH group (n=19)	
Cardiovascular	
Hypertension	3 (16)
Chronic atrial fibrillation	1 (5)
Digestive system	
Hepatitis B	1 (5)
Sigmoid diverticulosis	1 (5)
Antral gastritis	1 (5)
Gastroesophageal reflux disease	1 (5)
Pulmonary	
Pulmonary fibrosis	1 (5)
Endocrine	
Hypothyroidism	2 (11)
Autoimmune	
Autoimmune thyroiditis	1 (5)
Allergological	
Atopic dermatitis	1 (5)
Asthma	1 (5)
Metabolic	
Diabetes	1 (5)
Others	
Osteoporosis	1 (5)
Anaemia	1 (5)
Recurrent herpes simplex infections	1 (5)
Malignancies	
Breast cancer	1 (5)
Prostate cancer	1 (5)
Anal cancer	1 (5)

erythematous-brownish base filled with clear fluid, then evolving into pustules and later annular crusts. Accordingly, skin lesions were often accompanied by pruritus and pain, whereas mucosal surfaces generally showed no involvement. Although typically observed in flexural areas, the

trunk and extremities were the most commonly affected areas in our cohort.⁵¹ No malignancies were observed in patients with PIgA, but new comorbidities such as asthma and allergic rhinoconjunctivitis were noted.^{53–60,107}

On histology, acantholysis was detected in more than half of the patients [54% (14/26) vs. 61.1% in the literature], while eosinophilic spongiosis showed lower values [19.2% (5/26) vs. 53% in the literature].¹⁰⁷ Regarding cell infiltrates, the literature describes isolated neutrophils as the most frequent, followed by mixed neutrophilic–eosinophilic infiltrates and, lastly, lymphocytic or eosinophilic infiltrates.¹⁰⁷ Unlike other reviews, our study detected a smaller number of patients with PIgA with exclusive neutrophilic infiltrates, with mixed lymphocyte–neutrophilic infiltrates being the predominant pattern. The DIF findings in this study resemble those reported in other series, primarily showing IgA intercellular deposits [64% (16/25) vs. 72.7% in the literature], followed by IgA–C3 [36% (9/25) vs. 10.6%] and IgG–IgA deposits [8% (2/25) vs. 3%].¹⁰⁷ Positivity for autoantibodies against Dsg-1 and -3 detected by ELISA closely aligned with the literature.^{107, 120–122} Notably, the copresence of Dsg-1 and -3 in 86% (6/7) of our patients with PIgA represents an original finding not previously documented.

A schematic summary of the main differential diagnosis in PIgA is proposed in Table 5. Owing to the many clinical and histopathological similarities, some experts suggest that PIgA and Sneddon–Wilkinson disease may represent different manifestations of the same disease spectrum rather than truly distinct entities.^{123,124} Given the absence of specific guidelines, it is important to note that all final diagnoses were established through an integrated assessment of the clinical presentation, histological features and immunopathological data. Despite a 2020 review advocating combination therapy for PIgA, our cohort showed an equal distribution between patients on steroid monotherapy and those receiving additional agents.¹⁰⁷

Finally, turning to findings related to PH, in a recent work by Costa *et al.*, 54% of patients with PH were female patients, whereas our study revealed significantly higher percentages (73%, 16/22).⁸⁵ The median age at onset in our cohort was lower than the usual range of between 50 and 60 years. Given PH rarity, estimating mortality rates was not feasible. In accordance with the literature, mucous membranes were usually spared in our patients with PH, whereas cutaneous involvement resembled that of dermatitis herpetiformis, including erythematous-brownish, vesicular, bullous or papular lesions, usually along with severe pruritus.⁸⁴ Furthermore, we observed new associated comorbidities, such as asthma, atopic dermatitis, allergic rhinoconjunctivitis, breast cancer and anal canal cancer.^{72,89–101}

On histology, in our patients with PH, acantholysis was reported with higher percentages than in the literature [73% (16/22) vs. 51%], whereas eosinophilic spongiosis showed lower values [55% (12/22) vs. exceeding 70%].⁸⁵ Contrasting with the literature, our series exhibited higher percentages of mixed eosinophilic–neutrophilic [32% (7/22) vs. 29%] and neutrophilic–lymphocytic infiltrates [64% (14/22) vs. 11%].⁸⁶ The inflammatory infiltrate was predominantly eosinophilic in 91% (20/22) of patients (83% in the literature), whereas neutrophils were found in 36% (8/22), with exclusively neutrophilic infiltrates observed in 5% (1/22) of patients (9% in the literature).⁸⁵

Table 4 Differential diagnosis of paraneoplastic pemphigus (PNP)

Condition	Clinical features	Histological features	IF features
PNP	m: thickened haemorrhagic slough and erosions; necrotic crusts. Lateral border of the tongue, vermillion and lips s: heterogeneous skin lesions. Involvement of palms, soles and frequently paronychia tissues Frequent internal organ involvement. Association with solid or haematological malignancy	Acantholysis, bandlike lymphocytic infiltrates, necrosis, vacuolar degeneration and epidermal detachment	DIF: Intercellular IgG deposits, eventually concurrent IgG BMZ deposits IIF: Similar to DIF. Specificity of rat bladder substrate ELISA: Dsg-1 and -3, plakin family members, BPAg and α 2ML1
PV	m: ragging pattern superficial erosions. Gingiva, soft and hard palate, floor of the mouth, posterior pharynx labial mucosa, and less frequently the tongue s: flaccid bullae that rupture lead to erosions with crust	Suprabasal acantholysis with intraepidermal blisters	DIF: Intercellular IgG and C3 deposits, tombstone-like morphology IIF: Intercellular IgG deposits ELISA: Dsg-3 and -1
BP	m: mucous involvement only in 10–35% of patients s: tense pruritic blisters on healthy or erythematous skin. In people with skin of colour, lesions may develop on violaceous or hyperpigmented skin. Possibility of eczematous plaques or prurigo-like lesions	Subepidermal blisters, superficial dermal infiltrates of lymphocytes, eosinophil and histiocytes	DIF: IgG and C3 at BMZ IIF: IgG at BMZ ELISA: BPAg
MMP	m: persistent painful erosions on gingiva, tongue, and buccal, palatal and eye mucosa. Other sites may be involved s: involved in 25–35% of patients. Small vesicles or bullae on an erythematous/urticarial base. Mainly scalp, head, neck and upper trunk Anti-laminin 332 antibodies are associated with a higher risk of neoplasia, especially solid tumours	Subepidermal blister, superficial dermal infiltrate of lymphocytes, eosinophils and histiocytes	DIF: IgG and C3 at BMZ IIF: IgG anti-BMZ detection in some patients ELISA: BPAg
SJS/TEN	m: erythema evolving into painful erosions. Buccal, ocular and genital mucosa. The oral cavity, vermillion and lips are almost invariably involved with painful haemorrhagic erosions coated by greyish-white pseudomembranes and crusts. Conjunctival lesions include mainly hyperaemia, erosions, chemosis, photophobia and lacrimation s: confluent purpuric and erythematous macules evolving into flaccid blisters and epidermal detachment. In people with skin of colour, lesions may appear as greyish, dark brown or purplish. Trunk and upper limbs Linked to specific drugs; frequent extracutaneous symptoms; abrupt onset	Full-thickness necrosis of the epidermis associated with mild mononuclear cell infiltrate	Negative or nonspecific
EM major	m: present in up to 70% of patients and most often limited to the oral cavity s: highly regular, circular, weal-like erythematous papules or plaques that usually evolve into targetoid lesions. In people with skin of colour, papules may appear as violaceous, dusky or hyperpigmented. Symmetric presentation. Mostly acral distribution on the extensor surface of extremities, face and genitals Abrupt onset; mostly occurs in paediatric ages and young adults. Usually related to recurrent HSV infections. Anamnesis check for other similar episodes	Perivascular mononuclear infiltrate; oedema of the upper dermis; apoptosis of keratinocytes, with focal epidermal necrosis and subepidermal bulla formation; complete necrosis of epidermis in patients with severe cases	Negative or nonspecific
Acute GVHD	m: none s: Faint, erythematous macules with an early perifollicular pattern and late progression to an erythematous or bullous pattern. In people with skin of colour, lesions may initially present as hyperpigmented or violaceous macules, progressing in the later stages to hyperpigmented or violaceous plaques, or developing a bullous appearance. On any skin surface On average 20–80% of patients undergoing allogeneic bone marrow transplantation, about 10–30 days after infusion Frequent association with internal disorders other than skin	Basal vacuolization of DEJ; necrotic epidermal cells; lymphocytic infiltrates; subepidermal clefts; separation of epidermis from dermis The histological findings are described in order of GVHD four-stage grading	Negative or nonspecific
Lichen planus	m: painful milky-white reticulated papules, possible erosion s: flat-topped, pink to violaceous, shiny, and pruritic polygonal papules	Hyperkeratosis increased granular layer, irregular acanthosis liquefaction degeneration of the basal cell layer, colloid bodies at the DEJ and bandlike mononuclear infiltrate	DIF: DEJ fibrin and IgM deposits Less frequently IgA, IgG and C3 in the colloid bodies

α 2ML1, alpha-2-macroglobulin-like protein 1; BMZ, basement membrane zone; BP, bullous pemphigoid; BPAg, bullous pemphigoid antigen; DEJ, dermo-epidermal junction; DIF, direct immunofluorescence; Dsg, desmoglein; ELISA, enzyme-linked immunosorbent assay; EM, erythema multiforme; GVHD, graft-versus-host disease; HSV, herpes simplex virus; IIF, indirect immunofluorescence; m, mucosal lesions; IF, immunofluorescence; MMP, mucous membrane pemphigoid; PV, pemphigus vulgaris; s, skin lesions; SJS/TEN Stevens–Johnson syndrome/toxic epidermal necrolysis.

Table 5 Differential diagnosis of IgA pemphigus (PIgA) and pemphigus herpetiformis (PH)

Condition	Clinical features	Histological features	IF features
PIgA	m: rarely involved s: SPD and IEN-type forms: sterile pustules PF-like form: flaccid blisters with crusting	Scarce acantholysis SPD-type: subcorneal neutrophilic infiltrates IEN-type: intraepidermal neutrophilic infiltrates	DIF: IgA deposits in upper epidermis IIF: IgA deposits in upper epidermis ELISA: Dsc-1
SWD	m: rarely involved s: sterile pustules; eruption in cyclical pattern, coalescence in annular pattern and eventually burst to form crusted plaques Acute onset	Subcorneal pustules filled with polymorphonuclear leucocytes and occasional eosinophils; dermal perivascular infiltration with neutrophils; mild spongiosis	DIF: usually not relevant IIF: usually not relevant
LABD	m: oral and conjunctival erosions and scarring, in nearly 50% of patients s: scattered, tense bullae on a background of noninflamed skin; possible herpetiform appearance; mainly trunk and extremities, but also scalp, genital area or face	Subepidermal blisters with mainly neutrophilic infiltrates; cluster of jewels pattern	DIF: Linear pattern IgA deposits at BMZ IIF: IgA and C3 at BMZ
PF	m: rare involvement s: flaccid blisters with crusting; trunk and seborrhoeic areas	Subcorneal acantholysis	DIF: intercellular IgG and C3 deposits IIF: intercellular IgG deposits ELISA: Dsg-1 Negative or nonspecific
Pustular psoriasis	m: none s: palmoplantar pustulosis: only palms and soles. Chronic onset Generalized pustular psoriasis: burning, fiery-red erythema topped by pinpoint sterile yellow pustules in clusters all over the body. In people with skin of colour, lesions may develop on violaceous or hyperpigmented skin. Frequent general symptomatology, nail and hair lesions Acute onset	Intraepidermal pustules with different stages of involvement; early subcorneal infiltrates of neutrophils and slight acantholysis; late scaly crusts with neutrophils	
Bullous impetigo	m: none s: superficial multiple flaccid bullae with yellowish and slightly turbid exudate surrounded by erythematous or violaceous halo and easily rupture, showing shallow moist erosions surrounded by healthy skin, extremities, face and intertriginous areas The lesions are infectious	Subepidermal blisters; sporadic neutrophils, Gram-positive cocci and acantholytic cells, and mixed inflammatory cell infiltrate in the papillary dermis	Negative or nonspecific
PH	m: rare involvement s: erythematous-brownish or violaceous, vesicular, bullous or papular lesions; severe pruritus and symmetry of the lesions; mainly abdomen, gluteus, face and extensor surfaces of the extremities	Eosinophilic spongiosis in the mid-subcorneal epidermis; microabscesses in the mid-subcorneal epidermis; acantholysis, if present, emerges later	DIF: IgG and C3 superficial intraepithelial intercellular deposits (PF-type pattern). IgG and C3 deposits can be found deeper in the epidermidis (PV-type pattern) IIF: IgG and C3 intercellular deposits ELISA: mainly Dsg-1, but also Dsc-1 and Dsg-3
Dermatitis herpetiformis	m: none s: tense blisters with intense pruritus; extensor surfaces, scalp, buttocks and back	Subepidermal blistering; neutrophilic microabscesses at the tips of dermal papillae	DIF: haphazard granular IgA deposition IIF: IgA anti-endomysium ELISA: epidermal transglutaminase

α 2ML1, alpha-2-macroglobulin-like protein 1; BMZ, basement membrane zone; DIF, direct immunofluorescence; Dsc, desmocollin; Dsg, desmoglein; ELISA, enzyme-linked immunosorbent assay; IEN, intercellular epidermal neutrophilic; IF, immunofluorescence; IIF, indirect immunofluorescence; LABD, linear IgA bullous dermatosis; m, mucosal lesions; PF, pemphigus foliaceus; PV, pemphigus vulgaris; s, skin lesions; SPD, subcorneal pustular dermatosis; SWD, Sneddon–Wilkinson disease.

On DIF intercellular IgG–C3 deposits were the most prevalent, with exclusive IgG deposits constituting only 10% (2/21). In contrast, the literature shows a slight predominance of exclusive IgG deposits (49%) over IgG–C3

copresence (40%).⁸⁵ In ELISA studies, the literature identifies the following percentages: Dsg-1 (32%), Dsg-3 (7%), both (4%) and a variable combination of Dsg and Dsc in even rarer instances.^{47,75,78,85,87,125–128} In our study, Dsg-1

also emerged as the main target, whereas the copresence of Dsg-1 and -3 was also notably frequent (44%, 7/16). None of the patients showed exclusive positivity for Dsg-3.

A schematic summary of the main differential diagnosis for PH is provided in Table 5. According to the literature, PH therapy relied mainly on steroids and just a minority of patients required further treatments.^{47,85}

In conclusion, this is the first multicentre study, to our knowledge, to systematically enrol and describe a large cohort of patients with atypical pemphigus. Predominantly affecting adult female patients, the three variants of atypical pemphigus exhibited significant clinical polymorphism and frequent association with multiple comorbidities, some of which were newly identified. For patients with PNP, the sex distribution and laboratory findings were partially consistent with the existing literature. Acantholysis was the main histological feature in PlgA and PH, correlating with a bullous clinical pattern, while eosinophilic spongiosis and neutrophilic pustules, seen less frequently, were associated with pustular lesions. These observations underscore a consistent correlation between clinical morphology and histological patterns. Concerning ELISA findings across all three atypical variants, Dsg-1 and -3 showed frequent associations, but Dsg-3 was rarely found alone. Despite the Dsg compensation theory, Dsg-1 and -3 copresence was negative in the majority of patients with PNP who had mucocutaneous lesions, thus underlying the complexity of the pathogenesis involving targets other than Dsg. Conversely, in PlgA and PH, mucocutaneous manifestations were mainly associated with Dsg-1 and -3 copresence.

The limited availability of data and the polymorphic clinical presentation of atypical pemphigus variants often lead to misdiagnosis and significant delays in diagnosis, sometimes extending over several years. Notably, such delays were not observed in our cohort, probably owing to the inclusion of only specialized referral centres. To optimize patient management and in accordance with the recent EADV guidelines on PNP,¹⁰⁴ it is crucial to encourage steroid-sparing treatment strategies in patients with PlgA and PH, with rituximab recommended as a first-line option.

Funding sources

This research received no specific grant from any funding agency in the public, commercial or not-for-profit sectors.

Conflicts of interest

The authors declare no conflicts of interest.

Data availability

The data underlying this article cannot be shared publicly owing to reasons of sensitivity. The data will be shared on reasonable request to the corresponding author.

Ethics statement

Reviewed and approved on 13 September 2022 by 'Comitato Etico Regionale per la Sperimentazione Clinica della Regione Toscana, Sezione AREA VASTA CENTRO', Protocol code

VARIANT_P, Numero registro pareri del Comitato Etico 22552_oss.

Patient consent

The patients included in this manuscript have given written informed consent for the publication of their case details.

References

- Kridin K. Pemphigus group: overview, epidemiology, mortality, and comorbidities. *Immunol Res* 2018; **66**:255–70.
- Joly P, Litrowski N. Pemphigus group (vulgaris, vegetans, foliaceus, herpetiformis, brasiliensis). *Clin Dermatol* 2011; **29**:432–6.
- Ng PP, Thng ST, Mohamed K, Tan SH. Comparison of desmoglein ELISA and indirect immunofluorescence using two substrates (monkey oesophagus and normal human skin) in the diagnosis of pemphigus. *Australas J Dermatol* 2005; **46**:239–41.
- Ding X, Aoki V, Mascaro JM Jr *et al.* Mucosal and mucocutaneous (generalized) pemphigus vulgaris show distinct autoantibody profiles. *J Invest Dermatol* 1997; **109**:592–6.
- Harman KE, Seed PT, Gratian MJ *et al.* The severity of cutaneous and oral pemphigus is related to desmoglein 1 and 3 antibody levels. *Br J Dermatol* 2001; **144**:775–80.
- Tron F, Grassi V, Musette P *et al.* ELISA testing of anti-desmoglein 1 and 3 antibodies in the management of pemphigus. *Arch Dermatol* 2009; **145**:529–35.
- Tedbird B, Maho-Vaillant M, Houivet E *et al.* Sustained remission without corticosteroids among patients with pemphigus who had rituximab as first-line therapy: follow-up of the Ritux 3 trial. *JAMA Dermatol* 2024; **160**:290–6.
- Lauber J, Turk K, Beach H, Beau's lines and pemphigus vulgaris. *Int J Dermatol* 1990; **29**:309.
- Anhalt GJ. Making sense of antigens and antibodies in pemphigus. *J Am Acad Dermatol* 1999; **40**:763–6.
- Mahoney MG, Wang Z, Rothenberger K *et al.* Explanations for the clinical and microscopic localization of lesions in pemphigus foliaceus and vulgaris. *J Clin Invest* 1999; **103**:4618.
- Zimmermann J, Bahmer F, Rose C *et al.* Clinical and immunopathological spectrum of paraneoplastic pemphigus. *J Dtsch Dermatol Ges* 2010; **8**:598–606.
- Wieczorek M, Czernik A. Paraneoplastic pemphigus: a short review. *Clin Cosmet Investig Dermatol* 2016; **9**:291–5.
- Borradori L, Trüeb RM, Jaunin F *et al.* Autoantibodies from a patient with paraneoplastic pemphigus bind periplakin, a novel member of the plakin family. *J Invest Dermatol* 1998; **111**:338–40.
- Mahoney MG, Aho S, Uitto J, Stanley JR. The members of the plakin family of proteins recognized by paraneoplastic pemphigus antibodies include periplakin. *J Invest Dermatol* 1998; **111**:308–13.
- Schepens I, Jaunin F, Begre N *et al.* The protease inhibitor alpha-2-macroglobulin-like-1 is the p170 antigen recognized by paraneoplastic pemphigus autoantibodies in human. *PLoS One* 2010; **5**:e12250.
- Amagai M, Nishikawa T, Nousari HC *et al.* Antibodies against desmoglein 3 (pemphigus vulgaris antigen) are present in sera from patients with paraneoplastic pemphigus and cause acantholysis in vivo in neonatal mice. *J Clin Invest* 1998; **102**:775–82.
- Numata S, Teye K, Tsuruta D *et al.* Anti- α -2-macroglobulin-like-1 autoantibodies are detected frequently and may be pathogenic in paraneoplastic pemphigus. *J Invest Dermatol* 2013; **133**:1785–93.
- Oursler JR, Labib RS, Ariss-Abdo L *et al.* Human autoantibodies against desmoplakins in paraneoplastic pemphigus. *J Clin Invest* 1992; **89**:1775–82.
- Probst C, Schlumberger W, Stöcker W *et al.* Development of ELISA for the specific determination of autoantibodies against

- envoplakin and periplakin in paraneoplastic pemphigus. *Clin Chim Acta* 2009; **410**:13–18.
- 20 Kiyokawa C, Ruhrberg C, Nie Z *et al.* Envoplakin and periplakin are components of the paraneoplastic pemphigus antigen complex. *J Invest Dermatol* 1998; **111**:1236–8.
 - 21 Kim SC, Kwon YD, Lee IJ *et al.* cDNA cloning of the 210-kDa paraneoplastic pemphigus antigen reveals that envoplakin is a component of the antigen complex. *J Invest Dermatol* 1997; **109**:365–9.
 - 22 Proby C, Fujii Y, Owaribe K *et al.* Human autoantibodies against HD1/plectin in paraneoplastic pemphigus. *J Invest Dermatol* 1999; **112**:153–6.
 - 23 Tsuchisaka A, Numata S, Teye K *et al.* Epiplakin is a paraneoplastic pemphigus autoantigen and related to bronchiolitis obliterans in Japanese patients. *J Invest Dermatol* 2016; **136**:399–408.
 - 24 Ishii N, Teye K, Fukuda S *et al.* Anti-desmocollin autoantibodies in nonclassical pemphigus. *Br J Dermatol* 2015; **173**:59–68.
 - 25 Leger S, Picard D, Ingen-Housz-Oro S *et al.* Prognostic factors of paraneoplastic pemphigus. *Arch Dermatol* 2012; **148**:1165–72.
 - 26 Martel P, Loiseau P, Joly P *et al.* Paraneoplastic pemphigus is associated with the DRB1*03 allele. *J Autoimmun* 2003; **20**:91–5.
 - 27 Ostezan LB, Fabr e VC, Caughman SW *et al.* Paraneoplastic pemphigus in the absence of a known neoplasm. *J Am Acad Dermatol* 1995; **33**:312–15.
 - 28 Ohzono A, Sogame R, Li X *et al.* Clinical and immunological findings in 104 cases of paraneoplastic pemphigus. *Br J Dermatol* 2015; **173**:1447–52.
 - 29 Nguyen VT, Ndoye A, Bassler KD *et al.* Classification, clinical manifestations, and immunopathological mechanisms of the epithelial variant of paraneoplastic autoimmune multiorgan syndrome: a reappraisal of paraneoplastic pemphigus. *Arch Dermatol* 2001; **137**:193–206.
 - 30 Anhalt GJ. Paraneoplastic pemphigus. *J Invest Dermatol Symp Proc* 2004; **9**:29–33.
 - 31 Yong AA, Tey HL. Paraneoplastic pemphigus. *Australas J Dermatol* 2013; **54**:241–50.
 - 32 Zhu X, Zhang B. Paraneoplastic pemphigus. *J Dermatol* 2007; **34**:503–11.
 - 33 Almater AI, Abusayf MM, Alshahrani S *et al.* Paraneoplastic pemphigus associated with rapidly progressing endophthalmitis caused by *Morganella Morganii*: a case report. *Eur J Ophthalmol* 2022; **32**:NP69–72.
 - 34 Tam PMK, Cheng LL, Young AL, Lam PTH. Paraneoplastic pemphigus: an uncommon cause of chronic cicatrizing conjunctivitis. *BMJ Case Rep* 2009; **2009**:bcr12.2008.1306.
 - 35 Ahuero AE, Jakobiec FA, Bhat P *et al.* Paraneoplastic conjunctival cicatrization: two different pathogenic types. *Ophthalmology* 2010; **117**:659–64.
 - 36 Venkateswaran N, Klavdianou O, Kondylis G *et al.* Paraneoplastic pemphigus associated with bilateral corneal perforations in follicular dendritic cell sarcoma. *Ocul Immunol Inflamm* 2022; **30**:978–80.
 - 37 Piscopo R, Romano M, Maria AD *et al.* Ocular onset of paraneoplastic pemphigus presenting as hyperemic conjunctivitis and massive bilateral eyelid ulceration: a case report and literature review. *Ocul Immunol Inflamm* 2018; **26**:265–8.
 - 38 Beele H, Claerhout I, Kestelyn P *et al.* Bilateral corneal melting in a patient with paraneoplastic pemphigus. *Dermatol Basel Switz* 2001; **202**:147–50.
 - 39 Gong H, Zhou S, Hu Y *et al.* Recurrent corneal melting in the paraneoplastic pemphigus associated with Castleman's disease. *BMC Ophthalmol* 2016; **16**:106.
 - 40 Anan T, Shimizu F, Hatano Y *et al.* Paraneoplastic pemphigus associated with corneal perforation and cutaneous alternans: a case report and review of cases treated with rituximab. *J Dermatol* 2011; **38**:1084–9.
 - 41 Maldonado F, Pittelkow MR, Ryu JH. Constrictive bronchiolitis associated with paraneoplastic autoimmune multi-organ syndrome. *Respirology* 2009; **14**:129–33.
 - 42 Kishi T, Nakata J, Yamada T *et al.* Fatal progression of bronchiolitis obliterans in spite of complete remission of follicular lymphoma and paraneoplastic pemphigus. *Ann Hematol* 2022; **101**:453–5.
 - 43 Ouedraogo E, Gottlieb J, de Masson A *et al.* Risk factors for death and survival in paraneoplastic pemphigus associated with hematologic malignancies in adults. *J Am Acad Dermatol* 2019; **80**:1544–9.
 - 44 Mimouni D, Anhalt GJ, Lazarova Z *et al.* Paraneoplastic pemphigus in children and adolescents. *Br J Dermatol* 2002; **147**:725–32.
 - 45 Kridin K, Schmidt E. Epidemiology of pemphigus. *JID Innov Skin Sci Mol Popul Health* 2021; **1**:100004.
 - 46 Hashimoto T, Teye K, Hashimoto K *et al.* Clinical and immunological study of 30 cases with both IgG and IgA anti-keratinocyte cell surface autoantibodies toward the definition of intercellular IgG/IgA dermatosis. *Front Immunol* 2018; **9**:994.
 - 47 Porro AM, Caetano L de VN, Maehara L de SN *et al.* Non-classical forms of pemphigus: pemphigus herpetiformis, IgA pemphigus, paraneoplastic pemphigus and IgG/IgA pemphigus. *An Bras Dermatol* 2014; **89**:96–106.
 - 48 Yasuda H, Kobayashi H, Hashimoto T *et al.* Subcorneal pustular dermatosis type of IgA pemphigus: demonstration of autoantibodies to desmocollin-1 and clinical review. *Br J Dermatol* 2000; **143**:144–8.
 - 49 Amagai M. Adhesion molecules. I: keratinocyte-keratinocyte interactions; cadherins and pemphigus. *J Invest Dermatol* 1995; **104**:146–52.
 - 50 Tsuruta D, Ishii N, Hamada T *et al.* IgA pemphigus. *Clin Dermatol* 2011; **29**:437–42.
 - 51 Fabbri P. [Clinical Immunodermatology]. Padua: Piccin, 2023 (in Italian).
 - 52 Geller S, Gat A, Zeeli T *et al.* The expanding spectrum of IgA pemphigus: a case report and review of the literature. *Br J Dermatol* 2014; **171**:650–6.
 - 53 Hodak E, David M, Ingber A *et al.* The clinical and histopathological spectrum of IgA-pemphigus – report of two cases. *Clin Exp Dermatol* 1990; **15**:433–7.
 - 54 Wallach D. Intraepidermal IgA pustulosis. *J Am Acad Dermatol* 1992; **27**:993–1000.
 - 55 Ljubojevic S, Lipozen c J. Autoimmune bullous diseases associations. *Clin Dermatol* 2012; **30**:17–33.
 - 56 Kern JS, Gehring W, Kreisel W *et al.* Overlap of IgA pemphigus and linear IgA dermatosis in a patient with ulcerative colitis: a mere coincidence? *Acta Derm Venereol* 2014; **94**:228–30.
 - 57 Sotiriou MC, Foo CW, Scholes CT, Zone JJ. Immunobullous disease and ulcerative colitis: a case series of six patients. *Br J Dermatol* 2015; **173**:792–6.
 - 58 Papakonstantinou E, Kapp A, Jonkman MF, Raap U. Intraepidermal neutrophilic dermatosis type of IgA pemphigus with circulating linear IgA disease antibodies associated with ulcerative colitis. *J Eur Acad Dermatol Venereol* 2018; **32**:e10–11.
 - 59 Cetkovsk a P, Komorousov a M, Lomicov a I. Management of a pemphigus with IgA and IgG antibodies and coexistent lung cancer. *Dermatol Ther* 2014; **27**:236–9.
 - 60 Petropoulou H, Politis G, Panagakis P *et al.* Immunoglobulin A pemphigus associated with immunoglobulin A gammopathy and lung cancer. *J Dermatol* 2008; **35**:341–5.
 - 61 Hayder F, Bahloul E, Sellami K *et al.* Pemphigus herpetiformis in a 4-year-old child: case report and review of the literature. *Clin Case Rep* 2022; **10**:e05567.
 - 62 Hocar O, Ait Sab I, Akhdari N *et al.* A case of pemphigus herpetiformis in a 12-year-old male. *ISRN Pediatr* 2011; **2011**:712560.
 - 63 Leithauser LA, Mutasim DF. A case of pemphigus herpetiformis occurring in a 9-year-old boy. *Pediatr Dermatol* 2013; **30**:760–2.

- 64 Moutran R, Maatouk I, Stephan F *et al.* Letter: pemphigus herpeticiformis of age of onset at 6 years. *Dermatol Online J* 2011; **17**:10.
- 65 Jablonska S, Chorzelski TP, Beutner EH, Chorzelska J. Herpeticiform pemphigus, a variable pattern of pemphigus. *Int J Dermatol* 1975; **14**:353–9.
- 66 Floden CH, Gentile H. A case of clinically typical dermatitis herpeticiformis (MB Dühring) presenting acantholysis. *Acta Derm Venereol* 1955; **35**:128–31.
- 67 Duarte IB, Bastazini I, Barreto JA *et al.* Pemphigus herpeticiformis in childhood. *Pediatr Dermatol* 2010; **27**:488–91.
- 68 Adams A, Warschaw K, Hansen R, Jeck T. A case of pemphigus herpeticiformis in a 10-year-old female. *J Am Acad Dermatol* 2009; **60** (Suppl. 1):AB145.
- 69 Akoglu G, Yavuz SO. Pemphigus herpeticiformis-type drug reaction caused by erdosteine containing mucolytic in a child. *Cutan Ocul Toxicol* 2017; **36**:302–4.
- 70 Bonifazi E, Garofalo L, Pappalardi M. Childhood pemphigus foliaceus. Herpeticiform variant. *Eur J Pediatr Dermatol* 2003; **13**:154.
- 71 Maggiore R, Viglizzo G, Occella C *et al.* Pemphigus herpeticiformis resistant to first line therapy: a rare case in childhood. *G Ital Dermatol E Venereol* 2019; **154**:499–501.
- 72 Schoch JJ, Boull CL, Camilleri MJ *et al.* Transplacental transmission of pemphigus herpeticiformis in the setting of maternal lymphoma. *Pediatr Dermatol* 2015; **32**:e234–7.
- 73 Peterman CM, Vadeboncoeur S, Schmidt BA, Gellis SE. Pediatric pemphigus herpeticiformis: case report and review of the literature. *Pediatr Dermatol* 2017; **34**:342–6.
- 74 Huhn KM, Tron VA, Nguyen N, Trotter MJ. Neutrophilic spongiosis in pemphigus herpeticiformis. *J Cutan Pathol* 1996; **23**:264–9.
- 75 Tateishi C, Tsuruta D, Nakanishi T *et al.* Antidesmocollin-1 antibody-positive, antidesmoglein antibody-negative pemphigus herpeticiformis. *J Am Acad Dermatol* 2010; **63**:e8–10.
- 76 Ohata C, Higashi Y, Yamagami J *et al.* Coexistence of pemphigus herpeticiformis with IgG antibodies to desmoglein 1 and pemphigoid with IgG antibodies to BP180 C-terminal domain and laminin γ 2. *JAMA Dermatol* 2013; **149**:502–4.
- 77 Chan LS, Vanderlugt CJ, Hashimoto T *et al.* Epitope spreading: lessons from autoimmune skin diseases. *J Invest Dermatol* 1998; **110**:103–9.
- 78 Verdier-Sevrain S, Joly P, Thomine E *et al.* Thiopronine-induced herpeticiform pemphigus: report of a case studied by immunoelectron microscopy and immunoblot analysis. *Br J Dermatol* 1994; **130**:238–40.
- 79 Abe T, Kouno M, Yamamoto N *et al.* A case of D-penicillamine induced herpeticiform pemphigus. *Nishinihon J Dermatol* 2003; **65**:126–9.
- 80 Weltfreund S, Ingber A, David M, Sandbank M. [Pemphigus herpeticiformis following D-penicillamine in a patient with HLA B8]. *Hautarzt* 1988; **39**:587–8 (in German).
- 81 Marsden RA, Dawber RP, Millard PR, Mowat AG. Herpeticiform pemphigus induced by penicillamine. *Br J Dermatol* 1977; **97**:451–2.
- 82 Yoshimura K, Ishii N, Hamada T *et al.* Clinical and immunological profiles in 17 Japanese patients with drug-induced pemphigus studied at Kurume University. *Br J Dermatol* 2014; **171**:544–53.
- 83 Morioka S, Ogawa H. Herpeticiform pemphigus-like skin lesions induced by D-penicillamine. *J Dermatol* 1980; **7**:425–9.
- 84 Kasperkiewicz M, Kowalewski C, Jabłońska S. Pemphigus herpeticiformis: from first description until now. *J Am Acad Dermatol* 2014; **70**:780–7.
- 85 Costa LMC, Cappel MA, Keeling JH. Clinical, pathologic, and immunologic features of pemphigus herpeticiformis: a literature review and proposed diagnostic criteria. *Int J Dermatol* 2019; **58**:997–1007.
- 86 Robinson ND, Hashimoto T, Amagai M, Chan LS. The new pemphigus variants. *J Am Acad Dermatol* 1999; **40**:649–71.
- 87 Prado R, Brice SL, Fukuda S *et al.* Paraneoplastic pemphigus herpeticiformis with IgG antibodies to desmoglein 3 and without mucosal lesions. *Arch Dermatol* 2011; **147**:67–71.
- 88 Palleschi GM, Giomi B. Herpeticiform pemphigus and lung carcinoma: a case of paraneoplastic pemphigus. *Acta Derm Venereol* 2002; **82**:304–5.
- 89 Arranz D, Corral M, Prats I *et al.* [Herpeticiform pemphigus associated with esophageal carcinoma]. *Actas Dermosifiliogr* 2005; **96**:119–21 (in Spanish).
- 90 Marzano AV, Toulaki A, Cozzani E *et al.* Pemphigus herpeticiformis associated with prostate cancer. *J Eur Acad Dermatol Venereol* 2007; **21**:696–8.
- 91 Lu Y, Zhang M. Pemphigus herpeticiformis in a patient with well-differentiated cutaneous angiosarcoma: case report and review of the published work. *J Dermatol* 2012; **39**:89–91.
- 92 Yamamoto M, Ikai K, Horiguchi Y. A case of herpeticiform pemphigus associated with lung cancer. *Acta Dermatol Kyoto* 1988; **83**:63–7.
- 93 Vicente MA, Iranzo P, Castell T *et al.* [Pemphigus herpeticiformis associated with neoplasm of the lung]. *Med Cutan Ibero Lat Am* 1989; **17**:373–8 (in Spanish).
- 94 Kubota Y, Yoshino Y, Mizoguchi M. A case of herpeticiform pemphigus associated with lung cancer. *J Dermatol* 1994; **21**:609–11.
- 95 Bull RH, Fallowfield ME, Marsden RA. Autoimmune blistering diseases associated with HIV infection. *Clin Exp Dermatol* 1994; **19**:47–50.
- 96 Sanchez-Palacios C, Chan LS. Development of pemphigus herpeticiformis in a patient with psoriasis receiving UV-light treatment. *J Cutan Pathol* 2004; **31**:346–9.
- 97 Morita E, Amagai M, Tanaka T *et al.* A case of herpeticiform pemphigus coexisting with psoriasis vulgaris. *Br J Dermatol* 1999; **141**:754–5.
- 98 Marinović B, Basta-Juzbasić A, Bukvić-Mokos Z *et al.* Coexistence of pemphigus herpeticiformis and systemic lupus erythematosus. *J Eur Acad Dermatol Venereol* 2003; **17**:316–9.
- 99 Shimizu K, Hashimoto T, Wang N *et al.* A case of herpeticiform pemphigus associated with autoimmune hemolytic anemia: detection of autoantibodies against multiple epidermal antigens. *Dermatol Basel Switz* 1996; **192**:179–82.
- 100 Nakamura Y, Takahata H, Teye K *et al.* A case of pemphigus herpeticiformis-like atypical pemphigus with IgG anti-desmoglein 3 antibodies. *Br J Dermatol* 2014; **171**:1588–90.
- 101 Tagami H, Imamura S, Noguchi S, Nishitani H. Coexistence of peculiar pemphigus, myasthenia gravis and malignant thymoma. *Dermatologica* 1976; **152**:181–90.
- 102 Wang FF, Bai YP, Zheng ZC *et al.* Coexistence of pemphigus herpeticiformis with extramammary Paget disease. *Clin Exp Dermatol* 2018; **43**:324–6.
- 103 Lebeau S, Müller R, Masouyé IL *et al.* Pemphigus herpeticiformis: analysis of the autoantibody profile during the disease course with changes in the clinical phenotype. *Clin Exp Dermatol* 2010; **35**:366–72.
- 104 Antiga E, Bech R, Maglie R *et al.* S2k guidelines on the management of paraneoplastic pemphigus/paraneoplastic autoimmune multiorgan syndrome initiated by the European Academy of Dermatology and Venereology (EADV). *J Eur Acad Dermatol Venereol* 2023; **37**:1118–34.
- 105 StataCorp (2019) *Stata Statistical Software Release 16*. College Station, TX: StataCorp LLC, 2019.
- 106 Quintarelli L, Coi A, Maglie R *et al.* Clinical patterns, survival, comorbidities, and treatment regimens in 149 patients with pemphigus in Tuscany (Italy): a 12-year hospital-based study. *Front Immunol* 2022; **13**:895490.
- 107 Kridin K, Patel PM, Jones VA *et al.* IgA pemphigus: a systematic review. *J Am Acad Dermatol* 2020; **82**:1386–92.

- 108 Joly P, Horvath B, Patsatsi A *et al.* Updated S2 K guidelines on the management of pemphigus vulgaris and foliaceus initiated by the European Academy of Dermatology and Venereology (EADV). *J Eur Acad Dermatol Venereol* 2020; **34**:1900–13.
- 109 Joly P, Maho-Vaillant M, Prost-Squarcioni C *et al.* First-line rituximab combined with short-term prednisone versus prednisone alone for the treatment of pemphigus (Ritux 3): a prospective, multicentre, parallel-group, open-label randomised trial. *Lancet* 2017; **389**:2031–40.
- 110 Czernik A, Camilleri M, Pittelkow MR, Grando SA. Paraneoplastic autoimmune multiorgan syndrome: 20 years after. *Int J Dermatol* 2011; **50**:905–14.
- 111 Wang M, Li F, Wang X *et al.* Features and risk factors for paraneoplastic autoimmune multiorgan syndrome in 145 Chinese patients. *Acta Derm Venereol* 2020; **100**:adv00312.
- 112 Paolino G, Didona D, Magliulo G *et al.* Paraneoplastic pemphigus: insight into the autoimmune pathogenesis, clinical features and therapy. *Int J Mol Sci* 2017; **18**:2532.
- 113 Fournet M, Roblot P, Levillain P *et al.* Paraneoplastic pemphigus: retrospective study of a case series. *Ann Dermatol Venereol* 2018; **145**:564–71. in French.
- 114 Allenova A, Lepekhova A, Olisova O *et al.* Paraneoplastic pemphigus in Russian patients: a single center case series. *Int J Dermatol* 2018; **57**:e44–6.
- 115 Joly P, Richard C, Gilbert D *et al.* Sensitivity and specificity of clinical, histologic, and immunologic features in the diagnosis of paraneoplastic pemphigus. *J Am Acad Dermatol* 2000; **43**:619–26.
- 116 Poot AM, Siland J, Jonkman MF *et al.* Direct and indirect immunofluorescence staining patterns in the diagnosis of paraneoplastic pemphigus. *Br J Dermatol* 2016; **174**:912–15.
- 117 Amber KT, Valdebran M, Grando SA. Paraneoplastic autoimmune multiorgan syndrome (PAMS): beyond the single phenotype of paraneoplastic pemphigus. *Autoimmun Rev* 2018; **17**:1002–10.
- 118 Helou J, Allbritton J, Anhalt GJ. Accuracy of indirect immunofluorescence testing in the diagnosis of paraneoplastic pemphigus. *J Am Acad Dermatol* 1995; **32**:441–7.
- 119 Tsuchisaka A, Kawano H, Yasukochi A *et al.* Immunological and statistical studies of anti-BP180 antibodies in paraneoplastic pemphigus. *J Invest Dermatol* 2014; **134**:2283–7.
- 120 Hegazy S, Bouchouicha S, Khaled A *et al.* IgA pemphigus showing IgA antibodies to desmoglein 1 and 3. *Dermatol Pract Concept* 2016; **6**:31–3.
- 121 Wang J, Kwon J, Ding X *et al.* Nonsecretory IgA1 autoantibodies targeting desmosomal component desmoglein 3 in intraepidermal neutrophilic IgA dermatosis. *Am J Pathol* 1997; **150**:1901–7.
- 122 Kárpáti S, Amagai M, Liu WL *et al.* Identification of desmoglein 1 as autoantigen in a patient with intraepidermal neutrophilic IgA dermatosis type of IgA pemphigus. *Exp Dermatol* 2000; **9**:224–8.
- 123 Aimo C, Corrà A, Mariotti E *et al.* IgA pemphigus and Sneddon Wilkinson disease: a spectrum of diseases? *Ital J Dermatol Venereol* 2022; **157**:456–7.
- 124 Manjaly P, Sanchez K, Gregoire S *et al.* Superficial and bullous neutrophilic dermatoses: Sneddon-Wilkinson, IgA pemphigus, and bullous lupus. *Dermatol Clin* 2024; **42**:307–15.
- 125 Miyagawa S, Amagai M, Iida T *et al.* Late development of antidesmoglein 1 antibodies in pemphigus vulgaris: correlation with disease progression. *Br J Dermatol* 1999; **141**:1084–7.
- 126 Isogai R, Kawada A, Aragane Y *et al.* A case of herpetiform pemphigus with anti-desmoglein 3 IgG autoantibodies. *J Dermatol* 2004; **31**:407–10.
- 127 Ishii K, Amagai M, Komai A *et al.* Desmoglein 1 and desmoglein 3 are the target autoantigens in herpetiform pemphigus. *Arch Dermatol* 1999; **135**:943–7.
- 128 Kubo A, Amagai M, Hashimoto T *et al.* Herpetiform pemphigus showing reactivity with pemphigus vulgaris antigen (desmoglein 3). *Br J Dermatol* 1997; **137**:109–13.