



Long latency responses in tongue muscle elicited by various stimulation sites in anesthetized humans – New insights into tongue-related brainstem reflexes[☆]



Andrea Szelényi^{a, *}, Enrica Fava^b

^a Department of Neurosurgery, University Hospital, LMU Munich, Munich, Germany

^b Department of Neurosurgery, Great Metropolitan Hospital of Niguarda, University of Milano, Italy

ARTICLE INFO

Article history:

Received 17 June 2021
Received in revised form
15 March 2022
Accepted 16 March 2022

Mesh terms:

Adult
Blinking/physiology
Brain Stem/physiology
Brain Stem/surgery
Cranial Nerves/physiology
Electric Stimulation
Electromyography/methods
Evoked Potentials
Motor/physiology
Humans
Monitoring, Intraoperative/methods
Muscle, Skeletal/innervation
Muscle, Skeletal/physiology
Reflex/physiology
Tongue/innervation
Tongue/physiology
Trigeminal Nerve/physiology

Keywords:

Direct trigeminal nerve stimulation
Dorsal column stimulation
Trigemino-hypoglossal reflex
Long latency responses
Median nerve stimulation
Negative airway pressure reflex
Somatosensory-evoked tongue reflex
Transcranial electric stimulation
Tongue

ABSTRACT

Background: Long Latency Responses (LLR) in tongue muscles are a scarcely described phenomenon, the physiology of which is uncertain.

Objectives: The aim of this exploratory, observational study was to describe tongue-LLR elicited by direct trigeminal nerve (DTNS), dorsal column (DoCoLS), transcranial electric (TES) and peripheral median nerve (MNS) stimulation in a total of 93 patients undergoing neurosurgical procedures under general anesthesia.

Methods: Bilateral tongue responses were derived concurrently after each of the following stimulations: (1) DTNS applied with single monophasic or train-of-three pulses, ≤ 5 mA; (2) DoCoLS applied with a train-of-three pulses, ≤ 10 mA; (3) TES consisting of an anodal train-of-five stimulation, ≤ 250 mA; (4) MNS at wrist consisting of single or train-of-three monophasic pulses, ≤ 50 mA. Polyphasic tongue muscle responses exceeding the latencies of tongue compound muscle action potentials or motor evoked potentials were classified as LLR.

Results: Tongue-LLR were evoked from all stimulation sites, with latencies as follows: (1) DTNS: solely ipsilateral 20.2 ± 3.3 msec; (2) DoCoLS: ipsilateral 25.9 ± 1.6 msec, contralateral 25.1 ± 4.2 msec; (3) TES: contralateral 55.3 ± 10.2 msec, ipsilateral 54.9 ± 12.0 msec; (4) MNS: ipsilateral 37.8 ± 4.7 msec and contralateral 40.3 ± 3.5 msec.

Conclusion: The tongue muscles are a common efferent in brainstem pathways targeted by trigeminal and cervical sensory fibers. DTNS can elicit the “trigemino-hypoglossal-reflex”. For the MNS elicited tongue-LLR, we propose the term “somatosensory-evoked tongue-reflex”. Although the origin of the TES related tongue-LLR remains unclear, these data will help to interpret intraoperative tongue recordings.

© 2022 Published by Elsevier Inc. This is an open access article under the CC BY-NC-ND license (<http://creativecommons.org/licenses/by-nc-nd/4.0/>).

[☆] PRESENTATION AT A CONFERENCE: Parts of this paper have been published in Conference proceedings at the XX International Congress of Clinical Neurophysiology in Berlin in 2014 and as a doctoral thesis entitled “Evaluation kortikobulbärer motorisch evozierter Potentiale während neurochirurgischer Eingriffe” [1,2].

* Corresponding author. Department of Neurosurgery, LMU University Hospital, Campus Grosshadern Marchioninistrasse 15, D-81377, Muenchen, Germany.

E-mail address: Andrea.Szelenyi@med.uni-muenchen.de (A. Szelényi).

1. Introduction

The tongue is innervated by the hypoglossal nerve and is a striate muscle consisting of four intrinsic, intertwined sectors involved in complex, finely tuned movements contributing to airway patency, chewing, swallowing and speech. Various causes,

Abbreviations

| | |
|--------------|---------------------------------------|
| coMEP = | corticobulbar motor evoked potentials |
| DCS = | direct cortical stimulation |
| DTNS = | direct trigeminal nerve stimulation |
| DoCol = | dorsal column |
| DoCoIS = | dorsal column stimulation |
| MNS = | median nerve stimulation |
| SoTR = | somatosensory-evoked tongue reflex |
| TES = | transcranial electric stimulation |
| TN = | trigeminal nerve |
| Tongue-LLR = | tongue long latency response |

e.g. a paresis, contribute to functional impairment of the tongue resulting in obstructive sleep apnea, dysphagia or dysarthria.

Intraoperative neurophysiological monitoring (IONM) of tongue function is of special interest in neurosurgical procedures near the hypoglossal nerve, its nuclei and the corticobulbar pathways. Standard monitoring methods employed are the recording of electromyographic activity (EMG) and of compound muscle action potentials (CMAP) elicited by direct hypoglossal nerve stimulation from intrinsic tongue or genioglossus muscles for localization within the surgical site [3–7]. Corticobulbar motor evoked potentials (coMEP) of the tongue are elicited by transcranial (TES) and direct cortical stimulation (DCS) in order to monitor the corticobulbar pathways [1,8–11]. Preserved tongue-coMEP have been found to be a positive predictor of tongue movement [12]. Tongue-coMEP have also been proposed as aids in rostral control in cervical spine surgery [13].

During the intraoperative routine derivation of tongue-coMEP and tongue-EMG for various neurosurgical procedures in adult patients, we fortuitously observed that both TES and median nerve stimulation (MNS) elicited time-locked late polyphasic responses in the tongue. Multiple reflex circuits in the oropharyngeal region involving the trigeminal and hypoglossal nerves have been described in animals [14,15]. In humans, a trigemino-hypoglossal silent period following palatal mucosa stimulation was described [16]. Moeller et al. observed a “late EMG response of the tongue elicited by transcranial stimulation” of approximately 40 msec latency and classified it as a symptom of hemilingual spasm [17]. Long latency responses have been reported in the cricothyroid muscles elicited by transcranial magnetic stimulation in healthy subjects and by DCS of the caudal opercular part of the inferior frontal gyrus in patients undergoing awake craniotomies; these have been postulated to be part of the articulatory network [11,18,19].

We conducted prospective, exploratory, observational studies to characterize the occurrence of tongue-long latency responses (LLR) elicited by direct trigeminal nerve (DTNS) and dorsal column stimulation (DoCoIS), as well as TES and MNS, in an intraoperative setting and to obtain reference values for their eventual application in intraoperative neurophysiological monitoring.

2. Methods

2.1. Study design and patients

In total, data of 93 adult patients undergoing various neurosurgical procedures for supratentorial and infratentorial tumor removal, trigeminal neuralgia and for cervical intramedullary lesions were analyzed. Data were collected in prospective, exploratory, observational studies, which were approved by each site's

hospital ethical committee (site 1: E 9/07, Frankfurt University, Germany; site 2:701–16, LMU München; site 3: N.710-14122020, Niguarda Hospital, Italy). Patients gave informed consent to use their data.

2.2. Intraoperative methodology

2.2.1. Anesthesia

Muscle relaxants were applied only for intubation. At sites 1 and 2, total intravenous anesthesia was performed with propofol and a medium acting opioid (remifentanyl). At site 3, inhalational agents (Sevoflurane), not exceeding 0.5 minimum alveolar concentration, were titrated to achieve continuous theta activity in the EEG corresponding to a Bispectral Index of 30–45.

2.2.2. Neurophysiological recording and stimulation techniques

The routine IONM methodology in skull base and brainstem surgery consisted of auditory evoked potentials (AEP), bilateral median nerve somatosensory-evoked potentials (SEP), MEP, EMG and direct cranial nerve stimulation. Muscle responses were bilaterally recorded with stainless steel subdermal needle electrodes from hand muscles (abductor pollicis brevis muscles (APB)), facial (orbicularis oculi and oris, nasal, mentalis muscles), masseter and tongue muscles; the vocal cords, throat (levator veli palatini muscles) and limb muscles were added according to surgical needs. For stimulation and recording, commercially available, neurophysiological monitoring devices (ISIS IOM system, Inomed, Emmendingen, Germany (Site 1 and 2) or the NIM Eclipse System, Medtronic, USA (Site 3)) were employed. These multichannel systems allow simultaneous recording of motor responses.

2.2.3. Direct trigeminal nerve stimulation

In the cerebello-pontine angle (CPA) cistern, the exposed roots of the motor and sensory trigeminal nerve (TN) were stimulated with a probe. Two techniques were employed:

- At site 2, single pulse constant current stimulation was performed with a bipolar concentric probe of 2 mm diameter (Inomed Co., Emmendingen, Germany) at a 3 Hz repetition rate, maximum intensity of 0.5 mA and a pulse width of 0.2 msec.
- At site 3, stimulation was performed both with a monopolar probe (1.6 mm in diameter; Spes Medica srl, Genova, Italy) with the return electrode placed at Pz, and with the above described bipolar concentric probe. A train of 3 monophasic pulses of 0.1–0.2 msec individual pulse width, an interstimulus interval (ISI) of 2 msec at a train repetition rate 0.5–1 Hz and an intensity of maximum 3 mA was applied.

The train stimulation technique was used according to the methodology described for the blink reflex (BR) [20,21]. This follows the rationale that stimulation of sensory afferents under conditions of anesthesia would likely elicit reflex responses with a train stimulation modality rather than with single pulses.

2.2.4. Dorsal column stimulation

DoCoIS was applied with the bipolar concentric probe (see details above). In one patient, a double train with an intertrain interval of 60 msec was applied, as is typically proposed for spinal cord mapping [22]. In the other two, a train of 3 cathodal pulses, 0.2–0.4 msec duration, 2 msec ISI, a train repetition rate of 0.5–1 Hz, with an intensity of 3–10 mA was used (slightly modified as described in Ref. [22]).

2.2.5. Transcranial electric stimulation

For TES, corkscrew electrodes (Inomed Co., Emmendingen, Germany) were placed at C1, C2, C3, C4 and Cz, allowing stimulating electrode montages for interhemispheric and hemispheric stimulation [23]. MEP were evoked with an anodal train of 4–5 consecutive pulses of individual pulse width of 0.5 msec, with an ISI of 2–4 msec, a train repetition rate of 0.5 Hz and a stimulation intensity of maximum 250 mA. To distinguish peripherally elicited CMAP from true corticobulbar MEP (coMEP), a single pulse TES (same pulse width and stimulating electrode montage) was applied before the train stimulation [9,24]. This method diverges from current literature and was used due to technical constraints.

2.2.6. Median nerve stimulation

MNS was performed with subdermal needle electrodes at the wrist, using monophasic pulses of 0.2–0.5 msec and a maximum intensity of 50 mA, resulting in a CMAP of the corresponding APB >0.5 mV.

2.3. Recordings of tongue muscle responses

Pairs of stainless-steel needle electrodes (24 mm length, Spes Medica srl., Italy) were placed at an angle of 20–30° in the lateral aspect of each side of the tongue. These needles are most frequently inserted into the superior longitudinal or transverse muscle and were intended to representatively record activity from all intrinsic and genioglossus muscles (hereafter, “tongue muscle”). Tongue muscle responses were recorded with a sweep length of 100–200 msec and a hard-ware filter setting of 0.5–2000 Hz with a sampling rate of 20000 Hz. For MEP, a sweep length of 200 msec and a hardware filter setting of 0.5–2000 Hz with a sampling rate of 20000 Hz was applied.

For DTNS, TES and MNS, muscle recordings were set to obtain concurrent responses from ipsilateral masseter, bilateral tongue, facial and throat and APB muscles, corresponding to a minimum of 9 multichannel derivations. In DoCoLS, muscle recordings were set to concurrently obtain responses from bilateral tongue and limb muscles according to the level of surgery.

2.4. Study conduct

2.4.1. DTNS

Data (sites 2 and 3) were collected during intraoperative CPA procedures. At the surgeon's discretion, DTNS was performed to identify the TN within the CPA cistern. The occurrence of tongue-LLR was described.

2.4.2. DoCoLS

Data (site 3) were collected in intramedullary spinal cord surgery while stimulating the exposed dorsal aspect of the spinal cord.

2.4.2.1. TES elicited tongue-LLR. During supra- and infratentorial neurosurgical procedures performed at site 1, studies concerning the frequency and relation to TES-stimulation paradigms of facial, pharyngeal, and tongue muscle coMEP, as well as tongue-LLR elicited by TES were prospectively and systematically conducted and data collected.

2.4.2.2. Tongue-LLR elicited by TES and median nerve stimulation. During infratentorial neurosurgical procedures at site 2, the latencies and duration of tongue-LLR elicited by TES were prospectively and systematically collected and described to confirm the data obtained at site 1. MNS-triggered tongue-LLR were studied in those patients in whom TES-triggered tongue-LLR were present.

3. Data analysis

Descriptive statistical analysis was performed on patients' characteristics. Late responses were those that had the features of a reflex response with polyphasia and latency far exceeding the range of tongue coMEP or the peripheral CMAP. As reference value, we chose the latency of 4.1 ± 0.6 msec, which results from stimulating the hypoglossal nerve near the root exit zone on the brainstem, as this would be the most proximal site of “peripheral” stimulation [25]. Data were analyzed for latency, duration and side of occurrence. Three consecutive responses were used to calculate the means. Data of ipsi- and contralateral responses were each grouped (TES, MNS).

- 1) DTNS: We analyzed data only from those patients in whom the stimulation of the trigeminal nerve clearly elicited a masseter muscle CMAP (≤ 5 msec; [26]) and tongue-LLR were observed.
- 2) DoCoLS: As tongue-LLR we considered polyphasic long latency responses that followed DoCoLS of the spinal cervical level C4 – C6.
- 3) TES: Polyphasic tongue muscle responses that extended beyond tongue-coMEP latency ranges of 11.5 msec [13] were considered late responses. At site 1, analysis focused on TES-parameters (intensity, stimulation montages and ISI) and the frequency of tongue-coMEP and tongue-LLR. At site 2, analysis focused on the characteristics of tongue-LLR (latency, duration).
- 4) MNS: As tongue-LLR, we described tongue responses by MNS, that showed polyphasic morphology and a minimum onset latency of 30 msec.

4. Results

4.1. Tongue-LLR elicited by trigeminal nerve stimulation

Tongue-LLR following direct trigeminal stimulation (DTNS) were studied in 13 patients (eight patients from site 3: 5 male, age 52.5 ± 14.8 , median age 55 years, age range 18–68 years) undergoing neurosurgical treatment of lesions within the infratentorial compartment (Table 1). DTNS of the TN sensory root resulted only in tongue-LLR with a mean latency of 20.2 msec (Fig. 1A, Table 2), whereas the stimulation of the motor root elicited CMAP strictly in the masseter muscle (Fig. 1B). Responses were strongly ipsilateral in all patients.

4.2. Tongue-LLR elicited by dorsal column stimulation

Tongue-LLR were observed in 3/3 patients during DoCoL stimulation at the cervical levels C4 – C6. The patients (one male, age 58.7 ± 12.7 years, median age 61 years, age range 45–70 years) underwent neurosurgical removal of a cervical intramedullary cavernous angioma (one patient) or ependymoma (2 patients). The mean latencies of ipsilateral tongue-LLR were 25.9 ± 1.6 msec; the latencies of contralateral tongue-LLR were 25.1 ± 4.2 msec (Fig. 2).

4.3. Tongue-LLR elicited by TES

Data of 66 patients (site 1, 38 female, mean age 52 ± 13.9 , age range 19–79 years) undergoing various neurosurgical procedures (see Table 3 for patients' characteristics) were analyzed. Contralateral tongue-coMEP were elicited in 42/66 (63.6%) patients with a stimulation intensity of 110.6 ± 28.1 mA; tongue-LLR were observed in only 16/66 (24.2%). Interestingly, the average stimulation intensity required in order to elicit tongue-LLR was only 89.1 ± 32.3 mA. Data were grouped, as no statistical difference

Table 1
Characteristics of 13 patients with tongue-LLR elicited by direct trigeminal nerve stimulation.

| Location | Pathology | n |
|-------------------------|--|---|
| Cerebello pontine angle | Vestibular schwannoma | 2 |
| | Epidermoid | 1 |
| | Microvascular decompression for trigeminal neuralgia | 5 |
| Petroclival | Meningioma | 2 |
| Petrosal | Meningioma | 1 |
| Pontine | Cavernoma | 2 |

existed between contralateral and ipsilateral responses following right and left hemispheric as well as interhemispheric stimulation. Overall, midline interhemispheric stimulation (C1-anodal/C2-cathodal and C2-anodal/C1-cathodal) elicited tongue-LLR in 12/66 (18.2%) patients with both an ISI of 2 and 4 msec. Lateral interhemispheric (C3-anodal/Cz-cathodal and C4-anodal/Cz-cathodal) stimulation elicited tongue-LLR with an ISI of 2 msec in 13/66 (19.7%) patients and with an ISI of 4 msec in 14/66 (21.2%) patients. The mean latencies obtained with an ISI of 2 msec were 50 ± 10 msec, for an ISI of 4 msec 52 ± 12 msec, with no statistical difference.

4.4. Tongue-LLR elicited by TES and median nerve stimulation

Data of 11 patients (site 2; 8 female, mean age 51.1 ± 11.8 , 31–72 years) undergoing neurosurgical procedures for microvascular decompression (trigeminal neuralgia (three patients), hemifacial spasm (one patient)), tumor resection within the vicinity of the CPA (vestibular schwannoma in three patients, and an epidermoid) as well as petroclival meningioma, foramen magnum meningioma and cervical intramedullary hemangioblastoma (one each) were eligible for analysis. TES elicited contralateral tongue-LLRs with a mean onset of 55.3 msec and ipsilateral tongue-LLR of 54.9 msec (Table 4, Fig. 3). Left hemispheric TES elicited ipsilateral tongue-LLR in all 11 patients and contralateral in 10/11 (91%) patients; right hemispheric TES elicited ipsilateral responses in 10/11 (91%) patients and contralateral in 9/11 (82%) patients; the results indicated no significant statistical differences. We observed no habituation.

In 10 patients, MNS was performed at each wrist and elicited ipsilateral tongue-LLR with a mean onset 37.8 ± 4.7 msec and contralateral tongue-LLR with a mean onset of 40.3 ± 3.5 msec (Table 5, Fig. 4A and B). Left MNS elicited ipsilateral tongue-LLR in 7/10 patients but contralateral tongue-LLR in only 5/10 patients. Right MNS elicited ipsi- and contralateral tongue-LLR in 9/10 patients.

4.5. Summary of results

This is the first comprehensive presentation and analysis of the multiple occurrence of polyphasic tongue-LLR, under conditions of anesthesia, elicited by DTNS, DoCoIS, TES and MNS. We found that tongue-LLR latencies vary according to the stimulation site: the longest at more than 50 msec by TES, more than 30 msec for MNS; the shortest following stimulation of the sensory root of the TN at 20 msec. Comprehensive overviews of the stimulation sites, long latency responses and reflexes in the tongue are provided in Table 6.

5. Discussion

Our data demonstrates four types of tongue-LLR obtained intraoperatively in different patient cohorts at three hospitals, recorded with various neurophysiological devices [2]. The common end-organ, the tongue muscle, is neither indicative for the same origin of the responses and their underlying reflex arches, nor for the involvement of identical brainstem nuclei.

5.1. Trigeminal stimulation elicited tongue-LLR

It is our understanding that this is the first description of tongue-LLR elicited by DTNS in humans, most probably due to a polysynaptic brain stem reflex, with the afferent arc provided by the sensory fibers of the TN and the efferent arc provided by the hypoglossal nerve motor fibers. This may correspond to the trigemino-hypoglossal reflexes elicited by activation of trigeminal

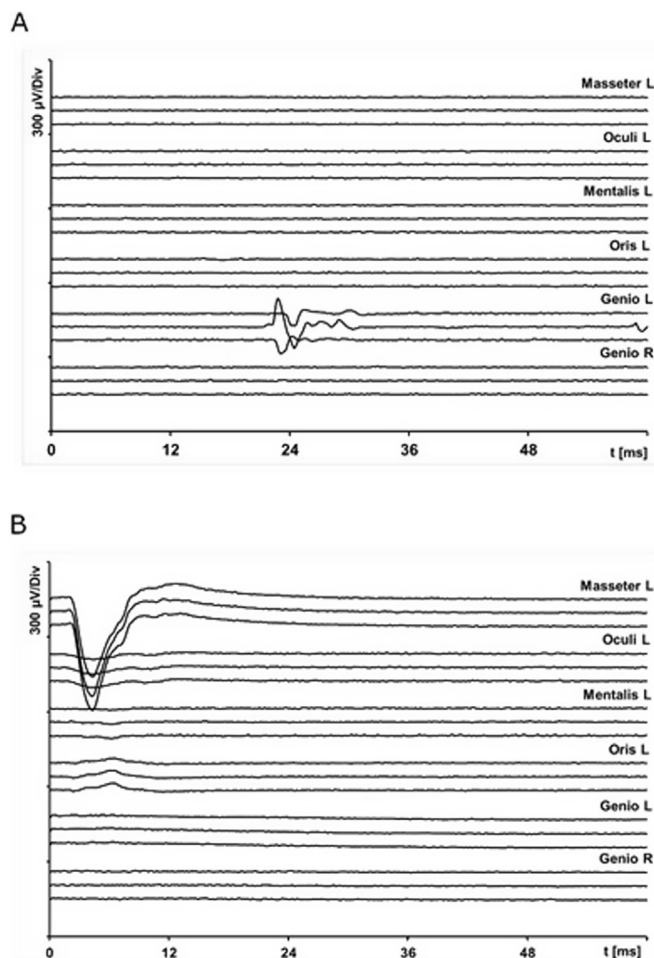


Fig. 1. A and B Concurrent recordings of left sided masseter, orbicularis oculi, mentalis, orbicularis oris and bilateral tongue (indicated as “genio”) muscles following left direct trigeminal nerve stimulation (0.2 mA; 0.2 msec pulse width, bipolar concentric probe). Stimulation of (A) the left sensory root of the trigeminal nerve eliciting late responses in the ipsilateral tongue; and (B) motor root of the trigeminal nerve eliciting CMAP in the masseter muscle.

Table 2
Trigeminal nerve stimulation elicited masseter muscle CMAP and tongue-long latency responses.

| n = 13 | masseter CMAP | | ipsilateral tongue-LLR | |
|------------|----------------|----------------|------------------------|----------------------|
| | latency [msec] | latency [msec] | duration [msec] | amplitude [μ V] |
| mean/stdev | 3.0 \pm 0.6 | 20.2 \pm 3.3 | 21.4 \pm 7.3 | 158.4 \pm 90.2 |
| median | 3 | 19.2 | 22.4 | 145 |
| range | 1.9–4 | 16.8–27.4 | 12.3–33.1 | 57.7–350 |

CMAP = compound muscle action potential; LLR = long latency response; stdev = standard deviation.

afferents described in humans and animals [27–29]. Trigemino-hypoglossal projections are the essential players in the coordination of mastication, swallowing and breathing [30]. In the cat, anatomical and neurophysiological methods confirmed fiber-connections between the spinal trigeminal nucleus and the juxta-trigeminal reticular formation, from which region interneurons connect to the hypoglossal nucleus [31]. Studies in rats also support the assumption of neuronal fiber connections between spinal trigeminal nucleus, receiving facial nociceptive fibers, and hypoglossal motor nuclei [32]. Stimulation of the upper trigeminal branch (V1) mediates the BR without any related activity within the tongue muscles. However, in the awake human subject mucosal stimulation (lingual nerve, mandibular trigeminal branch (V3)) results in an R1-like response of 12.5 msec latency within the genioglossus muscle, for which the term “tongue reflex” was coined [29]. The latency of this tongue reflex was 8 msec shorter compared to the tongue-LLR in our study (12.5 vs. 20 msec), which could be an effect of anesthesia. It is also possible to speculate that different sensory fibers are activated, and the latency of 20 msec is a result of the involvement of slow conducting C-fibers within the sensory trigeminal root. It is also interesting that the recording of tongue-LLR was not accompanied by cardiovascular reactions, which may indicate a conduction via vagal or glossopharyngeal efferents.

An inhibitory reflex elicited by palatal stimulation in healthy subjects and patients with brainstem lesions leading to suppression of tongue muscle activity with a latency of 30 msec and a duration of 30 msec has been termed “trigeminal hypoglossal silent period” [16]. Comparable inhibitory reflexes are also reported in animals [14,33,34]. As we observed the trigemino-hypoglossal reflex under anesthesia without muscle preinnervation, we do not consider an inhibitory reflex as an underlying mechanism.

5.2. Dorsal column stimulation elicited tongue-LLR

The technique of DoCoIS for determination of the dorsal raphe [35,36] or for spinal cord mapping [22] was introduced for safe

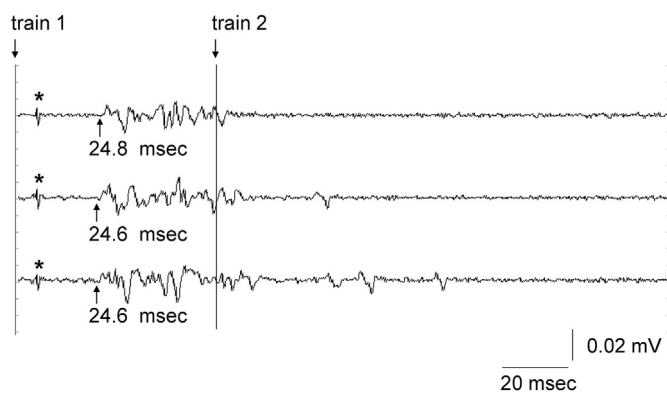


Fig. 2. Left ipsilateral tongue long latency responses following double train stimulation (3 mA, train of three pulses, 0.4 msec duration, interstimulus interval 2 msec, intertrain interval 60 msec) of the left cuneate tract of the dorsal columns at C5 level. The first train stimulus artifact is incompletely suppressed and only the last pulse is visible (*).

resection of intramedullary spinal cord tumors (imSCT). Our new findings indicate the occurrence of reflex responses rostral to the stimulation site.

Hypoglossal nerve injury related to an anterior cervical discectomy at cervical levels 3 and 4 not only induced an ipsilateral tongue atrophy but also hypesthesia of the ipsilateral lower face (V3), sparing other trigeminal functions [37]. In cats, there are supporting data about reflex arches connecting upper cervical roots, DoCoI and hypoglossal motor nuclei: stimulation of high cervical roots, C2 and C3, elicits activity in hypoglossal nerve [38,39]. In the rat, muscle afferents mediating via C1 to C4 terminate within the intermedius nucleus of the medulla, further projecting to the hypoglossal nucleus [39]. In human, perihypoglossal nuclei, nucleus of Roller and nucleus intercalatus might have the same connections and might explain our observations, although the involvement of the spinal trigeminal nucleus cannot be ruled out. Future studies are needed to describe the DoCoIS related tongue-LLR.

5.3. TES elicited tongue-LLR

To date, there is only one published description in humans of TES-elicited tongue-LLR [17] as well as a series of observations by J. Sarnthein (personal communication, 2021). Nevertheless, transcranial magnetic brain stimulation and DCS of the frontal operculum elicited LLR in laryngeal muscles in humans [40,41]. These cricothyroid-LLR have latencies of about 55 msec, which are comparable to the tongue-LLR we have reported. Because the tongue-LLR are so large and prominent, we assume that our reported LLR are generated in the tongue itself. Further evidence that the observed responses are not far-field activity is the fact that in some patients we recorded tongue LLR purely unilaterally.

Deletis et al. proposed an underlying pathway between the caudal opercular part of inferior frontal gyrus serving as premotor cortex for laryngeal muscles to the laryngeal representation area of M1, essential for initiation of the laryngeal motor program [41]. As this study was performed in awake human subjects and patients, recordings in tongue-muscles were not performed. We assume that tongue-LLRs are distinctly different from cricothyroid-LLRs, the latter playing an important role in human vocal control [11].

Moller and Osburn reported TES-elicited late and polyphasic EMG responses recorded from the tongue in a patient with a hemilingsual spasm undergoing neurosurgical microvascular hypoglossal nerve decompression [17,42]. Neural activity reverberating between chains of interneurons and hypoglossal motor neurons, necessary for exceeding the discharge threshold of motor neurons, was proposed as underlying mechanism [17]. Indeed, TES might elicit trigeminal sensory afferents and mediate tongue-LLR via multiple and complex reflex pathways of trigemino-hypoglossal projections. The morphology of the tongue-LLR closely resembles the R2 component of the BR and the laryngeal adductor reflex (LAR). In general anesthesia, only technical refinement with multipulse stimulation enables eliciting the R1 component of the BR, but only rarely the R2 component, which

Table 3
Characteristics of 66 patients with TES elicited tongue-LLR (study site 1).

| Supratentorial (n = 40) | location | frontal | 20 |
|-----------------------------------|-----------|-----------------------------|----------|
| | | | parietal |
| | | sella region | 4 |
| | | temporal | 5 |
| | pathology | intraventricular | 2 |
| | | intrinsic brain tumor | 18 |
| | | meningioma | 13 |
| | | metastasis | 5 |
| | | craniopharyngeoma | 2 |
| | | neurocytoma | 1 |
| | | sarcoma | 1 |
| Infratentorial (n = 23) | location | cerebello pontine angle | 8 |
| | | petroclival | 5 |
| | | IVth ventricle | 6 |
| | | tentorium | 3 |
| | pathology | Cerebral peduncle | 1 |
| | | meningioma | 9 |
| | | vestibular schwannoma | 4 |
| | | ependymoma | 4 |
| | | epidermoid | 2 |
| | | microvascular decompression | 2 |
| Cerebral aneurysm surgery (n = 3) | location | middle cerebral artery | 1 |
| | | anterior cerebral artery | 1 |
| | | vertebral artery | 1 |

habituates during repeated stimulation [20]. However, the LAR, entirely mediated by the vagal nerve, can be reliably elicited with one pulse or double pulse stimulation under general anesthesia, its ipsilateral R2 latency is 59 msec and contralateral slightly longer with 61 msec [43]. The LAR is now widely used for monitoring of the vagal nerve and its brainstem pathways [44–47]. We emphasize that TES and MNS elicited tongue-LLR did not habituate, which would be a strong indicator against a polysynaptic reflex. On the other hand, a life-sustaining reflex might be more resistant against anesthesia and habituation. When observing tongue-LLR, patients do not show any evidence of emerging from anesthesia, such as episodes of tachycardia, elevation of blood pressure or face respective pharyngeal muscle activity, which would make a vagal nerve mediated reflex activity less likely. In awake humans, painful stimulation of the protruded tongue elicited a rapidly habituating tongue muscle reflex activity with a latency of 25–40 msec and lasting for approximately 15–50 msec duration (Table 6) [48], most likely mediated by trigeminal afferents.

TES directly activates face, pharyngeal, neck and shoulder muscles. Such TES related masseter contraction might lead to jaw closure and timely retropulsion of the tongue, resembling the “tongue-jaw reflex” [14]. As neither masseter coMEP nor CMAP was observed when we recorded tongue-LLR, we consider the tongue-jaw reflex an unlikely explanation.

In an intubated patient, the oro-pharyngeal space is narrowed by the airway-tube, a gauze (used as bite-block), anteflexion of the head, receding of the tongue and the blockade of the lower airway. The “negative airway pressure related genioglossus reflex” could be considered as a possible causal mechanism (Table 6) [49]: TES

related contractions of the pharyngeal muscles might induce a brief negative airway pressure within the upper pharyngeal space, which results in a propulsion of the tongue by contraction of the genioglossus muscle. This reflex persists during sleep, although it has an earlier onset latency (23 vs. 26 msec) and shorter duration (16 vs. 23 msec) compared with wakefulness [50]. As this reflex is essential for airway patency and therefore life sustaining, it is more likely to be present during anesthesia compared to other polysynaptic brainstem reflexes or even speech related complex motor responses. This “negative upper airway pressure reflex” or “genioglossus-reflex” is either trigeminally (nasopharyngeal space) or vagally mediated (laryngeal space) [51]. As the genioglossus reflex is suppressed by local anesthetics, superficial mechanoreceptors or chemoreceptors might play the essential role [49].

We acknowledge that the underlying pathways of the TES-related tongue-LLR are currently unknown and that studies are needed to further understand the mechanism of the TES-related tongue-LLR.

5.4. Median nerve stimulation elicited tongue-LLR

Trigeminal sensory, facial and hypoglossal motor nuclei are connected for the conduction of voluntary and reflex activity of complex oro-facial and pharyngeal movements. For this newly described tongue-LLR elicited by electrical stimulation of peripheral median nerve, we propose the term “somatosensory-evoked tongue response” (SoTR). This might be analogous to median nerve elicited BR, which is enhanced when stimulating the median nerve with a hand position close to the face and is interpreted as

Table 4
Tongue responses elicited by transcranial electric stimulation in 11 patients.

| Contralateral tongue coMEP | | contralateral tongue-LLR | | | | ipsilateral tongue-LLR | | | |
|----------------------------|----------------|--------------------------|----------------|---------------|----------------|------------------------|----------------|-----------------|----------------|
| latency [msec] | amplitude [μV] | stim. Intensity [mA] | latency [msec] | duration [ms] | amplitude [μV] | stim. Intensity [mA] | latency [msec] | duration [msec] | amplitude [μV] |
| mean 14.1 ± 1.9 | 206.6 ± 298 | 106.9 ± 32.3 | 55.3 ± 10.2 | 36.9 ± 14.5 | 65.8 ± 62.2 | 98.0 ± 12.4 | 54.9 ± 12 | 57 ± 79.2 | 96.5 ± 95.4 |

coMEP = corticobulbar muscle evoked potential; LLR = long latency response; stim. = stimulation.

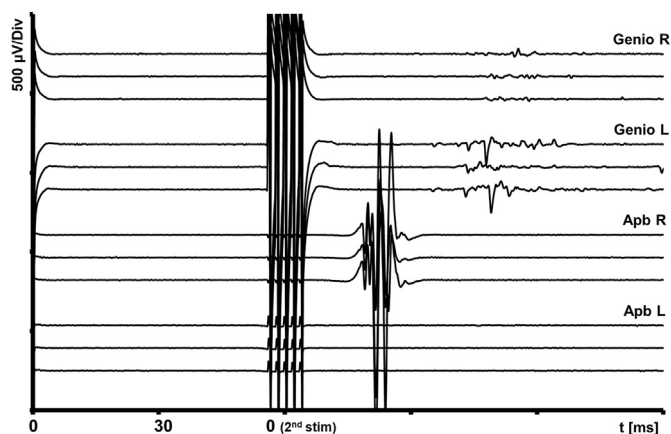


Fig. 3. Left hemispheric TES (C3-anodal – Cz-cathodal, 150 mA stimulation intensity; double train stimulation with first one pulse and then a train of five pulses, intertrain-interval 60 msec) elicited concurrent motor evoked potentials from right abductor pollicis brevis (Apb) and bilateral tongue long latency responses (“genio”) without eliciting tongue coMEP.

“defensive” of the peripersonal space [52,53]. This also resembles human behavior of touching the face when experiencing facial pain. Currently, we know neither the physiological role nor the exact reflex circuits of the SoTR, though it may be related to oropharyngeal pain or food-intake. The long latency implies a complex circuitry located within the brainstem where cutaneous afferents of peripheral sensory nerve fibers targeting the cuneate nucleus are likely connected via trigeminal spinal nuclei to the hypoglossal motor nuclei.

6. Future perspectives

From the standpoint of intraoperative neuromonitoring, tongue-LLR elicited by DTNS or cervical DoCoLS can serve as an additional tool for the assessment of both trigeminal sensory and hypoglossal motor nerve integrity. As such, we recommend using a sweep-length of at least 100 msec for recording. Future studies are needed to evaluate whether the recording of tongue-LLR may become a new method to assess the central connection of the trigeminal root in brainstem surgery as mutual adjunct to trigeminal somatosensory-evoked potentials or trigeminal nerve potentials. Further investigation into the SoTR is necessary, but in future, this might play a role in IONM of the cervicomedullary junction and in the assessment of the integrity of the hypoglossal pathway in neck surgery. TES elicited tongue-LLR should not be mistaken as coMEP, which are of shorter latency and duration with less polyphasic morphology. Whether their intraoperative alteration or loss is indicative for postoperative, neurological sequelae must be determined in future studies.

Table 5
Median nerve stimulation elicited ipsi- and contralateral tongue-LLR - “somatosensory-TR”.

| Amount of responses | Ipsilateral tongue-LLR responses | | | Contralateral tongue-LLR responses | | |
|---------------------|----------------------------------|-----------------|----------------|------------------------------------|-----------------|----------------|
| | 16/20 MNS | | | 14/20 MNS | | |
| | Latency [msec] | Duration [msec] | Amplitude [µV] | Latency [msec] | Duration [msec] | Amplitude [µV] |
| Mean | 37.8 ± 4.7 | 51.1 ± 22.5 | 126.3 ± 99.6 | 40.3 ± 3.5 | 37.8 ± 12.5 | 44.6 ± 61.4 |
| Min | 29.30 | 25 | 6 | 33 | 14 | 3 |
| Max | 43.3 | 102 | 360 | 46 | 64 | 233 |

MNS = Median nerve stimulation, LLR = long latency response.

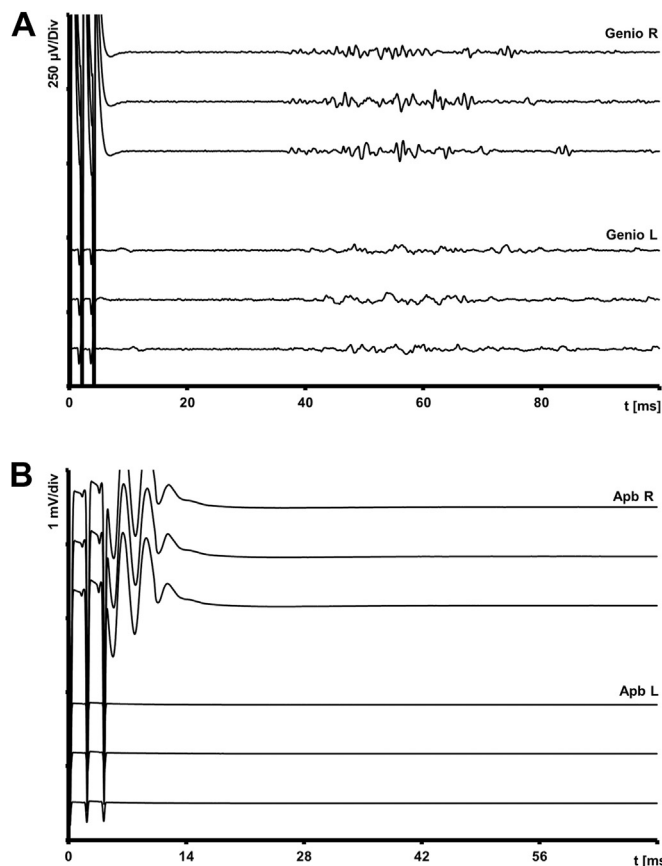


Fig. 4. A and 4B Somatosensory-evoked tongue reflex in bilateral tongue muscles (“genio”) elicited by right median nerve stimulation (train of 3 pulses, 0.2 msec pulse width, 50 mA stimulation intensity) (A) and concurrent recording of compound muscle action potential of right abductor pollicis brevis muscle (B).

7. Conclusion and significance

Here, we provide evidence that the common target organ “tongue” is involved in multiple polysynaptic brainstem mediated pathways (Fig. 5). For the first time, we describe the “somatosensory-evoked tongue reflex” elicited by transcutaneous MNS. Hypoglossal motoneurons seem to respond via polysynaptic connections to trigeminal and cutaneous afferents from the hand. The TES related and very robust tongue-LLR remains unclear and might be trigeminally mediated. Another hypothesis could be its involvement in the negative airway pressure reflex mediated by the vagal nerve. We propose that our data will aid the interpretation of intraoperative recordings in the tongue muscle and may expand the role of such recordings in the neuromonitoring of brainstem and cervical cord surgeries.

Table 6
Comprehensive overview over Tongue-LLR and tongue related brainstem responses in humans.

| Stimulation site | Type of stimulation | Author | Conditions | Recording site | Latency ipsi [msec mean] | Latency contra [msec; mean] | Coined term |
|-------------------------------|--------------------------|--------------------------------|--------------|----------------|--------------------------------------|-----------------------------|--|
| TN, mucosal afferents | Mucosal ES | Maisonobe, 1998 | awake | Tongue | 12.5 | No response | Mucosal trigeminal–hypoglossal reflex* |
| TN, CPA | Direct nerve ES | This study | anesthesia | Tongue | 20 | No response | Trigemino – hypoglossal reflex |
| Dorsal column | Direct ES | This study | anesthesia | Tongue | 26 | 25 | To be termed |
| Median nerve | Transcutaneous ES | This study | anesthesia | Tongue | 38 | 40 | Somatosensory elicited tongue response |
| Various montages [§] | Transcranial ES | This study | anesthesia | Tongue | 54 | 55 | TES-elicited tongue LLR |
| | Transcranial ES | Møller, 2009 | anesthesia | Tongue | 40 | Not reported | Related to hemilingual spasm |
| | Transcranial ES | Sarnthein, pers. communication | anesthesia | Tongue | 51 (lateral TES) 54 (midline TES) | | To be termed |
| Pharynx | Negative airway pressure | Eckert, 2007 | awake asleep | Genioglossus | 26 | | Genioglossus reflex |
| Pharynx | Negative airway pressure | White, 1998 | awake | Genioglossus | 59 | | Genioglossus reflex |
| Tongue | Tongue ES | Braztlavsky, 1974 | awake | Genioglossus | 25 – 40 | 25 - 40 | Exteroceptive reflex |

[§] C3/C4 and C1 /C2 and vice versa, as C3/Cz and C4/Cz, * The term “tongue-reflex” was also used; [§] local anesthesia, grey shaded rows: this study; TN = trigeminal nerve, CPA = cerebello-pontine angle, ES = electrical stimulation, LLR = long latency response

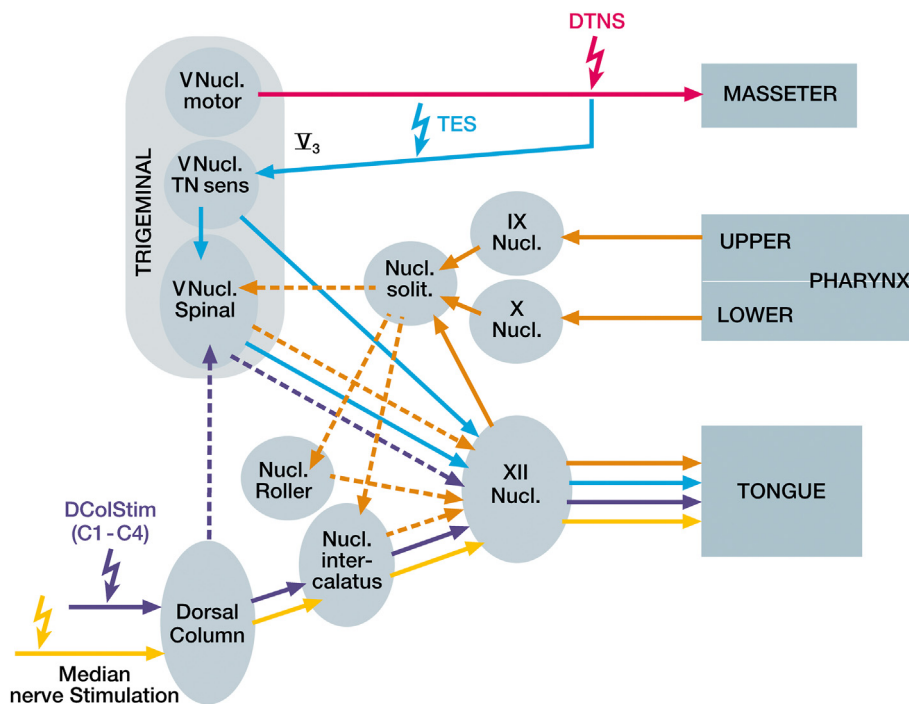


Fig. 5. Schematic map of the proposed brainstem circuits underlying the tongue responses from DTNS, DoCoLS, TES and MNS. DTNS of the trigeminal motor root (magenta) activates the masseter muscle, but DTNS of the sensory fibers (blue) recruits a relatively short latency connection to the XII nucleus mediating the “trigemino-hypoglossal-reflex”. DoCoLS (violet) may parallel the MNS pathways in SoTR, but may possibly recruit the V nucleus spinalis, adjacent to the cuneate nucleus. TES: The brainstem reflex-circuits involved in TES-elicited tongue-LLR are largely unknown. Two hypotheses are illustrated: 1. Direct activation of the trigeminal cutaneous afferents (blue), reverberating within complex reflex pathways projecting to XII nucleus; 2. Induction of the negative upper airway pressure reflex (orange), i.e. a contraction of the pharyngeal wall inducing a genioglossus reflex for airway patency mediated by the vagal nuclei. MNS (yellow) is involved in the “somatosensory-evoked tongue reflex” (SoTR), possibly mediated via premotor nuclei to the XII nucleus. Abbreviations and color scheme: DTNS = direct trigeminal nerve stimulation; DoCoLS = dorsal column stimulation; LLR = long latency response; TES = transcranial electric stimulation; MNS = Median Nerve Stimulation; blue = sensory trigeminal mediated; magenta = motor trigeminal mediated; orange = glossopharyngeal/vagal mediated via the solitary nucleus; violet = dorsal column afferents via trigeminal mediated connections (dotted line) or nucleus intercalatus (solid line), yellow = pathways related to the somatosensory-evoked tongue reflex” (SoTR).

Author contribution

AS and EF designed and performed the recordings, analyzed data and created figures, discussed and wrote the manuscript.

Funding

No funding was granted for this study.

Declaration of competing interest

AS is member of the inomed scientific advisory board and has received speaker fees for giving presentations at Arkana, an inomed based in-house course provider on IONM.

Acknowledgement

We would like to thank Renate Diener-Gluczak for the illustrations, Stan Skinner and Tobias Greve for their thorough reading and critical discussion of the manuscript.

References

- [1] Dittrich LM. Evaluation kortikobulbärer motorisch evozierter Potentiale während neurochirurgischer Eingriffe. *Human Medicine*. Dissertation. Germany: Johann Wolfgang Goethe Universität Frankfurt; 2012. p. 118. Frankfurt am Main, Germany.
- [2] Szelenyi A, Fava E. P167: late tongue responses elicited by transcranial electric stimulation and peripheral median nerve stimulation. *Clin Neurophysiol* 2014;125:S91. [https://doi.org/10.1016/s1388-2457\(14\)50305-7](https://doi.org/10.1016/s1388-2457(14)50305-7).
- [3] Romstock J, Strauss C, Fahlbusch R. Continuous electromyography monitoring of motor cranial nerves during cerebellopontine angle surgery. *J Neurosurg* 2000;93(4):586–93. <https://doi.org/10.3171/jns.2000.93.4.0586>.
- [4] Sala F, Krzan MJ, Deletis V. Intraoperative neurophysiological monitoring in pediatric neurosurgery: why, when, how? *Childs Nerv Syst* 2002;18(6–7):264–87. <https://doi.org/10.1007/s00381-002-0582-3>.
- [5] Sala F, Lanteri P. Brain surgery in motor areas: the invaluable assistance of intraoperative neurophysiological monitoring. *J Neurosurg Sci* 2003;47(2):79–88.
- [6] Jahangiri FR, Minhas M, Jane Jr J. Preventing lower cranial nerve injuries during fourth ventricle tumor resection by utilizing intraoperative neurophysiological monitoring. *Neurodiagn J* 2012;52(4):320–32.
- [7] Slotty PJ, Abdulazim A, Kodama K, Javadi M, Hanggi D, Seifert V, et al. Intraoperative neurophysiological monitoring during resection of infratentorial lesions: the surgeon's view. *J Neurosurg* 2017;126(1):281–8. <https://doi.org/10.3171/2015.11.JNS15991>.
- [8] Akagami R, Dong CC, Westerberg BD. Localized transcranial electrical motor evoked potentials for monitoring cranial nerves in cranial base surgery. *Neurosurgery* 2005;57(1 Suppl):78–85. <https://doi.org/10.1227/01.neu.0000163486.93702.95>; discussion 78–85.
- [9] Dong CC, MacDonald DB, Akagami R, Westerberg B, Alkhani A, Kanaan I, et al. Intraoperative facial motor evoked potential monitoring with transcranial electrical stimulation during skull base surgery. *Clin Neurophysiol* 2005;116(3):588–96. <https://doi.org/10.1016/j.clinph.2004.09.013>.
- [10] Deletis V, Fernandez-Conejero I, Ulkatan S, Costantino P. Methodology for intraoperatively eliciting motor evoked potentials in the vocal muscles by electrical stimulation of the corticobulbar tract. *Clin Neurophysiol* 2009;120(2):336–41. <https://doi.org/10.1016/j.clinph.2008.11.013>.
- [11] Deletis V, Fernandez-Conejero I, Ulkatan S, Rogic M, Carbo EL, Hiltzik D. Methodology for intra-operative recording of the corticobulbar motor evoked potentials from cricothyroid muscles. *Clin Neurophysiol* 2011;122(9):1883–9.
- [12] Sala F, Manganotti P, Tramontano V, Bricolo A, Gerosa M. Monitoring of motor pathways during brain stem surgery: what we have achieved and what we still miss? *Neurophysiol Clin* 2007;37(6):399–406.
- [13] Kim DG, Jo SR, Youn M, Hyun SJ, Kim KJ, Jahng TA, et al. Corticobulbar motor evoked potentials from tongue muscles used as a control in cervical spinal surgery. *Clin Neurophysiol Pract* 2017;2:124–9. <https://doi.org/10.1016/j.cnp.2017.05.003>.
- [14] Luo P, Zhang J, Yang R, Pendlebury W. Neuronal circuitry and synaptic organization of trigeminal proprioceptive afferents mediating tongue movement and jaw-tongue coordination via hypoglossal premotor neurons. *Eur J Neurosci* 2006;23(12):3269–83. <https://doi.org/10.1111/j.1460-9568.2006.04858.x>.
- [15] Miller AJ. Oral and pharyngeal reflexes in the mammalian nervous system: their diverse range in complexity and the pivotal role of the tongue. *Crit Rev Oral Biol Med* 2002;13(5):409–25. <https://doi.org/10.1177/154411130201300505>.
- [16] Urban PP. Trigeminal-hypoglossal silent period: a pontomedullary brainstem reflex. *Muscle Nerve* 2015;51(4):538–40. <https://doi.org/10.1002/mus.24349>.
- [17] Moller AR, Osburn LL, Cohen-Gadol AA. Hemilingual spasm: pathophysiology. *Neurosci Lett* 2009;461(2):76–9. <https://doi.org/10.1016/j.neulet.2009.05.081>.
- [18] Amassian VE, Anziska BJ, Cracco JB, Cracco RQ, Maccabee PJ. Focal magnetic coil excitation of frontal cortex activates laryngeal muscles in man. In: *J Physiol*. Proceedings of the Physiological Society, 6–7 November 1987, Mill Hill Meeting; 1988. <https://doi.org/10.1113/jphysiol.1988.sp017061>. 9–68; 41 P.
- [19] Aydinlar EI, Dikmen PY, Kocak M, Sahillioglu E, Pamir MN. Intraoperative motor speech mapping under general anesthesia using long-latency response from laryngeal muscles. *Clin Neurol Neurosurg* 2020;190:105672. <https://doi.org/10.1016/j.clineuro.2020.105672>.
- [20] Deletis V, Urriza J, Ulkatan S, Fernandez-Conejero I, Lesser J, Misita D. The feasibility of recording blink reflexes under general anesthesia. *Muscle Nerve* 2009;39(5):642–6. <https://doi.org/10.1002/mus.21257>.
- [21] Fernandez-Conejero I, Ulkatan S, Sen C, Deletis V. Intra-operative neurophysiology during microvascular decompression for hemifacial spasm. *Clin Neurophysiol* 2012;123(1):78–83.
- [22] Deletis V, Seidel K, Sala F, Raabe A, Chudy D, Beck J, et al. Intraoperative identification of the corticospinal tract and dorsal column of the spinal cord by electrical stimulation. *J Neurol Neurosurg Psychiatry* 2018;89(7):754–61. <https://doi.org/10.1136/jnnp-2017-317172>.
- [23] MacDonald DB. Overview on criteria for MEP monitoring. *J Clin Neurophysiol* 2017;34(1):4–11. <https://doi.org/10.1097/WNP.0000000000000302>.
- [24] Deletis V, Fernandez-Conejero I. Intraoperative monitoring and mapping of the functional integrity of the brainstem. *J Clin Neurol* 2016;12(3):262–73. <https://doi.org/10.3988/jcn.2016.12.3.262>.
- [25] Liscić RM, Morota N, Deletis V. Intramedullary stimulation of the facial and hypoglossal nerves: estimation of the stimulated site. *Croat Med J* 2000;41(4):384–8.
- [26] Minahan RE, Mandir AS. Neurophysiologic intraoperative monitoring of trigeminal and facial nerves. *J Clin Neurophysiol* 2011;28(6):551–65. <https://doi.org/10.1097/WNP.0b013e318241de1a>.
- [27] Borke RC, Nau ME. The ultrastructural morphology and distribution of trigemino-hypoglossal connections labeled with horseradish peroxidase. *Brain Res* 1987;422(2):235–41. [https://doi.org/10.1016/0006-8993\(87\)90930-9](https://doi.org/10.1016/0006-8993(87)90930-9).
- [28] Adachi K, Murray GM, Lee JC, Sessle BJ. Noxious lingual stimulation influences the excitability of the face primary motor cerebral cortex (face MI) in the rat. *J Neurophysiol* 2008;100(3):1234–44. <https://doi.org/10.1152/jn.90609.2008>.
- [29] Maisonobe T, Tankere F, Lamas G, Soudant J, Bouche P, Willer JC, et al. Reflexes elicited from cutaneous and mucosal trigeminal afferents in normal human subjects. *Brain Res* 1998;810(1–2):220–8. [https://doi.org/10.1016/s0006-8993\(98\)00953-6](https://doi.org/10.1016/s0006-8993(98)00953-6).
- [30] Matsuo K, Palmer JB. Coordination of mastication, swallowing and breathing. *Jpn Dent Sci Rev* 2009;45(1):31–40. <https://doi.org/10.1016/j.jdsr.2009.03.004>.
- [31] Mizuno N, Sauerland EK. Trigeminal proprioceptive projections to the hypoglossal nucleus and the cervical ventral gray column. *J Comp Neurol* 1970;139(2):215–26. <https://doi.org/10.1002/cne.901390205>.
- [32] Dong Y, Li J, Zhang F, Li Y. Nociceptive afferents to the premotor neurons that send axons simultaneously to the facial and hypoglossal motoneurons by means of axon collaterals. *PLoS One* 2011;6(9):e25615. <https://doi.org/10.1371/journal.pone.0025615>.
- [33] Zhang J, Luo P, Pendlebury WW. Light and electron microscopic observations of a direct projection from mesencephalic trigeminal nucleus neurons to hypoglossal motoneurons in the rat. *Brain Res* 2001;917(1):67–80. [https://doi.org/10.1016/s0006-8993\(01\)02911-0](https://doi.org/10.1016/s0006-8993(01)02911-0).
- [34] Zhang J, Pendlebury WW, Luo P. Synaptic organization of monosynaptic connections from mesencephalic trigeminal nucleus neurons to hypoglossal motoneurons in the rat. *Synapse* 2003;49(3):157–69. <https://doi.org/10.1002/syn.10227>.
- [35] Simon MV, Chiappa KH, Borges LF. Phase reversal of somatosensory-evoked potentials triggered by gracilis tract stimulation: case report of a new technique for neurophysiologic dorsal column mapping. *Neurosurgery* 2012;70(3):E783–8. <https://doi.org/10.1227/NEU.0b013e31822e0a76>.
- [36] Nair D, Kumaraswamy VM, Braver D, Kilbride RD, Borges LF, Simon MV. Dorsal column mapping via phase reversal method: the refined technique and clinical applications. *Neurosurgery* 2014;74(4):437–46. <https://doi.org/10.1227/NEU.0000000000000287>; discussion 46.
- [37] Lee SH, Kim DH, Chun SM, Choi YH. Irreversible hypoglossal nerve injury and concomitant trigeminal system dysfunction after anterior surgery to the cervical spine: case report and literature review. *World Neurosurg* 2020;136:187–92. <https://doi.org/10.1016/j.wneu.2019.12.094>.
- [38] Bolton PS, Kerman IA, Woodring SF, Yates BJ. Influences of neck afferents on sympathetic and respiratory nerve activity. *Brain Res Bull* 1998;47(5):413–9. [https://doi.org/10.1016/s0361-9230\(98\)00094-x](https://doi.org/10.1016/s0361-9230(98)00094-x).
- [39] Edwards IJ, Lall VK, Paton JF, Yanagawa Y, Szabo G, Deuchars SA, et al. Neck muscle afferents influence oromotor and cardiorespiratory brainstem neural circuits. *Brain Struct Funct* 2015;220(3):1421–36. <https://doi.org/10.1007/s00429-014-0734-8>.
- [40] Espadaler J, Rogic M, Deletis V, Leon A, Quijada C, Conesa G. Representation of cricothyroid muscles at the primary motor cortex (M1) in healthy subjects,

- mapped by navigated transcranial magnetic stimulation (nTMS). *Clin Neurophysiol* 2012;123(11):2205–11. <https://doi.org/10.1016/j.clinph.2012.04.008>.
- [41] Deletis V, Rogic M, Fernandez-Conejero I, Gabarros A, Jeronic A. Neurophysiologic markers in laryngeal muscles indicate functional anatomy of laryngeal primary motor cortex and premotor cortex in the caudal opercular part of inferior frontal gyrus. *Clin Neurophysiol* 2014;125(9):1912–22. <https://doi.org/10.1016/j.clinph.2014.01.023>.
- [42] Osburn LL, Moller AR, Bhatt JR, Cohen-Gadol AA. Hemilingual spasm: defining a new entity, its electrophysiological correlates and surgical treatment through microvascular decompression. *Neurosurgery* 2010;67(1):192–5. <https://doi.org/10.1227/01.NEU.0000370596.78384.2B>.
- [43] Sinclair CF, Téllez MJ, Tapia OR, Ulkatan S. Contralateral R1 and R2 components of the laryngeal adductor reflex in humans under general anesthesia. *Laryngoscope* 2017;127(12). <https://doi.org/10.1002/lary.26744>. E443–e8.
- [44] Sinclair CF, Téllez MJ, Tapia OR, Ulkatan S, Deletis V. A novel methodology for assessing laryngeal and vagus nerve integrity in patients under general anesthesia. *Clin Neurophysiol* 2017;128(7):1399–405. <https://doi.org/10.1016/j.clinph.2017.03.002>.
- [45] Sinclair CF, Téllez MJ, Ulkatan S. Noninvasive, tube-based, continuous vagal nerve monitoring using the laryngeal adductor reflex: feasibility study of 134 nerves at risk. *Head Neck* 2018;40(11):2498–506. <https://doi.org/10.1002/hed.25377>.
- [46] Sinclair CF, Téllez MJ, Ulkatan S. Human laryngeal sensory receptor mapping illuminates the mechanisms of laryngeal adductor reflex control. *Laryngoscope* 2018;128(11). <https://doi.org/10.1002/lary.27248>. E365–e70.
- [47] Tellez MJ, Mirallave-Pescador A, Seidel K, Urriza J, Shoakazemi A, Raabe A, et al. Neurophysiological monitoring of the laryngeal adductor reflex during cerebellar-pontine angle and brainstem surgery. *Clin Neurophysiol* 2021;132(2):622–31. <https://doi.org/10.1016/j.clinph.2020.10.021>.
- [48] Bratzlavsky M, van der Ecken H. Afferent influences upon human genioglossal muscle. *J Neurol* 1974;207(1):19–25. <https://doi.org/10.1007/BF00312589>.
- [49] White DP, Edwards JK, Shea SA. Local reflex mechanisms: influence on basal genioglossal muscle activation in normal subjects. *Sleep* 1998;21(7):719–28. <https://doi.org/10.1093/sleep/21.7.719>.
- [50] Eckert DJ, McEvoy RD, George KE, Thomson KJ, Catcheside PG. Genioglossus reflex inhibition to upper-airway negative-pressure stimuli during wakefulness and sleep in healthy males. *J Physiol* 2007;581(Pt 3):1193–205. <https://doi.org/10.1113/jphysiol.2007.132332>.
- [51] Mathew OP, Abu-Osba YK, Thach BT. Genioglossus muscle responses to upper airway pressure changes: afferent pathways. *J Appl Physiol Respir Environ Exerc Physiol* 1982;52(2):445–50. <https://doi.org/10.1152/jappl.1982.52.2.445>.
- [52] Miwa H, Nohara C, Hotta M, Shimo Y, Amemiya K. Somatosensory-evoked blink response: investigation of the physiological mechanisms. *Brain* 1998;121(Pt 2):281–91. <https://doi.org/10.1093/brain/121.2.281>.
- [53] Sambo CF, Liang M, Cruccu G, Iannetti GD. Defensive peripersonal space: the blink reflex evoked by hand stimulation is increased when the hand is near the face. *J Neurophysiol* 2012;107(3):880–9. <https://doi.org/10.1152/jn.00731.2011>.