

A case of severe aplastic anaemia after SARS-CoV-2 vaccination

There is increasing awareness about the possible relationship between severe acute respiratory syndrome coronavirus-2 (SARS-CoV-2) vaccines and the development of haematological diseases, including autoimmune cytopenias (AICs) and complement-mediated diseases. Specifically, the development or recrudescence of autoimmune haemolytic anaemia,^{1,2} immune thrombocytopenia purpura^{3,4} and paroxysmal nocturnal haemoglobinuria (PNH)^{5,6} have been described secondarily to coronavirus disease 2019 (COVID-19) vaccines, regardless of the type. It has been reported that vaccines other than anti-SARS-CoV-2 could trigger AICs, as well as complement activation, although the matter is highly debated.^{7,8} Only few data have been reported regarding aplastic anaemia (AA) that is characterised by the premature death of bone marrow precursors due to a T-cell mediated immune attack. AA may be primary or secondary to several triggers, and a number of cases developing or relapsing after vaccine for hepatitis B virus (HBV), H1N1 influenza, varicella-zoster virus have been described.^{9,15} Here we report the first case of acquired AA developing after the administration of SARS-CoV-2 Pfizer-Biontech mRNA vaccine.

In April 2021 a 76-year-old male was admitted to a local hospital because of the sudden onset of haematomas and epistaxis. His personal past and family medical history were unremarkable. The patient had never had symptoms of cytopenia (i.e. pallor, fatigue, jaundice, bleeding, or harmful/frequent infections), and blood counts from ~1 year before presentation were within the normal range. He had completed the SARS-CoV-2 Pfizer-Biontech vaccination schedule in March (Fig 1). At 1 month after the second dose, he developed asthenia and muco-cutaneous bleeding. At admission, laboratory tests found severe thrombocytopenia [platelet count (PLT) $3 \times 10^9/l$], confirmed in sodium-citrate, leucopenia (white blood cells $3.7 \times 10^9/l$) with severe neutropenia [absolute neutrophil count (ANC) $0.46 \times 10^9/l$], and mild normocytic anaemia [haemoglobin (Hb) 112 g/l]. Haemolytic markers were normal except for a slight lactate dehydrogenase increase ($1.1 \times$ upper limit of normal). Reticulocytes were low ($38 \times 10^9/l$), and serum erythropoietin levels increased (308 mu/ml). Vitamins and iron status, coagulation tests, serum electrophoresis, and total immunoglobulins (Igs) were within the normal ranges. Blood smear showed no schistocytes nor blasts. Serology for HBV, human immunodeficiency virus, hepatitis C virus and Epstein-Barr virus was negative, whilst cytomegalovirus (CMV) and

parvovirus B-19 IgG were positive (DNA negative). Autoimmune tests were all negative, including direct anti-globulin test (DAT), anti-nuclear antibodies (ANA), extractable nuclear antigen (ENA), p- and c-anti-neutrophil cytoplasmic antibodies (p-ANCA, c-ANCA). Bone marrow aspirate and biopsy showed 10% cellularity in absence of blasts or dysplastic features, and normal cytogenetics. Flow cytometry revealed the presence of a small PNH clone of 0.6% on granulocytes and 0.03% on erythrocytes. The diagnosis of severe AA (SAA) according to Camitta criteria was established, and the patient started on steroids (prednisone 1 mg/kg/day) and platelets transfusions with no response. Due to worsening pancytopenia (Hb 88 g/l, ANC $0.9 \times 10^9/l$, PLT $10 \times 10^9/l$) he was then referred to our Centre (May 2021) and treated with immunosuppressive therapy (IST, cyclosporin 3 mg/kg/day + rabbit anti-thymocyte globulin, ATG). At 15 days after ATG, the patient developed fever and severe right knee arthritis interpreted as serum sickness and managed at first with high-dose steroids. Thereafter, synovial liquid culture turned positive for *Pseudomonas aeruginosa*, and CMV reactivation occurred, requiring intravenous antibiotic and anti-viral therapy, with progressive resolution of the clinical picture. At last follow-up the patient was still severely pancytopenic and transfusion-dependent (Hb 82 g/l, ANC $0.58 \times 10^9/l$, PLT $18 \times 10^9/l$, after transfusion).

This is the first patient developing AA after SARS-CoV-2 vaccine reported to date, although we cannot prove a causative relationship besides the temporal association. Compared to post-COVID-19 vaccine peripheral AICs, which are mainly due to humoral autoimmunity and were rapidly controlled by steroids,¹⁻⁴ our patient presented a severe cellular-mediated autoimmune condition, not responsive to first-line immunosuppression, and complicated by serum sickness and infections. This is in keeping with the known deeper immune dysregulation of AA, including the derangement of central immunity, and with the consequent heavier immunosuppressants utilised. However, the clinical outcome seems highly unpredictable, as the other reported patients post-HBV, H1N1 influenza, and varicella-zoster virus vaccines were both paediatric or adults experiencing either transient disease or severe refractory AA requiring bone marrow transplant.⁹⁻¹⁵

This case highlights that AIC and AA may be secondary to undetected or disregarded triggers, such as infections, traumas, drugs, etc. Accordingly, COVID-19 infection has been associated with AIC and AA development/exacerbations,

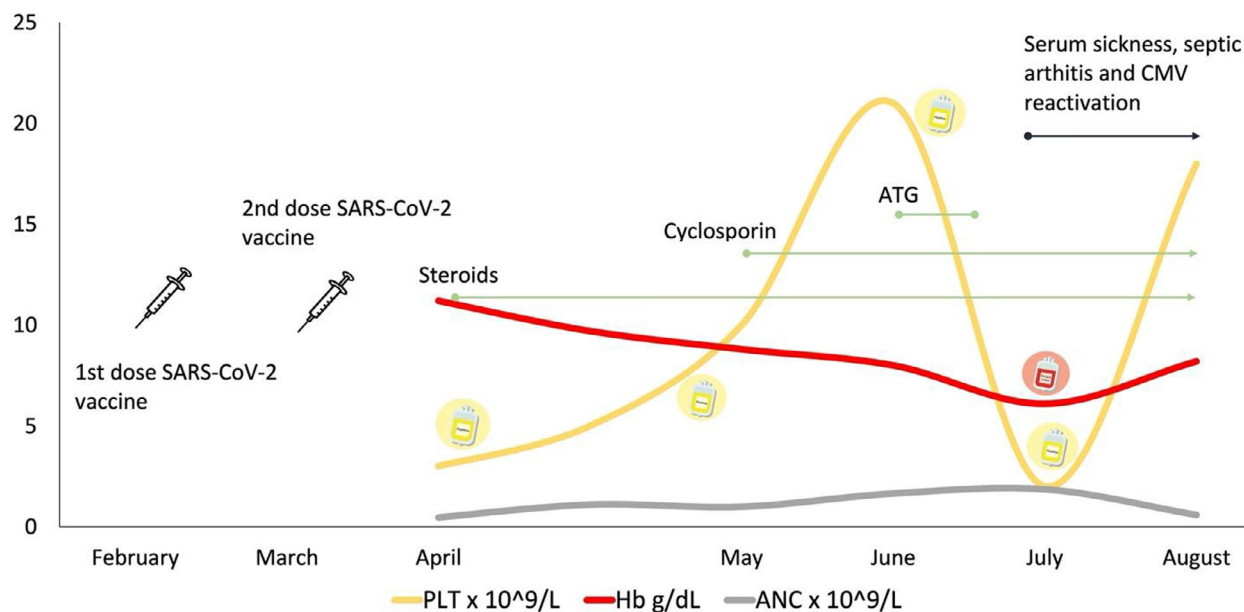


Fig 1. Clinical course and haematological values of our present patient with aplastic anaemia. ANC, absolute neutrophil counts; ATG, anti-thymocyte globulin; CMV, cytomegalovirus; Hb, haemoglobin; PLT, platelets.

through several hypothesised mechanisms (i.e. molecular mimicry and aberrant over activation of humoral and cellular immunity) that may occur even after vaccination.^{16–18} On the other hand, in our patient SARS-CoV-2 vaccine may have induced an immune activation that disclosed a latent autoimmunity. The presence of a PNH clone in our patient, as commonly observed in subjects with primary AA, favours the second pathogenic mechanism, although both hypotheses are not mutually exclusive. In our patient, AA developed ~1 month after the last booster dose of SARS-CoV-2 vaccine, possibly suggesting a relationship, although difficult to demonstrate given the mass vaccinations for SARS-CoV-2 and the known incidence of AA. Additionally, causes of secondary AA other than SARS-CoV-2 infection/vaccine should not be disregarded, including other infections, drugs, and the rarer congenital bone marrow failures.

In conclusion, SARS-CoV-2 vaccine may be associated with the development and/or exacerbation of both peripheral AICs and central AA, either as the single trigger or by disclosing a latent autoimmunity. Clinical awareness is fundamental to guide the evaluation of patients developing signs/symptoms suggestive of cytopenias after SARS-CoV-2 vaccine and to promptly establish the diagnosis and treatment of even rare haematological conditions. In any case, the several reports of AIC and AA complications caused by COVID-19 infection should be taken into consideration when weighing the risks/benefits of COVID-19 vaccination.

Funding information

No funding sources to declare.

Conflict of interest

All authors declare that they have no conflict of interest inherent to the present article to disclose. Bruno Fattizzo received consultancy from Apellis, Momenta, and Novartis and lecture fee/congress support from Alexion and Apellis. Wilma Barcellini received consultancy from Agios, Alexion, Apellis, Biocryst, Bioerativ, Incyte, Momenta, and Novartis; and lecture fee/congress support from Alexion, Incyte, Novartis, and Sanofi.

Author contributions

All the authors followed patients, wrote the article, and revised it for important intellectual content.

Nicola Cecchi^{1,2}

Juri Alessandro Giannotta¹

Wilma Barcellini¹

Bruno Fattizzo^{1,2}

¹Fondazione IRCCS Ca' Granda Ospedale Maggiore Policlinico, and

²Department of Oncology and Onco-hematology, University of Milan, Milan, Italy.

E-mail: bruno.fattizzo@unimi.it

Keywords: aplastic anaemia, autoimmune haemolytic anaemia, immune thrombocytopenia, coronavirus disease 2019, severe acute respiratory syndrome coronavirus-2 vaccine

References

1. Murdych TM. A case of severe autoimmune hemolytic anemia after a receipt of a first dose of SARS-CoV-2 vaccine. *Int J Lab Hematol.* 2021.

2. Pérez-Lamas L, Moreno-Jiménez G, Tenorio-Núñez MC, Velázquez-Kennedy K, Jiménez-Chillón C, Astibia-Mahillo B, et al. Hemolytic crisis due to Covid-19 vaccination in a woman with cold agglutinin disease. *Am J Hematol*. 2021;**96**:E288–91.
3. Kuter DJ. Exacerbation of immune thrombocytopenia following COVID-19 vaccination. *Br J Haematol*. 2021;**195**:365–70.
4. King ER, Towner E. A case of immune thrombocytopenia after BNT162b2 mRNA COVID-19 vaccination. *Am J Case Rep*. 2021;**22**:e931478.
5. Fattizzo B, Giannotta JA, Cecchi N, Barcellini W. SARS-CoV-2 vaccination induces breakthrough hemolysis in paroxysmal nocturnal hemoglobinuria on complement inhibitor. *Am J Hematol*. 2021;**96**:E344–6.
6. Portuguese AJ, Sunga C, Kruse-Jarres R, Gernsheimer T, Abkowitz J. Autoimmune- and complement-mediated hematologic condition recrudescence following SARS-CoV-2 vaccination. *Blood Adv*. 2021;**5**:2794–8.
7. Petrás M, Lesná IK, Dáňová J, Čelko AM. Can vaccination trigger autoimmune disorders? A meta-analysis. *Vaccines (Basel)*. 2021;**9**:821.
8. Segal Y, Shoenfeld Y. Vaccine-induced autoimmunity: the role of molecular mimicry and immune crossreaction. *Cell Mol Immunol*. 2018;**15**:586–94.
9. Angelini P, Kavadas F, Sharma N, Richardson SE, Tipples G, Roifman C, et al. Aplastic anemia following varicella vaccine. *Pediatr Infect Dis J*. 2009;**28**:746–8.
10. Donnini I, Scappini B, Guidi S, Longo G, Bosi A. Acquired severe aplastic anemia after H1N1 influenza virus vaccination successfully treated with allogeneic bone marrow transplantation. *Ann Hematol*. 2012;**91**:475–6.
11. Viallard JF, Boiron JM, Parrens M, Moreau JF, Ranchin V, Reiffers J, et al. Severe pancytopenia triggered by recombinant hepatitis B vaccine. *Br J Haematol*. 2000;**110**:230–3.
12. Ashok Shenoy K, Prabha Adhikari MR, Chakrapani M, Shenoy D, Pillai A. Pancytopenia after recombinant hepatitis B vaccine—an Indian case report. *Br J Haematol*. 2001;**114**:955.
13. Shah C, Lemke S, Singh V, Gentile T. Case reports of aplastic anemia after vaccine administration. *Am J Hematol*. 2004;**77**:204.
14. Hendry CL, Sivakumaran M, Marsh JC, Gordon-Smith EC. Relapse of severe aplastic anaemia after influenza immunization. *Br J Haematol*. 2002;**119**:283–4.
15. Ritz C, Meng W, Stanley NL, Baroja ML, Xu C, Yan P, et al. Postvaccination graft dysfunction/aplastic anemia relapse with massive clonal expansion of autologous CD8+ lymphocytes. *Blood Adv*. 2020;**4**:1378–82.
16. Avenoso D, Marsh JC, Potter V, Pagliuca A, Slade S, Dignan F, et al. SARS-CoV-2 infection in aplastic anaemia. *Haematologica*. 2021 (Online ahead of print). <https://doi.org/10.3324/haematol.2021.279928>
17. Barcellini W, Giannotta JA, Fattizzo B. Are patients with autoimmune cytopenias at higher risk of COVID-19 pneumonia? The experience of a reference center in Northern Italy and review of the literature. *Front Immunol*. 2021;**11**:609198.
18. Fattizzo B, Giannotta JA, Cecchi N, Barcellini W. SARS-CoV-2 vaccination in patients with autoimmune cytopenias: the experience of a reference center. *Am J Hematol*. 2021;**96**:E413–6.