

of cycles were grade 4), lead to frequent retreatment delay (1-2 weeks); such myelosuppression was primarily observed in patients with borderline renal function (data not shown).

One patient with malignant melanoma metastatic to liver and adrenals, who had previously received cisplatin and oxaliplatin given as single agents, had a surgically proven histologic complete response that lasted 35 months after completion of six cycles of the combination; the other patients progressed after one to five cycles.

Encouraging preclinical studies (6,7) enhance the rationale for giving patients combinations of these compounds. Conclusions about the therapeutic efficacy of the present investigation are not warranted, given the patient population characteristics.

Since the adequate administration of carboplatin entails dose calculation on the basis of individual renal clearance (8), we intend to re-evaluate this combination through a pharmacokinetically guided phase I-II trial. Moreover, the simultaneous administration of cisplatin and oxaliplatin, which is already being evaluated in clinical trials, has given very encouraging preliminary results for ovarian and germ cell tumor patients heavily pretreated with platinum (9).

J. F. LLORY

P. SOULIE

E. CVITKOVIC

J. L. MISSET

SMST—Hôpital Paul Brousse  
Villejuif, France

## References

- (1) Levin L, Simon R, Hryniuk W: Importance of multiagent chemotherapy regimens in ovarian carcinoma: dose intensity analysis. *J Natl Cancer Inst* 85:1732-1742, 1993
- (2) Ozols RF, Corden BJ, Jacob J: High-dose cisplatin in hypertonic saline. *Ann Intern Med* 100:19-24, 1984
- (3) Christian MC: The current status of new platinum analogs. *Semin Oncol* 19:720-733, 1992
- (4) Misset JL, Kidani Y, Gastiaburu J, et al: Oxalatoplatinum (L-OHP): experimental and clinical studies. In *Platinum and Other Metal Coordination Compounds in Cancer Chemotherapy* (Howell SB, ed). New York: Plenum Press, 1991, pp 369-375
- (5) Brienza S, Fandi A, Hugret F, et al: Neurotoxicity (NTX) of long term oxaliplatin (L-OHP) therapy. *Proc Am Assoc Cancer Res* 34:406, 1993

- (6) Mathe G, Chenu E, Bourut C, et al: Experimental study of three platinum complexes: CDDP, CBDCA and L-OHP on L1210 leukemia. Alternate or simultaneous association of two platinum complexes. *Proc Am Assoc Cancer Res* 30:1872, 1989
- (7) Ortuzar W, Paull K, Rixe O, et al: Comparison of the activity of cisplatin (CP) and oxaliplatin (OXALI) alone or in combination in parental and drug resistant sublines. *Proc Am Assoc Cancer Res* 35:332, 1994
- (8) Calvert AH, Newell DR, Gumbrell LA, et al: Carboplatin dosage: prospective evaluation of a simple formula based on renal function. *J Clin Oncol* 7:1748-1756, 1989
- (9) Soulie P, Cvitkovic E, Garrino C, et al: Combined Oxaliplatin (L-OHP) cisplatin (CP) (Bi): an effective approach to optimize Platinum (Pt) treatment of malignancies. *Proc Am Assoc Cancer Res* 35:438, 1994

## Note

Correspondence to: E. Cvitkovic, M.D., SMST—Hôpital Paul Brousse, 14 Av Paul-Vaillant-Couturier, 94804 Villejuif, France.

## Optic Nerve Disturbances: a New Form of Paclitaxel Neurotoxicity

The neurotoxicity of paclitaxel (Taxol) is cumulative and primarily characterized by a sensory and motor peripheral neuropathy (1-3). We describe here visual disturbances and neurologic findings consistent with a toxicity of paclitaxel to the optic nerve. The symptoms occurred in relapsed breast cancer patients during an ongoing trial of paclitaxel administered every 3 weeks by 3-hour infusion at the dose of 175 mg/m<sup>2</sup> (15 patients) or 225 mg/m<sup>2</sup> (32 patients) (4). The trial was approved by the local ethics committee, and all patients gave their informed witnessed consent before accrual.

Nine (19%) of 47 patients (three treated with 175 mg/m<sup>2</sup> and six with 225 mg/m<sup>2</sup> paclitaxel) described scintillating scotomata as small luminous dots or "flies" in the visual fields of both eyes at about the time paclitaxel infusion ended. The scotomata occurred in 26 of 60 courses, were never associated with changes of blood pressure, and persisted from a few minutes to several hours. They always spontaneously resolved and did not necessarily recur with subsequent administration of

paclitaxel. Three of the nine patients also reported a subjective reduction of vision that prompted examination by an ophthalmologist and serial assessments of visual acuity, fundi, and visual fields. Recordings of visual evoked potentials (VEPs) and electroretinograms (ERGs) were also performed to assess the function of the optic neural pathway (5). The three patients (P1, P2, and P3) were aged 62, 37, and 46 years, respectively, and had been pretreated with anthracyclines. Two had also received goserelin. They all received paclitaxel at the starting dose of 225 mg/m<sup>2</sup>. The cranial nerves were not involved in any of the three patients.

Patient P1 received six doses of paclitaxel, and World Health Organization (WHO) grade 1 paresthesias developed after each course. During the third infusion, this patient reported bilateral scintillating scotomata. After the fourth course, she also described a reduction of vision that affected the left eye. The patient denied any previous visual deficit. The visual acuity was 10/10 in the right eye and 7/10 in the left eye; the inspection of the fundi showed a peripapillary atrophic area on the left side. After the last cycle of paclitaxel, this patient underwent neurophysiologic evaluations that showed a reduction of sensitivity of the 30 central degrees of the left visual field and abnormal VEPs, with an increase in latency and a decrease in amplitude of the principal component of the response at 100 milliseconds (P100 response) (6). The results were worse on the left than on the right side. The ERG was normal. In the following 8 months, the neurophysiologic findings and the visual deficit did not change.

Patient P2 described a reduction of vision after the first dose of paclitaxel and complained of lighting scotomata that recurred after the second cycle. Bilateral visual acuity was 10/10, and fundi were normal. There was a bilateral enlargement of the physiologic blind spot. The VEPs recorded 2 weeks later showed bilateral abnormalities that were more prominent with the higher spatial frequencies of stimulation (Fig 1, B). The ERG was normal. Similar results were obtained after the third cycle, but the latency and amplitude of the P100

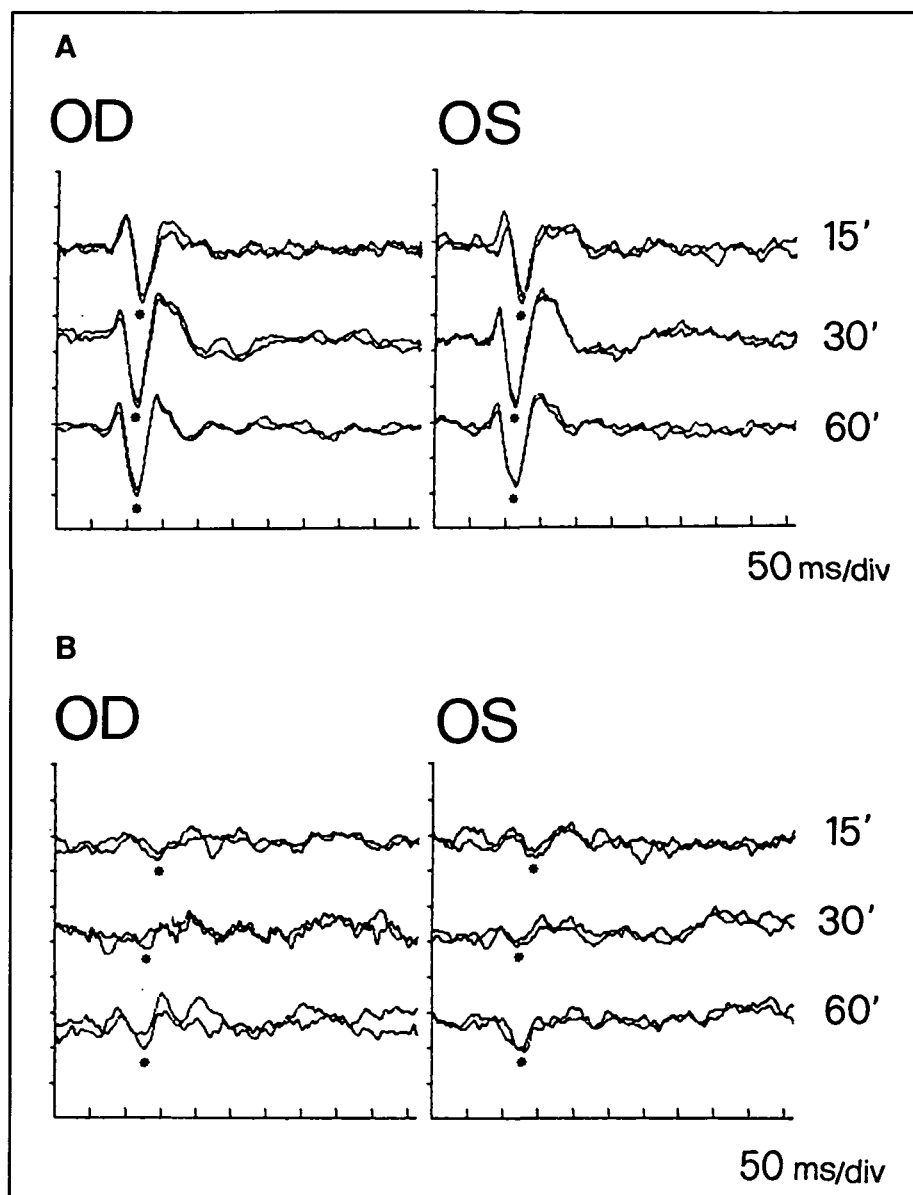


Fig. 1. A) Traces are visual evoked potentials obtained with checkerboard pattern-reversal stimulation and progressively higher spatial frequency stimulation (squares of 60, 30, and 15 minutes) in a normal subject (53-year-old woman). OD indicates the right eye and OS the left eye. The asterisk corresponds to the principal positive component (P100). Ordinate axis calibration is equal to 10  $\mu$ V per division. B) Visual evoked potentials were obtained with the same method from patient P2 (see text). A clear-cut reduction of the P100 amplitude is evident with all stimulations. An increase of P100 latency can also be seen, in particular with the 15-minute stimulation. Results are worse on the right eye. Ordinate axis calibration is equal to 5  $\mu$ V per division (note the difference with upper traces calibration). ms/div = milliseconds per division.

component of the VEP improved after the fifth and the last dose. Clinically, the visual symptoms did not improve.

Patient P3 received paclitaxel at a dose of 225 mg/m<sup>2</sup> for two cycles. The second cycle was complicated by WHO grade 3 peripheral neuropathy and by a decrease of vision. Visual acuity was 10/10 bilaterally, and fundi were normal. However, the VEPs showed a

marked reduction of the amplitude of the P100 response associated with a minor increase of latency. The ERG was normal bilaterally. Clinical and neurophysiologic findings were unchanged after the third and last cycle of paclitaxel. The patient was then lost to follow-up.

To our knowledge, this correspondence is the first description of visual

symptoms during paclitaxel chemotherapy. In nine patients, scintillating scotomata were in clear temporal relation with the drug infusion, and should be viewed as a reversible, transient side effect of the taxane. Their association with subjective visual impairment in three patients prompted a neurophysiologic assessment of the optic pathways from the retinal to the anterior and retrochiasmatic level (6,7). The ERG studies were normal, thus excluding an involvement of the retina as a main source of the visual alterations. The VEP abnormalities suggested an involvement of the optic nerve that was confirmed by the observation that the changes of amplitude and latency were not modified by using checkerboard horizontal or vertical bars pattern-reversal stimulation (5). The increase of the latency of the P100 component of the VEP is considered typical of demyelinating optic neuropathy (8); however, a reduction in amplitude without an increase in its latency, as observed in our patients (Fig. 1, A and B), has been found in ischemic or compressive neuropathies (9,10). These abnormalities did not seem progressive (patient P1) and showed some degree of recovery (patient P2).

In conclusion, paclitaxel damages the optic nerve. The ensuing loss of visual acuity is clearly more clinically relevant than the transient occurrence of scotomata. To assess the actual prevalence, the clinical relevance and reversibility, and the pathophysiology of these disturbances with different doses and schedules of paclitaxel, prospective studies will be required.

G. CAPRI  
E. MUNZONE  
E. TARENZI  
F. FULFARO  
L. GIANNI

*Division of Medical Oncology  
Laboratory of Clinical Pharmacology*

A. CARACENI  
C. MARTINI  
*Division of Palliative Care  
Istituto Nazionale Tumori, Milan, Italy*

V. SCAIOLI  
*Unit of Neurophysiology  
Istituto Neurologico C. Besta  
Milan, Italy*

## References

- (1) Rowinsky EK, Chaudhry V, Comblath DR, et al: Neurotoxicity of taxol. *Monogr Natl Cancer Inst* 15:107-115, 1993
- (2) Arbusk SG, Canetta R, Onetto N, et al: Current dosage and schedule issues in the development of paclitaxel (Taxol). *Semin Oncol* 20 (4 Suppl 3):31-39, 1993
- (3) Schiller JH, Storer B, Tutsch K, et al: Phase I trial of 3-hour infusion of paclitaxel with or without granulocyte colony-stimulating factor in patients with advanced cancer [see comment citation in Medline]. *J Clin Oncol* 12:241-248, 1994
- (4) Gianni L, Capri G, Munzone E, et al: Paclitaxel efficacy in patients with advanced breast cancer resistant to anthracyclines. *Eur J Cancer* 1994. In press
- (5) Celesia GG: Anatomy and physiology of visual evoked potentials and electroretinograms. *Neurol Clin* 6:657-679, 1988
- (6) Bodis-Wollner I, Ghilardi MF, Mylin LH: The importance of stimulus selection in VEP practice: the clinical relevance of visual physiology. *In Evoked Potentials. Frontiers in Clinical Neuroscience* (Cracco RQ, Bodis-Wollner I, eds). New York: Alan R. Liss, 1986, pp 15-27
- (7) Sherman J: ERG and VEP as supplemental aids in the differential diagnosis of retinal versus optic nerve disease. *In Evoked Potentials. Frontiers in Clinical Neuroscience* (Cracco RQ, Bodis-Wollner I, eds). New York: Alan R. Liss, 1986, pp 343-353
- (8) Halliday AM, McDonald WI, Mushin J: Delayed visual evoked response in optic neuritis. *Lancet* 1:982-985, 1972
- (9) Halliday AM, Halliday E, Kriss A, et al: The pattern-evoked potential in compression of the anterior visual pathways. *Brain* 99:357-374, 1976
- (10) Rumi V, Angelini L, Scaioli V, et al: Primary antiphospholipid syndrome and neurologic events. *Pediatr Neurol* 9:473-475, 1993

## Notes

*Correspondence to:* Luca Gianni, M.D., Divisione di Oncologia Medica A, Istituto Nazionale dei Tumori, Via Venezian 1, Milan 20133, Italy.

*Supported in part by contract 93.02309.PF39 of the Italian National Research Council and by Bristol Myers Squibb.*

**Erratum:** "Application of Pharmacokinetically Guided Dose Escalation With Respect to Cell Cycle Phase Specificity," by E. Fuse, S. Kobayashi, M. Inaba, et al. [*J Natl Cancer Inst* 86:989-996, 1994 (Issue 13)]. Because of a printer's error, information was omitted from three of the figures:  $\log SS/N = 0.149$  [Fig. 1];  $\log SS/N = 1.629$  [Fig. 2];  $\log SS/N$  [above the numbers 0.190 and 0.078 in Fig. 3]. The Journal regrets the error.

# Adverse reaction?

## If it's serious, we need to know.

1-800-FDA-1088.

**FDA MEDWATCH**  
THE FDA WATCH BY WHICH YOU CAN REPORT AND AVOID SERIOUS DRUG REACTIONS

If it's serious, we need to know.