

Contents lists available at [ScienceDirect](http://www.sciencedirect.com)

International Journal of Surgery

journal homepage: www.journal-surgery.net

ORIGINAL ARTICLE

Use of 3 mm percutaneous instruments with 5 mm end effectors during different laparoscopic procedures

Giulia David, Luigi Boni, Stefano Rausei, Elisa Cassinotti, Gianlorenzo Dionigi, Francesca Rovera, Sebastiano Spampatti, Elisabetta Marta Colombo, Renzo Dionigi

Department of Surgical and Morphological Sciences Insubria, University of Insubria Varese, 1st Division of Surgery Ospedale di Circolo e Fondazione Macchi, Varese, Italy

ARTICLE INFO

Keywords:

Minimally invasive surgery
Percutaneous instruments
Single-port surgery
NOTES™

ABSTRACT

Background and Purpose: With a recent focus on minimizing the visibility of scars, new techniques have been developed. Minilaparoscopy reemerged as an attractive option for surgery as it limits tissue trauma, reduces post-operative pain and improves cosmesis. This study was designed to describe our experience with percutaneous trocarless 3 mm instruments used in combination with standard 5 mm and 10 mm laparoscopic instruments in different general surgery procedures.

Methods: We used the PSS (Percutaneous Surgical Set, Ethicon Endo surgery, Cincinnati, OH, USA) in different surgical procedures as accessory instruments in combination with standard 5 mm and 10 mm standard laparoscopic instruments.

Main findings: The use of percutaneous instruments was safe and feasible in all performed procedures. The surgical technique was not modified. The percutaneous instruments can assure a good grip and can be used for traction and counter-traction. No complications have been described. No pain at the site of insertion has been reported. The skin, muscle and peritoneal defects were smaller than with the 3 mm laparoscopic traditional instruments.

Conclusions: Percutaneous approach seems to be a good option in general surgery in terms of efficiency, offering better cosmetic results and good pain control.

© 2013 Surgical Associates Ltd. Published by Elsevier Ltd. All rights reserved.

1. Introduction

In recent years in order to improve postoperative outcome, scarless surgery has gained importance in minimally invasive surgery. New techniques to reduce even more the invasiveness of laparoscopic surgery have been developed, first experimentally and then with the clinical introduction of other “ultra”-minimally invasive surgical techniques, such as minilaparoscopy or needlescopic surgery, Natural Orifice Transluminal Endoscopic Surgery (NOTES™) and single-site laparoscopy (SSL), and significant technological advantages have been achieved.^{1–5}

The purposes of these new techniques are to minimize trauma to the abdominal wall and post-operative pain and to improve the cosmetic result by reducing the size of scars.

Minilaparoscopy or needlescopic surgery is defined as minimally invasive surgery with instruments that are 3 mm or less and was first described in 1998 by Gagner and Garcia-Ruiz.⁶

The main limitation of needlescopic surgery is related to the instruments themselves since strength and durability of the instruments may limit tissue manipulation. Furthermore, 3 mm instruments do not offer the same range of end-effector options of functionally 5 mm instruments.^{7,8} In addition, studies comparing SSL

and NOTES™ to traditional multi-port surgery have demonstrated that these techniques are not suitable for all surgical procedures: the learning curve is longer, the triangulation is difficult, there is limited access and working space, instruments conflict, and strict selection of cases and patients is required (BMI < 30 kg/m²). For these reasons, indications for SSL and NOTES™ are still limited to date.^{9–12}

On the contrary, minilaparoscopy allows to perform surgical procedures with a technique similar to standard laparoscopy since triangulation and the position of instruments are the same as for standard laparoscopic surgery, while surgical trauma is reduced owing to the limited diameter of the instruments. A further evolution of minilaparoscopy was achieved with the development of percutaneous instruments that do not require a trocar for introduction and that have 5 mm end effectors designed to be assembled and disassembled inside the abdominal cavity.

The aim of this study is to describe our preliminary experience with a new set of percutaneous 3 mm instruments, PSS (Percutaneous Surgical Set, Ethicon Endo surgery, Cincinnati, OH, USA), used in combination with standard 5 mm and 10 mm laparoscopic instruments during different surgical procedures (Fig. 1).



Fig. 1. Percutaneous surgical set (PSS): 3 mm percutaneous instrument with 5 mm attachable grasper.

2. Methods and materials

We used the PSS in different surgical procedures as accessory instruments in combination with standard 5 mm and 10 mm standard laparoscopic instruments.

The PSS consists of a 3 mm percutaneous shaft with 5 mm loader that is used in conjunction with three different attachments such as 5 mm grasper and 5 mm Maryland dissector. It is designed for direct introduction to the surgical site without the need for a traditional trocar.

The loader is inserted through a traditional trocar (5 mm minimum) and used to attach and remove the 5 mm or 10 mm attachments to the shaft (Fig. 2). After a small puncture with an 11 blade at the point of insertion, the percutaneous instrument is inserted into the abdominal cavity with a rotating motion under direct visualization. The chosen attachment is connected to the distal end of the loader device that has an articulated feature to aid in alignment of the two

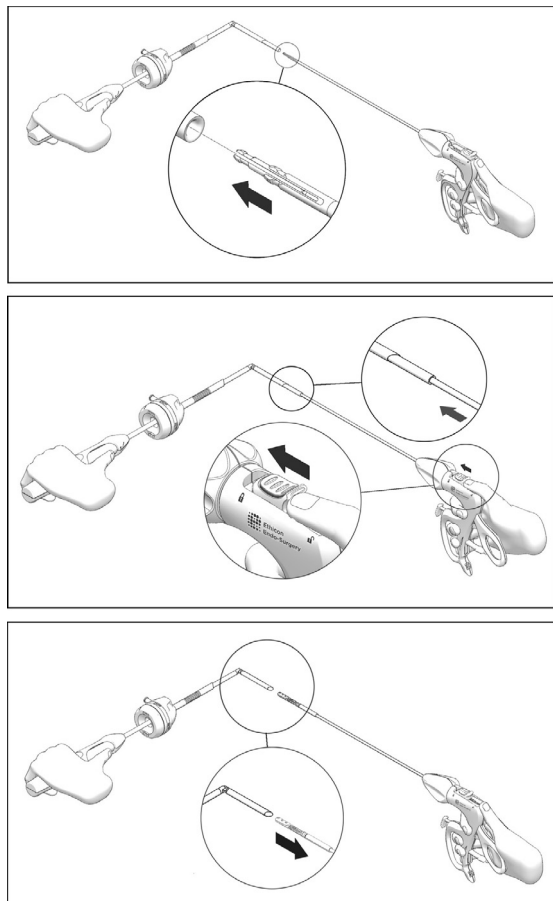


Fig. 2. End effector assembly.

devices. Alternatively, the connection can be completed under direct visualization into the transparent cannula of a trocar.

In order to utilize a different attachment, the current attachment can be removed from the loader by rotating counter-clockwise to align the indicator line and the attachment cartridge can then be removed. Alternatively, the percutaneous shaft can be removed and disconnected through the cannula of a trocar or through the defect created by a trocar (Fig. 2).

3. Results

From November 2011 to January 2012 we used the PSS during 21 surgical procedures in the General Surgery Department of the University of Insubria, Varese (7 cholecystectomies, 2 low anterior resections for rectal cancer, 3 right hemicolectomies, 2 left hemicolectomies, 2 Nissen funduplications, 1 gastric GIST resection, 1 sigmoid resection with NOSE, 2 splenectomies, 1 transverse colon resection). In all these procedures, percutaneous instruments were used with a grasper distal clamp, for traction.

The surgical technique was not modified in all procedures in comparison to the standard laparoscopic procedure and in all cases and the use of percutaneous instruments was safe with no intra-operative failure. No conversions to laparotomy or classic laparoscopic were required and no additional classic or percutaneous instruments had to be introduced during the procedure. The average duration of surgery was comparable to standard laparoscopic procedures.

Blood loss during surgery was minimal. The length of hospital stay was similar to that with classic procedures. No complications were recorded. None of the patients reported residual pain at the site of insertion of the percutaneous instruments. It was not necessary to close the fascia after the removal of the percutaneous shaft; skin suturing was not required and we used skin glue.

The residual scars were about 2 mm for the percutaneous instruments (Figs. 3, 4).

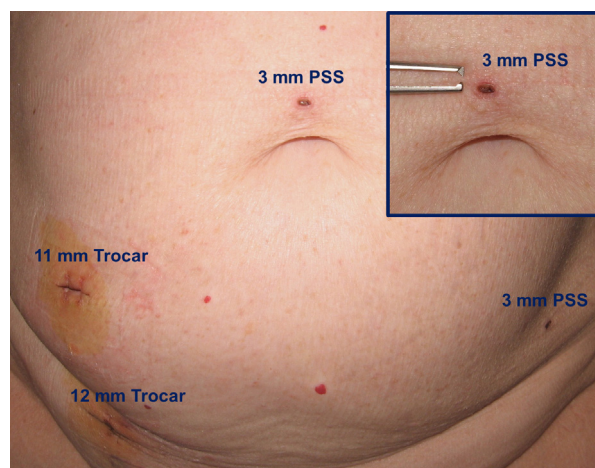


Fig. 3. Scars immediately after the procedure. Inset: larger view of PSS 3 mm scar.

4. Discussion

Ever since its development in surgical practice, the aim of minimally invasive surgery has been to decrease the morbidity associated with large incisions. As technology progressed, the size of laparoscopic instruments diminished in attempts by the surgeon to minimize the trauma induced by surgical procedures. The field of minimally invasive surgery is rapidly evolving and several significant technological and procedural advancements have been achieved.

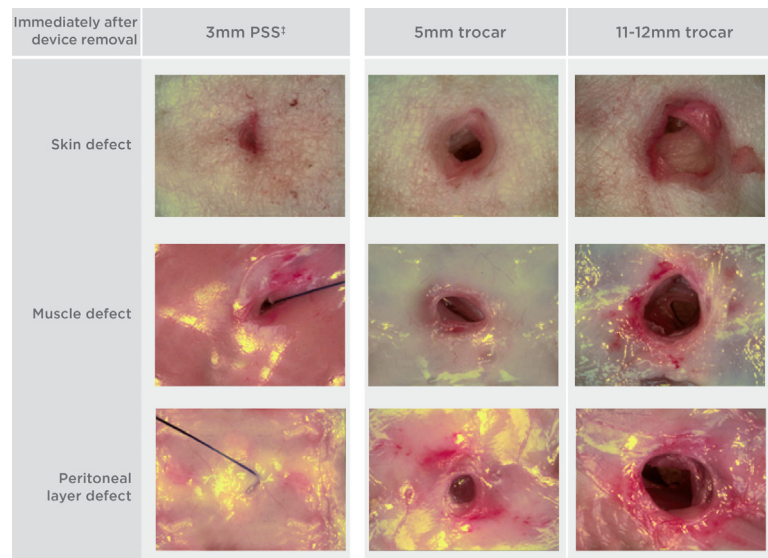


Fig. 4. The PSS tissue defect is 5 times smaller than the 5 mm trocar tissue defect.

During the last few years interest in SSL and NOTES™ has grown. Although data are limited, several advantages of SSL have emerged such as less incisional pain, shorter recovery and enhanced cosmesis. However, both of these new approaches are technically demanding, and many challenges – including loss of triangulation, poor visualization, limited access and working space, instrument conflicts – remain.^{9–11,13}

Minilaparoscopy is the next step in the natural continuum of minimally invasive surgery; it permits to perform the surgical procedure as in standard multi-port surgery, there is no loss of triangulation, the site of instrument insertion is maintained, the learning curve is not modified, and no patients selection is necessary; in fact, it can be used in obese patients (BMI ≥ 30 kg/m²).^{1,12,14–17}

In our experience the PSS is a good alternative because the instruments are less invasive, producing a markedly smaller defect in the skin layer, muscle layer and peritoneal layer compared to 3 mm, 5 mm and 11–12 mm trocars. In fact, the defect resulting from the PSS is five times smaller than the defect from a 5 mm trocar (Fig. 4).

Using these percutaneous instruments a standard 5 mm grasper can be assembled intra-abdominally ensuring a good grip, as in conventional 5 mm laparoscopic instruments. These instruments are more resistant than minilaparoscopic 3 mm instruments since the shaft is short because it does not require trocars.

The PSS allows the surgeon flexibility to place the instruments when needed during the procedures. Some of the possible limitations of the PSS are the cost, which is definitely higher than that of standard 5 or 3 mm instruments since they are disposable, and the limited availability of different types of end effector.

5. Conclusions

The use of percutaneous 3 mm instruments was feasible, safe, able to improve cosmesis and able to reduce postoperative pain. The PSS may be a good alternative to standard laparoscopic instruments especially for retraction or as accessory instrument.

Funding
None.

Disclosure statement

The authors have no conflicts of interest to declare.

References

- McCloy R, Randall D, Schug SA, et al. Is smaller necessarily better? A systematic review comparing the effects of minilaparoscopic and conventional laparoscopic cholecystectomy on patient outcomes. *Surg Endosc* 2008;**22**(12):2541–53.
- Auyang ED, Santos BF, Enter DH, Hungness ES, Soper NJ. Natural orifice transluminal endoscopic surgery (NOTES®): a technical review. *Surg Endosc* 2011;**25**(10):3135–48.
- Mohan HM, O'Riordan JM, Winter DC. Natural-orifice transluminal endoscopic surgery (NOTES): minimally invasive evolution or revolution? *Surg Laparosc Endosc Percutan Tech* 2013;**23**(3):244–50.
- Pucher PH, Sodergren MH, Singh P, Darzi A, Parakseva P. Have we learned from lessons of the past? A systematic review of training for single incision laparoscopic surgery. *Surg Endosc* 2013;**27**(5):1478–84.
- Kwasnicki RM, Aggarwal R, Lewis TM, Purkayastha S, Darzi A, Paraskeva PA. A comparison of skill acquisition and transfer in single incision and multi-port laparoscopic surgery. *J Surg Educ* 2013;**70**(2):172–9.
- Gagner M, Garcia-Ruiz A. Technical aspects of minimally invasive abdominal surgery performed with needlescopic instruments. *Surg Laparosc Endosc* 1998;**8**(3):171–9.
- Lee PC, Lai IR, Yu SC. Minilaparoscopic (needlescopic) cholecystectomy: a study of 1,011 cases. *Surg Endosc* 2004;**18**(10):1480–4.
- Mamazza J, Schlachta CM, Seshadri PA, Cadeddu MO, Poulin EC. Needlescopic surgery. A logical evolution from conventional laparoscopic surgery. *Surg Endosc* 2001;**15**(10):1208–12.
- Podolsky ER, Curcillo PG 2nd. Reduced-port surgery: preservation of the critical view in single-port-access cholecystectomy. *Surg Endosc* 2010;**24**(12):3038–43.
- Podolsky ER, Curcillo PG 2nd. Single port access (SPA) surgery – a 24-month experience. *J Gastrointest Surg* 2010;**14**(5):759–67.
- Wood SG, Panait L, Duffy AJ, Bell RL, Roberts KE. Complications of transvaginal natural orifice transluminal endoscopic surgery: a series of 102 patients. *Ann Surg* 2013 Apr 17 [Epub ahead of print].
- Hosogi H, Strassel V, Martin C, Sakai Y, Saad S. Single-port versus needlescopic versus conventional laparoscopic cholecystectomy: a comparative study. *Asian J Endosc Surg* 2011;**4**(3):120–6.
- Rivas H, Varela E, Scott D. Single-incision laparoscopic cholecystectomy: initial evaluation of a large series of patients. *Surg Endosc* 2010;**24**(6):1403–12.
- Sajid MS, Khan MA, Ray K, Cheek E, Baig MK. Needlescopic versus laparoscopic cholecystectomy: a meta-analysis. *ANZ J Surg* 2009;**79**(6):437–42.
- Cockbain AJ. Randomized clinical trial of single-port, minilaparoscopic and conventional laparoscopic cholecystectomy. *Br J Surg* 2013;**100**:339–50.
- Ghezzi F, Cromi A, Siesto G, et al. Minilaparoscopic versus conventional laparoscopic hysterectomy: results of a randomized trial. *J Minim Invasive Gynecol* 2011;**18**(4):455–6.
- Leggett PL, Churchman-Winn R, Miller G. Minimizing ports to improve laparoscopic cholecystectomy. *Surg Endosc* 2000;**14**(1):32–6.