ELSEVIER

European Journal of Cardio-thoracic Surgery 36 (2009) 352—356

EUROPEAN JOURNAL OF CARDIO-THORACIC SURGERY

www.elsevier.com/locate/ejcts

Montgomery T-tube placement in the treatment of benign tracheal lesions☆

Angelo Carretta*, Monica Casiraghi, Giulio Melloni, Alessandro Bandiera, Paola Ciriaco, Luca Ferla, Armando Puglisi, Piero Zannini

Department of Thoracic Surgery, Vita-Salute San Raffaele University, San Raffaele Scientific Institute, Via Olgettina, 60, 20132, Milan, Italy

Received 12 September 2008; received in revised form 23 February 2009; accepted 25 February 2009; Available online 11 April 2009

Abstract

Introduction: Although surgery remains the gold standard for the treatment of benign tracheal stenosis, airway stenting may be indicated in the event of complex lesions or associated diseases. We retrospectively investigated Montgomery T-tube placement as an alternative or complementary treatment to surgery. **Methods:** From January 1984 to March 2008, 158 patients were treated for benign tracheal lesions. Eighty-three patients underwent airway resection and reconstruction as the only treatment. Seventy-five other patients with complex lesions or major associated diseases were treated with a T-tube and were retrospectively analysed. Seven of them had undergone unsuccessful treatment with Dumon stents. T-tube placement was the only procedure adopted in 51 patients with a contraindication to surgery (group I), a temporary measure in 15 patients prior to surgery (group II), and in 9 patients (group III) for complications of airway reconstruction, 5 of whom were referred from other institutions. **Results:** Complications after T-tube placement were: stent dislocation in 3 (4%) patients, endoluminal granulomas in 14 (19%), subglottic edema in 3 (4%), and sputum retention in 7 (9%). Treatment of complications (tracheostomy cannula, steroid infiltration, Argon/LASER coagulation, and bronchoscopy) was required in 20 (27%) patients. In group I, the tube was removed in 12 (24%) patients after 35.3 ± 8.2 months following resolution of the stenosis. In group II, the tubes were maintained in place before surgery for 17.1 ± 4.8months. In group III, three stents were removed following tracheal healing after 115.3 ± 3.7months. After 5 years the stents were in place in 82%, 7% and 100% of the patients, respectively in groups I, II and III. **Conclusions:** Montgomery T-tube placement represents a useful option in patients with complex benign tracheal stenosis or associated diseases as an alternative or complementary treatment to surgery, and is effective even when other types of stents are unsuccessful.

Keywords: Trachea; Stenosis; Benign; Conservative; Stent; T-tube

1. Introduction

Surgical resection and reconstruction is the treatment of choice of benign tracheal stenosis and favourable results are reported in over 90% of patients after treatment [1]. Surgery may, however, be temporarily or permanently precluded if there are associated diseases. When general anaesthesia is required, as for instance in cases of post-traumatic neurological or orthopaedic lesions, reconstructive tracheal surgery has to be delayed in order to avoid intubation of a freshly reconstructed airway. On the other hand, local factors, such as an excessive length of the stenosis or severe inflammation of the tracheal mucosa, may also cause an absolute or temporary contraindication to surgical treatment. In these cases conservative treatment by means of a tracheostomy or airway stenting may therefore be indicated as an alternative or as a complementary treatment to surgery. In case of failure of surgical treatment, with anastomotic dehiscence or re-stenosis, conservative treatment may also be required while waiting for re-operation or when surgery is no longer considered a viable therapeutic option.

Although a number of airway stents have been developed in recent years, the Montgomery T-tube, first described more than 40 years ago, is still used in the conservative treatment of benign airway stenosis [2]. We retrospectively investigate our experience of Montgomery T-tube placement as an alternative or complementary treatment to surgery, and evaluate its present-day role in the management of benign tracheal stenosis. In particular the following indications for the use of Montgomery T-tubes were retrospectively evaluated: as the only treatment in patients with a permanent contraindication to surgery, as a temporary pre-surgical measure in patients with a temporary contra-indication to tracheal resection and reconstruction, and in the treatment of complications of tracheal surgery.

2. Methods

From January 1984 to March 2008, 158 patients were treated for benign tracheal lesions at the Department of

☆ Presented at the 22nd Annual Meeting of the European Association for Cardio-thoracic Surgery, Lisbon, Portugal, September 14—17, 2008.

* Corresponding author. Tel.: +39 02 26437138; fax: +39 02 26437147.
E-mail address: angelo.carretta@hsr.it (A. Carretta).

1010-7940/$ — see front matter
doi:10.1016/j.ejcts.2009.02.049

Table 1
Indications for the use of Montgomery T-tubes.

Indications	No. of patients
Post-intubation stenosis	57 (43 group I, 14 group II)
Failure of previous surgical treatment	9 (9 group III)
Trauma	5 (4 group I, 1 group II)
Tracheomalacia	2 (2 group I)
Idiopathic stenosis	2 (2 group I)
Total no.	75

Thoracic Surgery of the San Raffaele Scientific Institute of Milan, Italy. Eighty-three of these patients underwent airway resection and reconstruction as the only treatment. Seventy-five other patients with complex lesions or major associated diseases were treated with a Montgomery T-tube, in 7 patients with a laryngotracheal stenosis after unsuccessful treatment with Dumon stents. The Dumon stents were removed following migration into the distal trachea. Mean age of the 75 patients was 48 years (range 13—72). Forty-four patients were male and 31 female. Fifty-three patients had a tracheal and 22 a laryngotracheal stenosis. Mean length of the stenosis was 4.2 cm (range 2.5—7). The aetiology of the stenoses is reported in Table 1.

Montgomery T-tube placement was the only treatment in 51 patients with a permanent contraindication to surgery (group I), due in 22 patients to an excessive length of the stenosis, and in 29 to associated severe cardiac or respiratory illness. The T-tube was placed as a temporary airway support before surgery in 15 patients (group II): in 11 of these to wait for severe acute inflammation of the tracheal mucosa to subside and in 4 patients to enable them to undergo neurosurgical or orthopaedic procedures requiring mechanical ventilation prior to tracheal reconstruction. In a further group of 9 patients (group III), the T-tube was used to treat complications of airway reconstructive surgery: anastomotic dehiscence in 7 patients and re-stenosis in 2. Five of these 9 patients were referred from other institutions following failed airway reconstruction.

The T-tubes were positioned under general anaesthesia and spontaneous ventilation. Flexible or rigid bronchoscopy was first performed to assess the length of the stenosis, the distance of the stenosis to the vocal cords and to the carinal spur, and airway diameter. Dilation of the stenosis before T-tube insertion was performed in 18 patients with Jackson rigid bronchoscopes of increasing diameter. Surgical exploration before T-tube insertion was required in 8 patients with a complete occlusion of the airway and in 3 patients with an oblique stoma. These oblique stomas had to be re-positioned to create a horizontal tract so that the external branch of the stent could be correctly positioned. Kelly forceps were used to grasp the distal end of the tube for insertion through the tracheal stoma under rigid or flexible bronchoscopic control. The external arm of the tube was occluded with a plug a few hours after positioning. Saline solution was instilled daily and then suctioned throughout the hospital stay and patients were instructed to continue the procedure after discharge. Flexible bronchoscopic control was performed every three months through the external arm. The T-tubes were removed after an interval of 9—12 months, and a new T-tube was placed if the stenosis persisted. If the stenosis resolved, the T-tube was removed, a stoma stent was inserted to maintain tracheal stoma patency, and subsequently removed. Three patients had surgical closure of a persistent tracheal stoma.

3. Data analysis

Follow-up was obtained in all patients. Time from T-tube placement and removal was calculated in months in each patient. The percentage of patients who still had a Montgomery T-tube in place (freedom from T-tube removal) was calculated at different times in the three groups of patients using the Kaplan—Meier method with the SPSS software, version 16.0 (SPSS Inc., Chicago, IL).

4. Results

There were no deaths following T-tube positioning. Six patients died of cardiac failure during follow-up. Complications after T-tube placement were observed in 27 out of 75 patients, 20 of them requiring treatment. Dislocation outside the airway due to excessive traction on the external arm of the T-tube during suction was observed in 3 (4%) patients, treated temporarily with the positioning of a tracheostomy cannula, and then by repositioning a new T-tube. Granulomas at the proximal or distal end of the T-tube were observed in 14 (19%) patients. In 7 of these patients treatment with steroid infiltration, Argon or LASER coagulation was performed. Three patients (4%) had a subglottic oedema requiring temporary insertion of a tracheostomy cannula, and 7 patients (9.3%) had secretion retention with partial stent obstruction requiring bronchoscopic cleaning of the T-tube.

Twelve of the 51 patients (24%) in group I, in whom Montgomery T-tube placement was the only procedure adopted, had a resolution of the stenosis after an interval of 35.3 ± 8.2 months and T-tube removal occurred in 3 out of 4 patients with traumatic lesions of the trachea, specifically with a partial disruption of the tracheal wall, and 9 of the 43 patients with a post-intubation stenosis. Six patients died of unrelated cardiological causes during follow-up with the T-tubes in place. The remaining patients are alive with the T-tube still in place after a mean follow-up of 82.8 ± 8.3 months. After 5 years 82% of the patients had the T-tube in place (mean 129.9 ± 8.6 months, median not reached) (Fig. 1).

In the 15 patients in group II, who underwent temporary T-tube placement the tubes were maintained in place before surgery for 17.1 ± 4.8months. Fourteen of these patients had a post-intubation stenosis and one a traumatic tracheal lesion with a tracheal stenosis located 2 cm above the carina and treated with an extra-long stent. Twelve patients underwent a tracheal and three a laryngotracheal resection and reconstruction following stent removal, with favourable results in all cases. After 5 years the T-tubes were in place in 7% of the patients (mean 17.1 ± 4.8, median 13.0 ± 1.3 months) (Fig. 2).

Of the 9 patients in group III, six had undergone surgical treatment for post-intubation stenosis and three for post-intubation tracheo-oesophageal fistulas. Seven of these

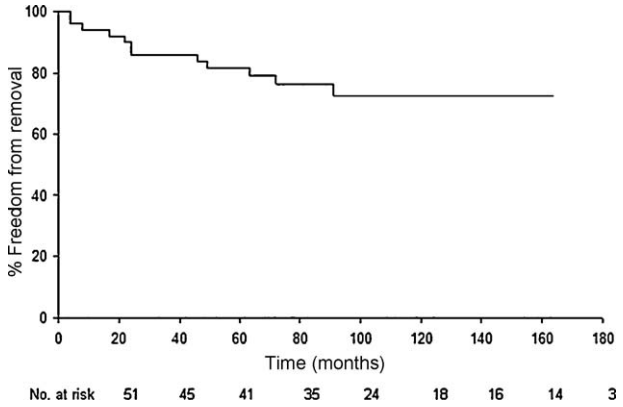

Fig. 1. Kaplan—Meier product limit estimates of freedom from T-tube removal in patients with a contraindication to surgery (group I). After 5 years 82% of the patients had the T-tube in place (mean 129.9 ± 8.6 months, median not reached).

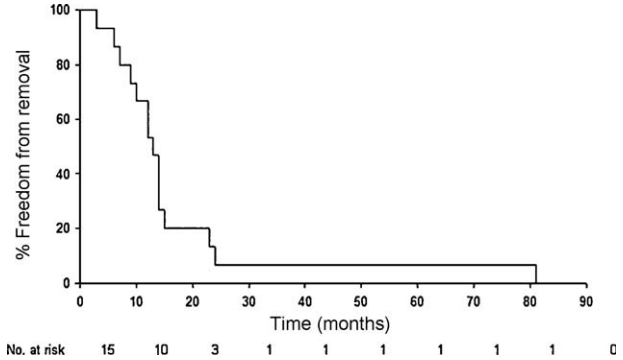

Fig. 2. Kaplan—Meier product limit estimates of freedom from T-tube removal in patients treated before surgery (group II). After 5 years 7% of the patients had the T-tube in place (mean 17.1 ± 4.8, median 13.0 ± 1.3 months).

patients had a dehiscence of the tracheal anastomosis and two a re-stenosis following surgery. The T-tubes were removed in 3 out of the 7 patients with a partial dehiscence of the anastomosis after a mean period of 115.3 ± 3.7 months. In the remaining 4 patients who had a complete separation of the anastomosis and in the 2 patients who had a re-stenosis after surgical treatment, the T-tubes are still in place after a mean period of 91 ± 20.3 months (Table 2). After a period of 5 years all the patients of group III still had a T-tube in place (mean 129.2 ± 7.2, median 120.0 ± 2.1 months) (Fig. 3).

Table 2
Outcome of treatment with Montgomery T-tubes (total no. 75 patients).

Indications	No. of patients	Outcome
Contraindication to surgical treatment (group I)	51	T-tube removed (12 patients) T-tube in place (33 patients) Death from unrelated causes (6 patients)
Temporary stenting before surgery (group II)	15	T- tube removed (15 patients)
Complications of surgical treatment (group III)	9	T- tube removed (3 patients) T- tube in place (6 patients)

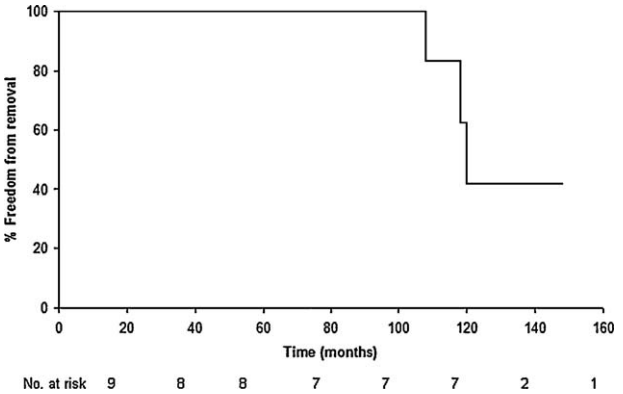

Fig. 3. Kaplan—Meier product limit estimates of freedom from T-tube removal in patients with complications of airway reconstruction (group III). After 5 years 100% of the patients still had a T-tube in place (mean 129.2 ± 7.2, median 120.0 ± 2.1 months).

5. Discussion

Single-stage tracheal resection and reconstruction is the treatment of choice for benign airway stenosis involving the trachea and subglottic larynx. An accurate preoperative selection of the candidates for surgical treatment and correct timing of the procedure is mandatory to obtain favourable results. Surgery may, however be temporarily or permanently contraindicated in patients with airway stenosis because of the excessive length of the lesion, severe acute inflammation of the airway or associated diseases. In these cases tracheostomy or airway stenting may be indicated as a temporary procedure or as a definitive treatment. The use of a tracheostomy cannula diverts the normal airflow from the larynx and is associated with severe limitations in phonation and humidification of secretions. Endoluminal silicon or metallic airway stents, which do not require a tracheostomy and are the most frequently used devices in the conservative treatment of tracheal stenosis, may provoke in certain conditions other complications. Silicon stents, the most used being the Dumon stent [3], have a relatively high incidence of migration in patients with laryngotracheal stenosis or tracheomalacia. A significant risk of obstruction due to secretions is also present when endoluminal stents are used in patients with a long airway stenosis or impaired coughing. Bolliger et al. reported migration of the Dumon stent in 3 out of 31 patients who had short (less than 2.5 cm) or conical malignant stenosis [4]. Mitsuoka et al. reported Dumon stent migration in 6% and obstruction due to secretions in 9% of 35 patients with benign and malignant airway stenosis [5]. Martinez-Ballarin et al. in a group of 64 patients with benign tracheal stenosis treated with Dumon stents also observed migration in 18% and obstruction in 6% of the patients [6].

Expandable metallic stents may be contraindicated in patients with benign stenoses [7] mainly because they are difficult to remove. This limitation makes them unsuitable for temporary stenting. Ideally, a tracheal stent is easy to place and remove, does not migrate, cause obstruction or create significant inflammation of the airway, is inexpensive and biocompatible. In the absence of such stents, long-standing models like the T-tube are therefore still being used in clinical practice to treat airway stenosis.

The first tracheal T-tube, described by Bond in 1891, was a metal tube made of two halves held together by a collar [8]. The present form of the tracheal T-tube was devised in 1965 by Montgomery and is currently available as a flexible silicon device [2]. Although it requires a tracheostomy, the T-tube has the advantage of being adaptable to the characteristics of individual patients as its arms may be modified for exact fit. T-tubes are available in various lengths and diameters, which extends its use to paediatric patients [9]. T—Y stents are also manufactured for the treatment of stenosis involving the carina and main stem bronchi. Contraindications to the use of T-tubes are limited to the need for mechanical ventilation or to factors such the inability to cough. The presence of laryngeal obstruction, which does not allow the external arm of the stent to be closed, leads to a high risk of stent obstruction by dried secretions.

T-tubes have a number of advantages over totally endoluminal stents. Firstly, they allow easier clearance of secretions and cleaning through the external arm of the stent, therefore reducing the risk of obstruction when the stenosis is long. Secondly, the risk of migration or accidental dislocation because of undue traction on the external arm of the stent, as observed in our series, is extremely limited although it may be relatively higher in patients with short T-tubes. Finally, the possibility of verifying stent patency during follow-up with a flexible bronchoscope through the sidearm of the T-tube significantly reduces patient discomfort. These characteristics also make the T-tube a viable alternative following failure of treatment with other more modern stents. Seven of our patients had been previously treated with a Dumon stent, which had to be removed because of stent migration. All these patients had a stenosis of the crico-tracheal region. The Montgomery T-tube proved to be superior to Dumon stents for laryngotracheal stenosis requiring stenting with a reduced risk of stent migration due to the stabilising effect of the sidearm.

T-tubes are relatively simpler to place and substitute than other types of stents since the procedures are usually performed during sedation through the tracheostomy under fiberoptic control. When this is not possible for anatomic reasons, the T-tube may be positioned with the aid of a rigid bronchoscope. Various techniques have been proposed to facilitate T-tube placement in special circumstances. In 47 patients with complex airway problems Cooper et al. described the use of a tracheostomy tape passed through the sidearm and the upper part of the T-tube and then grasped with endoscopic forceps during rigid bronchoscopy to ease the insertion of the proximal arm of stent. The same authors also described a translaryngeal placement technique by inserting the stent over the distal end of a rigid bronchoscope and by pushing it in place by means of an endotracheal tube positioned over the scope proximally to the T-tube, while retracting the bronchoscope [10].

We always positioned the T-tubes through the tracheal stoma, and resorted to surgical exploration only when the airway was completely obstructed or when an oblique tracheostomy had to be re-positioned in order to correctly insert the horizontal tract of the stent. Rigid bronchoscopy was required only when the stenosis had to be dilated before tube insertion.

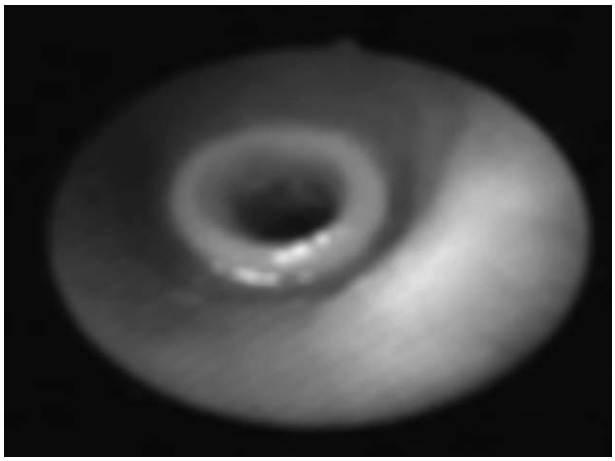

Fig. 4. Use of a T-tube in a laryngotracheal post-intubation stenosis: endoscopic view of the proximal end of the stent in the subglottic larynx.

Choosing the appropriate diameter and length of the T-tube and positioning it correctly are crucial factors for a successful outcome. The diameter of the tube was selected on the basis of radiological or endoscopic measurements and observations. The T-tube size chosen was the largest diameter which would fit snugly into the airway, but not too tightly to avoid causing excessive pressure on the tracheal wall mucosa, as this could provoke the formation of granulomas or stenoses. The T-tube was trimmed to exact length so as to completely cover the stenosis leaving an extra 3 mm margin proximally and distally. It was ensured that the trimmed edges were smooth to prevent inflammation. T-tube should be positioned with its proximal end distally to the conus elasticus of the subglottic larynx in order to avoid subglottic oedema or granuloma formation (Fig. 4). When this is not possible as, for instance, when the stenosis involves the larynx and extends to the vocal cords, transglottic positioning of the T-tube has been used in selected cases [10], although there is a higher risk of inhalation and a whispered voice (Fig. 5). Other authors also describe a technique that improves the impaired quality of life of patients with a tracheostomy: the external arm of the T-tube is shortened and buried in the subcutaneous tissue. The T-tube thus becomes similar to an endoluminal stent, with the only advantage of being more stable [11].

In our experience, the T-tube proved to be successful in the treatment of benign airway stenosis, with a relatively limited incidence of complications in comparison to previous reports. Liu et al. described the use of a T-tube in a group of 53 patients with benign laryngotracheal stenosis and reported five postoperative deaths with a respiratory success rate of 71.8%. In 28 out of these 53 patients, the T-tube was successfully removed after stenotic healing [12]. We were able to remove the T-tube once the stenosis had stabilised in all 15 patients who underwent subsequent surgical treatment, in 12 patients who only had conservative treatment and in 3 with airway complications following prior reconstructive surgery after a mean period of 40 months. The stenosis healed in 3 out of 4 patients with post-traumatic lesions (75%), in 9 out of 43 patients with post-intubation lesions (21%) and in 3 out of 7 patients with anastomotic

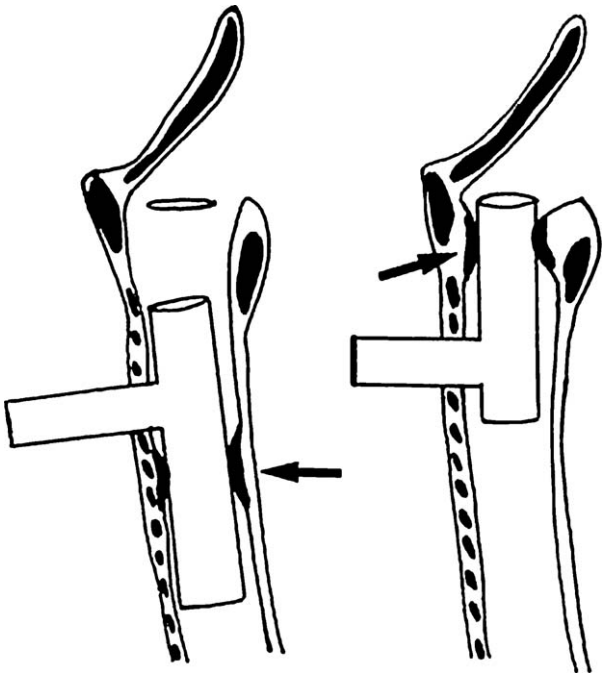

Fig. 5. Subglottic and transglottic positioning of the Montgomery T-tube.

dehiscence (43%). As observed by Gaissert et al., the degree of success in treating stenosis with T-tube placement depends on the presence of a partial lesion of the tracheal wall with preservation of cartilagineous structure at the level of the stenosis, without complete loss of tracheal wall stability. In their series of 140 patients with benign and malignant airway stenosis, the T-tube was the only treatment in 16 patients and was removed after a mean period of 20.9 months. These authors also reported two cases of airway obstruction, although not clearly related to the presence of the T-tube and a case of lethal haemorrhage from the tracheal stoma [13].

In conclusion, despite the limitations related to the necessity of a tracheostomy, the Montgomery T-tube still represents a useful option in patients with complex benign stenosis or associated diseases as an alternative or complementary treatment to surgery, and is effective even when other more commonly used stents are unsuccessful, in particular in patients with laryngotracheal stenosis, in the presence of tracheomalacia, or in patients with a long stenosis, in whom the probability of occlusion of the stent by secretions is higher.

References

[1] Grillo HC, Donahue DM, Mathisen DJ, Wain JC, Wright CD. Postintubation tracheal stenosis. Treatment and results. J Thorac Cardiovasc Surg 1995;109:486—92.

[2] Montgomery WW. T-tube tracheal stent. Arch Otolaryngol 1965;82: 320—1.

[3] Dumon JF. A dedicated tracheobronchial stent. Chest 1990;97:328—32.

[4] Bolliger CT, Probst R, Tschopp K, Solèr M, Perruchoud AP. Silicone stents in the management of inoperable tracheobronchial stenosis. Indications and limitations. Chest 1993;104:1653—9.

[5] Mitsuoka M, Sakuragi T, Itoh T. Clinical benefits and complications of Dumon stent insertion for the treatment of severe central airway stenosis or airway fistula. Gen Thorac Cardiovasc Surg 2007;55:275—80.

[6] Martinez-Ballarin JI, Diaz-Jimenez JP, Castro MJ, Moya JA. Silicone stents in the management of benign tracheobronchial stenosis. Tolerance and early results in 63 patients. Chest 1996;109(3):626—9.

[7] Gaissert HA, Grillo HC, Wright CD, Donahue DM, Wain JC, Mathisen DJ. Complication of benign tracheobronchial strictures by self-expanding metal stents. J Thorac Cardiovasc Surg 2003;126:744—7.

[8] Bond CJ. Treatment of tracheal stenosis by a new T-shaped tracheostomy tube. Lancet 1891;1:539.

[9] Preciado D, Zalzal G. Laryngeal and tracheal stents in children. Curr Opin Otolaryngol Head Neck Surg 2008;16:83—5.

[10] Cooper JD, Todd TRJ, Ilves R, Pearson FG. Use of the silicone tracheal T-tube for the management of complex tracheal injuries. J Thorac Cardiovasc Surg 1981;82:559—68.

[11] Keszler P. The tracheal T tube: for indwelling intubation as an alternative management method. In: Grillo HC, Eschapasse H, editors. International trends in general thoracic surgery, vol. 2. Philadelphia: Saunders; 1987. p. 133—7.

[12] Gaissert HA, Grillo HC, Mathisen DJ, Wain JC. Temporary and permanent restoration of airway continuity with the tracheal T-tube. J Thorac Cardiovasc Surg 1994;107:600—6.

[13] Liu H-C, Lee KS, Huang CJ, Cheng CR, Hsu WH, Huang MH. Silicon T-tube for complex laryngotracheal problems. Eur J Cardiothorac Surg 2002;21:326—30.

Appendix A. Conference discussion

Dr A. Nakas (*Leicester, United Kingdom*): I just wanted to ask you, did you have any problems with the patients clearing their secretions through the T-tubes? In our experience the main problem that we had was that the patients were not able to clear them. As a result, some patients had to go home with portable suction, and we did have to perform periodic bronchoscopy further down the line in the long-term patients to clear their secretions. Did you experience any problems?

Dr Carretta: The risk of obstruction, usually an incomplete obstruction of the stent, is lower than with endoluminal stents but is also observed with T-tubes. The patient must maintain cough efficacy. With a quite normal vocal cord function, the cough is effective in cleaning the T-tube. The T-tubes also have to be maintained closed to allow adequate cleaning of the stent. If the patient keeps the stent open, you have dried secretions and the risk of obstruction is much higher. So, yes, we also observed this complication, but usually that depends on the selection of the patients. A tracheostomy cannula is indicated if the patient has an ineffective cough.