CPD • Clinicopathological case

CED
Clinical and Experimental Dermatology

CPD

Multiple nodules on the scrotal wall

S. Giacalone,[1] G. Genovese[1] and M. Cusini[2]

[1]*Department of Medical-Surgical Physiopathology and Transplants, Università degli Studi di Milano, Milan, Italy; and* [2]*UOC Dermatology, Fondazione IRCCS Ca' Granda Ospedale Maggiore Policlinico, Milan, Italy*

doi: 10.1111/ced.14796

Clinical findings

A 34-year-old Moroccan man with Fitzpatrick skin type IV presented to the sexually transmitted diseases centre with multiple painless nodules involving the scrotum. The first lesions had appeared when he was 15 years old and had increased progressively in number and size. The patient was concerned about cosmesis and discomfort; however, the condition had not interfered with sexual relations or fertility. His medical history was unremarkable. There was no history of trauma, ulcers or infections of the genital area, and the patient denied any other skin diseases. He worked as a manual labourer.

On clinical examination (Fig. 1a,b), almost the entire scrotal wall was seen to be covered by multiple, firm, hard, subcutaneous nodules with sparing of the median raphe skin. The largest nodule was about 20 mm in size. Laboratory investigations showed serum calcium, phosphate, and parathyroid hormone levels to be within the normal range. Ultrasonography of the testicles did not reveal any abnormalities.

Histological findings

Histological examination showed a dermal globular nodule containing amorphous and homogeneous substances, corresponding to multifocal deposits of calcium (Fig. 2a) surrounded by inflammatory reaction (Fig. 2b). The patient was referred to the plastic surgeons for wide local excision.

Correspondence: Dr Serena Giacalone, Unità Operativa di Dermatologia, Fondazione IRCCS Ca' Granda, Ospedale Maggiore Policlinico, Via Pace 9, Milan, Italy
E-mail: serenagiacalone92@gmail.com

Conflict of interest: the authors declare that they have no conflicts of interest.

Accepted for publication 8 June 2021

What is your diagnosis?

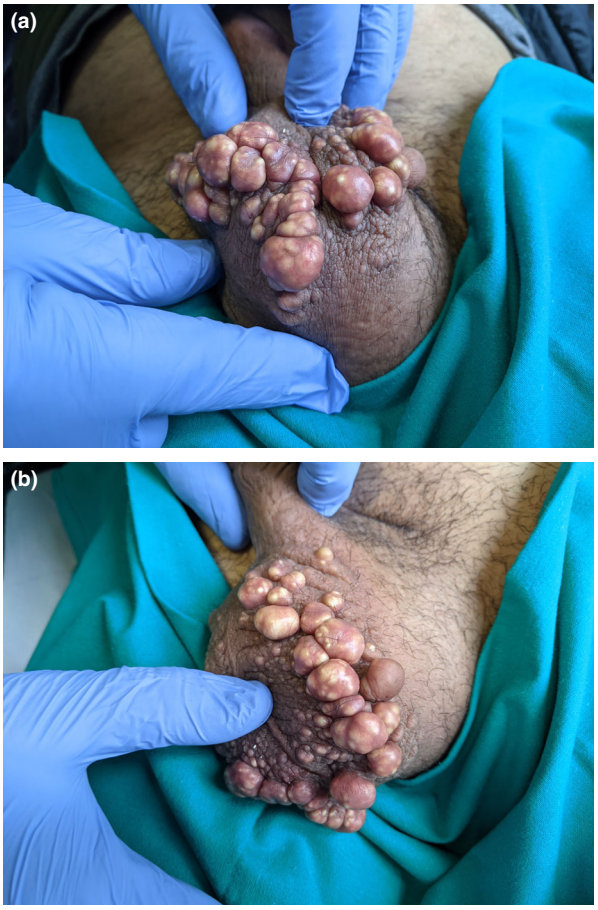

Figure 1 (a,b) Scrotal wall covered in multiple, firm, nontender, subcutaneous nodules with sparing of the median raphe skin.

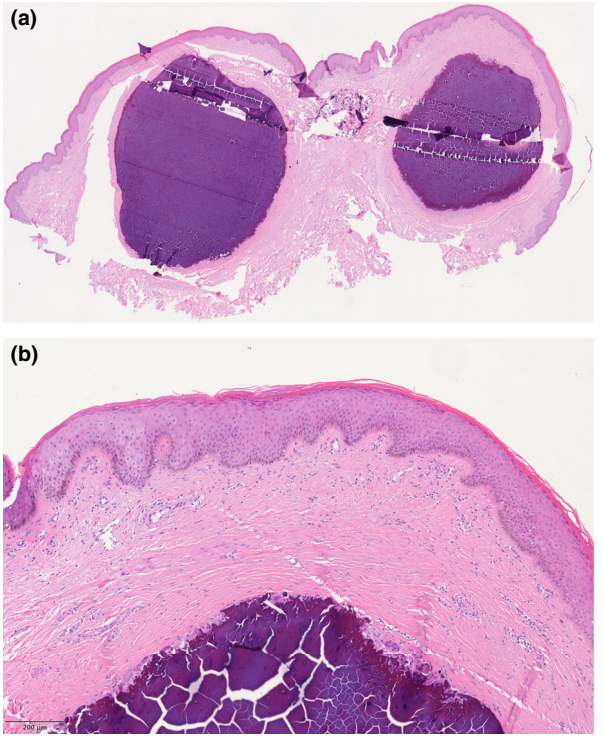

Figure 2 (a) Dermal globular nodule containing amorphous and homogeneous substances, corresponding to multifocal deposits of calcium. (b) Calcified nodule embedded in connective tissue matrix and partly rimmed by foreign body giant cell reaction; epidermis shows hyperplastic epithelium with basal hyperpigmentation. Haematoxylin and eosin, original magnification (a) × 10; (b) × 40.

Diagnosis

Idiopathic scrotal calcinosis (ISC).

Discussion

ISC is a rare benign condition characterized by the presence of multiple painless nodules limited to the scrotal wall. The nodules are confined to the dermis and appear firm and yellowish-brown, with white chalky material present. Usually, the first lesions appear during puberty with variable progression throughout adulthood. There is no association with calcium metabolic diseases or other systemic comorbidities. Accompanying symptoms are rare; sometimes patients complain of discomfort, itching and sense of heaviness, but usually cosmetic concerns trigger consultations.[1]

ISC was first described in 1983 by Lewinsky, but it was named in 1970 by Shapiro who demonstrated the absence of a cyst wall in 14 collected cases of ISC.[2] However, the term 'idiopathic' is still debated; subsequent studies that analysed nodules with varying stages of inflammation demonstrated the predominance a cyst lining in the early stages and calcification in the later stages of the disease. Numerous pathogenetic mechanisms have been proposed, including calcification of epidermoid cysts secondary to infections, eccrine epithelial cysts or degenerated dartos muscle. Histology shows deposits of calcium, surrounded by a granulomatous reaction.[3] Surgery is a curative option with satisfactory cosmetic outcomes and low rate of recurrence.[4] We offered our patient surgery at our hospital, but he preferred to have the surgery at a hospital local to his home; he was then lost to follow-up.

Acknowledgement

We thank the patient for their written informed consent to publication of the case details and images.

Learning points

- ISC is a rare benign condition that starts in puberty with one or more painless nodules on the scrotal wall, and shows variable progression of lesions over time.
- ISC have no association with calcium metabolic diseases or other systemic comorbidities.
- Surgery is the best curative option in terms of satisfactory cosmetic outcomes and low rate of recurrence.

References

1 Syed MMA, Rajbhandari A, Paudel U. Idiopathic calcinosis cutis of the scrotum: a case report and review of the literature. *J Med Case Rep* 2018; **12**: 366.
2 Shapiro L, Platt N, Torres-Rodríguez VM. Idiopathic calcinosis of the scrotum. *Arch Dermatol* 1970; **102**: 199–204.
3 Killedar MM, Shivani AA, Shinde U. Idiopathic scrotal calcinosis. *Indian J Surg* 2016; **78**: 329–30.
4 Kyei MY, Djagbletey R, Abrahams AD, Mensah JE. Idiopathic scrotal calcinosis: a *case* report and review of postoperative outcomes. *Case Rep Urol* 2020; **2020**: 8877695.

CPD questions

Learning objective

To focus differential diagnosis and histological criteria of idiopathic scrotal calcinosis.

Question 1

Which of the following diseases is considered a differential diagnosis of idiopathic scrotal calcinosis?

(a) Sarcoidosis
(b) Hidradenitis suppurativa.
(c) Basal cell carcinoma.
(d) Calcified sebaceous cyst.
(e) Acne fulminans.

Question 2

Which of the following histological features is typical of idiopathic scrotal calcinosis?

(a) Parakeratosis.
(b) Asteroid bodies.
(c) Band-like lymphocytic infiltrate.
(d) Multifocal deposits of calcium.
(e) Focal ulceration and erosion.

Instructions for answering questions

This learning activity is freely available online at http://www.wileyhealthlearning.com/ced

Users are encouraged to

- Read the article in print or online, paying particular attention to the learning points and any author conflict of interest disclosures.
- Reflect on the article.
- Register or login online at http://www.wileyhealthlearning.com/ced and answer the CPD questions.
- Complete the required evaluation component of the activity.

Once the test is passed, you will receive a certificate and the learning activity can be added to your RCP CPD diary as a self-certified entry.

This activity will be available for CPD credit for 2 years following its publication date. At that time, it will be reviewed and potentially updated and extended for an additional period.