

# Effects of a nutraceutical supplement in the management of mild equine squamous gastric disease in endurance horses

Chiara Maria Lo Feudo<sup>1</sup>  | Luca Stucchi<sup>2</sup>  | Bianca Conturba<sup>2</sup>  |  
Elena Alberti<sup>1</sup>  | Enrica Zucca<sup>1</sup>  | Francesco Ferrucci<sup>1</sup> 

<sup>1</sup> Department of Veterinary Medicine, Equine Sports Medicine Laboratory “Franco Tradati”, Università degli Studi di Milano, Lodi, Italy

<sup>2</sup> Veterinary Teaching Hospital, Università degli Studi di Milano, Lodi, Italy

## Correspondence

Ferrucci Francesco, Department of Veterinary Medicine, Equine Sports Medicine Laboratory “Franco Tradati”, Università degli Studi di Milano, via Università 6, Lodi, Italy.  
Email: [francesco.ferrucci@unimi.it](mailto:francesco.ferrucci@unimi.it)

## Funding information

Tecnozoo S.R.L.

## Abstract

**Introduction:** Equine squamous gastric disease (ESGD) may require prolonged treatments with acid suppressants; therefore, interest in nutraceutical supplements with anti-ulcerogenic properties has increased. This study aims to investigate the efficacy of Trophogast pellet for the treatment of ESGD in endurance horses.

**Material and methods:** Fifteen endurance horses were included based on their gastroscopic examination and randomly assigned to a treatment group, receiving Trophogast pellet for 30 days together with management changes, or to a control group, only subjected to management modifications. At the end of treatment, gastroscopy was repeated. Scores were assigned according to the Equine Gastric Ulcer Council scoring system. All horses were weighed at the beginning and at the end of the study. ESGD grades and weight before and after treatment were compared.

**Results:** At enrolment, median ESGD score in the treatment group was 2, while in the control group it was 1. After the treatment period, a significant decrease in ESGD grade was observed in the treatment group (median 1,  $p = 0.0078$ ), while there was no change in the control group (median 2). No significant weight change was observed in either group.

**Conclusion:** Trophogast pellet was effective at promoting healing of mild ESGD in endurance horses.

## INTRODUCTION

Equine gastric ulcer syndrome (EGUS) is a common clinical condition of the equine patient, representing a major cause of poor performance in sport horses.<sup>1</sup> In particular, the highest prevalence of gastric ulceration has been reported in Thoroughbred racehorses in training, varying from 82% to 94%,<sup>2–5</sup> while Standardbred racehorses in training show a prevalence of 63%–95%.<sup>6–8</sup> In adult horses, 75%–80% of ulcers are found in the squamous portion of the stomach,<sup>9</sup> primarily along the *margo plicatus*<sup>4,10</sup>; in fact, due to the lack of a protective layer of mucus and bicarbonate, the squamous mucosa is more susceptible to damage by hydrochloric acid, pepsin and bile acids.<sup>11</sup> This condition has been defined as equine squamous gastric disease (ESGD).<sup>1</sup> Only two studies have been reported about ESGD in endurance horses, showing a prevalence varying from 46% to 93% on the basis of their level of competition.<sup>12,13</sup> It has been observed that

the duration and intensity of training are correlated to increased prevalence, severity and number of lesions of the squamous mucosa<sup>2,8,14</sup>; since endurance horses exercise for longer periods compared to other sport horses,<sup>12</sup> they may be more exposed to these pathogenetic mechanisms, and therefore, at higher risk of developing ESGD.<sup>13</sup>

Although mucosal ulcers may heal spontaneously,<sup>15</sup> this is uncommon in horses in training or racing, and medical treatment is therefore required: omeprazole, a proton pump inhibitor, is considered the drug of choice for prevention and treatment of squamous ulceration, acting by suppressing acid secretion.<sup>1,5,11,16–22</sup> However, pharmacological treatment is expensive and may require prolonged administrations: therefore, interest in nutraceutical supplements with anti-ulcerogenic properties has increased and numerous studies have been carried out to evaluate their effectiveness in preventing and treating gastric ulceration.<sup>13,15,23–29</sup> Trophogast pellet is a feed

This is an open access article under the terms of the [Creative Commons Attribution-NonCommercial](https://creativecommons.org/licenses/by-nc/4.0/) License, which permits use, distribution and reproduction in any medium, provided the original work is properly cited and is not used for commercial purposes.

© 2021 The Authors. *Veterinary Record* published by John Wiley & Sons Ltd on behalf of British Veterinary Association

supplement designed to protect gastric mucosa, containing pectin, soy lecithin, zinc oxide and *Castanea sativa* Mill. (extract of sweet chestnut). Pectin–lecithin complexes have been studied experimentally, with variable results.<sup>13,15,23,25</sup> Pectins, when exposed to an acidic environment, are rendered into a gel that binds the bile acids of the gastroduodenal juice, protecting the mucosa from the effects of acidity<sup>15,30</sup>; moreover, they may help to stabilize the mucus, increase the buffering capacity of the stomach contents and stimulate a postprandial increase in gastric pH.<sup>31</sup> Lecithin is an exogenous phospholipid that tends to form a highly hydrophobic protective layer, reinforcing the acid-repellent properties of the phospholipids of the squamous mucosa.<sup>32,33</sup> Zinc oxide and *C. sativa* Mill. may provide an additional benefit due to their antioxidant properties, protecting the mucosa against the generation of damaging oxygen free radicals.<sup>34–39</sup> This study aims to investigate the efficacy of Trophogast pellet, administered for 30 days, for the treatment of spontaneously occurring ESGD in endurance horses in training.

## MATERIALS AND METHODS

### Horses

Among a population of patients referred to the Equine Unit of the Veterinary Teaching Hospital of the University of Milan for gastroscopic examination, 15 endurance horses from three different stables were selected for this study. To be enrolled, horses had to meet the following inclusion criteria: being in endurance training, being free from other clinical diseases, not receiving any medical treatment for EGUS, not affected by equine glandular gastric disease (EGGD), and not considered to have ESGD requiring medical therapy (grade 1–2 of 4 without concurrent clinical signs potentially attributable to EGUS).<sup>26</sup> Once enrolled into the study, horses were randomly assigned by a coin-flip to the treatment group (10 horses) or the control group (five horses). Before gastroscopic examination, a full physical examination was performed on all horses in order to exclude the presence of any other clinical disease.

### Gastroscopic examination

Gastroscopic examination was performed on Day 0 and 30, at the end of the treatment period. Before each gastroscopy, feed was withheld 6–8 h before endoscopy,<sup>26</sup> while water was freely accessible up to the time of examination.<sup>26,27</sup> All horses were examined with a video gastroscope (PV-G 34–325; Storz, Germany) connected to an aspirator pump (208-ACH; Faset, Italy). Horses were restrained with a twitch and sedated with detomidine hydrochloride (0.01 mg/kg IV; Domosedan; Vetoquinol, Italy). To enable observation of the squamous and glandular mucosae, the *margo plicatus* and the pylorus, the stomach was insufflated with air and the mucosa was rinsed of adherent food material and mucus with water through

**TABLE 1** Composition, analytical components and additives of Trophogast pellet

Composition:
Wheat semolina, pectin, beet sugar (sucrose), soy lecithin, molasses of sugar cane
Analytical components:
Raw protein 8%, raw fats 7%, raw fibre 5%, raw ash 15%, sodium < 0.1%, ash insoluble in HCl 12%
Additives per gram:
Oligo element compounds: 3b603 Zinc (zinc oxide) 0.0005 g
Binding agents, anti-agglomerates and coagulants: E554 sodium and aluminium silicate
Botanically defined natural products: <i>Castanea sativa</i> Mill.:
Chestnut extract 0.00018 g

the air/water channel of the endoscope. Whenever any lesion of the glandular mucosa was observed, the horses were excluded from the study. The squamous mucosa was graded by a single investigator using the Equine Gastric Ulcer Council 0–4 scoring system, as recommended by the Consensus Statement of the European College of Equine Internal Medicine<sup>1,11</sup>; the investigator remained blinded to the group allocation until all scores were assigned and recorded.

### Treatment

Once the gastric lesions had been scored, the treatment group received 200 g of Trophogast pellet (Equiplanet, Tecnozoo SRL, Italy) (Table 1) once daily for 30 days, together with changes in management (increase in pasture turnout, constant access to good-quality hay and reduction of nonstructural carbohydrate intake).<sup>40,41</sup> The control group, instead, underwent the same described management changes, without any adjunctive treatment, for 30 days. During this period, training regimen remained unchanged in both groups, at the discretion of their trainers. At the end of this period, the gastric lesions were re-evaluated gastroscopically and re-scored. Moreover, the horses were weighed before and after the treatment period.

### Statistical analysis

All data were evaluated for normality using a Shapiro–Wilk test. At enrolment, data for age and weight were normally distributed, while data for ESGD grade were not normally distributed. Age and weight between groups were compared using an unpaired Student's *t* test. The differences in sex and breed distribution between groups were evaluated by means of a Fisher's exact test. A Mann–Whitney *U* test was used to evaluate ESGD grades at enrolment between groups. A Wilcoxon paired test was used to assess changes in ESGD grades within groups over time, while a paired *t* test was used to evaluate weight variations within groups over time. Data are presented as mean  $\pm$  SD if normally distributed and as median and interquartile ranges (IQRs) if not normally distributed. Statistical significance was set at  $p < 0.05$ . Data were analyzed using a commercially available statistical software package (GraphPad Prism 9.1.0 for MacOS; GraphPad Software, San Diego, CA).

**TABLE 2** General information about the horses enrolled in the study, including age, sex, breed, body weight (BW), equine squamous gastric disease (ESGD) grade at Day 0 and ESGD grade at Day 30

Horse	Group	Age (years)	Sex	Breed	BW (kg)	ESGD grade Day 0	ESGD grade Day 30
1	T	12	M	Arabian	428	2	1
2	T	11	M	Arabian	383	2	1
3	T	9	M	Arabian	396	2	1
4	T	8	M	Arabian	420	2	1
5	T	9	G	Arabian	400	2	0
6	T	7	G	Arabian	443	1	1
7	T	10	G	Anglo-Arabian	472	1	1
8	T	9	M	Anglo-Arabian	525	2	1
9	T	14	G	Arabian	425	2	0
10	T	9	G	Anglo-Arabian	415	2	0
11	C	10	M	Arabian	458	1	1
12	C	9	G	Anglo-Arabian	475	1	2
13	C	10	G	Anglo-Arabian	460	1	0
14	C	16	G	Anglo-Arabian	400	2	2
15	C	11	G	Anglo-Arabian	515	2	2

Abbreviations: C, control; G, gelding; M, mare; T, treatment.

## Ethics approval statement

All procedures performed on horses were approved by the University of Milan Animal Welfare Organisation (Protocol Number OPBA\_156\_2019) and included informed owner consent.

## RESULTS

### Horses

The information about age, sex, breed, body weight, ESGD grade at Day 0 and 30 of the enrolled horses are reported in Table 2. The study population consisted of eight Arabian horses and seven Anglo-Arabian horses (5 mares, 10 geldings) and aged from 7 to 16 years (mean  $\pm$  SD: 10.27  $\pm$  2.31 years). At enrolment, there was no difference in baseline data between groups for age (treatment 9.8  $\pm$  2.15 years, control 11.2  $\pm$  2.78 years;  $p = 0.29$ ). Even if a greater percentage of males was present in the control group (four males, one female) compared to the treatment group (five males, five females), there was no significant difference in sex distribution between groups ( $p = 0.58$ ). Similarly, no significant difference was observed in breed distribution between groups ( $p = 0.12$ ). Physical examinations were within normal limits and there was no evidence of clinical disease in any of the horses before enrolment in the study. During the period of administration, no adverse events were observed and the product was readily consumed by all horses.

### Weight

The weight of the horses at enrolment varied from 383 to 525 kg (mean  $\pm$  SD: 441  $\pm$  42.76 kg). There

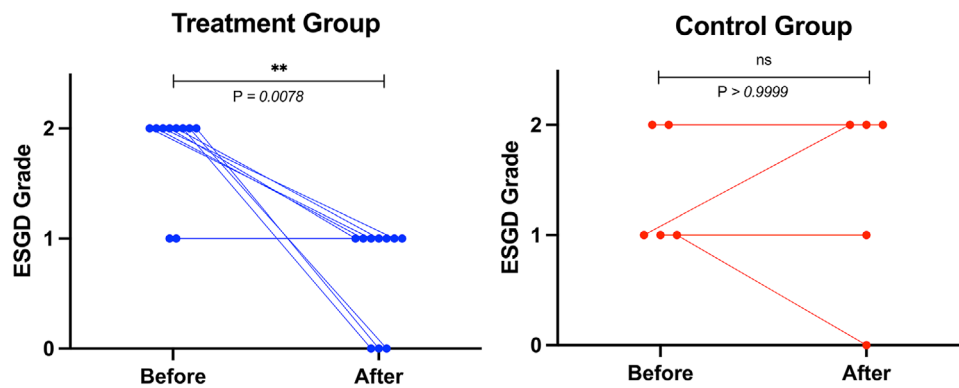
was no difference in baseline data between groups (treatment 430.7  $\pm$  47.73 kg, control 461.6  $\pm$  41.36 kg;  $p = 0.20$ ). After treatment time, the horses in the treatment group weighed from 398 to 490 kg body weight (mean  $\pm$  SD: 430.6  $\pm$  26.93 kg); the horses in the control group weighed from 388 to 490 kg (mean  $\pm$  SD: 456.6  $\pm$  41.08 kg). There was no change in weight over time in the treatment group ( $p = 0.9893$ ), nor in the control group ( $p = 0.51$ ).

### ESGD grade

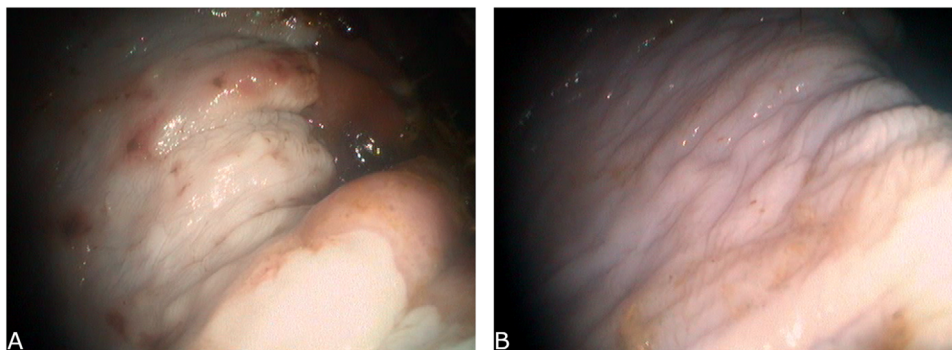
The squamous mucosa was adequately observed in all horses, both on Day 0 and 30. At enrolment, ESGD grades in the treatment group ranged from 1 to 2 (median 2, IQR 2–2), as well as in the control group (median 1, IQR 1–2). There was no difference between groups at enrolment regarding ESGD grades ( $p = 0.25$ ). After the treatment period, in the treatment group ESGD grades ranged from 0 to 1 (median 1, IQR 0–1), while in the control group they ranged from 0 to 2 (median 2, IQR 1–2). ESGD grades at the beginning and at the end of the study in the treatment group and the control group are displayed in Figure 1. A significant decrease in ESGD grade was observed in the treatment group ( $p = 0.0078$ ) (Figure 2); instead, there was no change over time in ESGD grade in the control group ( $p > 0.9999$ ).

## DISCUSSION

The results of this study suggest that Trophogast pellet may be effective at promoting healing of the squamous mucosa in endurance horses affected by mild ESGD. In fact, statistical analysis demonstrated a



**FIGURE 1** Equine squamous gastric disease (ESGD) grades before and after the treatment period in treatment (blue) and control (red) groups



**FIGURE 2** Gastroscopic view of one of the horses included in the treatment group at Day 0 (a) and 30 (b)

significant improvement in ESGD grade in the treatment group after treatment time. The administration of the supplement was accompanied by changes in management, which could have contributed to the reduction of gastric mucosa lesions and hyperkeratosis; indeed, stall confinement, intermittent feeding, and high in carbohydrates diets are considered to be important risk factors for EGUS<sup>40–45</sup>; therefore, increasing pasture turnout, providing ad libitum good-quality hay and reducing nonstructural carbohydrate intake may decrease the severity of EGUS.<sup>1,21,40,41,46</sup> However, the control group was also subjected to the same environmental and dietary modifications, without obtaining any improvement in ESGD grade: therefore, it is likely that the administration of Trophogast pellet had a decisive role in the healing of the squamous gastric mucosa. An improvement in the control group could also have been expected because of environmental and dietary changes. Although the trainers were instructed to make these modifications to the management of the horses, we were not able to control exactly which changes they actually accomplished. Moreover, we suggested to maintain the training regimen unchanged, but it is possible that the intensity of the training could have varied over time on the basis of the needs of the trainers; intense exercise has been reported to contribute to ulceration of the squamous mucosa.<sup>41,43,47</sup> The lack of monitoring of management modifications represents a limitation of the present study; however, we can reasonably assume that these changes were equal in both groups, since the horses shared the same stables and trainers.

The mechanism at the base of the efficacy of Trophogast pellet is likely to be multifactorial and could be explained by the properties of some of its components. Pectin–lecithin complexes have been investigated by various studies obtaining different results. In two different clinical trials, the results were promising, suggesting that pectin and lecithin may have a role in the treatment of EGUS in clinical circumstances<sup>13,15</sup>; however, both these studies did not include a control group, and it is therefore impossible to rule out that healing could have been achieved due to other factors (i.e., management changes). Two other studies failed to demonstrate a therapeutical effect in a fasting model of EGUS<sup>23,25</sup>; however, feed deprivation does not represent a reliable model of the multifactorial pathogenesis of EGUS and the conditions in which these studies were conducted were far from normal clinical situations. Therefore, to date the efficacy of pectin–lecithin complexes is still subject of debate. Furthermore, the other components of Trophogast pellet may have played a significant role in the efficacy observed. Zinc is reported to have an essential role in maintaining redox balance and protecting against oxidative stress,<sup>36–38</sup> and in controlling inflammatory reactions.<sup>37,48</sup> In horses affected by ESGD, chelated minerals containing zinc have been studied<sup>49</sup>; in particular, in one recent study zinc–methionine proved to be beneficial in reducing ESGD scores after omeprazole treatment.<sup>50</sup> Moreover, in human beings, zinc contributes to the maintenance of membrane barrier structure and function, which is especially important in the

gastro-intestinal tract<sup>37</sup>: in fact, serum zinc level is considered an indicator of gastric mucosal damage,<sup>51</sup> and zinc complexes have been reported to have anti-ulcer activity.<sup>37,52</sup> Also *C. sativa* Mill. (sweet chestnut extract) has natural antioxidant properties, mainly due to its content of phenolic compounds,<sup>34,35,39</sup> although its use for the treatment of gastric lesions has never been investigated.

Gastric ulceration is commonly associated with a poor body condition<sup>1,5,11,20,21,42</sup>; different studies have reported an increase in body weight after treatment, associated with an improvement in ulcer grades<sup>13,16,23,41</sup>. However, the results of the present study showed no significant difference in body weight before and after the treatment period, neither in the treatment group nor in the control group. It is reasonable that weight changes of the horses could be influenced by multiple factors, such as frequency and intensity of exercise, environmental variations and caloric density of food intake. Moreover, all the horses enrolled in this study were affected by low-grade sub-clinical ESGD, which likely did not influence body weight. Therefore, in our study, the improvement of ESGD grade was not associated with any significant weight changes.

In conclusion, Trophogast pellet was effective at promoting healing of mild ESGD in endurance horses, when administered for 30 days. These results suggest that it could be considered for use in horses affected by low-grade subclinical ESGD. However, the present study did not include grades 3–4 of ESGD: further investigations are needed to evaluate the efficacy of Trophogast pellet administered in association with standard pharmacological therapy for the treatment of more severe grades of ESGD. Moreover, the role of this supplement in the prevention of the onset of new mucosal lesions after discontinuation of pharmacological therapy and in the treatment of EGGD should be investigated.

#### ACKNOWLEDGEMENTS

The authors wish to acknowledge Dr. Monica Carraro and Mr. Andrea Treccani (TecnoZoo S.R.L., Italy) for the technical support during the trial and Dr. Giovanni Stancari for the help in performing the gastroscopic examinations. This study was funded by TecnoZoo S.R.L., which was involved in the development of the study design. Open Access Funding provided by Università degli Studi di Milano within the CRUI-CARE Agreement.

#### AUTHOR CONTRIBUTIONS

Conceptualization, C.M.L.F., L.S. and F.F.; methodology, C.M.L.F., L.S. and F.F.; formal analysis, C.M.L.F. and L.S.; investigation, C.M.L.F., L.S., B.C., E.A., E.Z. and F.F.; writing original draft preparation, C.M.L.F.; writing review and editing, C.M.L.F., L.S. and F.F.; visualization, C.M.L.F., L.S. and F.F.; supervision, F.F. All authors have read and agreed to the published version of the manuscript.

#### CONFLICT OF INTEREST

The authors declare no conflict of interest.

#### PEER REVIEW


The peer review history for this article is available at <https://publons.com/publon/10.1002/vetr.942>

#### DATA AVAILABILITY STATEMENT


The data that support the findings of this study are available from the corresponding author upon reasonable request.


#### ORCID

Chiara Maria Lo Feudo  <https://orcid.org/0000-0002-9964-2753>

Luca Stucchi  <https://orcid.org/0000-0002-2056-5426>

Bianca Conturba  <https://orcid.org/0000-0002-1302-3274>

Elena Alberti  <https://orcid.org/0000-0001-7819-6267>

Enrica Zucca  <https://orcid.org/0000-0003-0494-1329>

Francesco Ferrucci  <https://orcid.org/0000-0002-7285-9880>

#### REFERENCES

1. Sykes BW, Hewetson M, Hepburn RJ, Luthersson L, Tamzali Y. European College of Equine Internal Medicine consensus statement—equine gastric ulcer syndrome in adult horses. *J Vet Intern Med.* 2015;29(5):1288–99.
2. Murray MJ, Schusser GF, Pipers FS, Gross SJ. Factors associated with gastric lesions in Thoroughbred racehorses. *Equine Vet J.* 1996;28(5):368–74.
3. Vatisstas NJ, Snyder JR, Carlson G, Johnson B, Arthur RM, Thurmond M, et al. Cross-sectional study of gastric ulcers of the squamous mucosa in thoroughbred racehorses. *Equine Vet J Suppl.* 1999;29(29):34–9.
4. Begg LM, O'sullivan CB. The prevalence and distribution of gastric ulceration in 345 racehorses. *Aust Vet J.* 2003;81(4):199–201.
5. Bell R, Kingston JK, Mogg TD, Perkins NR. The prevalence of gastric ulceration in racehorses in New Zealand. *N Z Vet J.* 2007;55(1):13–8.
6. Dionne RM, Vrins A, Doucet MY, Pare J. Gastric ulcers in Standardbred racehorses: prevalence, lesion description, and risk factors. *J Vet Intern Med.* 2003;17(2):218–22.
7. Rabuffo TS, Orsini JA, Sullivan E, Engiles J, Norman T, Boston R. Associations between age or sex and prevalence of gastric ulceration in Standardbred racehorses in training. *J Am Vet Med Assoc.* 2002;221(8):1156–9.
8. Roy M-A, Vrins A, Beauchamp G, Doucet MY. Prevalence of ulcers of the squamous gastric mucosa in standardbred horses. *J Vet Intern Med.* 2005;19(5):744–50.
9. Andrews F, Bernard W, Byars D, et al. Recommendations for the diagnosis and treatment of equine gastric ulcer syndrome (EGUS). *Equine Vet Educ.* 1999;11(5):262–72.
10. Bezdekova B, Jahn P, Vyskocil M. Pathomorphological study on gastroduodenal ulceration in horses: localisation of lesions. *Acta Vet Hung.* 2007;55(2):241–9.
11. Ferrucci F, Zucca E, Croci C, Di Fabio V, Ferro E. Treatment of gastric ulceration in 10 standardbred racehorses with a pectin-lecithin complex. *Vet Rec.* 2003;152:679–81.
12. Nieto JE, Snyder JR, Beldomenico P, Aleman M, Kerr JW, Spier SJ. Prevalence of gastric ulcers in endurance horses—a preliminary report. *Vet J.* 2004;167(1):33–7.
13. Tamzali Y, Marguet C, Priymenko N, Lyazrhi F. Prevalence of gastric ulcer syndrome in high-level endurance horses. *Equine Vet J.* 2011;43(2):141–4.

14. Orsini JA, Hackett ES, Grenager N. The effect of exercise on equine gastric ulcer syndrome in the Thoroughbred and Standardbred athlete. *J Equine Vet Sci.* 2009;29(3):167-71.
15. Venner M, Lauffs S, Deegen E. Treatment of gastric lesions in horses with pectin-lecithin complex. *Equine Vet J Suppl.* 1999;29(29):91-6.
16. Murray MJ, Haven ML, Eichorn ES, Zhang D, Eagleson J, Hickey GJ. Effects of omeprazole on healing of naturally-occurring gastric ulcers in Thoroughbred racehorses. *Equine Vet J.* 1997;29(6):425-9.
17. Andrews FM, Sifferman RL, Bernard W, Hughes FE, Holste JE, Daurio CP, et al. Efficacy of omeprazole paste in the treatment and prevention of gastric ulcers in horses. *Equine Vet J Suppl.* 1999;29(29):81-6.
18. MacAllister CG, Sifferman RL, McClure SR, White GW, Vatis-tas NJ, Holste JE, et al. Effects of omeprazole paste on healing of spontaneous gastric ulcers in horses and foals: a field trial. *Equine Vet J Suppl.* 1999;29(29):77-80.
19. Endo Y, Tsuchiya T, Sato F, Murase H, Omura T, Korosue K, Nambo Y, Ishimaru M, Wakui Y. Efficacy of omeprazole paste in the prevention of gastric ulcers in 2 years old Thoroughbreds. *J Vet Med Sci.* 2012;74(8):1079-81.
20. Zavošti FR, Andrews FM. Therapeutics for equine gastric ulcer syndrome. *Vet Clin North Am-Equine Pract.* 2017;33(1):141-62.
21. Camacho-Luna P, Buchanan B, Andrews FM. Advances in diagnostics and treatments in horses and foals with gastric and duodenal ulcers. *Vet Clin North Am-Equine Pract.* 2018;34(1):97-111.
22. Mason LV, Moroney JR, Mason RJ. Prophylactic therapy with omeprazole for prevention of equine gastric ulcer syndrome (EGUS) in horses in active training: a meta-analysis. *Equine Vet J.* 2019;51(1):11-9.
23. Murray MJ, Grady TC. The effect of a pectin-lecithin complex on prevention of gastric mucosal lesions induced by feed deprivation in ponies. *Equine Vet J.* 2002;34(2):195-8.
24. Huff NK, Auer AD, Garza F, Keowen ML, Kearney MT, McMullin RB, Andrews FM. Effect of sea buckthorn berries and pulp in a liquid emulsion on gastric ulcer scores and gastric juice pH in horses. *J Vet Intern Med.* 2012;26(5):1186-91.
25. Sanz MG, Viljoen A, Saulez MN, Olorunju S, Andrews FM. Efficacy of a pectin-lecithin complex for treatment and prevention of gastric ulcers in horses. *Vet Rec.* 2014;175(6):147.
26. Sykes BW, Sykes KM, Hallowell GD. Efficacy of a combination of apolectol, live yeast (*Saccharomyces cerevisiae* [CNCM I-1077]), and magnesium hydroxide in the management of equine gastric ulcer syndrome in Thoroughbred racehorses: a blinded, randomized, placebo-controlled clinical trial. *J Equine Vet Sci.* 2014;34(11-12):1274-8.
27. Hellings IR, Larsen S. ImproWin® in the treatment of gastric ulceration of the squamous mucosa in trotting racehorses. *Acta Vet Scand.* 2014;56(1):13.
28. Woodward MC, Huff NK, Garza F, Keowen ML, Kearney MT, Andrews FM. Effect of pectin, lecithin, and antacid feed supplements (Egusin®) on gastric ulcer scores, gastric fluid pH and blood gas values in horses. *BMC Vet Res.* 2014;10(Suppl 1):S4.
29. Stucchi L, Zucca E, Serra A, Stancari G. Efficacy of the administration of a natural feed supplement in the management of equine gastric ulcer syndrome in 7 sport horses: a field trial. *Am J Anim Vet Sci.* 2017;12(3):104-10.
30. Rydning A, Berstad A. Influence of fiber on acidity, pepsin, and bile acids in human gastric juice in vitro. *Scand J Gastroenterol.* 1984;19(7):953-9.
31. Dunji BS, Svensson I, Axelson J, Adlercreutz P, Ar'rajab A, Larsson K, Bengmark S. Green banana protection of gastric mucosa against experimentally induced injuries in rats. *Scand J Gastroenterol.* 1993;28(10):894-8.
32. Lichtenberger LM. The hydrophobic barrier properties of gastrointestinal mucus. *Annu Rev Physiol.* 1995;57:565-83.
33. Ethell MT, Hodgson DR, Hills BA. Evidence for surfactant contributing to the gastric mucosal barrier of the horse. *Equine Vet J.* 2000;32(6):470-4.
34. Calliste C-A, Trouillas P, Allais D-P, Duroux J-L. *Castanea sativa* Mill. leaves as new sources of natural antioxidant: an electronic spin resonance study. *J Agric Food Chem.* 2005;53(2):282-8.
35. Silva V, Falco V, Dias MI, Barros L, Silva A, Capita R, et al. Evaluation of the phenolic profile of *Castanea sativa* mill. By-products and their antioxidant and antimicrobial activity against multiresistant bacteria. *Antioxidants* 2020;9(1):87.
36. Mousavi SM, Hajishafiee M, Clark CCT, Borges Do Nascimento IJ, Milajerdi A, Amini MR, et al. Clinical effectiveness of zinc supplementation on the biomarkers of oxidative stress: a systematic review and meta-analysis of randomized controlled trials. *Pharmacol Res.* 2020;161(May):105166.
37. Faa G, Nurchi VM, Ravarino A, Fanni D, Nemolato S, Gerosa C, Van Eyken P, Geboes K. Zinc in gastrointestinal and liver disease. *Coord Chem Rev.* 2008;252(10-11):1257-69.
38. Yu C, Mei X-T, Zheng Y-P, Xu D-H. Gastroprotective effect of taurine zinc solid dispersions against absolute ethanol-induced gastric lesions is mediated by enhancement of antioxidant activity and endogenous PGE2 production and attenuation of NO production. *Eur J Pharmacol.* 2014;740:329-36.
39. Frankić T, Salobir J. In vivo antioxidant potential of sweet chestnut (*Castanea sativa* Mill.) wood extract in young growing pigs exposed to n-3 PUFA-induced oxidative stress. *J Sci Food Agric.* 2011;91(8):1432-9.
40. Reese RE, Andrews FM. Nutrition and dietary management of equine gastric ulcer syndrome. *Vet Clin North Am-Equine Pract.* 2009;25(1):79-92.
41. Buchanan BR, Andrews FM. Treatment and prevention of equine gastric ulcer syndrome. *Vet Clin North Am-Equine Pract.* 2003;19(3):575-97.
42. Bell R, Mogg TD, Kingston JK. Equine gastric ulcer syndrome in adult horses: a review. *N Z Vet J.* 2007;55(1):1-12.
43. McClure SR, Carithers DS, Gross SJ, Murray MJ. Gastric ulcer development in horses in a simulated show or training environment. *J Am Vet Med Assoc.* 2005;227(5):775-7.
44. Nadeau JA, Andrews FM, Mathew AG, Argenzio RA, Blackford JT, Sohtell M, et al. The effect of diet on severity of gastric ulcers in horses. *Gastroenterology* 1998;114(4):973.
45. Murray MJ. Equine model of inducing ulceration in alimentary squamous epithelial mucosa. *Dig Dis Sci.* 1994;39(12):2530-5.
46. Smyth GB, Young DW, Hammond LS. Effects of diet and feeding on postprandial serum gastrin and insulin concentrations in adult horses. *Equine Vet J.* 1989;21(7S):56-9.
47. Orsini J. Gastric ulceration in the mature horse: a review. *Equine Vet Educ.* 2000;12(1):24-7.
48. Salga MS, Ali HM, Abdulla MA, Abdelwahab SI. Gastroprotective activity and mechanism of novel dichlorido-zinc(II)-4-(2-(5-methoxybenzylideneamino)ethyl)piperazine-1-iumphenolate complex on ethanol-induced gastric ulceration. *Chem Biol Interact.* 2012;195(2):144-53.
49. Andrews FM, Larson C, Harris P. Nutritional management of gastric ulceration. *Equine Vet Educ.* 2017;29(1):45-55.
50. Loftin P, Woodward M, Bidot WA, Cartmill J, Zoccarato S, Garza F, Jr, et al. Evaluating replacement of supplemental inorganic minerals with Zinpro Performance Minerals on equine gastric ulcers. *J Vet Intern Med.* 2012;26(3):737-8.
51. Zhang W-H, Wu X-J, Niu X-X, Yan H, Wang X-Z, Yin X-D, Pang Y. Serum zinc status and helicobacter pylori infection in gastric disease patients. *Asian Pacific J Cancer Prev.* 2012;13(10):5043-6.
52. Mei X-T, Xu D-H, Xu Si-Ka, Zheng Y-P, Xu S-Bo. Zinc(II)-curcumin accelerates the healing of acetic acid-induced chronic gastric ulcers in rats by decreasing oxidative stress and downregulation of matrix metalloproteinase-9. *Food Chem Toxicol.* 2013;60:448-54.

**How to cite this article:** Lo Feudo CM, Stucchi L, Conturba B, Alberti E, Zucca E, Ferrucci F. Effects of a nutraceutical supplement in the management of mild equine squamous gastric disease in endurance horses. *Vet Rec.* 2021;e942. <https://doi.org/10.1002/vetr.942>