

# A new leadless pacemaker with atrioventricular synchronous pacing replacing a still working VVI leadless pacemaker: a case report

Massimo Moltrasio<sup>1</sup>, Rita Sicuso <sup>1\*</sup>, Fabrizio Tundo <sup>1</sup>, and Claudio Tondo<sup>1,2</sup>

<sup>1</sup>Department of Clinical Electrophysiology and Arrhythmia, Heart Rhythm Center, Centro Cardiologico Monzino IRCCS, Via Carlo Parea 4, 20138 Milan, Italy; and <sup>2</sup>Department of Clinical Science and Community Health, University of Milan, Via della Commenda 19, 20122 Milan, Italy

Received 21 March 2021; first decision 18 April 2021; accepted 13 July 2021

## Background

A new intracardiac leadless pacemaker (ILP) has been developed to ensure atrioventricular (AV) synchrony (AVS) during ventricular pacing (VP). Recent studies have shown the feasibility and safety of accelerometer-based atrial sensing and an improvement in AVS among patients with atrioventricular block implanted with the Micra AV ILP (Medtronic Inc., Minneapolis, MN, USA). However, no data exists about the benefits of a VDD ILP in patients wearing a still working VVI Nanostim ILP (St Jude Medical, St Paul, MN, USA). We describe the feasibility of the procedure and the absence of device-related adverse events in the short-term follow-up.

## Case summary

We present the case of a 72-year-old man implanted with a VVI ILP (Nanostim, St Jude Medical, St Paul, MN, USA) on May 2014, who has developed symptomatic high percentage of VVI asynchronous pacing and was treated with an upgrade to synchronous AV pacemaker (PM) ILP—Micra AV (Medtronic Inc., Minneapolis, MN, USA), which has improved symptoms and functional class.

## Discussion

Intracardiac leadless pacemakers represent the best current option for patients requiring PM implantation who are at high risk of infection and bleeding. Our case shows that the new AVS ILP is a good alternative to VVI ILP in patients with sinus rhythm and a strong need for VP.

## Keywords

Case report • Leadless pacemaker • Micra TPS • Atrioventricular block • Atrioventricular synchronous pacing • Pacemaker syndrome

## Learning points

- Intracardiac leadless pacemakers (ILPs) were developed to reduce the short- and long-term risk of lead and pocket complications but were limited to single-chamber pacing.
- A new ILP ensures atrioventricular synchrony and reduces the risk of pacemaker (PM) syndrome.
- Concomitant presence of two different intracardiac leadless PMs in the right ventricle does not appear to be associated with adverse events.

\* Corresponding author. Tel: +39-0258002549, Email: [rita.sicuso@cardiologicomonzino.it](mailto:rita.sicuso@cardiologicomonzino.it)

Handling Editor: Christopher Wong

Peer-reviewers: Fabian Barbieri; Patrick Badertscher

Compliance Editor: Max Sayers

Supplementary Material Editor: Vishal Shahil Mehta

© The Author(s) 2021. Published by Oxford University Press on behalf of the European Society of Cardiology.

This is an Open Access article distributed under the terms of the Creative Commons Attribution-NonCommercial License (<http://creativecommons.org/licenses/by-nc/4.0/>), which permits non-commercial re-use, distribution, and reproduction in any medium, provided the original work is properly cited. For commercial re-use, please contact [journals.permissions@oup.com](mailto:journals.permissions@oup.com)

## Introduction

Permanent cardiac pacing delivered by conventional pacemaker (PM) is the cornerstone of the treatment of bradycardia.<sup>1</sup> Nevertheless, complications related to transvenous pacing leads and subcutaneous pockets may lead to device extraction and, consequently, to discontinuous pacing therapy. Intracardiac leadless pacemakers (ILPs) have been developed to overcome these events.<sup>2–4</sup> Recently, a new ILP, capable of ensuring atrioventricular synchrony (AVS) during ventricular pacing (VP) has been launched.<sup>5,6</sup> Micra AV (Medtronic Inc., Minneapolis, MN, USA) is the first ILP that is able to use a three-axis accelerometer-based algorithm to synchronize VP to the sensed mechanical contraction of the right atrium. Recent studies have shown the feasibility and safety of accelerometer-based atrial sensing and an improvement in AVS among patients with atrioventricular block (AVB) implanted with a Micra AV ILP.<sup>5,6</sup>

We present a case study of an implantation of an AVS ILP in a patient previously implanted with a VVI ILP who developed paroxysmal complete AVB, showing a high percentage of asynchronous pacing and symptoms that refer to a PM syndrome.

## Timeline

May 2014	<p>A 72-year-old man with paroxysmal II degree atrioventricular block, right bundle branch block, and normal left ventricular ejection fraction was implanted with a VVI intracardiac leadless pacemaker (ILP) (Nanostim, St Jude Medical, St Paul, MN, USA).</p> <p>At that time, the patient preferred an ILP implantation for aesthetic reasons.</p>
June 2020	<p>During a follow-up visit, the patient complained of exertional asthenia and dyspnoea.</p> <p>An increased percentage of ventricular pacing was detected during pacemaker (PM) interrogation. The electrocardiogram examination revealed a high percentage of VVI asynchronous pacing.</p> <p>Transthoracic echocardiogram was normal.</p> <p>An upgrade to synchronous atrioventricular leadless PM was performed according to patient preference.</p>
December 2020	<p>Follow-up visit and PM interrogation were accomplished.</p> <p>Clinical examination revealed improvements in patient symptoms with a normal functional class.</p>

## Case presentation

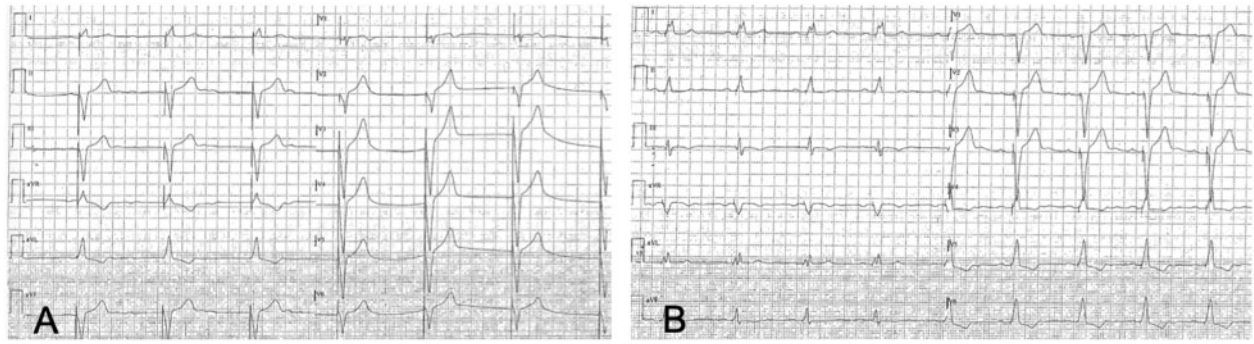
A 72-year-old man suffering from type 2 diabetes with paroxysmal II degree AVB, right bundle branch block, and normal left ventricular ejection fraction was implanted with a VVI ILP (Nanostim, St Jude Medical, St Paul, MN, USA) on May 2014. Following the patient's preference, it was decided to use an ILP instead of traditional pacing system. The ILP was successfully implanted in the low septum of the right ventricle. Routine device and clinical follow-up visits were performed every 6 months, reporting stable electrical parameters (sensing: 10 mV, Capture Threshold 1.3 v@ 0.24 ms and impedance: 870 Ohm), a low percentage of VP <5%, and a good clinical status. The ILP was programmed in VVI mode at 40 beats per minute (b.p.m.) to promote spontaneous conduction. On June 2020, during a routine follow-up, the patient reported the onset of exertional asthenia and dyspnoea, and an increased percentage of VP (42%) was detected. The electrocardiogram examination revealed a high percentage of VVI asynchronous pacing (*Figure 1A*). Cardiovascular examination was normal.

A change of programming was attempted to enable rate responsiveness, but without any improvement. Moreover, we performed an echocardiography examination that demonstrated a normal ejection fraction of both the right and left ventricle without any valvular abnormalities.

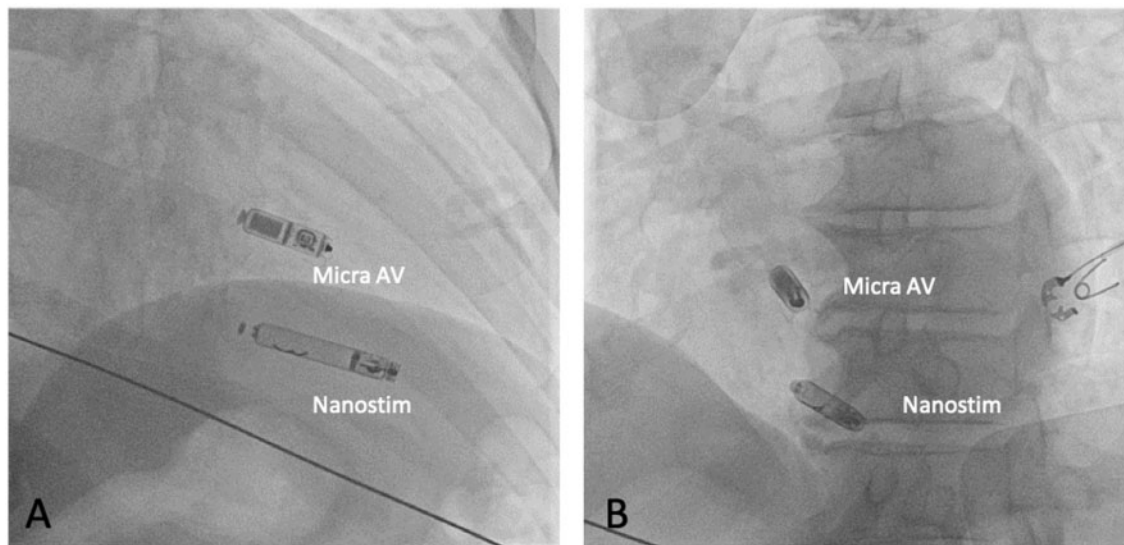
An upgrade to synchronous AV PM was proposed to increase AVS. The patient's preference was for AV ILP. After an evaluation on the safety and feasibility of extraction, it was decided to implant a new ILP instead of retrieving the old one. During the procedure, the previous implanted VVI ILP was left to VVI 40 b.p.m. and the magnet mode was switched off. Implantation was performed according to the manufacturer's training recommendation via the right femoral access. Micra™ Delivery Catheter (105-cm-long) inserted in the Micra™ Introducer (27-Fr outer diameter) allowed to deploy the AVS ILP on the mid-ventricular septum to avoid possible interference with the old VVI ILP (*Figure 2A and B*). Electrical measurements were good [right ventricular (RV) sensing: 6 mV, Capture threshold: 0.63 V @ 0.24 ms and impedance: 700 ohm]. A pull and hold test was performed to confirm the stability of the ILP fixation. At the end of the procedure, the previous VVI ILP was switched off. No complication occurred and the electrical parameters were confirmed the day after. The AV-ILP was programmed in VDD 40 b.p.m. (*Figure 1B*). At the 6th-month follow-up visit, the electrical parameters were stable and the AVS was achieved 72.6% of the time as showed by remote ILP control (*Figure 3*). No interactions were observed between the two devices. The patient-reported improvement in symptoms with a normal functional class, without any bleeding and infectious complications.

## Discussion

Intracardiac leadless pacemakers are an alternative to transvenous PMs in patients with previous device-related infection, venous access issues, previous device or leads extractions, comorbidities including renal failure and diabetes. Until now, ILP devices were able to provide only single-chamber pacing, therefore representing an acceptable solution for a limited target of patients (i.e. subjects with AVB requiring a low percentage of VP or sedentary patients<sup>2–4</sup>). The recently



**Figure 1** VVI RV low septal pacing (A) and VDD septal pacing (MICRA AV) (B).

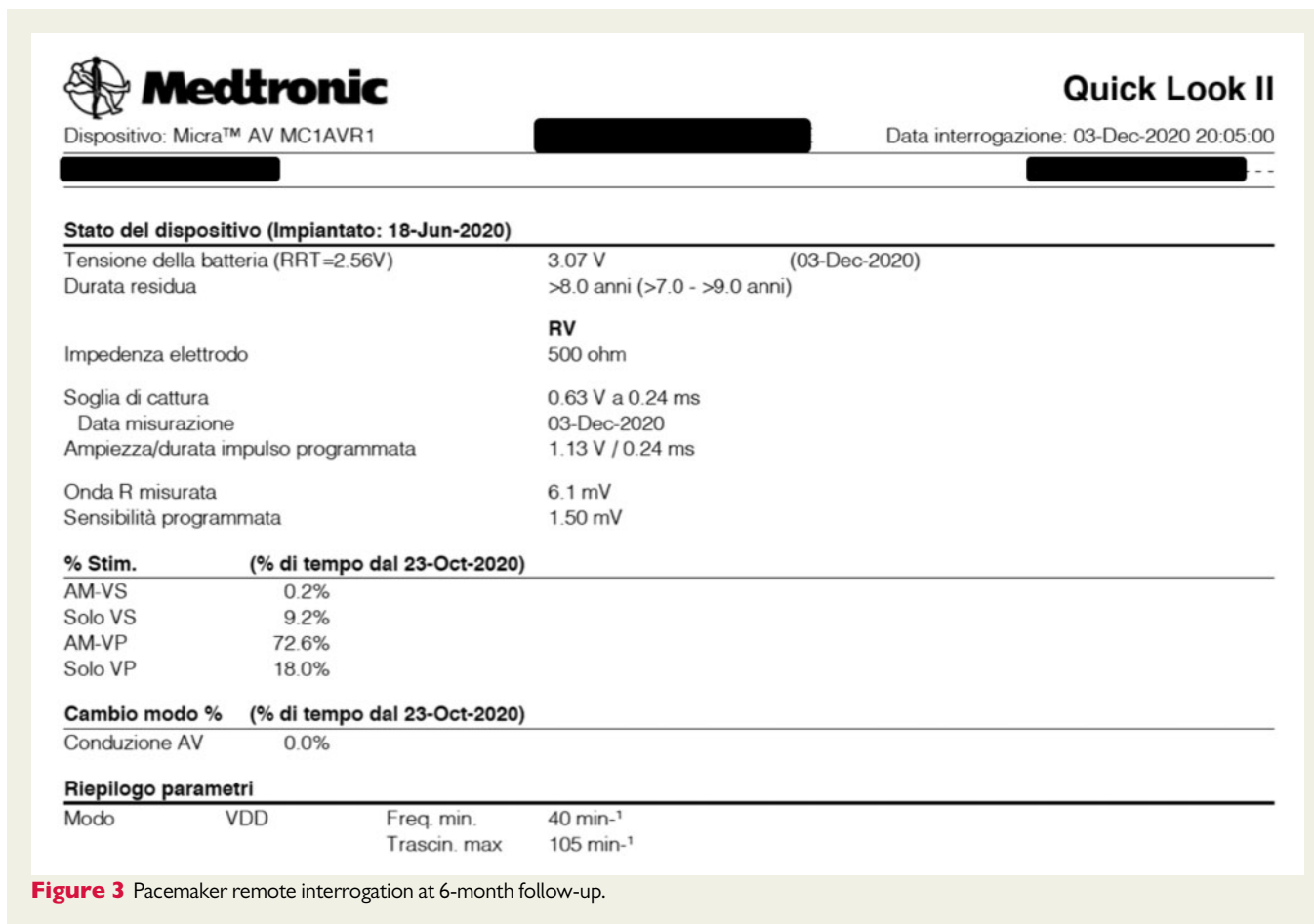


**Figure 2** Radiographs in the left and right anterior oblique projections (A and B) following implantation of the leadless pacemaker.

published MARVEL II study has demonstrated the safety and feasibility of atrial tracking by using the inbuilt 3D accelerometer. In particular, mean AVS during normal sinus rhythm was 89% and almost 80% in patients with complete AVB and intact AV conduction, respectively.<sup>5,6</sup> In our case report, the need for VP increased over time and the patient-reported symptoms which referred to a PM syndrome. The PM syndrome results from atrial contraction occurring during ventricular systole and is often a consequence of VP, so that we decided to promote atrial tracking and ventricular synchronous pacing to guarantee a higher percentage of AVS. This may lead to an increase in stroke volume, lower incidence of PM syndrome, and improvement in long-term cardiac functional status.<sup>7,8</sup> In our case, AVS was achieved in 72.6% due to the characteristic of Micra algorithm which reduces unnecessary RV pacing. After 1 min working in VDD mode, the device switches to VVI+ (40 b.p.m.) mode. If patient intrinsic AV conduction is detected, the device keeps pacing with the same mode until two out of four of the last ventricular events are paced, then it

returns to VDD mode. Micra AV tries to switch to VVI+ mode by assessing the AV conduction at increasing intervals until a maximum time of 8 h. Our report confirms no interference or adverse events due to the contemporary presence of two ILPs in the RV chamber, as previously reported.<sup>9,10</sup> Our decision to leave the old ILP was made according to a risk-benefit balance evaluation. We considered the long time from the index procedure (>6 years), the unpredictable degree of ILP encapsulation, the intrinsic risk of injury to the myocardium and all potential complications. On the other hand, we assessed the possible interference between the two devices and the need for a third ILP. Considering the promising published evidence reporting no complications associated with the concomitant presence of two ILPs in the right ventricle,<sup>9,10</sup> the second option seemed to be the preferable one.

Intracardiac leadless pacemakers represent the best current option for patients requiring PM implantation who are at high risk for infection and bleeding.



We present the first reported case of a new AV synchronous ILP implanted in a patient wearing a functioning VVI ILP.

Our report confirms that no adverse event is associated with the concomitant presence of two different ILPs in the right ventricle in the short-term follow-up, and shows that the new AV synchronous ILP is a good alternative to VVI ILP in patients with sinus rhythm and a high need for VP.

## Lead author biography



Rita Sicuso was graduated from the Faculty of Medicine, Catania University in 2012. I obtained a Master of Electrophysiology and Cardiac Pacing in 2019. Now, I'm an electrophysiologist in Department of Clinical Electrophysiology and Arrhythmia, Centro Cardiologico Monzino, Milan.

## Supplementary material

Supplementary material is available at *European Heart Journal - Case Reports* online.

**Slide sets:** A fully edited slide set detailing this case and suitable for local presentation is available online as [Supplementary data](#).

**Consent:** The authors confirm that written consent for submission and publication of this case report including images and associated text has been obtained from the patient in line with COPE guidance.

**Conflict of interest:** M.M. and F.T. received consulting fees/honoraria from Medtronic. C.T. has received consulting fees/honoraria from Abbott, Medtronic, Boston Scientific, and Biosense Webster, and serves as a member of EU Medtronic Advisory Board and Boston Scientific Advisory Board. The other author has no relationships relevant to the contents of this paper to disclose.

**Funding:** None declared.

## References

1. Brignole M, Auricchio A, Baron-Esquivias G, Bordachar P, Boriani G, Breithardt O et al. 2013 ESC Guidelines on cardiac pacing and cardiac resynchronization therapy. *Europace* 2013;**15**:1070–1118.
2. Ritter P, Duray GZ, Steinwender C, Soejima K, Omar R, Mont L et al.; Micra Transcatheter Pacing Study Group. Early performance of a miniaturized leadless

- cardiac pacemaker: the Micra Transcatheter Pacing Study. *Eur Heart J* 2015;**36**: 2510–2519.
3. Reynolds D, Duray GZ, Omar R, Soejima K, Neuzil P, Zhang S et al.; Micra Transcatheter Pacing Study Group. A leadless intracardiac transcatheter pacing system. *N Engl J Med* 2016;**374**:533–541.
  4. Sperzel J, Defaye P, Delnoy PP, Garcia Guerrero JJ, Knops RE, Tondo C et al. Primary safety results from the LEADLESS Observational Study. *Europace* 2018;**20**:1491–1497.
  5. Chinitz L, Ritter P, Khelae SK, Iacopino S, Garweg C, Grazia-Bongiorni M et al. Accelerometer-based atrioventricular synchronous pacing with a ventricular leadless pacemaker: results from the Micra atrioventricular feasibility studies. *Heart Rhythm* 2018;**15**:1363–1371. 10.1016/j.hrthm.2018.05.004.
  6. Steinwender C, Khelae SK, Garweg C, Chan JYS, Ritter P, Johansen JB et al. Atrioventricular synchronous pacing using a leadless ventricular pacemaker: results from the MARVEL 2 Study. *JACC Clin Electrophysiol* 2020;**6**:94–106.
  7. Masuyama T, Nanto S, Kodama K, Uematsu M, Taniura K, Kitabatake A et al. Beneficial effects of atrioventricular sequential pacing on cardiac output and left ventricular filling assessed with pulsed Doppler. *Jpn Circ J* 1986;**50**: 799–807.
  8. Ouali S, Neffeti E, Ghoul K, Hammam S, Kacem S, Gribaa R et al. DDD versus VVIR pacing in patients, ages 70 and over, with complete heart block. *Pacing Clin Electrophysiol* 2010;**33**:583–589.
  9. Boldt LH, Lacour P, Pieske B, Haverkamp W, Blaschke F. First-in-human: leadless Micra transcatheter pacing system meets the Nanostim leadless cardiac pacing system. *Europace* 2018;**20**:391.
  10. Beurskens NEG, Tjong FVY, Quast ABE, Knops RE. Successful replacement of the longest worldwide in situ Nanostim leadless cardiac pacemaker for a Micra Transcatheter Pacing System. *J Interv Card Electrophysiol* 2018;**51**: 161–162.