


Unrevealed foreign body in the deep neck space: A case report

Marco Borin^{1,2} | Lorenzo Pignataro^{1,2} | Tullio Ibba¹ | Maurizio Di Cicco¹ |
 Francesco Folino³  | Paola Marchisio^{1,3} | Pasquale Capaccio^{1,4} | Sara Torretta^{1,2}

¹Fondazione IRCCS Ca' Granda Ospedale Maggiore Policlinico, Milan, Italy

²Department of Clinical Sciences and Community Health, Università degli Studi di Milano, Milan, Italy

³Department of Pathophysiology and Transplantation, Università degli Studi di Milano, Milan, Italy

⁴Department of Biomedical Surgical Dental Science, Università degli Studi di Milano, Milan, Italy

Correspondence

Francesco Folino, Università degli Studi di Milano, Department of Pathophysiology and Transplantation, Via Festa del Perdono 7, Milan 20122, Italy.
 Email: francesco.folino@unimi.it

Abstract

Clinical data provided by the patient are not always reliable or could be difficult to collect. In this case, a difficult history collection resulted in a diagnostic delay. Major complications were avoided performing an urgent surgical intervention.

KEYWORDS

case report, deep neck space abscess, deep neck space infection, emergency, foreign body, otolaryngology

1 | INTRODUCTION

Residual foreign bodies are a major cause of mortality if they are not identified promptly. Among the different examination tools available for the diagnostic workup, an accurate anamnestic collection remains fundamental. However, clinical data provided by the patient are not always reliable or could be difficult to collect.

Penetrating foreign bodies represent a potentially life-threatening event demanding an early surgical treatment, especially in a region enriched in vital structures as the neck.¹

Radiological investigations are fundamental for diagnosis and surgical programming, as the foreign body is not always evident at the clinical examination.² For this reason, anamnestic collection remains pivotal to direct the diagnostic workup and to prevent delayed treatments and complications.

Our clinical case considers a deep neck space infection (DNSI) originating from a penetrating foreign body (graphite

pencil). Further lethal complications were avoided performing an urgent surgical treatment. An important language barrier and a lack of information provided by the patient were the principal causes of the diagnostic delay. The great diagnostic difficulty increased the probability of unwanted consequences, being the early diagnosis and management of this pathology an indispensable tool to limit them.

2 | CASE REPORT

A 21-year-old Egyptian man presented to the Emergency Department of our hospital on 19 September 2019 complaining the occurrence of a painful redness and swelling of the left lateral cervical region, associated with temperature and impaired cervical movement. There was an important language barrier with the patient, who was accompanied to the emergency room by his brother who spoke for him.

This is an open access article under the terms of the Creative Commons Attribution-NonCommercial-NoDerivs License, which permits use and distribution in any medium, provided the original work is properly cited, the use is non-commercial and no modifications or adaptations are made.

© 2021 The Authors. *Clinical Case Reports* published by John Wiley & Sons Ltd.

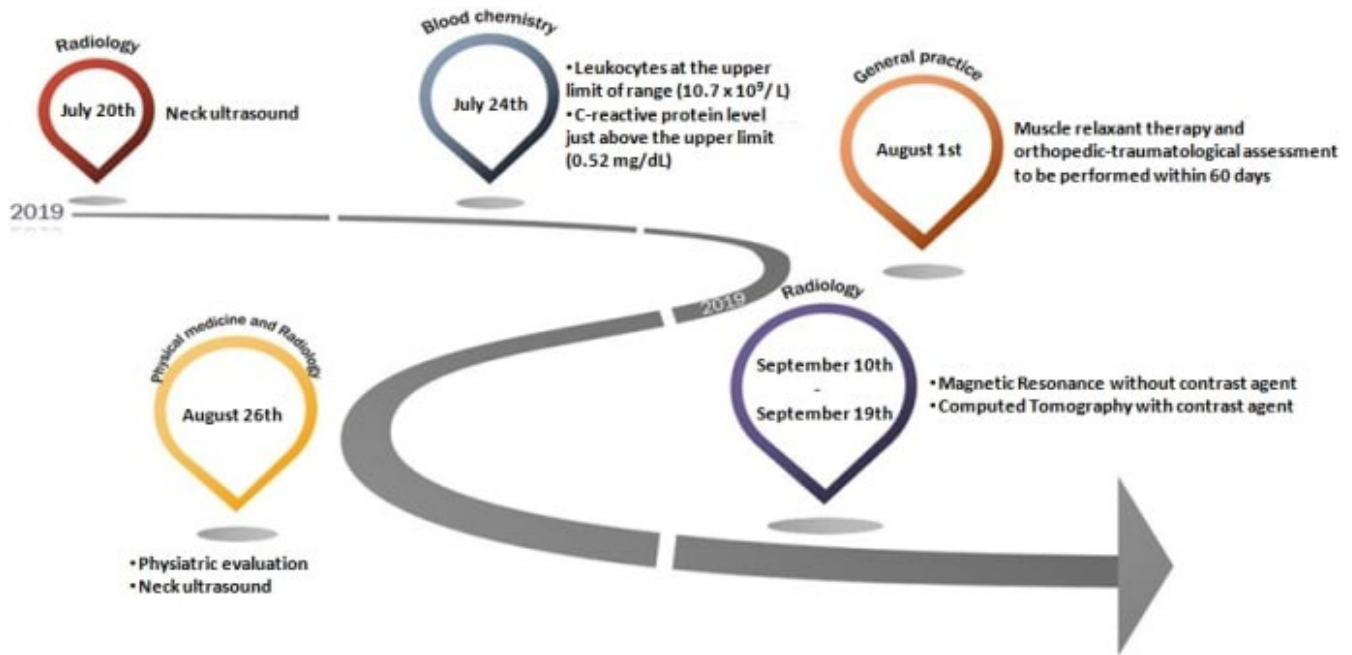


FIGURE 1 Graphical representation of recent clinical history of the patient

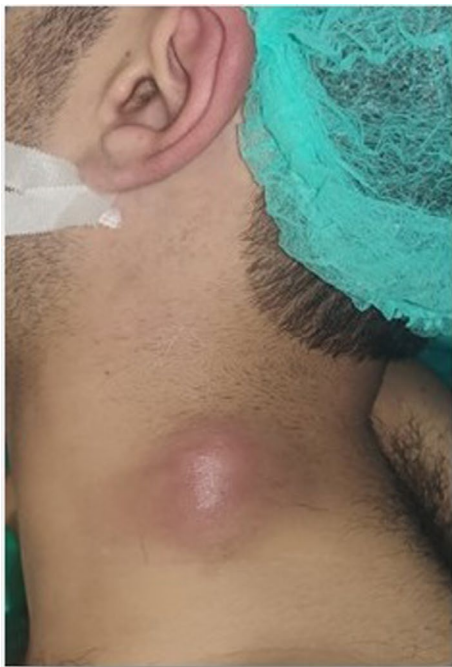

FIGURE 2 Painful redness and swelling of the left lateral cervical region

The initial complaints had occurred two months earlier in conjunction with a referred workplace injury. In the context of anamnestic collection, the patient delivered documentation about his recent clinical history (see Figure 1): an ultrasound of the neck found a contracture of the trapezius muscle on its left side with hyperechoic echostructure but no hematomas inside. Blood tests documented leukocytes at the upper limits

of the range ($10.7 \times 10^9/L$) and a CRP level just above the upper limit (0.52 mg/dL).

Based on these findings, the attending physician (who had not been informed about a previous workplace injury) prescribed a muscle relaxant therapy and a subsequent physiatric evaluation, documenting a massive painful swelling at the base of the left neck.

A further ultrasonographic assessment detected a mixed echostructure formation (35 x 28 mm) within the trapezius muscle with blurred edges and some vascular poles (suspected organized hematoma). Based on this, a magnetic resonance (MRI) was prescribed, documenting a 60 x 6 mm foreign body crossing the trapezius muscle deeply reaching the conjugation foramen C4-C5 region and surrounded by an inflammatory component that reached the subcutaneous surface planes from the left posterior paraspinal region.

On 19 September 2019, the patient finally reported a work trauma in the left laterocervical region of uncertain dynamic (probably with iron or a nail resting on the ground) and he was sent to our emergency room.

2.1 | Investigation and treatment

Clinical assessment revealed the presence of a painful swelling in the left laterocervical region covered by skin redness with fluctuation (Figure 2). Swelling was about 5 x 5 cm and mainly located in the posterior triangle of the neck lower portion, and it was associated with temperature and impaired cervical movement.

Complete blood assessment only documented an increase in leukocytes ($12.8 \times 10^9/L$) and PCR (10 mg/dL).

An urgent contrasted computed tomography (CT) documented a metallic elongated foreign body containing a tubular formation, about 6 cm long with an oblique course from the bottom upwards in the postero-anterior direction and apex between the transverse process of C4 and C5, where there was a small bone parcel detachment, 4 mm distant from the common carotid artery (Figure 3 and Figure 4). The foreign body appeared surrounded by aphlogistic collection of $4.7 \times 2.6 \times 5$ cm with some abscessual formations inside.

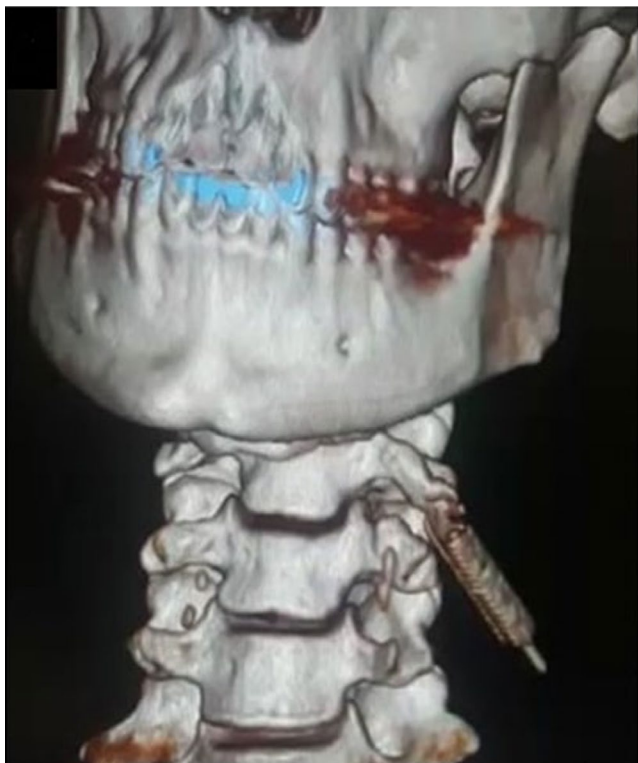

FIGURE 3 Computed tomography reconstruction documenting a metal tube containing a tubular formation, about 6 cm long with an oblique course from the bottom upwards in the postero-anterior direction and apex between the transverse process of C4 and C5

The patient was rushed to the operating room and positioned in lateral decubitus position, exposing the redness skin swelling at the 5th cervical level. An incision was made below it, isolating the capsule and draining the abscess component. Subsequently, the trapezius muscle was incised transversely to reach the foreign body, placed from the 5th level, parallel to the vertebral bodies, up to the 2nd cervical level. Finally, the tip of the foreign body was visualized; after being delicately mobilized, it was extracted preserving the direction of entry, without resistance or induction of bleeding. The foreign body was identified as a broken graphite pencil (Figure 5).

The patient was subsequently hospitalized and treated with a systemic antibiotic therapy (Piperacillin - Tazobactam, 4.5 g, four times a day for seven days).

2.2 | Outcome and follow-up

After a week of hospitalization, a complete clinical recovery was attested. At a further interview, the patient refused to explain the facts related to the presence of this unusual foreign body.

3 | DISCUSSION

Our clinical case considers a deep neck space infection (DNSI) originating from a penetrating foreign body (graphite pencil). Without early diagnosis and treatment, residual foreign bodies remain a major cause of mortality.³⁻⁹ Moreover, retained foreign bodies might lead to long-term sequelae as chronic infection and neurological or functional impairment.²

Foreign bodies as etiology cause of DNSI are extremely rare.⁶⁻⁸ Si-Youn Song et al described a 50-year-old patient with a blade of a grass cutter suddenly dislodged on impact and penetrated his neck. However, unlike our case, this patient had a 7-mm-sized linear skin laceration and the foreign body was vaguely palpable on clinical examination.¹⁰

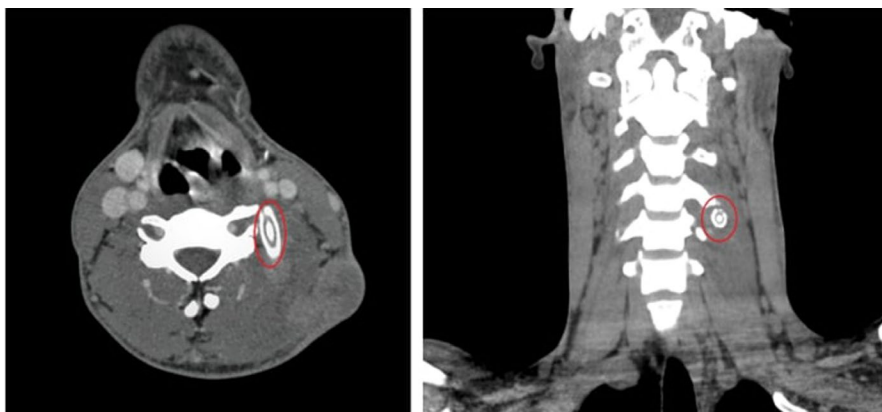


FIGURE 4 Axial and coronal CT sections documenting an occulted foreign body and its relationship with vital neck structures

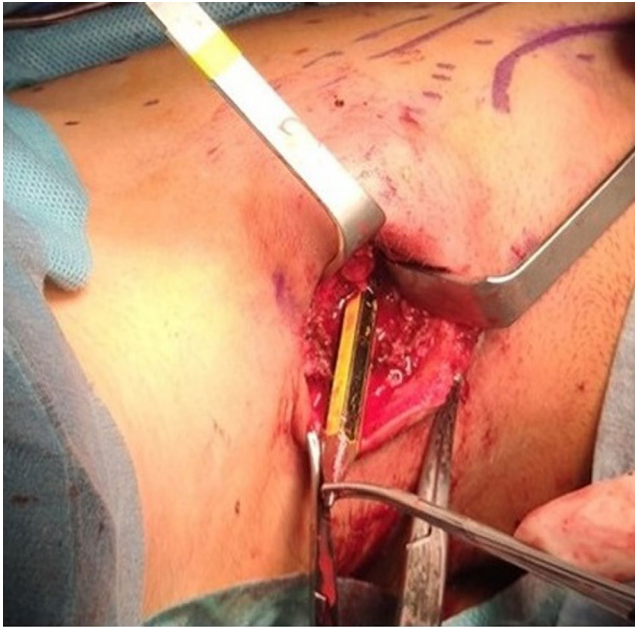


FIGURE 5 Intraoperative view after abscess evacuation and documenting foreign body (broken pencil) extraction

Ge XY et al reported the onset of a DNSI as a consequence of esophageal perforation, linked to the ingestion of a foreign body.¹¹ However, although the diagnosis involved, as in our case, the use of specific imaging (CT with contrast agent), the etiological origin of the cervical abscess was different (ingestion of the foreign body vs. post-traumatic event) and consequently its treatment.

According to other studies, in our case CT and MRI imaging are surely useful to plan the surgical approach.^{12,13} An accurate radiological planning allows indeed surgical minimally invasive approaches and helps to reduce complications.¹⁴

The lack of explanations by the patient regarding the dynamics of the cervical trauma represents an atypical aspect in our case. It is possible to hypothesize, given the position of the foreign body as well as its orientation at the time of surgical extraction, that the trauma was occurred after a struggle and that the patient's reticence was due to the fear of retaliation; another hypothesis could be that the event was linked to a quarrel in the home environment and the patient wanted to protect his family members from a potential criminal proceeding. Moreover, anamnestic collection was complicated by the language barrier with the patient.

4 | CONCLUSIONS

A difficult history collection resulted in a greater diagnostic difficulty with the use of unnecessary drugs, multiple unnecessary clinical tests, and potentially harmful instrumental

tests. For example, undergoing an MRI while harboring an unrevealed foreign body whose material is not known could expose the patient to serious complications during the procedure, as the movement of the retained object in case of materials with ferromagnetic properties.^{15,16} Moreover, it has increased the probability of unwanted consequences, being the early diagnosis and management of neck foreign bodies and deep neck space infections an indispensable tool to limit them.

ACKNOWLEDGMENTS

Published with written consent of the patient.

CONFLICT OF INTEREST

The author(s) declare no potential conflicts of interest with respect to the research, authorship, and/or publication of this paper.

AUTHOR CONTRIBUTIONS

Marco Borin: conceived the paper and drafted it. Lorenzo Pignataro: revised the paper for important intellectual contributions. Tullio Ibba: performed surgery and contributed to drafting. Maurizio Di Cicco: performed surgery and contributed to drafting. Francesco Folino: contributed to drafting and revision. Paola Marchisio: revised the paper for important intellectual contributions. Pasquale Capaccio: revised the paper for important intellectual contributions. Sara Torretta: conceived the paper and drafted it.

ETHICAL APPROVAL

The study was published with written consent of the patient.

DATA AVAILABILITY STATEMENT

All relevant data are included and are available as part of the article.

ORCID

Francesco Folino  <https://orcid.org/0000-0002-1003-6993>

REFERENCES

1. Khadivi E, Bakhshae M, Khazaeni K. A rare penetrating neck trauma to zone III. *Emerg Med J.* 2007;24(12):840.
2. Voss JO, Thieme N, Doll C, et al. Penetrating foreign bodies in head and neck trauma: a surgical challenge. *Craniofac Trauma Reconstr.* 2018;11(3):172-182.
3. Boscolo-Rizzo P, Marchiori C, Montolli F, Vaglia A, Da Mosto MC. Deep neck infections: a constant challenge. *ORL J Otorhinolaryngol Relat Spec.* 2006;68(5):259-265.
4. Huang TT, Liu TC, Chen PR, Tseng FY, Yeh TH, Chen YS. Deep neck infection: analysis of 185 cases. *Head Neck.* 2004;26(10):854-860.
5. Rzepakowska A, Rytel A, Krawczyk P, et al. The factors contributing to efficiency in surgical management of purulent infections

- of deep neck spaces. *Ear Nose Throat J.* 2019;014556131987728. Epub ahead of print.
6. Kataria G, Saxena A, Bhagat S, Singh B, Kaur M, Kaur G. Deep Neck Space Infections: A Study of 76 Cases. *Iran J Otorhinolaryngol.* 2015;27(81):293-299.
 7. Buckley J, Harris AS, Addams-Williams J. Ten years of deep neck space abscesses. *J Laryngol Otol.* 2019;133(4):324-328.
 8. Velhonoja J, Lääveri M, Soukka T, Irjala H, Kinnunen I. Deep neck space infections: an upward trend and changing characteristics. *Eur Arch Otorhinolaryngol.* 2020;277(3):863-872.
 9. Almutairi DM, Alqahtani RM, Alshareef N, Alghamdi YS, Al-Hakami HA, Algarni M. Deep neck space infections: a retrospective study of 183 cases at a tertiary hospital. *Cureus.* 2020;12(2):e6841.
 10. Song SY, Bae CH, Kim YD, Choi YS. Intravascular Migration of a Metallic Foreign Body After a Penetrating Neck Injury. *Ear Nose Throat J.* 2020;99(4):259-261.
 11. Ge XY, Liu LF, Lu C, Zhang AB, Wang ZX. Lin Chung Er Bi Yan Hou Tou Jing Wai Ke ZaZhi. 2018;32(4):292-294.
 12. Faguy K. Imaging foreign bodies. *Radiol Technol.* 2014;85(6):655-682.
 13. Ingraham CR, Mannelli L, Robinson JD, Linnau KF. Radiology of foreign bodies: how do we image them? *Emerg Radiol.* 2015;22(4):425-430.
 14. Siessegger M, Mischkowski RA, Schneider BT, Krug B, Klesper B, Zöllner JE. Image guided surgical navigation for removal of foreign bodies in the head and neck. *J Craniomaxillofac Surg.* 2001;29(6):321-325.
 15. Jarraya M, Hayashi D, de Villiers RV, et al. Multimodality imaging of foreign bodies of the musculoskeletal system. *AJR Am J Roentgenol.* 2014;203(1):W92-W102..
 16. Hunter TB, Taljanovic MS. Foreign bodies. *Radiographics.* 2003;23(3):731-757.

How to cite this article: Borin M, Pignataro L, Ibba T, et al. Unrevealed foreign body in the deep neck space: A case report. *Clin Case Rep.* 2021;9:1478–1482. <https://doi.org/10.1002/ccr3.3806>