

HEAD AND NECK

3D video-assisted trans-oral removal of deep hilo-parenchymal sub-mandibular stones

Rimozione trans-orale dei calcoli sottomandibolari ilo-parenchimali profondi con tecnica videoassistita 3D

P. CAPACCIO^{1,2}, D. DI PASQUALE¹, L. BRESCIANI¹, S. TORRETTA^{1,3}, L. PIGNATARO^{1,3}

¹ Fondazione IRCCS Ca' Granda Ospedale Maggiore Policlinico, Milano, Italy; ² Department of Biomedical, Surgical and Dental Sciences; ³ Department of Clinical Sciences and Community Health, Università degli Studi di Milano, Italy

SUMMARY

The aim of this paper is to describe the intra-operative findings and surgical results of the first application of 3D high-definition (HD) endoscopic support to the trans-oral surgical treatment of five patients with deep hilo-parenchymal sub-mandibular stones who underwent clinical and ultrasonographic (US) follow-up examinations at one month after the procedure. Five patients undergoing 2D-HD video-assisted transoral surgery for the same condition were used as controls. The results were classified as successful (US - demonstrated complete clearance) or unsuccessful (US - demonstrated total or partial persistence). Visual analogue scales (VAS) were used post-surgically to evaluate the sharpness and brightness of the 2D and 3D images on the screen and stereoscopic depth perception (SDP) of the 3D-HD endoscope. Successful stone removal and significant subjective improvement (lack of obstructive symptoms) was obtained in all but one of the patients in the 3D group, in whom the one-month US evaluation revealed a residual 3 mm asymptomatic hilo-parenchymal stone that was successfully treated by sialendoscopy-assisted intra-corporeal laser lithotripsy. Wharton's duct and the lingual nerve were identified and preserved in all cases. The mean 3D-HD VAS results were brightness 7 (range 6-8), sharpness 7.8 (range 7-9) and SDP 8.2 (range 8-9); the mean 2D-HD results were brightness 7.8 (range 7-9) and sharpness 7 (range 7-8). Our findings confirm the safety and efficacy of conservative transoral surgical treatment of hilo-parenchymal sub-mandibular stones. From a surgeon's perspective, 3D-HD guided exploration of the oral floor seems to provide a better view of Wharton's duct and the lingual nerve, especially near the sub-mandibular parenchyma. The 3D-HD video-assisted transoral removal of deep hilo-parenchymal sub-mandibular stones can therefore be considered a useful new means of preserving the function of an obstructed salivary gland.

KEY WORDS: Sub-mandibular stones • Sialendoscopy • Three-dimensional (3D) • 3D endoscope

RIASSUNTO

L'articolo descrive la prima applicazione dell'endoscopia 3D in alta definizione (3D-HD) nella rimozione chirurgica transorale di calcoli sottomandibolari siti in sede ilo-parenchimale profonda in cinque pazienti. Vengono riportati i riscontri intraoperatori ed i risultati chirurgici ottenuti in questo gruppo di pazienti; cinque pazienti sottoposti a chirurgia transorale videoassistita con endoscopi 2D-HD per la medesima patologia sono stati utilizzati come controlli. Il follow-up clinico ed ecografico è stato effettuato ad un mese di distanza dal trattamento chirurgico. Il successo della procedura è stato definito dalla completa clearance del calcolo alla valutazione ecografica. La valutazione della nitidezza, luminosità e della percezione stereoscopica della profondità (SDP) delle immagini 3D e 2D è stata definita mediante valutazione soggettiva dei chirurghi eseguita post-operativamente mediante una scala di valutazione analogica (VAS). La rimozione chirurgica completa dei calcoli ed un miglioramento soggettivo (attestato dalla risoluzione sintomatologica) sono stati ottenuti in tutti i pazienti, eccetto in un paziente appartenente al gruppo 3D in cui è stata riscontrata ecograficamente la presenza a livello ilo-parenchimale di un piccolo calcolo residuo asintomatico di 3 mm, successivamente trattato con litotrissia intracorporea laser con completa clearance. Il dotto di Wharton ed il nervo linguale sono stati correttamente identificati e preservati in tutti i casi. Le VAS medie relative alla luminosità, nitidezza e SDP delle immagini 3D-HD sono risultate rispettivamente 7 (range 6-8), 7,8 (range 7-9), e 8,2 (range 8-9); le VAS medie relative alla luminosità e nitidezza delle immagini 2D-HD sono risultate rispettivamente 7,8 (range 7-9), 7 (range 7-8). In conclusione i nostri riscontri confermano la sicurezza ed efficacia dell'approccio chirurgico conservativo transorale per la rimozione di calcoli ilo-parenchimali. Sulla base dei riscontri intraoperatori e del livello di confort riferito post-operativamente dai chirurghi, l'esplorazione endoscopica 3D-HD sembra fornire una migliore visualizzazione delle strutture anatomiche nobili limitrofe, specialmente nelle vicinanze del parenchima sottomandibolare. Il supporto dell'endoscopia 3D-HD sembra pertanto utile a migliorare la performance chirurgica e a preservare i meccanismi funzionali nella riabilitazione chirurgica dei disordini ostruttivi salivari.

PAROLE CHIAVE: Scialolitiasi • Scialoendoscopia • 3D • Endoscopia 3D

Introduction

Sialolithiasis is mainly (80-90%) observed in the sub-mandibular glands (SMGs)¹, and most frequently in the distal tracts of the duct and hilum: only about 10% are pure intraparenchymal stones². The exact position of a stone can be radiologically confirmed by ultrasonography (US)³, computed tomography (CT) and/or cone beam tomography (CBCT)⁴.

Sialendoscope-assisted removal of large (> 7 mm) hilo-parenchymal sub-mandibular stones is an effective conservative surgical procedure that preserves the main sub-mandibular duct and allows the stone to be removed through a minimal hilo-parenchymal incision, thus preserving the function of the obstructed gland and allowing sialendoscopic access through the natural ostium in the case of a recurrence^{2,3,5-12}. Its intra-operative success rate of 98.5% and 11.2% recurrence rate⁷ also make it a safe alternative to traditional surgery¹³. However, one critical step in trans-oral surgery is identifying and dissecting Wharton's duct and the lingual nerve, which not only requires a detailed knowledge of the anatomy of the oral floor, but also a wide surgical field in order to avoid late complications such as lingual nerve injury. Furthermore, in the case of deep hilo-parenchymal stones, the operating view may be negatively affected by possible damage to the main anatomical landmarks despite the support of magnifying instruments such as loupes.

Two-dimensional, high-definition (2D-HD) endoscopes are widely used in the endoscopic surgical treatment of various head-and-neck diseases. This technique is considered the gold standard for the sinonasal and skull base regions, is frequently used to treat the orbits, the laryngopharyngeal and tracheal regions, the middle and inner ear, and the salivary ductal system¹⁴⁻¹⁸, and is also considered a complementary means of undertaking traditional open head-and-neck surgery¹⁹. However, three-dimensional (3D) endoscopic surgery is now being increasingly used not only in neurosurgery, gastroenterology and gynecology, but also in otolaryngology²⁰⁻²⁴, including skull base and lacrimal surgery²¹. The benefits of 3D surgical vision are enhanced depth perception and safety, shorter surgery and recovery times, and improved morbidity, and it can also be used to train inexperienced surgeons^{25,26}.

This preliminary pilot study describes the first application of 3D-HD endoscopic support in the transoral surgical treatment of five patients with deep hilo-parenchymal sub-mandibular stones.

Materials and methods

In January 2018, 10 patients (five males and five females; mean age 45.2 years, range 21-62) with symptomatic deep, large (> 7 mm), fixed and palpable hilo-parenchymal sub-mandibular stones (mean diameter 12 mm, range 8-20 mm) were selected for video-assisted transoral stone removal at the Fondazione IRCCS Ca' Granda Policlinico and University of Milan's Department of Biomedical, Surgical and Dental Sciences and Department of Clinical Sciences and Community Health. The presence of stones was assessed by complete ENT clinical examination (including bimanual palpation), and size and location were determined by US (Hitachi H21, 7.5 MHz; Hitachi High Technology Corporation Ltd., Tokyo, Japan) and CBCT (Fig. 1). Exclusion criteria were inability to open the mouth and the presence of deep non-palpable parenchymal stones. A random number generator was used to assign five patients to 3D-HD (group A; Table I) and five to 2D-HD video-assisted transoral stone removal (group B), with the latter being used as controls.

All of the procedures were performed by the same first surgeon (PC) and one of the second surgeons (LP, DDP or LB) with the patient under general anaesthesia in a half-seated position after intravenous administration of amoxicillin/clavulanic acid and steroids. The surgical aim was complete stone delivery and removal.

The results are given as arithmetical mean values and ranges. The between-group analyses were made using the Wilcoxon-Mann-Whitney test and STATA 10.0 software (StataCorp, College Station, Texas). A p-value of < 0.05 was considered statistically significant.

Surgical setting and technique

Group A patients underwent surgery under 3D-HD vision using an 18 cm long, rigid, 4 mm diameter 3D endoscope (TIPCAM 1S 3D ORL, Karl Storz, Tuttlingen, Germany; Fig. 2) and an endoscopic system consisting of an Image 1S modular platform (Karl Storz) on which existing endoscopic systems can be expanded. The 26- or 32-inch 3D-HD display monitor is provided with multiple video input and output options, and its in-built visualisation modes "clara", "clara + chroma" and "spectra" delineate tissue structures such as vascular structures. The 3D video endoscopic system has a full HD image sensor with a frame rate of 50/60 Hz and resolution of 1920 × 1080 pixels²¹. The 3D monitor was placed in front of the observer, and no headlight illumination or loupe magnification was used. The surgical team consisted of three surgeons, all of whom were equipped with 3D polarisation glasses or circularly polarised 3D clips on glasses for viewing: two

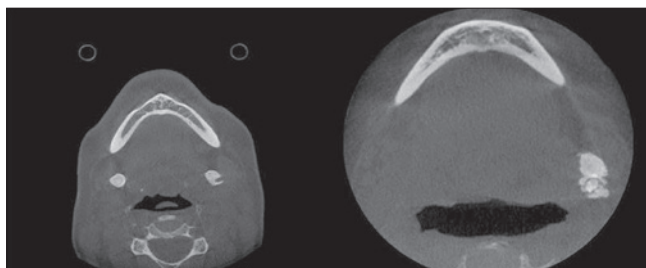


Fig. 1. CBCT images of a patient with bilateral sub-mandibular stones (left), and a patient with a single giant left sub-mandibular stone (right).

performed the surgery, and the third held the endoscope. The only difference between group A and group B procedures was that the latter made use of an 18 cm long, 4 mm diameter, 2D 0° Hopkins II HD endoscope with a H3-Z Karl Storz HD camera head image (Karl Storz GmbH & Co., Tuttlingen, Germany) and HD monitor display.

In all cases, the patient's mouth was held open by a small gag, the tongue was retracted antero-medially and the floor of the mouth was infiltrated by 5 mL of mepivacaine 25 mg/mL + adrenaline 5 mg/mL just below the oral mucosa. An oblique incision was made near the papillary region of Wharton's duct, along the floor of the mouth toward the second molar. The loose areolar tissue was dissected medially to the internal edge of the sublingual gland, which was rotated laterally to expose Wharton's duct and the lingual nerve running from the tongue, passing under the duct, and then ascending medially. The lingual nerve was mobilised from the duct and retracted medially in order to be able to visualise the stone in the gland hilum (Figs. 3, 4), which was moved upward to the sub-mandibular gland area by external finger pressure applied by the second surgeon. The stone was removed in one piece by a sub-mandibulotomy using a micro- or Freer eleva-

tor (Martin, Tuttlingen, Germany). At the end of the procedure, the cavity was irrigated with saline to clear any debris, and a haemostatic, anti-microbial fibrillar surgical net (Tabotamp, Johnson & Johnson Medical Limited, Gargrave, Skipton, UK) was positioned over the hilar opening to avoid the risk of stricture or stenosis. Finally, the wound was irrigated with antibiotic solution (rifampicin), and the oral floor was sutured using resorbable stitches (3.0 Vicryl). If necessary, sialendoscopy (0.8-1.1 mm, Erlangen sialoendoscope, Karl Storz Co., GmbH, Tuttlingen, Germany) was used to locate the stone more precisely, and to check for any residual intra-parenchymal stones or debris through the incision.

All of the patients received antibiotic therapy (amoxicillin and clavulanic acid) for one week after the procedure; steroids were also administered in the case of oral floor oedema. In accordance with Albrecht et al.²⁷, the surgeons attributed a visual analogue scale (VAS) score (from 1 to 10) after each procedure to assess the sharpness and brightness of the 2D and 3D images on the screen, and the stereoscopic depth perception (SDP) of the 3D-HD endoscope.

The duration of the procedures was recorded, and the procedures were classified as successful (US-demonstrated complete stone clearance), partially successful (US-demonstrated partial stone clearance), or unsuccessful (US-demonstrated total stone persistence) regardless of the persistence of salivary swelling at the one-month US evaluation.

Results

One of the five patients in group A had bilateral parenchymal sub-mandibular stones (9 mm each, Fig. 1); the remaining four had single deep parenchymal stones (mean diameter 11.8 mm, range 8-20), two of which were

Table I. Characteristics of patients and procedures.

| Characteristics | Group A (3D-HD) (n = 5) | Group B (2D-HD) (n = 5) |
|---|---------------------------|--|
| Mean age + SD, years | 53.4 ± 8.6 | 37 ± 14.1 |
| Sex | 3 F, 2 M | 3 M, 2 F |
| Endoscope | TIPCAM 1S 3D ORL | 2D 0° Hopkins II HD, H3-Z Karl Storz HD camera head image |
| Mean stone diameter + SD, mm | 11.8 ± 4.3 | 9.4 ± 1.0 |
| Uni-/bilateral interventions | 4 uni; 1 bil; 2 left side | 5 uni; 3 left side |
| 3D glasses | Yes | No |
| Mean duration of surgery + SD, minutes | 44 ± 10.1 | 35 ± 4.4 |
| Intra-/postoperative complications | 0 | 0 |
| Residual stones at one-month US follow-up | 1 | 0 |

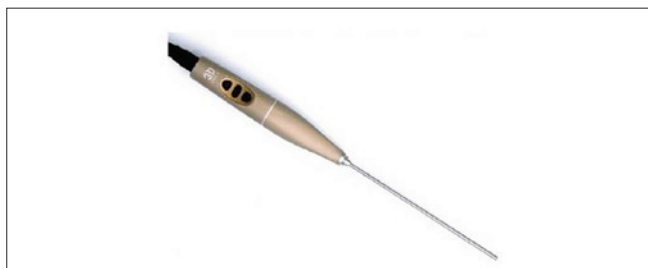

Fig. 2. The TIPCAMR 1S 3D ORL endoscope.

left-sided. The procedure was successful in all but one patient, in whom it was partially successful: no residual stones were observed at the one-month US evaluation except for a residual asymptomatic 3 mm hilo-parenchymal stone in the left gland of the patient with bilateral stones, which was subsequently successfully removed by means of sialendoscopy-assisted intra-corporeal holmium laser lithotripsy²⁸⁻³⁰.

All five patients in group B had single parenchymal stones (mean diameter 9.4 mm, range 8-11), three of which were left-sided. A successful result was obtained in all cases as assessed on the basis of clinical improvement and US evidence of complete stone clearance.

Wharton's duct and the lingual nerve were clearly identified, dissected and preserved in both groups. There were no major complications, and all of the patients were discharged on the day after surgery with variably mild oede-

ma of the oral cavity and variably mild gland swelling. Two patients (one in each group) underwent sialendoscopy in order to locate the stone more precisely before the hilo-parenchymal incision. All of the patients underwent sub-mandibulotomy with minimal parenchymal exposure. The mean 2D-HD VAS scores for sharpness and brightness were, respectively, 7 (range 7-8) and 7.8 (range 7-9); the mean 3D-HD VAS scores were 7.8 (range 7-9) for sharpness, 7 (range 6-8) for brightness and 8.2 (range 8-9) for SDP. No statistically significant between-group differences were revealed by means of the Wilcoxon-Mann-Whitney test.

There was consensus that the definition of the 3D images of the anatomy oral floor and the noble structures was excellent, and surgeons reported greater comfort when using 3D assistance. The mean duration of surgery was 44 minutes (range 30-60) in group A, and 35 minutes (range 30-40) in group B: the Wilcoxon-Mann-Whitney test showed that the difference was not statistically significant. Finally, all of the surgeons underlined the more active role of the second surgeon in comparison with the traditional trans-oral procedure due to the sharing of the narrow endoscopic operating field, regardless of the endoscope used.

Discussion

Sialendoscopic-assisted transoral surgery is currently considered the best means of removing large (> 7 mm)

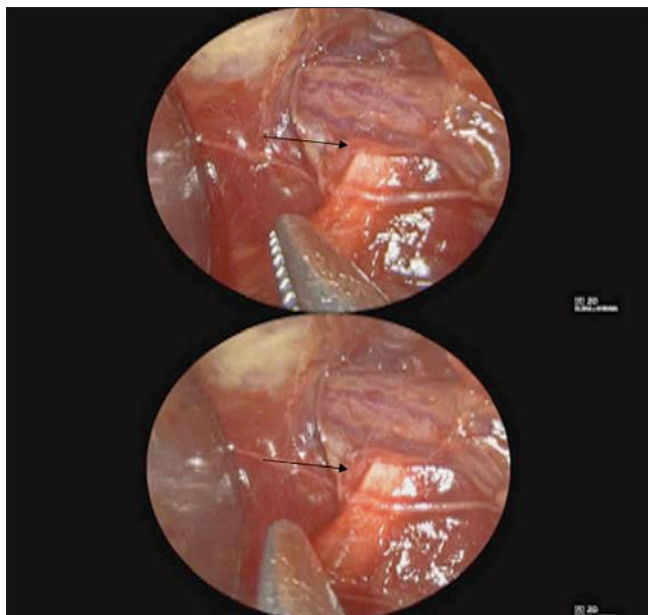


Fig. 3. A split intraoperative 3D-HD image showing the crossing between the lingual nerve and Wharton's duct (arrow) of the left sub-mandibular gland.

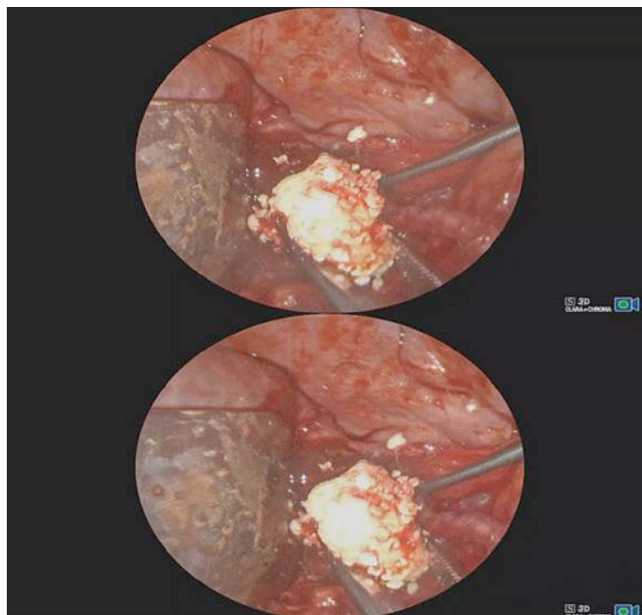


Fig. 4. A split intraoperative 3D-HD image showing the removal of a giant stone from the left sub-mandibular gland.

hilo-parenchymal sub-mandibular stones. It is the most frequently used technique for patients scheduled for conservative treatment and, on the basis of our experience, is successful in removing parenchymal stones in most cases ^{6,9}. However, some failures may occur in patients with a deep stone location, and a 14.3% rate of recurrent obstructive symptoms due to residual stones has been observed during the follow-up period, thus suggesting that the use of advanced endoscopic technologies such as 3D-HD-instruments would help to improve surgical outcomes. The technique is also safe as only a few mild unwanted effects have been described, such as tingling of the tip of the tongue (3.6%), permanent lingual nerve injury (1.2%), ranula formation (1.2%) and hilar stenosis (1.2%) ⁹.

The sialendoscopy-assisted transoral removal of hilo-parenchymal sub-mandibular stones is generally a single-surgeon technique and, as it may be characterised by a narrow surgical field, magnifying instruments such as Loupes lenses are used to improve visibility and the localisation and preservation of the noble structures of the oral floor (the lingual nerve and Wharton's duct). Furthermore, the narrow surgical field may limit the second surgeon's contribution and prevent the assistance required to guarantee stone removal using a minimal surgical incision.

Various fields of head-and-neck surgery have now introduced the use of 2D- and 3D-HD video-assisted techniques ^{20,21,31-33} but, to the best of our knowledge, this is the first study comparing the 2D- and 3D-HD video-assisted transoral removal of deep hilo-parenchymal sub-mandibular stones. Both procedures proved to be successful and there was no substantial difference in their duration (Table I), but the use of the 3D technique led to a slightly (but not significant) better sharpness score (7.8 vs 7) and a slightly lower brightness score (7 vs 7.8), and all of the surgeons subjectively judged that it improved overall surgical performance. None of our patients experienced any early or late complications, and lingual nerve and Wharton's duct anatomy were identified and preserved in all cases.

Our results confirm those of previous authors who have found no substantial difference between 2D and 3D endoscopic surgery in terms of blood loss and operative times, but less bright 3D endoscopes images ^{33,34}. Yu et al. ³² have recently proposed 3D endoscopy for patients undergoing endoscopic-assisted thyroidectomy via the anterior chest approach. In their case series of 103 patients (32 undergoing 3D and 71 undergoing 2D endoscopy), they found that the two techniques were comparably safe and effective, whereas the 3D procedure provided better depth percep-

tion and made it easier to recognise critical anatomical landmarks. Moreover, Albrecht et al. ²⁷ carried out a randomised, controlled trial involving 46 patients who were candidates for the endoscopic sinus surgical treatment of chronic rhinosinusitis with nasal polyps, and compared the surgeons' visual perception and comfort during surgery using 2D-HD (control), 3D standard-definition or 3D-HD endoscopes: both 3D procedures significantly increased subjective SDP and comfort.

The main advantages of both approaches were a better view of the operating field by all members of the surgical team (with the second surgeon being more involved than in the case of loupes lens-guided surgery), clear anatomical delineation, and enhanced depth perception of the oral floor, lingual nerve and Wharton's duct, especially in patients undergoing 3D video-assisted surgery (the surgeons' SDP VAS score for the TIPCAM 1S 3D ORL endoscope was 8.2).

The surgical removal of deep hilo-parenchymal stones through a minimal parenchymal incision was easier even in the case of large calculi (up to 20 mm). The procedure was successful in all but one patient with bilateral parenchymal stones, in whom US revealed a residual 3 mm stone. However, as this conservative approach guarantees salivary duct system anatomy, the patient could be successfully treated by means of sialendoscopy-assisted intra-corporeal laser lithotripsy ^{28,30,35,36}. Our initial experience of 3D endoscopically-assisted trans-oral surgery highlighted the need for a third surgeon to hold the endoscope with a subsequent lack of stability and the risk of smearing of one of the lenses with the sudden loss of 3D vision. Finally, the shared intra-operative view of the operating field and the possibility of making 3D-HD recordings can be used for teaching purposes and to reduce the duration of the learning curve.

This paper describes the first use of this new technology in the transoral surgical treatment of deep hilo-parenchymal sub-mandibular stones, and suggests that it could lead to potential benefits. However, the study design and small sample size do not allow our findings to be used to make a direct comparison of 3D and 2D endoscopic approaches (which is beyond the scope of this study). Other limitations are the short follow-up period and the impossibility to compare our findings with previously published results using the traditional approach. Consequently, dedicated controlled studies of larger case-series are needed to assess the real benefits of 3D-HD endoscopic support in the transoral surgical treatment of deep hilo-parenchymal sub-mandibular stones in comparison with the traditional 2D technique.

Conclusions

Video-assisted transoral surgical removal of deep hило-parenchymal sub-mandibular stones is a safe, efficacious and conservative procedure regardless of whether it is performed using a 3D or 2D system. Both approaches allow the clear identification and preservation of the noble structures of the oral floor, thus minimising the risk of complications, but 3D-HD endoscopy seems to work better in terms of anatomical delineation and enhances depth perception of the oral floor. The findings of this initial study of a small series of patients indicate that the 3D-HD video-assisted transoral surgery is a useful new means of functionally managing hило-parenchymal sub-mandibular stones.

Conflict of interest statement

None declared.

References

- Gillespie MB, Koch M, Iro H, et al. *Endoscopic-assisted gland-preserving therapy for chronic sialadenitis: a German and US comparison*. Arch Otolaryngol Head Neck Surg 2011;137:903-8. <https://doi.org/10.1001/archoto.2011.130>
- Zenk J, Constantinidis J, Al-Kadah B, et al. *Transoral removal of submandibular stones*. Arch Otolaryngol Head Neck Surg 2011;127:432-6. <https://doi.org/10.1001/archotol.127.4.432>
- Cho W, Lim D, Park H. *Transoral sonographic diagnosis of submandibular duct calculi*. J Clin Ultrasound 2014;42:125-8. <https://doi.org/10.1002/jcu.22063>
- Abdel-Wahed N, Amer ME, Abo-Taleb NS. *Assessment of the role of cone beam computed sialography in diagnosing salivary gland lesions*. Imaging Sci Dent 2013;43:17-23. <https://doi.org/10.5624/isd.2013.43.1.17>
- Walvekar RR, Bomeli SR, Carrau RL, et al. *Combined approach technique for the management of large salivary stones*. Laryngoscope 2009;119:1125-9. <https://doi.org/10.1002/lary.20203>
- Marchal F. *A combined endoscopic and external approach for extraction of large stones with preservation of parotid and submandibular glands*. Laryngoscope 2015;125:2430. <https://doi.org/10.1002/lary.25565>
- Capaccio P, Gaffuri M, Rossi V, et al. *Sialendoscope-assisted transoral removal of hило-parenchymal sub-mandibular stones: surgical results and subjective scores*. Acta Otorhinolaryngol Ital 2017;37:122-7. <https://doi.org/10.14639/0392-100X-1601>
- Iro H, Zenk J, Waldfahrer F, et al. *Extracorporeal shock wave lithotripsy of parotid stones. Results of a prospective clinical trial*. Ann Otol Rhinol Laryngol 1998;107:860-4. <https://doi.org/10.1177/000348949810701009>
- Capaccio P, Clemente IA, McGurk M, et al. *Transoral removal of hiloparenchymal submandibular calculi: a long-term clinical experience*. Eur Arch Otorhinolaryngol 2011;268:1081-6. <https://doi.org/10.1007/s00405-011-1508-z>
- McGurk M, Makdissi J, Brown JE. *Intra-oral removal of stones from the hilum of the submandibular gland: report of technique and morbidity*. Int J Oral Maxillofac Surg 2004;33:683-6. <https://doi.org/10.1016/j.ijom.2004.01.024>
- Makdissi J, Escudier MP, Brown JE, et al. *Glandular function after intraoral removal of salivary calculi from the hilum of the submandibular gland*. Br J Oral Maxillofac Surg 2004;42:538-41. <https://doi.org/10.1016/j.bjoms.2004.08.006>
- Zhang L, Escudier M, Brown J, et al. *Long-term outcome after intraoral removal of large submandibular gland calculi*. Laryngoscope 2010;120:964-6. <https://doi.org/10.1002/lary.20839>
- Nahlieli O. *Complications of traditional and modern therapeutic salivary approaches*. Acta Otorhinolaryngol Ital 2017;37:142-7. <https://doi.org/10.14639/0392-100X-1604>
- Presutti L, Anschuetz L, Rubini A, et al. *The impact of the transcranial endoscopic approach and mastoid preservation on recurrence of primary acquired attic cholesteatoma*. Otol Neurotol 2018;39:1-5. <https://doi.org/10.1097/MAO.0000000000001626>
- Capaccio P, Torretta S, Ottavian F, et al. *Modern management of obstructive salivary diseases*. Acta Otorhinolaryngol Ital 2007;27:161-72.
- Solari D, Chiamonte C, Di Somma A, et al. *Endoscopic anatomy of the skull base explored through the nose*. World Neurosurg 2014;82:S164-70. <https://doi.org/10.1016/j.wneu.2014.08.005>
- Castelnuovo P, Turri-Zanoni M, Battaglia P, et al. *Endoscopic endonasal management of orbital pathologies*. Neurosurg Clin N Am 2015;26:463-72. <https://doi.org/10.1016/j.nec.2015.03.001>
- Freitag L, Darwiche K. *Endoscopic treatment of tracheal stenosis*. Thorac Surg Clin 2014;24:27-40. <https://doi.org/10.1016/j.thor-surg.2013.10.003>
- Vaiman M. *Comparative analysis of methods of endoscopic surgery of the submandibular gland: 114 surgeries*. Clin Otolaryngol 2015;40:162-6. <https://doi.org/10.1111/coa.12357>
- Felisati G, Lenzi R, Pipolo C, et al. *Endoscopic expanded endonasal approach: preliminary experience with the new 3D endoscope*. Acta Otorhinolaryngol Ital 2013;33:102-6
- Ali MJ, Naik MN. *First intraoperative experience with three-dimensional (3D) high-definition (HD) nasal endoscopy for lacrimal surgeries*. Eur Arch Otorhinolaryngol 2017;274:2161-4. <https://doi.org/10.1007/s00405-017-4466-2>
- Raspagliesi F, Bogani G, Martinelli F, et al. *Incorporating 3D laparoscopy for the management of locally advanced cervical cancer: a comparison with open surgery*. Tumori 2016;102:393-7. <https://doi.org/10.5301/tj.5000527>
- Nassimzadeh A, Muzaffar S, Nassimzadeh M, et al. *Three-dimensional hand-to-gland combat: the future of endoscopic surgery?* J Neurol Surg Reports 2015;76:e200-4. <https://doi.org/10.1055/s-0035-1547368>
- Pennacchietti V, Garzaro M, Grottoli S, et al. *Three-dimensional endoscopic endonasal approach and outcomes in sellar lesions: a single-center experience of 104 cases*. World Neurosurg 2016;89:121-5. <https://doi.org/10.1016/j.wneu.2016.01.049>
- Fergo C, Burcharth J, Pommergaard H-C, et al. *Three-dimensional laparoscopy vs 2-dimensional laparoscopy with high-definition technology for abdominal surgery: a systematic review*. Am J Surg 2017;213:159-70. <https://doi.org/10.1016/j.amjsurg.2016.07.030>
- Cheng J, Gao J, Shuai X, et al. *Two-dimensional versus three-dimensional laparoscopy in surgical efficacy: a systematic review and meta-analysis*. Oncotarget 2016;7:70979-90. <https://doi.org/10.18632/oncotarget.10916>
- Albrecht T, Baumann I, Plinkert PK, et al. *Three-dimensional endoscopic visualization in functional endoscopic sinus surgery*. Eur Arch Otorhinolaryngol 2016;273:3753-8. <https://doi.org/10.1007/s00405-016-4040-3>
- Su CH, Lee KS, Tseng TM, et al. *Endoscopic Holmium:YAG laser-assisted lithotripsy: a preliminary report*. B-ENT 2015;11:57-61.
- Sun Y-T, Lee K-S, Hung S-H, et al. *Sialendoscopy with holmium:YAG*

- laser treatment for multiple large sialolithiasis of the Wharton duct: a case report and literature review.* J Oral Maxillofac Surg 2014;72:2491-6. <https://doi.org/10.1016/j.joms.2014.06.448>
- ³⁰ Capaccio P, Torretta S, Pignataro L, et al. *Salivary lithotripsy in the era of sialendoscopy.* Acta Otorhinolaryngol Ital 2017;37:113-21. <https://doi.org/10.14639/0392-100X-1600>
- ³¹ Altieri R, Tardivo V, Pacca P, et al. *3D HD endoscopy in skull base surgery: from darkness to light.* Surg Technol Int 2016;29:359-65.
- ³² Yu S, Han P, Liang F, et al. *Three-dimensional versus two-dimensional endoscopic-assisted thyroidectomy via the anterior chest approach: a preliminary report.* Surg Endosc 2017;31:4194-200. <https://doi.org/10.1007/s00464-017-5477-1>
- ³³ Kari E, Oyesiku NM, Dadashev V, et al. *Comparison of traditional 2-dimensional endoscopic pituitary surgery with new 3-dimensional endoscopic technology: intraoperative and early postoperative factors.* Int Forum Allergy Rhinol 2012;2:2-8. <https://doi.org/10.1002/alr.20036>
- ³⁴ Ogino-Nishimura E, Nakagawa T, Sakamoto T, et al. *Efficacy of three-dimensional endoscopy in endonasal surgery.* Auris Nasus Larynx 2015;42:203-7. <https://doi.org/10.1016/j.anl.2014.10.004>
- ³⁵ Durbec M, Dinkel E, Vigier S, et al. *Thulium-YAG laser sialendoscopy for parotid and submandibular sialolithiasis.* Lasers Surg Med 2012;44:783-6. <https://doi.org/10.1002/lsm.22094>
- ³⁶ Sun Y-T, Lee K-S, Hung S-H, et al. *Sialendoscopy with Holmium:YAG laser treatment for multiple large sialolithiasis of the Wharton Duct: a case report and literature review.* J Oral Maxillofac Surg 2014;72:2491-6. <https://doi.org/10.1016/j.joms.2014.06.448>

Received: July 21, 2018 - Accepted: September 25, 2018

How to cite this article: Capaccio P, Di Pasquale D, Bresciani L, et al. *3D video-assisted trans-oral removal of deep hilo-parenchymal sub-mandibular stones.* Acta Otorhinolaryngol Ital 2019;39:367-373. <https://doi.org/10.14639/0392-100X-2282>

Address for correspondence: Sara Torretta, Department of Clinical Sciences and Community Health, Università degli Studi di Milano, Fondazione IRCCS Ca' Granda Policlinico, via F. Sforza 35, 20122 Milan, Italy. Tel. +39 02 55032563. E-mail: sara.torretta@unimi.it

This is an open access article distributed in accordance with the Creative Commons Attribution Non Commercial (CC BY-NC 4.0) license, which permits others to distribute, remix, adapt, build upon this work non-commercially, and license their derivative works on different terms, provided the original work is properly cited, appropriate credit is given, any changes made indicated, and the use is non-commercial. See: <http://creativecommons.org/licenses/by-nc/4.0/>.