



# Neonatal respiratory and cardiac ECMO in Europe

Ilaria Amodeo<sup>1</sup> · Matteo Di Nardo<sup>2</sup> · Genny Raffaelli<sup>1,3</sup> · Shady Kamel<sup>1,4</sup> · Francesco Macchini<sup>5</sup> · Antonio Amodeo<sup>6</sup> · Fabio Mosca<sup>1,3</sup> · Giacomo Cavallaro<sup>1</sup>

Received: 9 October 2020 / Revised: 25 November 2020 / Accepted: 30 November 2020  
© The Author(s), under exclusive licence to Springer-Verlag GmbH, DE part of Springer Nature 2021

## Abstract

Neonatal extracorporeal membrane oxygenation (ECMO) is a life-saving procedure for critically ill neonates suffering from a potentially reversible disease, causing severe cardiac and/or respiratory failure and refractory to maximal conventional management. Since the 1970s, technology, management, and clinical applications of neonatal ECMO have changed. Pulmonary diseases still represent the principal neonatal diagnosis, with an overall 74% survival rate, and up to one-third of cases are due to congenital diaphragmatic hernia. The overall survival rate in cardiac ECMO is lower, with congenital heart defect representing the main indication. This review provides an overview of the available evidence in the field of neonatal ECMO. We will address the changing epidemiology, basic principles, technologic advances in circuitry, and monitoring, and deliver a current multidisciplinary management framework, focusing on ECMO applications, complications, and long-term morbidities. Lastly, areas for further research will be highlighted.

**Conclusions:** ECMO is a life support with a potential impact on long-term patients' outcomes. In the next years, advances in knowledge, technology, and expertise may push neonatal ECMO boundaries towards more premature and increasingly complex infants, with the final aim to reduce the burden of ECMO-related complications and improve overall patients' outcomes.

## What is Known:

- ECMO is a life-saving option in newborns with refractory respiratory and/or cardiac failure.
- The multidisciplinary ECMO management is challenging and may expose neonates to complications with an impact on long-term outcomes.

## What is New:

- Advances in technology and biomaterials will improve neonatal ECMO management and, eventually, the long-term outcome of these complex patients.
- Experimental models of artificial placenta and womb technology are under investigation and may provide clinical translation and future research opportunities.

---

Ilaria Amodeo and Matteo Di Nardo are co-first authors.

---

Communicated by Daniele De Luca

✉ Giacomo Cavallaro  
giacomo.cavallaro@policlinico.mi.it

Ilaria Amodeo  
amodeoilaria@gmail.com

Matteo Di Nardo  
matteo.dinardo@opbg.net

Genny Raffaelli  
genny.raffaelli@unimi.it

Shady Kamel  
kamelshady.o.f@gmail.com

Francesco Macchini  
francesco.macchini@policlinico.mi.it

Antonio Amodeo  
antonio.amodeo@opbg.net

Fabio Mosca  
fabio.mosca@unimi.it

<sup>1</sup> NICU, Fondazione IRCCS Ca' Granda Ospedale Maggiore Policlinico, Via Della Commenda 12, 20122 Milan, Italy

<sup>2</sup> PICU, Bambino Gesù Children's Hospital, IRCCS, Rome, Italy

<sup>3</sup> Department of Clinical Sciences and Community Health, Università degli Studi di Milano, Milan, Italy

<sup>4</sup> Betamed Perfusion Service, Rome, Italy

<sup>5</sup> Department of Pediatric Surgery, Fondazione IRCCS Ca' Granda Ospedale Maggiore Policlinico, Milan, Italy

<sup>6</sup> ECMO & VAD Unit, Bambino Gesù Children's Hospital, IRCCS, Rome, Italy

**Keywords** Neonate · Developmental Hemostasis · Anticoagulation · ECMO · Respiratory ECMO · Cardiac ECMO · ECMO management · Follow-up · ECMO complications

### Abbreviations

aPTT	Activated partial thromboplastin time
CDH	Congenital diaphragmatic hernia
CHD	Congenital heart disease
CPB	Cardiopulmonary bypass
ECMO	Extracorporeal membrane oxygenation
ECPR	Extracorporeal cardiopulmonary resuscitation
ELSO	Extracorporeal life support organization
GBS	Group B streptococcus
PPHN	Persistent pulmonary hypertension of the newborn
SpreO <sub>2</sub>	Pre-pump blood oxygen saturation
UFH	Unfractionated heparin
VA ECMO	Veno-arterial extracorporeal membrane oxygenation;
VILI	Ventilator-induced lung injury
VV ECMO	Veno-venous extracorporeal membrane oxygenation

### ECMO patients and trends

Neonatal *extracorporeal membrane oxygenation* (ECMO) begins in 1975 with Dr. Bartlett and colleagues at the University of Irvine, CA, USA, where they successfully placed on ECMO Esperanza, a 1-day-old newborn with severe persistent pulmonary hypertension of the newborn (PPHN), after failing conventional therapies [1]. Since then, neonatal ECMO has rapidly evolved due to the increased understanding of cardiopulmonary pathophysiology, advances in medical management, and ECMO technology [2–10].

The principle of ECMO can be resumed as follows: the neonate's deoxygenated blood is taken from the right heart; enters the ECMO circuit; passes through the membrane lung where oxygenation, temperature control, and carbon dioxide clearance are provided; and finally returns to either the arterial system (*veno-arterial*, VA ECMO, Fig. 1A) or the right heart (*veno-venous*, VV ECMO, Fig. 1B, C) [11].

From 1989 to 2020, the Extracorporeal Life Support Organization (ELSO) registry reported 43,707 neonates supported with ECMO worldwide [12].

The number of neonatal respiratory ECMO cases has decreased in the last decade, while cardiac indications remained stable [12]. ECMO survival is variable and depends on the underlying disease [13–19]. Nevertheless, pulmonary diseases still represent the primary diagnosis for neonatal ECMO (Table 1) [12]. In 2019, 280 newborns (160 respiratory, 93 cardiac, and 27 extracorporeal cardiopulmonary resuscitation (ECPR)) have been supported with ECMO in Europe.

### ECMO criteria in neonates

ECMO may be offered to neonates with severe cardiac and/or respiratory failure, refractory to maximal conventional management, potentially reversible etiology, and high mortality risk [20–23]. ECMO criteria, as well as contraindications, are reported in Table 2 [22, 24].

Absolute and relative contraindications are the same for respiratory and cardiac ECMO. Gestational age (< 34 weeks) and low body weight (< 2000 g) have been associated with high rates of intracranial hemorrhage and mortality [20, 25–30]. Currently, the neonatal ECMO population is more critically ill than in the past, making patients' management and cost-benefit assessment more challenging [9, 31]. However, there is wide center-to-center heterogeneity in the lower gestational age limits, based on the local level of expertise [28, 32].

### Neonatal respiratory indications

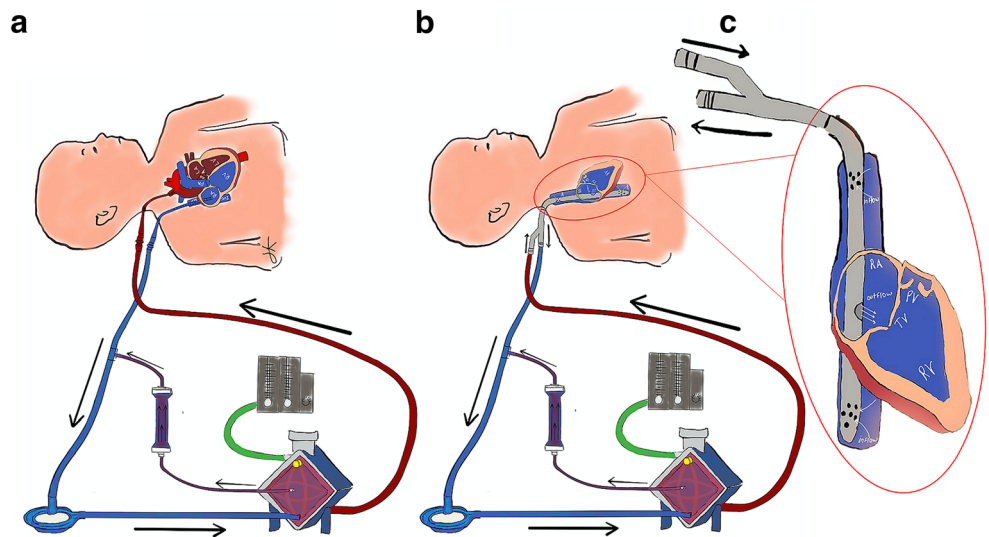
Historically, meconium aspiration syndrome, PPHN, and neonatal respiratory distress syndrome were the most common ECMO indications in the neonatal period. Their incidence has recently declined due to perinatal care improvement [12, 14–17, 33–36]. The use of ECMO for pneumonia and neonatal sepsis has also declined. The universal maternal group B streptococcus (GBS) screening and intrapartum antibiotic prophylaxis induced an 80% reduction of GBS neonatal sepsis and, consequently, sepsis-related ECMO use [8, 37, 38]. Unfortunately, ECMO survival for septic shock did not improve [14, 16, 17, 36, 39]. This data could probably be explained by the increase of more aggressive and resistant pathogens, such as *Escherichia coli* [8, 40].

To date, one-third of ECMO neonatal diagnosis is represented by *congenital diaphragmatic hernia* (CDH). CDH ECMO has a mean survival rate of 50% that has remained unchanged over time [8, 12, 14, 15, 17, 22, 35, 36]. Although there are reports of a significant improvement in CDH ECMO survival rates in highly specialized centers over the past decade, the overall trend is due to the higher risk profile of the actual CDH population compared to the past [8, 41–47].

### ECMO for congenital diaphragmatic hernia

The pathophysiology of CDH includes pulmonary hypoplasia and PPHN, which are responsible for life-threatening cardiorespiratory failure in the first weeks of life [22]. ECMO has the

**Fig. 1** Venous-Arterial (VA) ECMO with passive hemofiltration (a); Venous-Venous (VV) ECMO with dual lumen (DL) single bicaval cannula and passive hemofiltration (b); DL bicaval cannula (c)



potential to rescue severe patients, avoiding iatrogenic lung injury, and providing time for improvement of pulmonary hypertension [45, 47–49].

Criteria predicting high mortality in CDH patients before ECMO have been recently published based on ELSO data [42, 50], while entry criteria suggested by ELSO are substantially the general ones for respiratory failure and pulmonary hypertension of any cause [22, 48, 51–54].

In the 5<sup>th</sup> Edition of the ECLS Red Book [55], CDH ECMO criteria have been integrated with the CDH EURO Consortium Consensus Guidelines Update 2015 (Table 3) [22, 48, 52, 56].

The optimal mode of ECMO in CDH is still debatable. A systematic review showed no differences in survival rates in the use of VV or VA mode. However, VA ECMO is more extensively used, not only for the advantage of providing both

**Table 1** Neonatal ECMO: diagnosis and survival rates between ELSO European and international report

Etiology	ELSO European report*		ELSO international report <sup>o</sup>		Local reports	
	Incidence (%)	Survival (%)	Incidence (%)	Survival (%)	Survival (%)	References
<b>Pulmonary</b>	<b>59.8</b>	<b>74</b>	<b>54.6</b>	<b>68</b>	<b>61.9–79.7</b>	14–18
CDH	33.7	59	33.1	53	46–57.9	14–15, 17, 34–35
MAS	16	97	16.3	91	84.6–100	14–17, 34–35
PPHN	12	71	13.2	72	79.4–84.6	14–15, 35
RDS	0.7	100	0.7	85	92.5–92.9	14, 35
Sepsis	2.6	56	2.6	51	44–69	14, 16–17, 35, 38
Pneumonia	0.8	42	0.5	45	69 <sup>^</sup>	16
Other	33.9	72	33.2	71	8.7–43	14, 16, 35
<b>Cardiac</b>	<b>31.7</b>	<b>46</b>	<b>34.5</b>	<b>50</b>	<b>50–86</b>	15, 18–19
Congenital defect	55.3	51	58.9	48	20–50	34, 69
Cardiogenic shock	4.9	36	4.9	50	-	-
Cardiomyopathy	0.4	0	0.8	40	-	-
Myocarditis	0.4	50	0.7	61	36	77
Other	38.9	55	34.9	54	-	-
<b>ECPR</b>	<b>8.5</b>	<b>39</b>	<b>10.9</b>	<b>44</b>	<b>67</b>	18

\*Survival rates from 2015 to 2019, according to ELSO ECLS Registry Report, European Summary—July 2020 [13]

<sup>o</sup>Survival rates from 2015 to 2019, according to ELSO ECLS Registry Report, International Summary—July 2020 [12]

CDH, congenital diaphragmatic hernia; MAS, meconium aspiration syndrome; PPHN, persistent pulmonary hypertension of the newborn; RDS, respiratory distress syndrome; ECPR, extracorporeal cardiopulmonary resuscitation

<sup>^</sup>Combined survival of sepsis and/or pneumonia

**Table 2** Neonatal ECMO indications and contraindications (adapted from the ELSO Guidelines for Neonatal Respiratory Failure 2017 [22] and ELSO Guidelines for Pediatric Cardiac Failure 2018 [24])

### Neonatal respiratory ECMO

1. Oxygenation index (OI) > 40 for > 4h  

$$OI = \frac{\text{Mean Airway pressure} \times \text{FiO}_2 \times 100}{\text{Post ductal PaO}_2}$$
2. Failure to wean from 100% oxygen despite prolonged (> 48 h) maximal medical therapy or persistent episodes of decompensation
3. Severe hypoxic respiratory failure with acute decompensation ( $\text{PaO}_2 < 40$  mmHg) unresponsive to intervention
4. Severe pulmonary hypertension with evidence of right ventricular dysfunction and/or left ventricular dysfunction
5. Pressor-resistant hypotension

### Neonatal cardiac ECMO

1. Low cardiac output with evidence end-organ malperfusion despite maximal medical therapy
2. Refractory hypotension
3. Low cardiac output with increasing lactates levels (> 4 mmol/L)
4. Low cardiac output state with mixed venous oxygen saturation (or superior central venous oxygen saturation for single ventricles patients) < 50%

### Absolute contraindications

1. Lethal chromosomal disorder<sup>1</sup> or another lethal anomaly
2. Irreversible brain damage
3. Uncontrolled bleeding
4. Grade III or greater intraventricular hemorrhage

### Relative contraindications

1. Irreversible organ damage (unless considered for organ transplant)
2. Weight < 2 kg
3. Postmenstrual age < 34 weeks
4. Mechanical ventilation > 10–14 days

<sup>1</sup> Includes trisomy 13 and trisomy 18 (not trisomy 21)

respiratory and cardiac support [57, 58] but also for the lack of adequate double-lumen cannulas for VV ECMO. Timing for optimal diaphragmatic repair in ECMO patients is controversial. Ideally, it is performed when the patient is stable [59, 60]. Some centers do prefer to delay surgery after ECMO weaning to limit the risk of hemorrhagic complications [60–62]. However, it has been suggested that early surgical repair while on ECMO may increase survival in the most severe forms of CDH [63–65]. Although the optimal timing has not been established, there is an increasing consensus that early repair within the first week of life would improve outcomes [49, 56].

CDH patients usually need long ECMO support, as either the severe vascular disease or pulmonary hypoplasia is less likely to improve over the weeks [8, 12, 42, 49, 66, 67]. Although time limits have not yet been established, a prolonged ECMO course is associated with increased mortality [49].

### ECMO for tracheal and bronchial malformations

Congenital tracheobronchial malformations are rare disorders often associated with other intrathoracic anomalies (e.g., left

pulmonary artery sling, bronchial extension, congenital heart disease) [68]. Currently, several operative approaches can be used for their treatment, including tracheal resection with end-to-end anastomosis, augmentation tracheoplasty with a pericardial patch, and slide tracheoplasty depending on the type, position, and length of the lesion. Peripheral ECMO (VA or VV) can be considered a valid alternative to cardiopulmonary bypass (CPB) to manage these complex lesions. ECMO requires a lower level of anticoagulation and lasts for several days; further, preoperative ECMO may facilitate the diagnostic workup (cardiac ultrasound, bronchoscopy, and computed tomography with three-dimensional reconstruction), often necessary due to the high prevalence of other intrathoracic anomalies. Intraoperative ECMO may allow surgeons to have better access to the operative field than CPB, which requires a mid sternotomy. Postoperative ECMO may allow lung resting with low-pressure mechanical ventilation favoring the healing of the sutures. The type of ECMO (VA vs. VV) varies among centers and surgical expertise. Despite its possible complications (bleeding, sepsis, neurologic injuries), ECMO may be considered the first extracorporeal approach in unstable neonates with an isolated tracheal lesion. Intraoperative conversion to CPB is used in case of concomitant cardiovascular anomalies [69].

### ECMO for neonatal cardiac failure

The use of ECMO for neonatal cardiac failure has progressively increased in the last decade in Europe [13]. Currently, neonatal cardiac ECMO has reported a hospital survival of around 36–55%, which depends mainly on the indications [12, 13, 15, 18, 19]. Pre- and postoperative stabilization of congenital heart disease (CHD) are the most frequent ECMO indication, followed by cardiac arrest, cardiogenic shock, cardiomyopathies and myocarditis, and refractory arrhythmias [12, 13, 35, 70]. Preoperative stabilization (e.g., transposition of great arteries with pulmonary hypertension), failure to wean from cardiopulmonary bypass (stunned myocardium, pulmonary hypertension following cardiac surgery), or postoperative low cardiac output syndrome (Ross-Konno repair, truncus arteriosus repair, anomalous left coronary artery from the pulmonary artery repair, total anomalous pulmonary venous drainage repair) is the most frequent indication for ECMO in neonates with CHD [71, 72]. Risk factors associated with the use of ECMO in CHD are young age, low weight (< 3 kg), pre-ECMO clinical course (mechanical ventilation before surgery > 14 days, presence of fluid overload, cardiopulmonary resuscitation requirements), high complexity of the case according to the STAT classification, presence of shock or arrhythmias, and duration of cardiopulmonary bypass [73].

Cardiac failure associated with septic shock or cardiac arrest (ECPR) is also another ECMO indication in neonates

**Table 3** ECMO Criteria for CDH patients: a comparison between ELSO and CDH Euro Consortium Consensus indications

ELSO*	CDH EURO Consortium Consensus <sup>o</sup>
1. Inability to maintain preductal saturations > 85% or postductal saturations > 70%;	1. Inability to maintain preductal saturations > 85% or postductal saturations > 70%;
2. Respiratory acidosis with pH < 7.15 despite optimal ventilator management;	2. Increased PaCO <sub>2</sub> and respiratory acidosis with pH < 7.15 despite optimization of ventilator management;
3. PIP > 28 cm H <sub>2</sub> O or MAP > 17 cm H <sub>2</sub> O is required to achieve saturation > 85%;	3. PIP > 28 cm H <sub>2</sub> O or MAP > 17 cm H <sub>2</sub> O is required to achieve saturation > 85%;
4. Refractory metabolic acidosis;	4. Inadequate oxygen delivery with metabolic acidosis as measured by elevated lactate ≥ 5 mmol/L and pH < 7.15;
5. PaO <sub>2</sub> < 40 for 4 h on FiO <sub>2</sub> 1.00;	5. Systemic hypotension, resistant to fluid and inotropic therapy, resulting in urine output < 0.5 mL/kg/h for at least 12–24 h;
6. Hypotension refractory to vasopressors;	6. OI ≥ 40 present for at least 3 h.
7. OI > 40 for 4 h.	

\*Adapted from the ELSO Guidelines for neonatal respiratory failure 2017 [22]

<sup>o</sup>Adapted from the CDH EURO Consortium Consensus – 2015 Update [52]

PIP, peak inspiratory pressure; MAP, mean airway pressure; OI, oxygenation index

[71]. Hospital survival in these groups is variable and ranges between 40 and 50% [18, 74, 75].

Causes of cardiac arrest and ECPR initiation may impact survival [55]. In the postcardiotomy population, patients with single ventricle physiology received ECMO for cardiac arrest (56%) and low cardiac output state (44%) [76]. ECPR due to hypoxemia or modified Blalock-Taussig shunt thrombosis reported a higher survival than ECPR for low cardiac output syndrome or right ventricular to pulmonary artery shunt thrombosis [71].

Neonatal myocarditis/cardiomyopathy is rare but often requires ECMO to maintain end-organ perfusion [71]. In these cases, ECMO may be used as a bridge to recovery (e.g., viral myocarditis), bridge to heart transplantation or ventricular assist device, or bridge to decision-making. Survival is poor for cardiomyopathies, often fatal, while it is relatively good for viral myocarditis [77, 78].

Arrhythmias (e.g., supraventricular tachycardia, ventricular tachycardia, bradycardia, or severe atrioventricular block) may occur in the perinatal period (primary arrhythmia), post-operatively, or in myocarditis/cardiomyopathy. ECMO support is generally used to maintain end-organ perfusion while optimizing pharmacological/surgical treatment (e.g., catheter ablation, pacemaker implantation) [79].

Timing for ECMO deployment in neonatal cardiac failure is still controversial; however, early initiation may reduce myocardium exposure and peripheral organs to hypoxia [80]. Cannulation for neonatal cardiac failure may be peripheral as well as central according to the circumstances (e.g., failure to wean from cardiopulmonary bypass, the need for high flow). Neonates unable to be weaned from cardiopulmonary bypass are generally supported with central cannulation, while neonates receiving ECPR can receive either a central or peripheral cannulation based on patient clinical history and

surgical expertise. Current evidence describing the ECMO cannulation site's frequency and its impact on outcomes is limited to retrospective single-center studies, mainly focused on ECPR. Further, conflicting results have been reported describing the neurologic complications of carotid versus central cannulation on mortality [81, 82].

ECMO duration is associated with outcome. Prolonged ECMO in children with cardiac disease carries a high mortality and reduces the chances of a successful heart transplant [83]. Survival drops from 45 % (overall survival of children with cardiac disease) to 23–25 % when ECMO duration is between 14 and 28 days and 13% for ECMO course longer than 28 days [71]. Notably, also neonatal respiratory ECMO duration is associated with poor outcome. Prolonged respiratory ECMO > 21 days has reported a survival of 23.5% [9].

Based on all these considerations, when evaluating ECMO as a bridge to a ventricular assist device, its duration should not be longer than 5–7 days [71, 84].

Optimizing end-organ perfusion and oxygen delivery awaiting myocardium recovery is the primary purpose of ECMO in neonatal cardiac failure, and its efficacy is generally reflected by the clearance of acidosis [70]. Thus, when lactate remains high, other causes of hypoperfusion should be appropriately evaluated. Among these, the persistence of residual lesions and the presence of a stunned and dilated myocardium may negatively impact on survival. Postoperative neonatal cardiac surgery patients unable to be weaned off ECMO should be evaluated for residual lesions, and when present, early correction should be advocated [70]. Unloading the left ventricle by creating an atrial shunt via a septostomy or placing another cannula in the left atrium is the most effective strategy to decompress and perfuse a failing left ventricle, especially when a low dose of inotropes is unable to improve ejection [85].

## ECMO management

Neonatal ECMO should be provided in a dedicated intensive care unit by a multidisciplinary team, including neonatologists, surgeons, perfusionists, nurses, and psychologists. Psychological support for the family is crucial and should be planned in advance, sometimes also before delivering a special diagnosis (e.g., CDH). A high-quality communication between the ECMO team and the family may also help in ECMO withhold or withdrawal. ECMO management at the bedside starts with the circuit priming and with the choice of the cannulas.

Priming is generally constituted by a mixture of packed red cells and plasma [55]. Electrolytes are added to maintain physiologic levels. Cannulas are generally chosen according to the vessels' size, often evaluated with ultrasound [86] (Table 4).

When the cannulas are placed at the neck (either surgical or percutaneously), the position is generally checked with chest X-ray or transthoracic echocardiography [21, 22, 87–89]. When ECMO is connected to the patient, the pump flow should be started slowly at 20 ml/kg/min and increased gradually over 5 to 10 min in order to achieve adequate oxygen delivery. For VA ECMO, pump flow is increased to achieve a pre-pump blood oxygen saturation (SpreO<sub>2</sub>) of 70–80%. On VV ECMO, instead, pump flow is increased to achieve an arterial saturation  $\geq$  80%.

Although most European centers use centrifugal pumps, differently to the USA, where the roller pump is common practice, this discrepancy in the management would not seem to impact on mortality even if O'Halloran et al. demonstrated contrasting data in favor of the use of roller versus centrifugal pump [90].

As the cardiopulmonary function is gradually replaced, blood gases must be strictly monitored and maintained within normal ranges [22]. SpreO<sub>2</sub> is a proxy of tissue oxygenation status, as it reflects the ratio of oxygen delivery to oxygen consumption [22]. Ventilator settings should be tailored at “rest settings” to reduce the risk of VILI, although specific guidelines have not been defined [21, 22]. Serial lung mechanics measurements, such as the forced oscillation technique, may be used to titrate ventilatory support and chest physiotherapy, and support either lung recruitment maneuver and pharmacological treatment [91]. Extubation may be feasible during neonatal ECMO [92].

Fluid management during ECMO is crucial to limit fluid overload and edema [21]. Diuretics, slow continuous ultrafiltration, and continuous renal replacement therapy may be used to achieve dry weight [20, 22, 93]. Full nutritional support should be provided, either enterally or parenterally [22, 94]. Interaction between drugs and non-endothelial surfaces, sequestration into the circuit components, the increase of volume of distribution, and changes in the clearance of many drugs may alter pharmacokinetics and pharmacodynamics;

thus, pharmacotherapy should be tailored accordingly [95, 96].

An overview of the critical points of ECMO management is provided in Fig. 2.

## Anticoagulation

When approaching this critical issue, maturational differences of the hematologic system across age, known as “developmental hemostasis,” should be considered [97–102]. Indeed, despite prolonged activated partial thromboplastin time (aPTT) at birth, the neonatal clotting system is balanced and gradually evolves towards a procoagulant phenotype over the first weeks of life [103, 104].

Further, the priming volume (often around three times the neonate's circulating volume), the use of low ECMO flows, and the contact with foreign surfaces (polyvinyl chloride tubes and polymethylpentene) may impact hemostasis [105–107]. Unfractionated heparin (UFH) is the anticoagulation of choice for neonatal ECMO despite its age-dependent variation in activity [22, 105, 108–112]. As critically ill neonates are also at increased risk of bleeding, namely intracranial hemorrhage, close hemostatic monitoring is required to detect mechanical complications and consumptive coagulopathy [22, 105–107, 112].

As each coagulation assay has advantages and limitations, the optimal test is lacking, and instead, a combination of them is usually performed to tailor UFH dosage and blood product replacement (Table 5) [105, 108–116]. Besides the use of plasmatic assays, such as aPTT and anti-Xa, many centers adopt whole blood-based tests such as activated clotting time, thromboelastography, or rotational thromboelastography [11, 22, 105, 109, 110, 117–123].

Although UFH has molecule- and age-dependent variation in activity, it is the anticoagulant of choice [22, 105, 108–112].

Normal antithrombin levels are essential for UFH efficacy; however, they are physiologically lower in neonates than in children and adults. Evidence for antithrombin supplementation has yet to be proven, and there are increasing concerns regarding thromboembolic events associated with AT supplementation, especially in critically ill newborns and children [124–128]. The presence of high levels of latent antithrombin, with potent pro-coagulative effects, in the commercially available products could explain this phenomenon [129].

Direct thrombin inhibitors are a promising alternative to UFH for anticoagulation in neonates, especially in heparin-induced thrombocytopenia, heparin resistance, or significant thrombosis. Dosing strategies and risk of adverse effects are still a matter of debate [22, 101, 105, 110, 130–134].

Overall, there is still a wide heterogeneity in coagulation management during neonatal ECMO across centers [109, 113, 135–141].

**Table 4** Characteristics of neonatal cannulas (based on Medtronic Bio-Medicus Pediatric Cannulas, technical sheet 2010; Maquet Avalon Elite Bi-Caval Dual Lumen Catheter, technical sheet 2015) and circuits (based

on Permanent Life Support (PLS) System and Quadrox-iD Pediatric (Rotaflow Console with PLS Set))

**Cannula sizes and characteristics**

Cannula	Internal diameter (in.)	Size (Fr)	Tip length (cm)	Blood flow (L/min)*	Radiopacity
SL arterial	1/4	6	10	0.35	Metal spiral ends at 0.5 cm from the tip
		8	10	0.6	
		10	10	1.25	
		12	11	2	
SL venous	1/4	8	10	0.4	Metal spiral ends at 4 cm from the tip
		10	10	0.8	
		12	11	1.3	
		14	12	1.8	
SL arterial NextGen	1/4	9	10	0.6	Metal spiral ends at 0.2 cm from the tip
		11	10.5	1.2	
		13	11	2	
SL venous NextGen	1/4	9	10	0.4	Metal spiral ends at 0.2 cm from the tip
		11	10.5	0.8	
		13	11	1.3	
		15	11.5	1.8	
DL Bi-Caval	1/4	13	11	Arterial 0.5 Venous 0.65	Metal spiral ends at the tip
	1/4	16	14	Arterial 0.75 Venous 1.0	

**Cannula selection**

Weight	VA circuit—SL arterial	VA circuit—SL venous	VV circuit—DL Bi-Caval
< 3 kg	8 Fr	8 Fr	-
3–5 kg	10–12 Fr	10–14 Fr	13 Fr
4–8 kg	10–12 Fr	10–14 Fr	16 Fr

Characteristics of 1/4 in. circuit			
Blood flow (L/min)	0.2–2.8	Oxygenator volume (mL)	81
Gas flow (L/min)	0.1–5.6	Centrifugal pump volume (mL)	32
Venous pressure (mmHg)	< – 80	Hemoconcentrator volume (mL)	17

SL, single lumen; DL, double lumen; VA, veno-arterial; VV, veno-venous; Fr, French

\*Based on blood flow at 100 mmHg for arterial cannula and at – 40 mmHg for venous cannula

## Weaning, decannulation, and withdrawal

As minimal support is reached to ensure tissue oxygenation, decannulation is considered. Trial-off support is performed to test the patient's readiness for weaning before any attempt of decannulation [22].

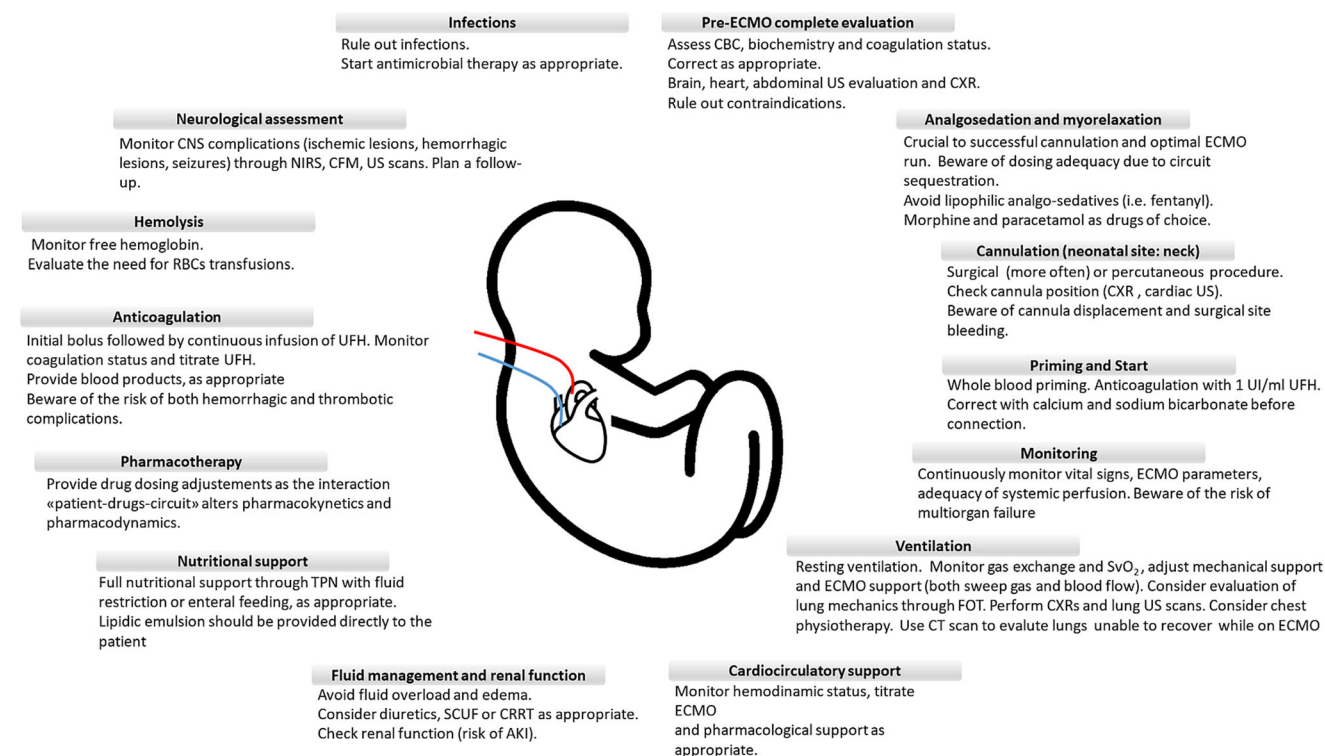
During VV ECMO, native gas exchange is evaluated by progressively reducing sweep gas flow while adjusting ventilatory support. When the gas flow is stopped and gas exchange is adequate with minimal ventilator support, patients are ready to be weaned. During VA ECMO, the blood flow rate and gas flow is gradually reduced over time while adapting the ventilator setting and monitoring patients' status. Alternatively, a bridge may be inserted into the circuit between the venous and the arterial side, to allow blood flow to re-circulate within the circuit, thus excluding the patients. Achieving low flow conditions in

neonates is often impossible due to the required minimum flow for the ECMO devices (100–200 ml/min). Thus, other groups successfully promoted trial-off with a retrograde pump flow of the ECMO circuit [142]. If trial-off is tolerated, the patient is ready for decannulation [21, 22]. The carotid artery's repair is rarely performed and is still a matter of debate [22, 143].

ECMO should also be discontinued if there is no hope of survival, there is no chance of organ replacement, or the patient has not shown any improvement during a reasonable amount of time, which must be defined on a case by case basis [21].

## Complications

Critical issues related to hemostatic disturbances make hemorrhagic and thrombotic complications prevalent, with

**ECMO critical points and management.**

CBC: complete blood count; US: ultrasound; CXR: chest X-ray; UFH: unfractionated heparin; SvO<sub>2</sub>: mixed venous saturation; FOT: forced oscillation techniques; SCU: slow continuous ultrafiltration; CRRT: continuous renal replacement therapy; AKI: acute kidney injury; TPN: total parenteral nutrition; RBCs: red blood cells; CNS: central nervous system; NIRS: near infrared spectroscopy; CFM: cerebral function monitoring.

**Fig. 2** Overview of the critical points of ECMO management

decreased survival rates [144, 145]. Circuit clotting is the most frequent mechanical complication, being the oxygenator the most common site. Coagulation abnormalities may lead to ischemic and hemorrhagic injuries [12, 22]. Since brain injuries are worrisome during neonatal ECMO, bedside imaging and neuromonitoring are mandatory during and after ECMO [22, 146–148].

Among the most severe neurological complications, seizures, ischemic infarction, and brain death are frequent and associated with poor prognosis [149, 150]. Cerebral function monitoring, continuous electroencephalography, and near-infrared spectroscopy may help to detect neurologic events, although pediatric literature is still limited [11, 151].

A degree of renal impairment, ranging from oliguria to renal failure, frequently occurs while on ECMO. Acute kidney injury and fluid overload are independent risk factors associated with increased mortality [152, 153]. Chronic kidney injury is less frequent since the long-term renal function is usually restored [154].

Cannulas, central lines, immobility, and general conditions are risk factors for infections associated with increased ECMO duration and higher mortality [20, 155]. Routine prophylaxis is not recommended unless a specific culture demonstrates an ongoing infection, while antibiotic coverage for cannulation should follow standard surgical prophylaxis [156–159].

Arrhythmias and myocardial dysfunction are common in VA mode. Other complications, like cannula displacement and cardiac tamponade, are life-threatening and need to be promptly recognized and corrected (Fig. 3) [20].

## Long-term morbidities and follow-up

Improved survival carries a higher risk of long-term morbidity among survivors depending on several factors, such as the primary underlying condition and adverse events arising during the ECMO course [12, 13, 49, 160–167].

Among respiratory ECMO patients, the risk of developmental disabilities is significantly increased [150, 168–172]. Bilateral sensorineural hearing loss, motor problems, learning difficulties, behavior disorders, and cognitive and neuropsychological impairments require specific assessment and multidisciplinary long-term follow-up [160, 161, 166, 167, 173–178].

Nevertheless, adult ECMO survivors show high self-esteem and are satisfied with their quality of life [179–181].

The need for oxygen supplementation, pulmonary hypertension, obstructive pattern with bronchospasm, asthma, decreased exercise tolerance, and chronic lung disease are



**Table 5** Assessment of coagulation status and management during neonatal ECMO

**Anticoagulation**

Administration of UFH: bolus of UFH 50 UI/kg at cannulation, followed by continuous infusion at 25 UI/kg/h

**Coagulation monitoring and management**

<b>Parameter</b>	<b>Characteristics</b>	<b>Target</b>	<b>Intervention</b>	<b>Advantages</b>	<b>Disadvantages</b>
<b>AT</b>	- Sample: citrated plasma - Endpoint: available AT	80–120%	Consider AT supplementation	- Possible optimization of UFH dose and effect	- Lack of evidence of improved clinical outcome following AT supplementation - Possible increased risk of bleeding and thrombosis
<b>ACT</b>	- Point of care test - Sample: whole blood - Endpoint: clot detection	180–220 s	Titrate UFH infusion, especially at ECMO start	- Small sample size (2–3 whole blood drops) - Low cost - Rapid and easy to perform - Suitable for transport	- Least related to UFH doses and UFH changes - Poor correlation with aPTT at lower UFH (risk of underestimation of heparin effect) - Influenced by hemodilution, thrombocytopenia, platelet dysfunction, hypothermia, age, coagulation factors deficiencies - Analyzer and reagent dependent
<b>aPTT</b>	- Clotting-based assay - Sample: citrated plasma - Endpoint: thrombus detection - Monitors intrinsic and common coagulation pathways (factors XII, XI, IX, X, V, II, fibrinogen)	Ratio 1.5–2.5 times baseline	Titrate UFH infusion Consider fresh-frozen plasma if aPTT is prolonged	- Low cost, widely used, readily available - Suitable for transport - Can detect underlying factor deficiencies (congenital or acquired), vitamin K deficiency, DIC in presence of UFH by using heparinase	- Age-dependent effect of UFH on aPTT - Poor correlation with ACT and anti-Xa results in neonates - Mainly responsive to procoagulant drivers, does not reflect in vivo hemostasis - Influenced by UFH contamination of sample, hemodilution, coagulation factor deficiencies, and liver disease increased bilirubin, triglycerides, and plasma free Hb - Large blood sample size - Analyzer and reagent dependent - Risk of pre-analytic errors (i.e., suboptimal tube filling)
<b>Anti-Xa</b>	- Functional assay - Sample: citrated plasma - Endpoint: bound Factor Xa	0.3–0.7 IU/mL	Titrate UFH infusion	- Direct measurement of heparin effect on Factor Xa - Can monitor the effect of LMWH and oral Anti-Xa drugs - Calibration of aPTT reference ranges	- Anti-IIa effect not measured - Influenced by AT levels and assay type (exogenous AT, dextran sulfate additive), hyperbilirubinemia, triglycerides, and elevated plasma free Hb - High costs - Not available in all laboratories - Experienced staff needed
<b>TEG</b>	- Point of care test - Sample: whole blood	R times in kaolin should be 2- to 3-fold longer than R times in heparinase: consider	Titrate UFH infusion and blood products Long R times in heparinase: consider	- Small sample size - Rapid and easy to perform - Suitable for transport	- Influenced by the reagents and plasma free Hb - Lack of neonatal ranges of TEG parameters for anticoagulation during ECMO

Table 5 (continued)

## Anticoagulation

<p>- Endpoint: clot formation, strength, and breakdown</p> <ul style="list-style-type: none"> <li>• R time: time to factor IIa generation and fibrin formation;</li> <li>• Angle and K: fibrin mesh formation;</li> <li>• MA: platelet function and platelet fibrin interaction;</li> <li>• LY30: clot lysis 30 min after MA</li> </ul>	<p>heparinase (i.e., R times in kaolin 15–25 min)</p> <p>fresh-frozen plasma administration</p> <p>Low ratio R kaolin/R heparinase: consider increase heparin</p> <p>High ratio R kaolin/R heparinase: consider decrease heparin</p> <p>Low MA values: check platelet count and fibrinogen levels and correct</p>	<p>- Viscoelastic clotting tests with real-time global assessment of hemostasis (clot formation, strength, fibrinolysis)</p> <p>- Can monitor the role of fibrinogen and platelet</p> <p>- Can assess in vitro coagulation with UFH (kaolin) or without UFH (kaolin + heparinase), thus allowing to evaluate native hemostasis</p>
<p><b>Platelets</b></p> <p>- Sample: EDTA blood</p> <p>- Endpoint: platelet count</p>	<p>&gt; 80,000–100,000 if high risk of bleeding</p> <p>&gt; 45,000 if low risk of bleeding</p> <p>Consider administration of platelets (20 mL/kg)</p>	<p>- Platelet count does not reflect platelet function</p> <p>- Platelets may stick to the ECMO circuit components, contributing to either circuit deterioration and bleeding risk in patients</p> <p>- Fibrinogen is usually depleted on ECMO and shows less sensitivity in detecting DIC</p>
<p><b>Fibrinogen</b></p> <p>- Sample: citrated plasma</p> <p>- Endpoint: fibrinogen concentration</p>	<p>&gt; 100–150 mg/dL</p> <p>Consider administration of fibrinogen concentrate:</p> <ul style="list-style-type: none"> <li>- 50–70 mg/kg if fibrinogen &lt; 50 mg/dL</li> <li>- 30 mg/kg if fibrinogen 50–100 mg/dL</li> </ul> <p>Consider fresh-frozen plasma</p> <p>If D-dimer levels increase:</p> <ul style="list-style-type: none"> <li>- Check the circuit for clots</li> <li>- Consider changing the oxygenator</li> </ul> <p>Consider fresh-frozen plasma if PT is prolonged</p>	<p>- Low cost, widely used, readily available</p> <p>- Low cost, widely used, readily available</p> <p>- Role in detecting hypercoagulability and DIC, including the concurrent evaluation of platelet count and D-dimers</p> <p>- Monitors fibrinolysis</p> <p>- Role in detecting hyperfibrinolysis and DIC together with fibrinogen status and platelet count trends</p> <p>- Low cost, widely used, readily available</p> <p>- Suitable for transport</p> <p>- Can detect effects of vitamin K inhibitors and Anti-Xa agents</p>
<p><b>D-Dimers</b></p> <p>- Sample: citrated plasma</p> <p>- Endpoint: available fibrin split products</p>	<p>&lt; 300 µg/L</p> <p>Ratio &lt; 1.5 times baseline</p>	<p>- Low specificity</p>
<p><b>PT</b></p> <p>- Clotting-based assay</p> <p>- Sample: citrated plasma</p> <p>- Endpoint: thrombus detection</p> <p>- Monitors extrinsic coagulation pathway</p>	<p>Ratio &lt; 1.5 times baseline</p> <p>PT is prolonged</p>	<p>- Does not reflect the UFH effect</p> <p>- Age, analyzer, and reagent dependent</p> <p>- Large blood sample size</p>

AT, antithrombin; UFH, unfractionated heparin; ACT, activated clotting time; aPTT, activated partial thromboplastin time; DIC, disseminated intravascular coagulation; EDTA, ethylenediaminetetraacetic acid; LMWH, low molecular weight heparin; TEG, thromboelastography; PT, prothrombin time

Additional details and specific references are provided in the text

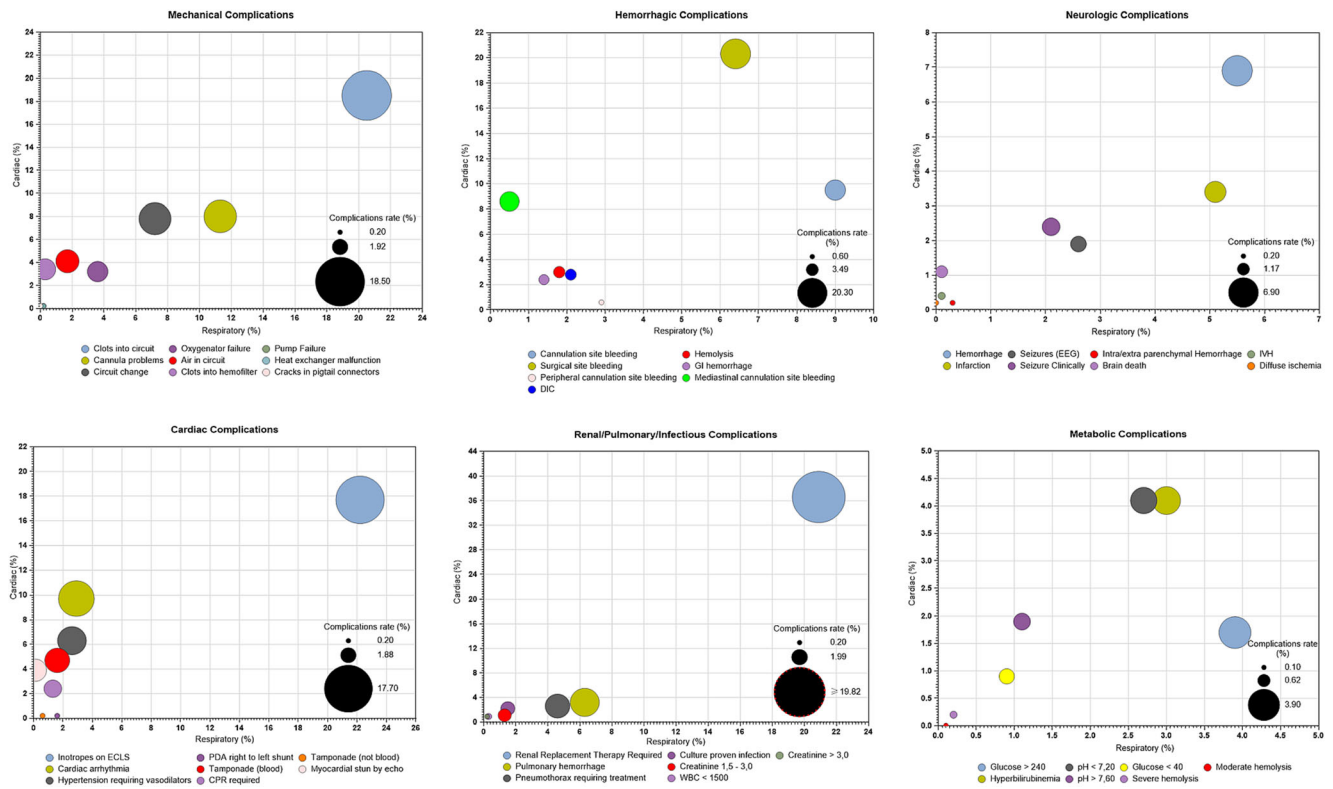


Fig. 3 Complications during neonatal respiratory and cardiac ECMO and incidence

among the most common conditions within the long-term respiratory morbidity [59, 161, 162, 173, 182–185].

The growth pattern is generally typical or slightly decreased in ECMO survivors, with good chances of catch-up growth during childhood and adolescence [162, 173, 186].

Most deaths occur while on bypass or early on in the hospital course, while late deaths occurring after ECMO discontinuation are uncommon and mainly affecting CDH patients (14.3%) [187].

There are considerable data regarding survival to hospital discharge of neonates receiving ECMO for cardiac failure; however, limited data exist on intermediate- and long-term outcomes. Among survivors, 40–60% reported new neurologic deficits and low health-related quality of life than healthy controls [188–190]. Neurologic complications may have variable features (language acquisition delay, motor development stages delay, behavioral problems) and represent a source of significant morbidity and long-term care requirements [190]. Due to the cohorts’ heterogeneity, which includes different age groups and different ECMO indications (ECPR, low cardiac output syndrome, septic shock, myocarditis), a robust conclusion cannot be achieved.

In the light of these considerations, standardized follow-up protocols among centers and data sharing are important to provide further knowledge and implement interventions to prevent and manage complications, improve quality assistance, and improve the overall quality of life.

## Conclusions and future directions

Over the years, ECLS technology and expertise have considerably improved, pushing the lower limit of gestational age and suggesting that ECMO use may be potentially extended to more premature infants in the next years [28].

Experimental models of artificial placenta have been developed [191–193]. An ideal artificial placenta provides ECMO through the umbilical vessels, thus preserving major fetal blood vessels from cannulation. It uses low partial pressure of oxygen because of fetal hemoglobin features and increases hematocrit levels. No ventilation is required since the infant could “breathe” with fluid-filled lungs (perfluorocarbon liquid ventilation), reducing the risk of VILI to the developing lungs [194–197]. A trial using an artificial placenta in preterm lambs showed increased survival compared to mechanical-ventilated lambs [192]. An experimental extra-uterine system to physiologically support fetal lambs has shown encouraging results in terms of hemodynamic stability, oxygenation, and maintenance of fetal circulation [193].

Advances in technology, materials, and miniaturization of equipment would help to reduce ECMO-related complications. Biomimetic or biopassive tubing may mitigate the adverse effects of the contact between blood and non-endothelial surfaces, but their efficacy is partial [101]. The endothelization of the circuit would provide physiological regulation of coagulation and inflammatory response in

ECMO patients. However, the in vitro process is technically challenging, takes time, and cannot be produced in urgent settings [198–201]; the in vivo process is currently not feasible, but ongoing research is promising. Lastly, paracorporeal lung assist devices might be explored in selected cases where traditional ECMO is not an option, although evidence for hybrid approaches is scarce [202].

**Acknowledgments** The authors would like to thank all the “Neonatal ECMO Team Mangiagalli” of the Fondazione IRCCS Ca’ Granda Ospedale Maggiore Policlinico and the “Neonatal and Pediatric ECMO Team” of Children’s Hospital Bambino Gesù (Area Rossa), IRCCS, Rome, Italy; surgeons of the Department of Pediatric Surgery of the Fondazione IRCCS Ca’ Granda Ospedale Maggiore Policlinico; anesthesiologists of the Pediatric Anesthesiology and Intensive Care Unit; and nurses of the operating room of the Fondazione IRCCS Ca’ Granda Ospedale Maggiore Policlinico.

**Author contributions** IA, GR, MDN, FMo, FMa, AA, and GC contributed conception and design of the manuscript; SK and GC developed the graphic part of the manuscript. IA, GR, MDN, and GC wrote the first draft of the manuscript. All authors contributed to manuscript critical revision and read and approved the submitted version.

**Data availability** N/A

## Compliance with ethical standards

**Conflict of interest** The authors declare that they have no conflict of interest.

**Ethics approval** N/A

**Consent to participate** N/A

**Consent for publication** N/A

**Code availability** N/A

## References

- Bartlett RH (2017) Esperanza: the first neonatal ECMO patient. *ASAIO J* 63(6):832–843
- Hintz SR, Suttner DM, Sheehan AM, Rhine WD, Van Meurs KP (2000 Dec) Decreased use of neonatal extracorporeal membrane oxygenation (ECMO): how new treatment modalities have affected ECMO utilization. *Pediatrics* 106(6):1339–1343
- Kennaugh JM, Kinsella JP, Abman SH, Hernandez JA, Moreland SG, Rosenberg AA (1997) Impact of new treatments for neonatal pulmonary hypertension on extracorporeal membrane oxygenation use and outcome. *J Perinatol* 17(5):366–369
- Christou H, Van Marter LJ, Wessel DL, Allred EN, Kane JW, Thompson JE et al (2000 Nov) Inhaled nitric oxide reduces the need for extracorporeal membrane oxygenation in infants with persistent pulmonary hypertension of the newborn. *Crit Care Med* 28(11):3722–3727
- Barrington KJ, Finer N, Pennaforte T, Altit G (2017) Nitric oxide for respiratory failure in infants born at or near term. *Cochrane Database Syst Rev* 2017, Issue 1. Art. No.: CD000399. <https://doi.org/10.1002/14651858.CD000399.pub3>. Accessed 8 Jan 2021.
- El Shahed AI, Dargaville PA, Ohlsson A, Soll R (2014) Surfactant for meconium aspiration syndrome in term and late preterm infants. *Cochrane Database Syst Rev* 2014, Issue 12. Art. No.: CD002054. <https://doi.org/10.1002/14651858.CD002054.pub3>. Accessed 8 Jan 2021.
- Bartlett RH (2005 Feb) Extracorporeal life support: history and new directions. *Semin Perinatol* 29(1):2–7
- Mahmood B, Newton D, Pallotto EK (2018) Current trends in neonatal ECMO. *Semin Perinatol* 42(2):80–88
- Sharma J, Sherman A, Rimal A, Haney B, Weiner J, Pallotto E (2020) Neonatal respiratory extracorporeal membrane oxygenation and primary diagnosis: trends between two decades. *J Perinatol* 40(2):269–274
- Konduri GG, Sokol GM, Van Meurs KP, Singer J, Ambalavanan N, Lee T et al (2013) Impact of early surfactant and inhaled nitric oxide therapies on outcomes in term/late preterm neonates with moderate hypoxic respiratory failure. *J Perinatol* 33(12):944–949
- Valencia E, Nasr VG (2020) Updates in pediatric extracorporeal membrane oxygenation. *J Cardiothorac Vasc Anesth* 34(5):1309–1323
- Extracorporeal Life Support Organization (2020) ECLS Registry Report. International summary - July 2020. Available on January 8, 2021; from <https://www.elseo.org>
- Extracorporeal Life Support Organization (2020) ECLS Registry Report. European summary - July 2020. Available on January 8, 2021; from <https://www.elseo.org>
- Karimova A, Brown K, Ridout D, Beierlein W, Cassidy J, Smith J et al (2009) Neonatal extracorporeal membrane oxygenation: practice patterns and predictors of outcome in the UK. *Arch Dis Child Fetal Neonatal Ed* 94(2), F129–F132.
- Kuok CM, Tsao PN, Chen CY, Chou HC, Hsieh WS, Huang SC, Chen YS, Wu ET (2017) Extracorporeal membrane oxygenation support in neonates: a single medical center experience in Taiwan. *Pediatr Neonatol* 58(4):355–361
- Schaible T, Hermle D, Loersch F, Demirakca S, Reinshagen K, Varnholt V (2010) A 20-year experience on neonatal extracorporeal membrane oxygenation in a referral center. *Intensive Care Med* 36(7):1229–1234
- Reiterer F, Resch E, Haim M, Maurer-Fellbaum U, Riccabona M, Zobel G et al (2018) Neonatal extracorporeal membrane oxygenation due to respiratory failure: a single center experience over 28 years. *Front Pediatr* 6(September):1–7
- Trivedi P, Glass K, Clark JB, Myers JL, Cilley RE, Ceneviva G, Wang S, Kunselman AR, Ündar A (2019) Clinical outcomes of neonatal and pediatric extracorporeal life support: a seventeen-year, single institution experience. *Artif Organs* 43(11):1085–1091
- Hsu J, Chang CH, Chiang LT, Caffrey JL, Lin JW, Chen YS (2019) Survival analysis of extracorporeal membrane oxygenation in neonatal and pediatric patients – a nationwide cohort study. *J Formos Med Assoc* 118(9):1339–1346. <https://doi.org/10.1016/j.jfma.2018.12.008>
- Fletcher K, Chapman R, Keene S (2018) An overview of medical ECMO for neonates. *Semin Perinatol* 42(2):68–79
- Extracorporeal Life Support Organization (2017) ELSO Guidelines for Cardiopulmonary Extracorporeal Life Support. pp 1–26. Available on January 8, 2021; from <https://www.elseo.org>
- Wild KT, Rintoul N, Kattan J, Gray B, Keene S, Best D et al (2020) Extracorporeal Life Support Organization (ELSO): Guidelines for Neonatal Respiratory Failure. *Asaio Journal* 66(5):463–70.

23. Maclaren G, Conrad S, Peek G, Peek G, Maclaren G, Brodie D (2015) ELSO Guidelines: Indications for pediatric respiratory extracorporeal life support, pp 1–8
24. Extracorporeal Life Support Organization. ECLS Guidelines 2018 - x Failure. 2018;1–43. Available on January 8, 2021; from <http://www.else.org>
25. Hardart GE, Hardart MKM, Arnold JH (2004 Aug) Intracranial hemorrhage in premature neonates treated with extracorporeal membrane oxygenation correlates with conceptional age. *J Pediatr* 145(2):184–189
26. Ramachandrapa A, Rosenberg ES, Wagoner S, Jain L (2011) Morbidity and mortality in late preterm infants with severe hypoxic respiratory failure on extra-corporeal membrane oxygenation. *J Pediatr* 159(2):192–198.e3
27. McMullan DM, Thiagarajan RR, Smith KM, Rycus PT, Brogan TV (2014) Extracorporeal cardiopulmonary resuscitation outcomes in term and premature neonates. *Pediatr Crit Care Med* 15(1):9–16
28. Church JT, Kim AC, Erickson KM, Rana A, Drongowski R, Hirschl RB, Bartlett RH, Mychaliska GB (2017 Nov) Pushing the boundaries of ECLS: outcomes in < 34 week EGA neonates. *J Pediatr Surg* 52(11):1810–1815
29. Revenis ME, Glass P, Short B (1992 Sep) Lou. Mortality and morbidity rates among lower birth weight infants (2000 to 2500 grams) treated with extracorporeal membrane oxygenation. *J Pediatr* 121(3):452–458
30. Cilley R, Zwischenberger J, Andrews A, Bowerman R, Roloff D, Bartlett R (1986) Intracranial hemorrhage during extracorporeal membrane oxygenation in neonates. *Pediatrics* 78(4):699–704.
31. Di Nardo M, Ore AD, Testa G, Annich G, Piervincenzi E, Zampini G et al (2019) Principlism and personalism. comparing two ethical models applied clinically in neonates undergoing extracorporeal membrane oxygenation support. *Front Pediatr* 7(JULY):1–9
32. Chapman RL, Peterec SM, Bizzarro MJ, Mercurio MR (2009) Patient selection for neonatal extracorporeal membrane oxygenation: beyond severity of illness. *J Perinatol* 29(9):606–611
33. American College of Obstetricians and Gynecologists (2007) ACOG Committee Opinion No. 394: cesarean delivery on maternal request. *Obstet Gynecol* 110(6):1501
34. Yoder B (2002 May) Changing obstetric practices associated with decreasing incidence of meconium aspiration syndrome. *Obstet Gynecol* 99(5):731–739
35. Yeo AS, Chong JH, Tan TH, Ng AS, Rajadurai VS, Chan YH (2014) Neonatal and Paediatric Extracorporeal Membrane Oxygenation (ECMO) in a Single Asian Tertiary Centre. *Ann Acad Med Singap* 43(7):355–61
36. Brown KL, Sriram S, Ridout D, Cassidy J, Pandya H, Liddell M, Davis C, Goldman A, Field D, Karimova A (2010) Extracorporeal membrane oxygenation and term neonatal respiratory failure deaths in the United Kingdom compared with the United States: 1999 to 2005. *Pediatr Crit Care Med* 11(1):60–65
37. Puopolo KM, Lynfield R, Cummings JJ (2019 Aug) Management of infants at risk for group B streptococcal disease. *Pediatrics* 144(2):e20191881
38. Nair IS (2020 Feb) Prevention of group B streptococcal early-onset disease in newborns: ACOG Committee Opinion, Number 797. *Obstet Gynecol* 135(2):e51–e72
39. Rambaud J, Guellec I, Léger PL, Renolleau S, Guilbert J (2015) Venoarterial extracorporeal membrane oxygenation support for neonatal and pediatric refractory septic shock. *Indian J Crit Care Med* 19(10):600–605
40. Butt WW, Chiletto R (2020) ECMO for neonatal sepsis in 2019. *Front. Pediatr* 8:50. <https://doi.org/10.3389/fped.2020.00050>
41. Ford J (2006) Neonatal ECMO: current controversies and trends. *Neonatal Netw* 25(4):229–238
42. Guner YS, Delaplain PT, Zhang L, Di Nardo M, Brogan TV, Chen Y et al (2019) Trends in mortality and risk characteristics of congenital diaphragmatic hernia treated with extracorporeal membrane oxygenation. *ASAIO J* 65(5):509–515
43. Kays DW, Islam S, Perkins JM, Larson SD, Taylor JA, Talbert JL (2015) Outcomes in the physiologically most severe congenital diaphragmatic hernia (CDH) patients: whom should we treat? *J Pediatr Surg* 50(6):893–897
44. Morini F, Goldman A, Pierro A (2006) Extracorporeal membrane oxygenation in infants with congenital diaphragmatic hernia: a systematic review of the evidence. *Eur J Pediatr Surg* 16(6):385–391
45. Zalla JM, Stoddard GJ, Yoder BA (2015) Improved mortality rate for congenital diaphragmatic hernia in the modern era of management: 15 year experience in a single institution. *J Pediatr Surg* 50(4):524–527
46. Snoek KG, Greenough A, Van Rosmalen J, Capolupo I, Schaible T, Ali K et al (2017) Congenital diaphragmatic hernia: 10-year evaluation of survival, extracorporeal membrane oxygenation, and foetoscopic endotracheal occlusion in four high-volume centres. *Neonatology* 113(1):63–68
47. Kays DW (2017) ECMO in CDH: is there a role? *Semin Pediatr Surg* 26(3):166–170
48. Brogan TV, Lequier L, Lorusso R, Peek G (2017) Congenital diaphragmatic hernia and ECMO. In: Brogan TV, Lequier L, Lorusso R, MacLaren G, Peek G (eds) *Extracorporeal life support: the ELSO red book*, 5th edn. Ann Arbor, Michigan
49. Grover TR, Rintoul NE, Hedrick HL (2018) Extracorporeal membrane oxygenation in infants with congenital diaphragmatic hernia. *Semin Perinatol* 42(2):96–103
50. Guner YS, Nguyen DV, Zhang L, Chen Y, Harting MT, Rycus P, Barbaro R, di Nardo M, Brogan TV, Cleary JP, Yu PT (2018) Development and validation of extracorporeal membrane oxygenation mortality-risk models for congenital diaphragmatic Hernia. *ASAIO J* 64(6):785–794
51. Chandrasekharan PK, Rawat M, Madappa R, Rothstein DH, Lakshminrusimha S (2017 Dec 11) Congenital Diaphragmatic hernia – a review. *Matern Heal Neonatol Perinatol* 3(1):6
52. Snoek KG, Reiss IKM, Greenough A, Capolupo I, Urlesberger B, Wessel L, Storme L, Deprest J, Schaible T, van Heijst A, Tibboel D, for the CDH EURO Consortium (2016) Standardized postnatal management of infants with congenital diaphragmatic hernia in Europe: the CDH EURO Consortium Consensus - 2015 Update. *Neonatology* 110(1):66–74
53. Russo FM, Eastwood MP, Keijzer R, Al-Maary J, Toelen J, Van Mieghem T et al (2017) Lung size and liver herniation predict need for extracorporeal membrane oxygenation but not pulmonary hypertension in isolated congenital diaphragmatic hernia: systematic review and meta-analysis. *Ultrasound Obstet Gynecol* 49(6):704–713
54. Oluyomi-Obi T, Kuret V, Puligandla P, Lodha A, Lee-Robertson H, Lee K, Somerset D, Johnson J, Ryan G (2017) Antenatal predictors of outcome in prenatally diagnosed congenital diaphragmatic hernia (CDH). *J Pediatr Surg* 52(5):881–888
55. Brogan TV, Lequier L, Lorusso R, Al E (2017) In: Brogan TV, Lequier L, Lorusso R et al (eds) *Red book*, 5th edn. Ann Arbor, Michigan
56. Rafat N, Schaible T (2019) Extracorporeal membrane oxygenation in congenital diaphragmatic hernia. *Front Pediatr* 7(August):1–9
57. Puligandla PS, Grabowski J, Austin M, Hedrick H, Renaud E, Arnold M, Williams RF, Graziano K, Dasgupta R, McKee M, Lopez ME, Jancelewicz T, Goldin A, Downard CD, Islam S (2015) Management of congenital diaphragmatic hernia: a systematic review from the APSA outcomes and evidence based practice committee. *J Pediatr Surg* 50(11):1958–1970

58. Guner YS, Khemani RG, Qureshi FG, Wee CP, Austin MT, Dorey F, Rycus PT, Ford HR, Friedlich P, Stein JE (2009) Outcome analysis of neonates with congenital diaphragmatic hernia treated with venovenous vs venoarterial extracorporeal membrane oxygenation. *J Pediatr Surg* 44(9):1691–1701
59. Grover TR, Murthy K, Brozanski B, Gien J, Rintoul N, Keene S, Najaf T, Chicoine L, Porta N, Zaniletti I, Pallotto EK, Children's Hospitals Neonatal Consortium (2015) Short-term outcomes and medical and surgical interventions in infants with congenital diaphragmatic hernia. *Am J Perinatol* 32(11):1038–1044
60. Golden J, Jones N, Zagory J, Castle S, Bliss D (2017) Outcomes of congenital diaphragmatic hernia repair on extracorporeal life support. *Pediatr Surg Int* 33(2):125–131
61. Bryner BS, West BT, Hirschl RB, Drongowski RA, Lally KP, Lally P et al (2009) Congenital diaphragmatic hernia requiring extracorporeal membrane oxygenation: does timing of repair matter? *J Pediatr Surg* 44(6):1165–1172
62. Partridge EA, Peranteau WH, Rintoul NE, Herkert LM, Flake AW, Adzick NS, Hedrick HL (2015) Timing of repair of congenital diaphragmatic hernia in patients supported by extracorporeal membrane oxygenation (ECMO). *J Pediatr Surg* 50(2):260–262
63. Prabhu S, Mattke AC, Anderson B, McBride C, Cooke L, Karl T, Alphonso N (2016) Repair of congenital diaphragmatic hernia during extracorporeal life support: experience with six neonates. *ANZ J Surg* 86(9):711–716
64. Dassinger MS, Copeland DR, Gossett J, Little DC, Jackson RJ, Smith SD (2010) Early repair of congenital diaphragmatic hernia on extracorporeal membrane oxygenation. *J Pediatr Surg* 45(4):693–697
65. Fallon SC, Cass DL, Olutoye OO, Zamora JJ, Lazar DA, Larimer EL, Welty SE, Moise AA, Demny AB, Lee TC (2013) Repair of congenital diaphragmatic hernias on extracorporeal membrane oxygenation (ECMO): does early repair improve patient survival? *J Pediatr Surg* 48(6):1172–1176
66. Prophan P, Stroud M, El-Hassan N, Peoples S, Rycus P, Brogan TV et al (2014) Prolonged extracorporeal membrane oxygenator support among neonates with acute respiratory failure: a review of the Extracorporeal Life Support Organization registry. *ASAIO J* 60(1):63–69
67. Dillon PW, Cilley RE, Mauger D, Zachary C, Meier A (2004) The relationship of pulmonary artery pressure and survival in congenital diaphragmatic hernia. *J Pediatr Surg* 39(3):307–312. Discussion 307-12
68. Yeh Y-T, Liu C, Tsai H-L, Wu F-Y, Soong W-J, Lee Y-S, Tsao PC (2019) A combination of tracheoplasty and tracheal stenting is an acceptable method of treating severe congenital tracheobronchial stenosis under extracorporeal membrane oxygenation. *J Pediatr Surg* 54(12):2492–2497
69. Antón-Pacheco JL, Cano I, Comas J, Galletti L, Polo L, García A, López M, Cabezalí D (2006) Management of congenital tracheal stenosis in infancy. *Eur J Cardio-thoracic Surg* 29(6):991–996
70. Howard TS, Kalish BT, Wigmore D, Nathan M, Kulik TJ, Kaza AK, Williams K, Thiagarajan RR (2016) Association of extracorporeal membrane oxygenation support adequacy and residual lesions with outcomes in neonates supported after cardiac surgery\*. *Pediatr Crit Care Med* 17(11):1045–1054
71. Roeleveld PP, Mendonca M (2019) Neonatal cardiac ECMO in 2019 and beyond. *Front Pediatr* 7(August):1–13
72. Di Nardo M, MacLaren G, Marano M, Cecchetti C, Bernaschi P, Amodeo A (2016) ECLS in pediatric cardiac patients. *Front Pediatr* 7:4
73. Mascio CE, Austin EH, Jacobs JP, Jacobs ML, Wallace AS, He X et al (2014) Perioperative mechanical circulatory support in children: an analysis of the society of thoracic surgeons congenital heart surgery database. *J Thorac Cardiovasc Surg* 147(2):658–665. <https://doi.org/10.1016/j.jtcvs.2013.09.075>
74. Shakoor A, Pedroso FE, Jacobs SE, Okochi S, Zenilman A, Cheung EW, Middlesworth W (2019) Extracorporeal cardiopulmonary resuscitation (ECPR) in infants and children: a single-center retrospective study. *World J Pediatr Congenit Hear Surg* 10(5):582–589
75. van Leeuwen Bichara GC, Furlanetto B, Gondim Teixeira L, Di Nardo M (2019) Is peripheral venovenous-arterial ECMO a feasible alternative to central cannulation for pediatric refractory septic shock? *Intensive Care Med* 45(11):1658–1660
76. Hoskote A, Bohn D, Gruenwald C, Edgell D, Cai S, Adatia I, van Arsdell G (2006) Extracorporeal life support after staged palliation of a functional single ventricle: subsequent morbidity and survival. *J Thorac Cardiovasc Surg* 131(5):1114–1121
77. Lin K-M, Li M-H, Hsieh K-S, Kuo H-C, Cheng M-C, Sheu J-J, Lin YJ (2016) Impact of extracorporeal membrane oxygenation on acute fulminant myocarditis-related hemodynamic compromise arrhythmia in children. *Pediatr Neonatol* 57(6):480–487
78. Cortina G, Best D, Deisenberg M, Chiletto R, Butt W (2018) Extracorporeal membrane oxygenation for neonatal collapse caused by enterovirus myocarditis. *Arch Dis Child Fetal Neonatal Ed* 103(4):F370–F376
79. Dyamenahalli U, Tuzcu V, Fontenot E, Papagiannis J, Jaquiss R, Bhutta A, Morrow WR, Erickson CC, Imamura M, Prophan P (2012) Extracorporeal membrane oxygenation support for intractable primary arrhythmias and complete congenital heart block in newborns and infants. *Pediatr Crit Care Med* 13(1):47–52
80. Ford MA, Gauvreau K, McMullan DM, Almodovar MC, Cooper DS, Rycus PT et al (2016) Factors associated with mortality in neonates requiring extracorporeal membrane oxygenation for cardiac indications. *Pediatr Crit Care Med* 17(9):860–870
81. Teele SA, Salvin JW, Barrett CS, Rycus PT, Fynn-Thompson F, Laussen PC, Thiagarajan RR (2014) The association of carotid artery cannulation and neurologic injury in pediatric patients supported with venoarterial extracorporeal membrane oxygenation\*. *Pediatr Crit Care Med* 15(4):355–361
82. Lasa JJ, Jain P, Raymond TT, Minard CG, Topjian A, Nadkarni V, Gaies M, Bembea M, Checchia PA, Shekerdemian LS, Thiagarajan R (2018) Extracorporeal cardiopulmonary resuscitation in the pediatric cardiac population. *Pediatr Crit Care Med* 19(2):125–130
83. Merrill ED, Schoeneberg L, Sandesara P, Molitor-Kirsch E, O'Brien J, Dai H et al (2014) Outcomes after prolonged extracorporeal membrane oxygenation support in children with cardiac disease—Extracorporeal Life Support Organization registry study. *J Thorac Cardiovasc Surg* 148(2):582–588
84. Villa CR, Lorts A, Riggs KW, Alten J, Morales DL (2019) How small can you go? A 2.5-kg infant with pulmonary atresia and coronary atresia bridged to cardiac transplantation with a paracorporeal-continuous flow ventricular assist device. *J Thorac Cardiovasc Surg* 158(2):e67–e69
85. Eastaugh LJ, Thiagarajan RR, Darst JR, McElhinney DB, Lock JE, Marshall AC (2015) Percutaneous left atrial decompression in patients supported with extracorporeal membrane oxygenation for cardiac disease\*. *Pediatr Crit Care Med* 16(1):59–65
86. Pantalos GM, Abel DE, Ravisankar A, Horrell TJ, Lind C, Funk A, Austin EH III, Mascio CE (2012) In vitro pumping performance evaluation of the ension pediatric cardiopulmonary assist system for venoarterial and venovenous ECMO. *Cardiovasc Eng Technol* 3(3):250–262
87. Macchini F, Di Cesare A, Morandi A, Ichino M, Raffaelli G, Conigliaro F et al (2019) Surgical expertise in neonatal extracorporeal membrane oxygenation (ECMO): a single center experience. *Front Pediatr* 7:7
88. Mayer A, Raffaelli G, Schena F, Parente V, Sorrentino G, Macchini F et al (2019) Successful extracorporeal membrane oxygenation after incidental azygos vein cannulation in a neonate

- with right-sided congenital diaphragmatic hernia interruption of the inferior vena cava and azygos continuation. *Front Pediatr* 7(October):1–6
89. Thomas TH, Price R, Ramaciotti C, Thompson M, Megison S, Lemler MS (2009) Echocardiography, not chest radiography, for evaluation of cannula placement during pediatric extracorporeal membrane oxygenation\*. *Pediatr Crit Care Med* 10(1):56–59
  90. O'Halloran CP, Thiagarajan RR, Yarlagadda VV, Barbaro RP, Nasr VG, Rycus P et al (2019) Outcomes of infants supported with extracorporeal membrane oxygenation using centrifugal versus roller pumps: an analysis from the Extracorporeal Life Support Organization Registry. *Pediatr Crit Care Med* 20(12):1177–1184
  91. Raffaelli G, Veneroni C, Ghirardello S, Lavizzari A, Passera S, Mosca F et al (2018) Role of lung function monitoring by the forced oscillation technique for tailoring ventilation and weaning in neonatal ECMO: new insights from a case report. *Front Pediatr* 6:332. <https://doi.org/10.3389/fped.2018.00332>
  92. Costa J, Dimberger DR, Froehlich CD, Beaty CD, Priest MA, Ogino MT (2020) Awake Neonatal Extracorporeal Membrane Oxygenation. *ASAIO J* 66(5):e70–e73
  93. Chen H, Yu RG, Yin NN, Zhou JX (2014) Combination of extracorporeal membrane oxygenation and continuous renal replacement therapy in critically ill patients: a systematic review. *Crit Care* 18(1):1–11
  94. Stoppe C, Nesterova E, Elke G (2018) Nutritional support in patients with extracorporeal life support and ventricular assist devices. *Curr Opin Crit Care* 24(4):269–276
  95. Raffaelli G, Pokorna P, Allegaert K, Mosca F, Cavallaro G, Wildschut ED et al (2019) Drug disposition and pharmacotherapy in neonatal ECMO: from fragmented data to integrated knowledge. *Front. Pediatr* 7:360. <https://doi.org/10.3389/fped.2019.00360>
  96. Raffaelli G, Cavallaro G, Allegaert K, Koch BCP, Mosca F, Tibboel D et al (2020) Sequestration of voriconazole and vancomycin into contemporary extracorporeal membrane oxygenation circuits: an in vitro study. *Front. Pediatr* 8:468. <https://doi.org/10.3389/fped.2020.00468>
  97. Andrew M, Vegh P, Johnston M, Bowker J, Ofosu F, Mitchell L (1992) Maturation of the hemostatic system during childhood. *Blood* 80(8):1998–2005
  98. Favalaro EJ, Lippi G (2017) Translational aspects of developmental hemostasis: infants and children are not miniature adults and even adults may be different. *Ann Transl Med* 5(10):212
  99. Cheung PY, Sawicki G, Salas E, Etches PC, Schulz R, Radomski MW (2000) The mechanisms of platelet dysfunction during extracorporeal membrane oxygenation in critically ill neonates. *Crit Care Med* 28(7):2584–2590
  100. Monagle P, Newall F, Campbell J (2010) Anticoagulation in neonates and children: pitfalls and dilemmas. *Blood Rev* 24(4–5):151–162
  101. Sniderman J, Monagle P, Annich GM, MacLaren G (2020) Hematologic concerns in extracorporeal membrane oxygenation. *Res Pract Thromb Haemost* 4(4):455–468
  102. Cashen K, Meert K, Dalton H (2019) Anticoagulation in neonatal ECMO: an enigma despite a lot of effort! *Front Pediatr* 7(September):1–11
  103. Raffaelli G, Tripodi A, Cavallaro G, Cortesi V, Scalabrino E, Pesenti N, Artoni A, Mosca F, Ghirardello S (2020) Thromboelastographic profiles of healthy very low birthweight infants serially during their first month. *Arch Dis Child - Fetal Neonatal Ed* 105(4):412–418
  104. Tripodi A, Raffaelli G, Scalabrino E, Padovan L, Clerici M, Chantarangkul V, Cavallaro G, Peyvandi F, Mosca F, Ghirardello S (2020) Procoagulant imbalance in preterm neonates detected by thrombin generation procedures. *Thromb Res* 185:96–101
  105. Kamdar A, Rintoul N, Raffini L (2018) Anticoagulation in neonatal ECMO. *Semin Perinatol* 42(2):122–128
  106. Arnold P, Jackson S, Wallis J, Smith J, Bolton D, Haynes S (2001) Coagulation factor activity during neonatal extracorporeal membrane oxygenation. *Intensive Care Med* 27(8):1395–1400
  107. Murphy DA, Hockings LE, Andrews RK, Aubron C, Gardiner EE, Pellegrino VA, Davis AK (2015) Extracorporeal membrane oxygenation-hemostatic complications. *Transfus Med Rev* 29(2):90–101
  108. Annich G, Adachi I (2013) Anticoagulation for pediatric mechanical circulatory support. *Pediatr Crit Care Med* 14(5 Suppl 1):S37–S42
  109. Saini A, Spinella PC (2014) Management of anticoagulation and hemostasis for pediatric extracorporeal membrane oxygenation. *Clin Lab Med* 34(3):655–673
  110. Barton R, Ignjatovic V, Monagle P (2019) Anticoagulation during ECMO in neonatal and paediatric patients. *Thromb Res* 173(2017):172–177
  111. Hirsh J, Anand SS, Halperin JL, Fuster V (2001) Mechanism of action and pharmacology of unfractionated heparin. *Arterioscler Thromb Vasc Biol* 21(7):1094–1096
  112. Bridges B, Ranucci M, Lequier R (2017) Anticoagulation and disorders of haemostasis. In: Brogan TV, Lequier L, Lorusso R, MacLaren G, Peek G (eds) *Extracorporeal life support: the ELSO red book*, 5th edn. Ann Arbor, Michigan, pp 93–103
  113. Bembea MM, Annich G, Rycus P, Oldenburg G, Berkowitz I, Pronovost P (2013) Variability in anticoagulation management of patients on extracorporeal membrane oxygenation: an international survey. *Pediatr Crit Care Med* 14(2):e77–e84
  114. Khaja WA, Bilen O, Lukner RB, Edwards R, Teruya J (2010) Evaluation of heparin assay for coagulation management in newborns undergoing ECMO. *Am J Clin Pathol* 134(6):950–954
  115. Sulkowski JP, Preston TJ, Cooper JN, Duffy VL, Deans KJ, Chicoine LG, Minneci PC (2014) Comparison of routine laboratory measures of heparin anticoagulation for neonates on extracorporeal membrane oxygenation. *J Extra Corpor Technol* 46(1):69–76
  116. Hansen JB, Svensson B, Olsen R, Ezban M, Osterud B, Paulssen RH (2000) Heparin induces synthesis and secretion of tissue factor pathway inhibitor from endothelial cells in vitro. *Thromb Haemost* 83(6):937–943
  117. Padhya DP, Prutsky GJ, Nemerug ME, Schears GS, Flick RP, Farah W, Wang Z, Prokop LJ, Murad MH, Alsawas M (2019) Routine laboratory measures of heparin anticoagulation for children on extracorporeal membrane oxygenation: systematic review and meta-analysis. *Thromb Res* 179(February):132–139
  118. Henderson N, Sullivan JE, Myers J, Wells T, Calhoun A, Berkenbosch J, Tzanetos DT (2018) Use of thromboelastography to predict thrombotic complications in pediatric and neonatal extracorporeal membranous oxygenation. *J Extra Corpor Technol* 50(3):149–154
  119. Newall F, Johnston L, Ignjatovic V, Monagle P (2009) Unfractionated heparin therapy in infants and children. *Pediatrics* 123(3):e510–e518
  120. Monagle P, Barnes C, Ignjatovic V, Furmedge J, Newall F, Chan A, de Rosa L, Hamilton S, Ragg P, Robinson S, Auldlist A, Crock C, Roy N, Rowlands S (2006) Developmental haemostasis. Impact for clinical haemostasis laboratories. *Thromb Haemost* 95(2):362–372
  121. Kuhle S, Eulmesekian P, Kavanagh B, Massicotte P, Vegh P, Lau A et al (2007) Lack of correlation between heparin dose and standard clinical monitoring tests in treatment with unfractionated heparin in critically ill children. *Haematologica* [Internet] 92(4):554–557. Available from: <http://www.ncbi.nlm.nih.gov/pubmed/17488668>

122. Maul TM, Wolff EL, Kuch BA, Rosendorff A, Morell VO, Wearden PD (2012) Activated partial thromboplastin time is a better trending tool in pediatric extracorporeal membrane oxygenation. *Pediatr Crit Care Med* 13(6):e363–e371
123. Liveris A, Bello RA, Friedmann P, Duffy MA, Manwani D, Killinger JS, Rodriguez D, Weinstein S (2014) Anti-factor Xa assay is a superior correlate of heparin dose than activated partial thromboplastin time or activated clotting time in pediatric extracorporeal membrane oxygenation\*. *Pediatr Crit Care Med* 15(2):e72–e79
124. Allingstrup M, Wetterslev J, Ravn FB, Møller AM, Afshari A (2016) Antithrombin III for critically ill patients: a systematic review with meta-analysis and trial sequential analysis. *Intensive Care Med* 42(4):505–520
125. Wong TE, Nguyen T, Shah SS, Brogan TV, Witmer CM (2016) Antithrombin concentrate use in pediatric extracorporeal membrane oxygenation: a multicenter cohort study\*. *Pediatr Crit Care Med* 17(12):1170–1178
126. Stansfield BK, Wise L, Ham PB, Patel P, Parman M, Jin C et al (2017) Outcomes following routine antithrombin III replacement during neonatal extracorporeal membrane oxygenation. *J Pediatr Surg* 52(4):609–613
127. Perry R, Stein J, Young G, Ramanathan R, Seri I, Klee L, Friedlich P (2013) Antithrombin III administration in neonates with congenital diaphragmatic hernia during the first three days of extracorporeal membrane oxygenation. *J Pediatr Surg* 48(9):1837–1842
128. Niebler RA, Christensen M, Berens R, Wellner H, Mikhailov T, Tweddell JS (2011) Antithrombin replacement during extracorporeal membrane oxygenation. *Artif Organs* 35(11):1024–1028
129. Broman LM (2020) When antithrombin substitution strikes back. *Perfusion* 35(1\_suppl):34–37
130. Sanfilippo F, Asmussen S, Maybauer DM, Santonocito C, Fraser JF, Erdoes G, Maybauer MO (2017) Bivalirudin for alternative anticoagulation in extracorporeal membrane oxygenation: a systematic review. *J Intensive Care Med* 32(5):312–319
131. Scott LK, Grier LR, Conrad SA (2006) Heparin-induced thrombocytopenia in a pediatric patient receiving extracorporeal membrane oxygenation managed with argatroban. *Pediatr Crit Care Med* 7(5):473–475
132. Nagle EL, Dager WE, Duby JJ, Roberts AJ, Kenny LE, Murthy MS et al (2013) Bivalirudin in pediatric patients maintained on extracorporeal life support. *Pediatr Crit Care Med* 14(4):5–9
133. Pieri M, Agracheva N, Bonaveglia E, Greco T, De Bonis M, Covello RD et al (2013) Bivalirudin versus heparin as an anticoagulant during extracorporeal membrane oxygenation: a case-control study. *J Cardiothorac Vasc Anesth* 27(1):30–34
134. Ranucci M, Ballotta A, Kandil H, Isgro G, Carlucci C, Baryshnikova E, Pistuddi V, the Surgical and Clinical Outcome Research Group (2011) Bivalirudin-based versus conventional heparin anticoagulation for postcardiotomy extracorporeal membrane oxygenation. *Crit Care* 15(6):R275
135. Paden ML, Rycus PT, Thiagarajan RR, ELSO Registry (2014) Update and outcomes in extracorporeal life support. *Semin Perinatol* 38(2):65–70
136. Cashen K, Dalton H, Reeder RW, Saini A, Zuppa AF, Shanley TP, Newth CJL, Pollack MM, Wessel D, Carcillo J, Harrison R, Dean JM, Meert KL, Eunice Kennedy Shriver National Institute of Child Health and Human Development Collaborative Pediatric Critical Care Research Network (CPCCRN) (2020) Platelet transfusion practice and related outcomes in pediatric extracorporeal membrane oxygenation\*. *Pediatr Crit Care Med* 21(2):178–185
137. Verrijckt A, Proulx F, Morneau S, Vobecky S (2004) Activated recombinant factor VII for refractory bleeding during extracorporeal membrane oxygenation. *J Thorac Cardiovasc Surg* 127(6):1812–1813
138. Repessé X, Au SM, Bréchet N, Trouillet JL, Leprince P, Chastre J et al (2013) Recombinant factor VIIa for uncontrollable bleeding in patients with extracorporeal membrane oxygenation: report on 15 cases and literature review *Crit Care* 17(2), R55.
139. Swaminathan M, Shaw AD, Greenfield RA, Grichnik KP (2008) Fatal thrombosis after factor VII administration during extracorporeal membrane oxygenation. *J Cardiothorac Vasc Anesth* 22(2):259–260
140. Downard CD, Betit P, Chang RW, Garza JJ, Arnold JH, Wilson JM (2003) Impact of AMICAR on hemorrhagic complications of ECMO: a ten-year review. *J Pediatr Surg* 38(8):1212–1216
141. Bui JD, Despotis GD, Trulock EP, Alexander Patterson G, Goodnough LT (2002) Fatal thrombosis after administration of activated prothrombin complex concentrates in a patient supported by extracorporeal membrane oxygenation who had received activated recombinant factor VII. *J Thorac Cardiovasc Surg* 124(4):852–854
142. Westrope C, Harvey C, Robinson S, Speggorin S, Faulkner G, Peek GJ (2013) Pump controlled retrograde trial off from VA-ECMO. *ASAIO J* 59(5):517–519
143. Duggan EM, Maitre N, Zhai A, Krishnamoorthi H, Voskresensky I, Hardison D, Tice J, Pietsch JB, Lovvorn HN III (2015) Neonatal carotid repair at ECMO decannulation: patency rates and early neurologic outcomes. *J Pediatr Surg* 50(1):64–68
144. Dalton HJ, Garcia-Filion P, Holubkov R, Moler FW, Shanley T, Heidemann S, Meert K, Berg RA, Berger J, Carcillo J, Newth C, Harrison R, Doctor A, Rycus P, Dean JM, Jenkins T, Nicholson C, Eunice Kennedy Shriver National Institute of Child Health and Human Development Collaborative Pediatric Critical Care Research Network (2015) Association of bleeding and thrombosis with outcome in extracorporeal life support. *Pediatr Crit Care Med* 16(2):167–174
145. Dalton HJ, Reeder R, Garcia-Filion P, Holubkov R, Berg RA, Zuppa A, Moler FW, Shanley T, Pollack MM, Newth C, Berger J, Wessel D, Carcillo J, Bell M, Heidemann S, Meert KL, Harrison R, Doctor A, Tamburro RF, Dean JM, Jenkins T, Nicholson C, Eunice Kennedy Shriver National Institute of Child Health and Human Development Collaborative Pediatric Critical Care Research Network (2017) Factors associated with bleeding and thrombosis in children receiving extracorporeal membrane oxygenation. *Am J Respir Crit Care Med* 196(6):762–771
146. Bulas D, Glass P (2005) Neonatal ECMO: neuroimaging and neurodevelopmental outcome. *Semin Perinatol* 29(1):58–65
147. Wien MA, Whitehead MT, Bulas D, Ridore M, Melbourne L, Oldenburg G, Short BL, Massaro AN (2017) Patterns of brain injury in newborns treated with extracorporeal membrane oxygenation. *Am J Neuroradiol* 38(4):820–826
148. Schiller RM, van den Bosch GE, Muetzel RL, Smits M, Dudink J, Tibboel D, Ijsselstijn H, White T (2017) Neonatal critical illness and development: white matter and hippocampus alterations in school-age neonatal extracorporeal membrane oxygenation survivors. *Dev Med Child Neurol* 59(3):304–310
149. Polito A, Barrett CS, Wypij D, Rycus PT, Netto R, Cogo PE, Thiagarajan RR (2013) Neurologic complications in neonates supported with extracorporeal membrane oxygenation. An analysis of ELSO registry data. *Intensive Care Med* 39(9):1594–1601
150. Parish AP, Bunyapen C, Cohen MJ, Garrison T, Bhatia J (2004) Seizures as a predictor of long-term neurodevelopmental outcome in survivors of neonatal extracorporeal membrane oxygenation (ECMO). *J Child Neurol* 19(12):930–934
151. Tian F, Jenks C, Potter D, Miles D, Raman L (2017) Regional cerebral abnormalities measured by frequency-domain near-infrared spectroscopy in pediatric patients during extracorporeal membrane oxygenation. *ASAIO J* 63(5):e52–e59
152. Askenazi DJ, Ambalavanan N, Hamilton K, Cutter G, Laney D, Kaslow R, Georgeson K, Barnhart DC, Dimmitt RA (2011) Acute



- kidney injury and renal replacement therapy independently predict mortality in neonatal and pediatric noncardiac patients on extracorporeal membrane oxygenation. *Pediatr Crit Care Med* 12(1): e1–e6
153. Fleming GM, Sahay R, Zappitelli M, King E, Askenazi DJ, Bridges BC, Paden ML, Selewski DT, Cooper DS (2016) The incidence of acute kidney injury and its effect on neonatal and pediatric extracorporeal membrane oxygenation outcomes. *Pediatr Crit Care Med* 17(12):1157–1169
  154. Paden ML, Warshaw BL, Heard ML, Fortenberry JD (2011) Recovery of renal function and survival after continuous renal replacement therapy during extracorporeal membrane oxygenation. *Pediatr Crit Care Med* 12(2):153–158
  155. Bizzarro MJ, Conrad SA, Kaufman DA, Rycus P (2011) Infections acquired during extracorporeal membrane oxygenation in neonates, children, and adults. *Pediatr Crit Care Med* 12(3): 277–281
  156. Extracorporeal Life Support Organization (2012) ELSO ID TASK FORCE Recommendation Summary. Available on January 8, 2021, from: <https://www.else.org/Portals/0/Files/ELSO-ID-Task-Force-Recommendations-Summary.pdf>
  157. O'Horo JC, Cawcutt KA, De Moraes AG, Sampathkumar P, Schears GJ (2016) The evidence base for prophylactic antibiotics in patients receiving extracorporeal membrane oxygenation. *ASAIO J* 62(1):6–10
  158. Glater-Welt LB, Schneider JB, Zinger MM, Rosen L, Sweberg TM (2016) Nosocomial bloodstream infections in patients receiving extracorporeal life support: variability in prevention practices: a survey of the Extracorporeal Life Support Organization members. *J Intensive Care Med* 31(10):654–659
  159. Hsu M-S, Chiu K-M, Huang Y-T, Kao K-L, Chu S-H, Liao C-H (2009 Nov) Risk factors for nosocomial infection during extracorporeal membrane oxygenation. *J Hosp Infect.* 73(3):210–216
  160. Schiller RM, Madderom MJ, Reuser JJCM, Steiner K, Gischler SJ, Tibboel D et al (2016) Neuropsychological follow-up after neonatal ECMO. *Pediatrics* 138(5):e20161313; <https://doi.org/10.1542/peds.2016-1313>
  161. McNally H, Bennett CC, Elbourne D, Field DJ (2006) United Kingdom collaborative randomized trial of neonatal extracorporeal membrane oxygenation: follow-up to age 7 years. *Pediatrics* 117(5):e845–e854
  162. Cortes RA, Keller RL, Townsend T, Harrison MR, Farmer DL, Lee H, Picuch RE, Leonard CH, Hetherington M, Bisgaard R, Nobuhara KK (2005) Survival of severe congenital diaphragmatic hernia has morbid consequences. *J Pediatr Surg* 40(1):36–46
  163. Glass P, Bulas D, Wagner A, Rajasingham S, Civitello L, HPapero P et al (1997) Severity of brain injury following neonatal extracorporeal membrane oxygenation and outcome at age 5 years. *Dev Med Child Neurol* 39(7):441–448
  164. The Collaborative UK (1998) ECMO Trial: follow-up to 1 year of age. *Pediatrics* 101(4):e1–e1
  165. Robertson CMT, Finer NN, Sauve RS, Whitfield MF, Belgaumkar TK, Synnes AR, Grace MG (1995) Neurodevelopmental outcome after neonatal extracorporeal membrane oxygenation. *Cmaj* 152(12):1981–1988
  166. Khambekar K, Nichani S, Luyt DK, Peek G, Firmin RK, Field DJ et al (2006) Developmental outcome in newborn infants treated for acute respiratory failure with extracorporeal membrane oxygenation: present experience. *Arch Dis Child Fetal Neonatal Ed* 91(1): 21–25
  167. Danzer E, Hoffman C, D'Agostino JA, Gerdes M, Bembaum J, Antiel RM et al (2017) Neurodevelopmental outcomes at 5 years of age in congenital diaphragmatic hernia. *J Pediatr Surg* 52(3): 437–443
  168. Danzer E, Zarnow D, Gerdes M, D'Agostino JA, Siegle J, Bebbington MW et al (2012) Abnormal brain development and maturation on magnetic resonance imaging in survivors of severe congenital diaphragmatic hernia. *J Pediatr Surg* 47(3):453–461
  169. Madderom MJ, Reuser JJCM, Utens EMWJ, Van Rosmalen J, Raets M, Govaert P et al (2013) Neurodevelopmental, educational and behavioral outcome at 8 years after neonatal ECMO: a nationwide multicenter study. *Intensive Care Med* 39(9):1584–1593
  170. Graziani LJ, Gringlas M, Baumgart S (1997) Cerebrovascular complications and neurodevelopmental sequelae of neonatal ECMO. *Clin Perinatol* 24(3):655–675
  171. Van Heijst AFJ, De Mol AC, IJsselstijn H (2014) ECMO in neonates: neuroimaging findings and outcome. *Semin Perinatol* 38(2): 104–113
  172. Mehta A (2013) Neurologic complications and neurodevelopmental outcome with extracorporeal life support. *World J Crit Care Med* 2(4):40–47
  173. IJsselstijn H, Van Heijst AFJ (2014) Long-term outcome of children treated with neonatal extracorporeal membrane oxygenation: increasing problems with increasing age. *Semin Perinatol* 38(2): 114–121
  174. Macrae DJ, Field DJ (2016) Our study 20 years on: UK collaborative randomised trial of neonatal extracorporeal membrane oxygenation. *Intensive Care Med* 42(5):841–843
  175. Fligor BJ, Neault MW, Mullen CH, Feldman HA, Jones DT (2005) Factors associated with sensorineural hearing loss among survivors of extracorporeal membrane oxygenation therapy. *Pediatrics* 115(6):1519–1528
  176. Murray M, Nield T, Larson-Tuttle C, Seri I, Friedlich PS (2011) Sensorineural hearing loss at 9-13 years of age in children with a history of neonatal extracorporeal membrane oxygenation. *Arch Dis Child Fetal Neonatal Ed* 96(2):128–132
  177. Van Den Hondel D, Madderom MJ, Goedegebure A, Gischler SJ, Mazer P, Tibboel D et al (2013) Sensorineural hearing loss and language development following neonatal extracorporeal membrane oxygenation. *Pediatr Crit Care Med* 14(1):62–69
  178. Schiller RM, Tibboel D (2019) Neurocognitive outcome after treatment with(out) ECMO for neonatal critical respiratory or cardiac failure. *Front Pediatr* 7(November):1–9
  179. Engle WA, West KW, Hocutt GA, Pallotto EK, Haney B, Keith RJ, Stewart DL, Knodel E, Suttner D, Chapman R, Thomas A, Schwerin B, Stork E, Crowley M, Piazza AJ, Heard ML, Gebregziabher N, Fadel W, Bartlett R (2017) Adult outcomes after newborn respiratory failure treated with extracorporeal membrane oxygenation. *Pediatr Crit Care Med* 18(1):73–79
  180. Madderom M.J. (2013) Long-term Follow-up of Children Treated with Neonatal Extracorporeal Membrane Oxygenation: neuropsychological outcome. Erasmus University Rotterdam. Available on 08 January 2021, from: <http://hdl.handle.net/1765/40289>
  181. Toussaint LCC, Van Der Cammen-Van Zijp MHM, Janssen AJ, Tibboel D, Van Heijst AF, IJsselstijn H (2016) Perceived motor competence differs from actual performance in 8-year-old neonatal ECMO survivors. *Pediatrics* 137(3):e20152724; <https://doi.org/10.1542/peds.2015-2724>
  182. Hoffhuis W, Hanekamp MN, IJsselstijn H, Nieuwhof EM, Hop WCJ, Tibboel D et al (2011) Prospective longitudinal evaluation of lung function during the first year of life after extracorporeal membrane oxygenation. *Pediatr Crit Care Med* 12(2):159–164
  183. Hamutcu R, Nield TA, Garg M, Keens TG, Platzker ACG (2004) Long-term pulmonary sequelae in children who were treated with extracorporeal membrane oxygenation for neonatal respiratory failure. *Pediatrics* 114(5):1292–1296
  184. Jaillard SM, Pierrat V, Dubois A, Truffert P, Lequien P, Wurtz AJ, Storme L (2003) Outcome at 2 years of infants with congenital diaphragmatic hernia: a population-based study. *Ann Thorac Surg* 75(1):250–256

185. Wynn J, Krishnan U, Aspelund G, Zhang Y, Duong J, Stolar CJH et al (2013) Outcomes of Congenital Diaphragmatic Hernia in the Modern Era of Management. *J Pediatr* 163(1):114–119.e1
186. Pierog A, Aspelund G, Farkouh-Karoleski C, Wu M, Kriger J, Wynn J, Krishnan U, Mencin A (2014) Predictors of low weight and tube feedings in children with congenital diaphragmatic hernia at 1 year of age. *J Pediatr Gastroenterol Nutr* 59(4):527–530
187. Iguchi A, Ridout DA, Galan S, Bodlani C, Squire K, O'Callaghan M, Brown KL (2013) Long-term survival outcomes and causes of late death in neonates, infants, and children treated with extracorporeal life support. *Pediatr Crit Care Med* 14(6):580–586
188. Peer SM, Emerson DA, Costello JP, Shu MK, Zurakowski D, Jonas RA, Berger JT, Nath DS (2014) Intermediate-term results of extracorporeal membrane oxygenation support following congenital heart surgery. *World J Pediatr Congenit Hear Surg* 5(2):236–240
189. Garcia Guerra G, Robertson CMT, Alton GY, Joffe AR, Moez EK, Dinu IA, Ross DB, Rebeyka IM, Lequier L, Western Canadian Complex Pediatric Therapies Follow-Up Group (2014) Health-related quality of life in pediatric cardiac extracorporeal life support survivors\*. *Pediatr Crit Care Med* 15(8):720–727
190. Fleck TPK, Dangel G, Bächle F, Benk C, Grohmann J, Kroll J, Siepe M, Höhn R, Kirschner J, Beyersdorf F, Stiller B (2017) Long-Term follow-up on health-related quality of life after mechanical circulatory support in children. *Pediatr Crit Care Med* 18(2):176–182
191. Schoberer M, Arens J, Lohr A, Seehase M, Jellema RK, Collins JJ, Kramer BW, Schmitz-Rode T, Steinseifer U, Orlikowsky T (2012) Fifty years of work on the artificial placenta: milestones in the history of extracorporeal support of the premature newborn. *Artif Organs* 36(6):512–516
192. Bryner BS, Mychaliska GB (2014) ECLS for preemies: the artificial placenta. *Semin Perinatol* 38(2):122–129
193. Partridge EA, Davey MG, Hornick MA, McGovern PE, Mejaddam AY, Vrecenak JD et al (2017) An extra-uterine system to physiologically support the extreme premature lamb. *Nat Commun* 8:15112
194. Church JT, Perkins EM, Coughlin MA, McLeod JS, Boss K, Bentley JK et al (2018) Perfluorocarbons prevent lung injury and promote development during artificial placenta support in extremely premature lambs. *Neonatology* 113(4):313–321
195. Mychaliska GB (2016) The artificial placenta: is clinical translation next? *Pediatr Pulmonol* 51(6):557–559
196. Reoma JL, Rojas A, Kim AC, Khouri JS, Boothman E, Brown K, Grotberg J, Cook KE, Bartlett RH, Hirschl RB, Mychaliska GB (2009) Development of an artificial placenta I: pumpless arteriovenous extracorporeal life support in a neonatal sheep model. *J Pediatr Surg* 44(1):53–59
197. Kading JC, Langley MW, Lautner G, Jeakle MMP, Toomasian JM, Fegan TL, Pfannes RA, Toor SC, Reiber MA, Kordell PR, Cornell MS, Bartlett RH, Rojas-Pena A, Mychaliska GB (2020) Tidal flow perfusion for the artificial placenta: a paradigm shift. *ASAIO J* 66(7):796–802
198. Liu T, Liu S, Zhang K, Chen J, Huang N (2014) Endothelialization of implanted cardiovascular biomaterial surfaces: the development from in vitro to in vivo. *J Biomed Mater Res - Part A* 102(10):3754–3772
199. Lavery KS, Rhodes C, McGraw A, Eppihimer MJ (2017) Anti-thrombotic technologies for medical devices. *Adv Drug Deliv Rev* 112:2–11
200. Goh ET, Wong E, Farhatnia Y, Tan A, Seifalian AM (2015) Accelerating in situ endothelialisation of cardiovascular bypass grafts. *Int J Mol Sci* 16(1):597–627
201. Pang JH, Farhatnia Y, Godarzi F, Tan A, Rajadas J, Cousins BG, Seifalian AM (2015) In situ endothelialization: bioengineering considerations to translation. *Small* 11(47):6248–6264
202. Maul TM, Nelson JS, Wearden PD (2018) Paracorporeal lung devices: thinking outside the box. *Front Pediatr* 6(September):1–13

**Publisher's note** Springer Nature remains neutral with regard to jurisdictional claims in published maps and institutional affiliations.