



Evaluation of a smartphone-based electrocardiogram device accuracy in field and in hospital conditions in horses

Elena Alberti ,¹ Luca Stucchi,¹ Valeria Pesce,² Giovanni Stancari,¹ Elisabetta Ferro,¹ Francesco Ferrucci,¹ Enrica Zucca¹

To cite: Alberti E, Stucchi L, Pesce V, *et al.* Evaluation of a smartphone-based electrocardiogram device accuracy in field and in hospital conditions in horses. *Veterinary Record Open* 2020;**7**:e000441. doi:10.1136/vetreco-2020-000441

Received 12 August 2020
Revised 20 October 2020
Accepted 12 November 2020

ABSTRACT

Background Due to compactness and cheapness, smartphone ECG (sECG) could be very useful to equine practitioners. However, previous studies have evaluated the accuracy of sECG in hospitalised horses only. Different conditions in the field could influence the accuracy of the device. The aim of this study is to compare the accuracy of sECG in field and in hospital conditions.

Methods This is a prospective study. Paired standard base-apex ECG (stECG) and sECG were recorded in hospitalised horses and in subjects examined in field conditions. ECGs were analysed for heart rate and rhythm, presence/type of arrhythmias, presence/duration of artefacts, electrocardiographic waves and interval parameters by a blinded clinician. Statistical analysis evaluated the agreement between stECG and sECG and the differences in the prevalence of artefact in field and hospital conditions.

Results Nineteen (hospital) and 40 (field) paired ECGs were analysed. Agreement between stECG and sECG was found for heart rate and rhythm, evaluation of atrioventricular block and premature complexes, P wave and PQ interval duration, and QRS complex duration and polarity. No differences were found between artefacts recorded in hospital and in field conditions.

Conclusion sECG is a feasible tool for evaluation of rhythm in horses and is as accurate in field as in ambulatory conditions.

INTRODUCTION

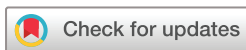Evaluation of heart rhythm is a relevant aspect of physical examination of the cardiovascular system. Electrocardiography is the gold standard for diagnosis of cardiac arrhythmias. In equine species, the standard method consists of performing a base-apex lead using a bipolar electrode coupled with a diagnostic electrocardiograph.^{1 2} However, standard ECG is quite cumbersome, requires the use of cables, and in some cases requires connection with power supply which is not always available in field conditions.

In recent years, a new relatively inexpensive technology capable of recording ECG tracing

through a smartphone has been developed. This technology consists of a small, practical and handy device that incorporates two electrodes that can easily generate a single-lead ECG directly on the smartphone. In 2012, this device was approved by the Food and Drug Administration for use in people.³ Several studies were conducted to evaluate the accuracy and the use of smartphone devices for different purposes in human medicine.⁴ In veterinary medicine, different authors performed comparative studies between smartphone ECG (sECG) and standard ECG to evaluate the accuracy of new devices in healthy water buffalo calves,⁵ dairy cows⁶ and horses,⁴ and in dogs and cats with arrhythmias.^{7 8} A study evaluated the feasibility of heart rate and rhythm home monitoring with an sECG device in healthy and cardiopathic dogs.⁹ Moreover, the device was used to detect pretrace and postrace heart rate and rhythm in Thoroughbred horses that received furosemide¹⁰ and as a rapid screening for cardiac arrhythmias in draft horse' competition.¹¹ Another study evaluated the use of smartphone device to obtain ECG data in seven horses while they were standing, walking and trotting.¹² Recently, a comparative study between a smartphone device and a standard base-apex ECG (stECG) in 24 horses with sinus rhythm and arrhythmias referred to a hospital has been published.¹³

Due to compactness and cheapness, these devices may be very useful to equine practitioners for rapid diagnosis of arrhythmias and evaluation of heart rate and rhythm during field anaesthesia, and may be applicable to veterinary controls during competitions.

However, the comparative studies evaluated the accuracy of smartphone devices in horses in hospital conditions.^{4 13} In the present study it was hypothesised that the different



© British Veterinary Association 2020. Re-use permitted under CC BY-NC. No commercial re-use. Published by BMJ.

¹Dipartimento di Medicina Veterinaria, Università degli Studi di Milano, Lodi, Italy

²Veterinary practitioner, Genova, Italy

Correspondence to

Dr Enrica Zucca; enrica.zucca@unimi.it

environment and working conditions in the field (ie, possible interferences, less restraint of the horse, etc), as well as the small dipole created by the proximity of the electrodes in the smartphone device, could make the assessment of arrhythmias more difficult.

The purposes of this study are to evaluate the accuracy of an sECG to monitor heart rhythm in horses examined in the field and in those referred to the hospital, and to compare parameters of accuracy obtained using the device in field and in hospital conditions.

MATERIALS AND METHODS

Animals

This research was a prospective study performed on a convenience sample of equine patients admitted to the Equine Internal Medicine Unit of the University of Milan and horses examined at their stables in Northern Italy between May and August 2019. An informed client consent was signed by the owners, and the highest standard (best practice) of veterinary care was guaranteed.

Paired ECGs were recorded and archived for subsequent analysis. Demographic data (age, sex and breed) and bodyweight were recorded. Moreover, the body condition score (BCS) was noted, according to the classification in nine degrees described by Kronfeld.¹⁴

ECG acquisition

An sECG and an stECG were recorded simultaneously for 30 seconds in non-sedated horses in standing position at rest. The smartphone device AliveCor Veterinary Heart Monitor (AliveCor, San Francisco, California, USA) was positioned on the left chest wall, just caudal to the olecranon (precordial area), with a slightly dorsocranial-ventrocaudal orientation (figure 1). The negative electrode (on the microphone side of the smartphone) was positioned dorsocranially and the positive electrode (on the camera side of the smartphone) was positioned caudoventrally to create a similar axis as the standard base-apex lead where a negative QRS complex is obtained. The area of application of the device was moistened with alcohol in order to improve contact with electrodes and obtain good-quality tracing. The hair was clipped, when needed, in longhaired horses to improve contact.

sECGs were recorded with iPhone SE, iPhone 6S and iPhone 7 (Apple, Cupertino, California, USA) at 25 mm/s with a gain of 20 mm/mV, after the application of automatic filters. sECGs were automatically digitised by the device and then sent via email as a PDF. Stored sECGs were subsequently analysed on a laptop.

stECG (in field: Carewell ECG-1101, Shenzhen Carewell Electronics, China; in hospital: Delta Vis 3 channels, Cardioline, Trento, Italy) was performed using a modified base-apex lead configuration. Electrodes were applied to the skin using alligator clips. The negative electrode was placed in the distal third of the right jugular groove near the thoracic inlet, and the positive electrode was attached




Figure 1 Positioning of the smartphone ECG device.

at the cardiac apex, on the left precordium. The ground electrode was positioned at any site remote from the heart. In order to maintain electrical contact, alcohol was rubbed on the skin. stECGs were printed on graph paper at 25 mm/s with a gain of 10 mm/mV.

ECG analysis

All paired ECGs were analysed by a blinded experienced clinician. After analysis, ECG tracings were divided into two groups for comparison of results: paired ECG recorded at the hospital (group 1) and paired ECG recorded in the field (group 2).

An initial evaluation of all ECGs was performed in order to exclude from the comparative study those in which P waves or QRS complexes were not identifiable in more than 20 per cent of the whole tracing due to the presence of artefacts. Only paired ECGs considered acceptable were analysed. For each stECG and sECG, the following variables were noted: heart rate calculated manually (HR_m); heart rate calculated automatically by the app (HR_{app}); P wave duration, amplitude and polarity; PQ interval duration; QRS complex duration, amplitude and polarity; presence and type of arrhythmias; and presence and duration of major and minor artefacts. The number of QRS complexes was counted over 30 seconds and multiplied by 2 to obtain the HR_m . The HR_{app} was calculated by the AliveCor software using an R wave autodetection algorithm. Heart rate was classified in bradycardia (heart rate <28 beats per minute (bpm)), normal (28 bpm ≤ heart rate ≤44 bpm) and tachycardia (heart rate >44 bpm).¹⁵ Each wave or interval duration and amplitude was calculated as the mean of three randomly selected heart beats. The rhythm was classified

as sinus, supraventricular or ventricular rhythm. Supraventricular rhythm included arrhythmias that originate from the sinus node, atria, atrioventricular (AV) node or junctional tissues, while ventricular rhythm included arrhythmias that originate from the ventricles.^{16,17} First-degree AV block was defined as a prolonged PR interval (>0.44 seconds).¹⁸ Second-degree AV block was diagnosed as P wave, not followed by a QRS complex, with double the length of the RR interval.^{15,17} A supraventricular premature complex was identified as premature complex with shorter RR interval, decreased more than 20 per cent in distance from the previous RR interval.¹⁹ In addition, the supraventricular premature complex was characterised by the presence of a QRS complex of normal morphology and was followed by a non-compensatory pause. The P wave could be buried in the preceding T wave, and the T wave of the premature complex could show opposite polarity to the QRS complex.¹⁷ Ventricular premature complex was defined as a premature QRS and T complex with a configuration that differed from that of the normal sinus QRS and T complex. Most commonly, ventricular premature complexes are followed by a compensatory pause.^{17,19} Atrial fibrillation was characterised by irregular RR intervals, absence of P waves and presence of f waves.^{17,19}

Major artefact was defined as ECG segment in which P waves and/or QRS complexes could not be identified due to the presence of sudden abnormal movements of the baseline, while minor artefact was defined as a slight baseline disturbance that did not compromise the identification of electrocardiographic waves.

Statistical analyses

Statistical analyses were performed separately for the two groups (group 1 and group 2). Data distribution was tested for normality using Shapiro-Wilk test. Cohen's k test was used to calculate the agreement between sECG and stECG for heart rate classification, heart rhythm, polarity of P wave and QRS complex. According to the k coefficient, the agreement between the two methods was classified as follows: values ≤ 0.20 as no agreement, 0.21–0.40 as fair, 0.41–0.60 as moderate, 0.61–0.80 as good, 0.81–0.99 as very good, and 1 as perfect agreement. If the contingency table shows one or more values equal to zero, the k coefficient could not be calculated and therefore the percentage of agreement will be used. In order to analyse the differences between sECG and stECG, bias and 95 per cent limits of agreement for HR_m , duration of the P wave, PQ interval and QRS complex, and amplitude of P wave and QRS complex were calculated using the Bland-Altman test. Moreover, bias and 95 per cent limits of agreement were calculated to analyse the difference between HR_m and HR_{app} . Using Fisher's exact test, differences in the prevalence of major and minor artefacts on the two ECG tracings were evaluated. Furthermore, to verify the hypothesis that the presence of major and minor artefacts could be due to different BCS, Mann-Whitney test was performed.

Finally, according to the hypothesis that possible differences in the prevalence of minor and major artefacts could be due to different recording conditions (in field versus in hospital), Fisher's exact test was applied to group 1 and group 2 sECG tracings.

Cohen's kappa test was performed using a commercial software (Microsoft Excel V.2016), while the Bland-Altman test, Fisher's exact test and Mann-Whitney test were performed using a statistical analysis software (GraphPad Prism V.8). Statistical significance was set at $P < 0.05$.

RESULTS

Animals

Paired ECGs were recorded in 19 horses admitted to the Veterinary Hospital of the University of Milan (group 1) and in 44 subjects examined at their stables in Northern Italy (group 2). According to the exclusion criteria, four of the 44 paired ECGs recorded in the field were excluded from the study due to the presence of major artefacts in more than 20 per cent of the sECG tracing; all the paired ECGs recorded in hospital were included in the study.

Therefore, group 1 consisted of 19 horses and group 2 consisted of 40 horses. Among 19 horses of group 1, seven (36.8 per cent) were geldings, seven were mares (36.8 per cent) and five (26.4 per cent) were males. The mean age was 11 ± 7 years old (range 2–28 years old). The bodyweight ranged between 346 kg and 601 kg (mean value 486 ± 70 kg). The majority of the subjects had a BCS of 5 and 6 (seven subjects and five subjects, respectively).

In the 40 subjects of group 2, 23 (57.5 per cent) were geldings, 16 (40.0 per cent) were mares and one (2.5 per cent) was male. The mean age was 16 ± 7 years old (range 5–34 years old). The bodyweight ranged between 195 kg and 560 kg (mean value 406 ± 79 kg). The majority of the subjects had a BCS of 5 and 6 (10 subjects and 13 subjects, respectively).

ECG analysis

Group 1

In group 1, the HR_m in both ECGs ranged between 24 bpm and 64 bpm (median 32 bpm; interquartile range (IQR) 11 bpm). The HR_{app} ranged between 31 bpm and 159 bpm (mean 84 ± 34 bpm). According to heart rate classification, 12 out of 19 (63.2 per cent) horses had normal HR_m , four (21.0 per cent) had bradycardia and three (15.8 per cent) had tachycardia.

Eleven horses (57.9 per cent) had sinus rhythm, eight (42.1 per cent) had supraventricular arrhythmia while no horse had ventricular arrhythmia. Among horses with supraventricular arrhythmia, one or more types of AV block were detected in seven horses (36.8 per cent); in particular, first-degree AV block was detected in one horse, while second-degree AV block was present in seven horses. One horse had also supraventricular premature complexes. Finally, one horse had atrial fibrillation (figure 2).

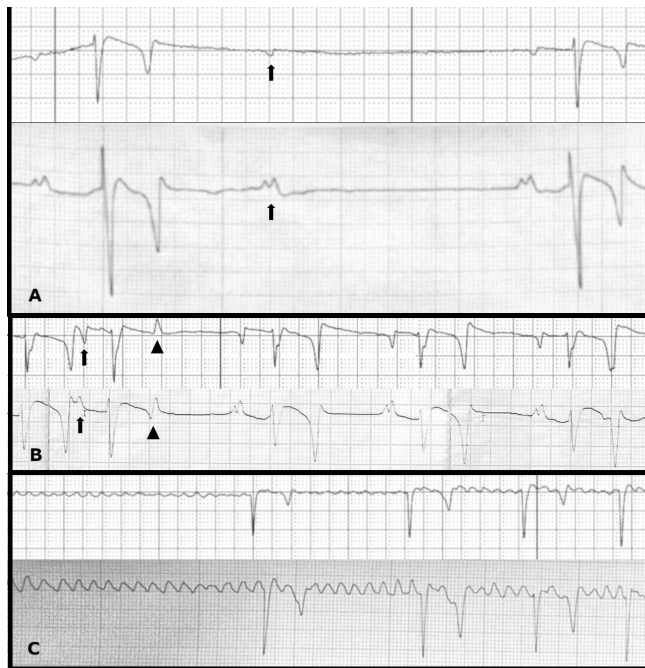

Figure 2 Smartphone ECG (above) and standard ECG (below) tracings recorded simultaneously in horses of both groups. Heart rate and rhythm are the same on both tracings of each panel where the ECG pairs have been lined up to match exact time points. (a) Second-degree atrioventricular block. Notice the single P wave (arrow), not followed by a QRS and T wave. Moreover, a different appearance of the P waves is visible on the standard ECG tracing. (b) Supraventricular premature complex. Notice the premature P wave (arrow) followed by a QRS complex of normal morphology and a T wave of opposite polarity to the QRS complex (arrowhead). (c) Atrial fibrillation. Notice the absence of P waves and the presence of f waves, associated with irregularity of the RR intervals.

On stECG, the P wave was positive in 17 cases (89.5 per cent) and biphasic in one case. On sECG, the P wave was biphasic in 18 cases (94.7 per cent). In one case, the P wave was absent due to the presence of atrial fibrillation. On both ECGs, the QRS complex was negative in all cases. The ECG measurements are reported in [table 1](#).

Major artefacts were recorded in five out of 19 (26.3 per cent) of both stECG and sECG. The mean duration of major artefacts was 2.08 ± 1.08 seconds (range 0.8–3.4 seconds) on stECG and 0.64 ± 0.33 seconds (range 0.2–1 seconds) on sECG. Minor artefacts were noted in four out of 19 (21.0 per cent) stECGs and in 14 out of 19 (73.6 per cent) sECGs. The mean duration of minor artefacts was 0.95 ± 0.34 seconds (range 0.4–1.4 seconds) on stECG and 8.66 ± 9.78 seconds (range 1.0–30.0 seconds) on sECG.

Group 2

In group 2, the manually calculated heart rate ranged between 20 bpm and 58 bpm (mean 36 ± 9 bpm) on both ECG tracings. The HR_{app} ranged between 33 bpm and 115 bpm (median 67 bpm; IQR 48.25 bpm). According to heart rate classification, 29 out of 40 (72.5 per cent)

subjects had normal HR_m , six (15.0 per cent) had bradycardia and five (12.5 per cent) had tachycardia.

Twenty-six subjects (65.0 per cent) had sinus rhythm and 14 (35.0 per cent) had supraventricular arrhythmia; ventricular arrhythmias were not detected. Among supraventricular arrhythmias, one or more types of AV block were detected in 12 horses (28.6 per cent); in particular, first-degree AV block was observed in a horse (2.4 per cent), while second-degree AV block was present in 12 horses (28.6 per cent). Two horses (4.8 per cent) had supraventricular premature complexes and one horse had atrial fibrillation ([figure 2](#)).

On stECG, the P wave was positive in 38 cases (95.0 per cent) and biphasic in one case. On sECG, the P wave was biphasic in 39 cases (97.5 per cent). In one case, the P wave was absent due to the presence of atrial fibrillation. On both ECG tracings, the QRS complex was negative in all patients. ECG measurements are reported in [table 1](#).

Major artefacts were recorded in one out of 40 (2.5 per cent) stECGs and in 12 (30.0 per cent) sECGs. On the only stECG with major artefacts, the duration was 0.56 seconds. The mean duration of major artefacts on sECG was 1.34 ± 1.07 seconds (range 0.4–3.4 seconds). Minor artefacts were noted in seven out of 40 (17.5 per cent) stECGs and in 26 (65.0 per cent) sECGs. The mean duration of minor artefacts was 3.57 ± 6.20 seconds (range 0.4–17.4 seconds) on stECG and 15.72 ± 12.61 seconds (range 1.0–30.0 seconds) on sECG.

Statistical analysis

For both group 1 and group 2, a perfect agreement ($k=1$) between stECG and sECG was found in the classification of HR_m and rhythm, as well as in the evaluation of AV block, premature complexes and atrial fibrillation. Moreover, the percentage of agreement between stECG and sECG for QRS complex polarity was 100 per cent. Conversely, no agreement (group 1 $k=0.055$; group 2 $k=0.024$) was found in the evaluation of P wave polarity.

HR_m on stECG and sECG recorded at the Veterinary Hospital showed a bias of -0.105 bpm (95 per cent confidence interval (CI): -1.005 to 0.794 bpm). Bias between HR_m and HR_{app} of sECG was -49.21 bpm (95 per cent CI: -115.6 to 17.2 bpm). Duration and amplitude of P wave measured on stECG and sECG had a bias of 0.00556 seconds (95 per cent CI: -0.0125 to 0.02362 seconds) and 0.1444 mV (95 per cent CI: -0.0483 to 0.3372 mV), respectively. Bias between PQ interval duration measured on stECG and sECG was 0.00556 seconds (95 per cent CI: 0.0207 to 0.03178 seconds). Duration and amplitude of the QRS complex measured on stECG and sECG showed a bias of 0.15×10^{-17} seconds (95 per cent CI: -0.01307 to 0.01307 seconds) and 1.318 mV (95 per cent CI: 0.458 to 2.179 mV), respectively.

Moreover, in group 1, the prevalence of minor artefacts ($P=0.0029$) was significantly higher on sECG tracings than on stECG tracings. No differences were found in the prevalence of major artefacts ($P>0.999$).

Table 1 ECG measurements data

	Group 1				Group 2			
	Median	IQR	Min	Max	Median	IQR	Min	Max
P wave duration (seconds)								
stECG	0.12	0	0.12	0.16	0.12	0	0.10	0.16
sECG	0.12	0	0.10	0.16	0.12	0.01	0.10	0.14
P wave amplitude (mV)								
stECG	0.30	0.20	0.10	0.50	0.30	0.10	0.20	0.50
sECG	0.15	0.10	0.05	0.30	0.10	0.05	0.05	0.20
PQ interval duration (seconds)								
stECG	0.32	0.07	0.24	0.44	0.30	0.04	0.20	0.44
sECG	0.32	0.075	0.24	0.44	0.28	0.04	0.20	0.44
QRS complex duration (seconds)								
stECG	0.12	0.04	0.08	0.12	0.08	0.02	0.08	0.12
sECG	0.10	0.04	0.08	0.14	0.08	0.02	0.08	0.12
QRS complex amplitude (mV)								
stECG	2.0	0.70	1.10	3.0	1.85	0.625	1.10	2.90
sECG	0.7	0.375	0.20	1.40	0.425	0.262	0.15	1.10

Group 1: 19 hospitalised horses; group 2: 40 horses examined in the field.

IQR, interquartile range; max, maximum value; min, minimum value; sECG, smartphone ECG; stECG, standard base-apex ECG.

No differences in BCS were found between sECG tracing with major ($P=0.5806$) and minor ($P=0.2423$) artefacts and tracings without artefacts.

HR_m on stECG and sECG recorded in the field showed a bias of 0 bpm. Bias between HR_m and HR_{app} of the sECG was -34.6 bpm (95 per cent CI: -88.06 to 18.86 bpm). Duration and amplitude of P wave measured on stECG and sECG had a bias of 0.005128 seconds (95 per cent CI: -0.01441 to 0.02466 seconds) and 0.2333 mV (95 per cent CI: 0.07225 to 0.3944 mV), respectively. Bias between PQ interval duration measured on stECG and sECG was 0.00359 seconds (95 per cent CI: -0.01411 to 0.02129 seconds). Duration and amplitude of the QRS complex measured on stECG and sECG showed a bias of 0.001 seconds (95 per cent CI: -0.007652 to 0.009652 seconds) and 1.486 mV (95 per cent CI: 0.6775 to 2.295 mV), respectively.

Moreover, in group 2 the prevalence of major ($P=0.0015$) and minor ($P<0.0001$) artefacts was significantly higher on sECG tracings than on stECG tracings.

No differences in BCS were found between sECG tracing with major ($P=0.7802$) and minor ($P=0.8800$) artefacts and tracings without artefacts.

With regard to the prevalence of major and minor artefacts, the comparison between group 1 and group 2 showed no significant differences ($P>0.9999$ and $P=0.5577$, respectively).

Conditions causing bad recordings

On two occasions, it was not possible to record the sECG tracing; the first episode occurred during a storm, while the second episode occurred during winter, in particular cold conditions.

DISCUSSION

The results obtained from the present research are in accordance with previous studies and confirm that AliveCor Vet is a feasible and reasonably accurate method to rapidly evaluate heart rate and rhythm in horses. In fact, a perfect agreement between sECG and stECG in the evaluation of heart rate, sinus rhythm and supraventricular arrhythmias was detected.

As previously described,^{4 6 7 13} the results verified that heart rate obtained automatically by the app is not accurate. The HR_{app} is calculated by an R wave autodetection algorithm and RR interval measurement and the mean value is based on the duration of the recording.¹³ Kraus and colleagues¹³ reported that the misleading HR_{app} is due to 'over sensing' of artefacts or to missing QRS complexes. In the authors' experience, P and T waves could also be erroneously identified as an R wave, with HR_{app} overestimation (figure 3). For these reasons, it would be better to check the autodetection of R waves on the PDF, observing the mark under each wave identified as R, or calculate the heart rate manually.

The results demonstrated the accuracy of the AliveCor Veterinary Heart Monitor in the analysis of the ECG wave and interval duration and in the evaluation of the polarity of QRS complex. In fact, differences in these parameters between sECG and stECG were minimal both in group 1 and in group 2. These results are consistent with previous studies on horses, dogs and dairy cows.^{4 6 7} Conversely, no agreement between the two ECG methods was found in the evaluation of P wave polarity, as previously reported in horses and cows.^{4 6} Moreover, the results showed that the sECG underestimated the amplitude of the P wave

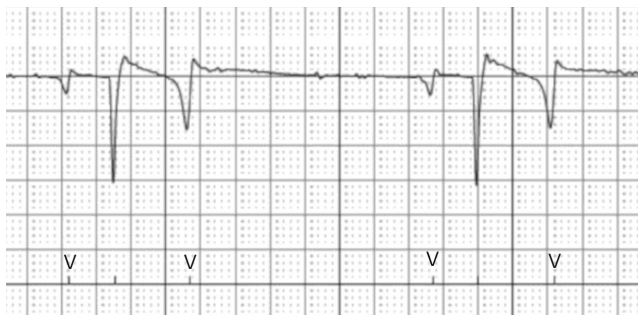

Figure 3 A smartphone ECG tracing in which the P and T waves were recognised as R waves by the autodetection algorithm. Arrowheads indicate the wrong marks.

and QRS complex. Similar results are described in dogs,⁷ whereas, to the authors' knowledge, no previous studies have been carried out on the evaluation of wave amplitude in horses. The differences in amplitude between sECG and stECG could be due to the different placement of the electrodes. In fact, the proximity of the two electrodes of the smartphone device creates a small dipole compared with stECG and this can result in a lower voltage of ECG waves and in a variation in polarity of P wave. A similar hypothesis has been suggested by Kraus and colleagues, who however did not compare P and QRS amplitudes in their study.¹³

In the present study, four of the sECGs were excluded from the analysis due to the presence of major artefacts in more than 20 per cent of the tracing. Therefore, sECGs were interpretable in 59 out of 63 cases (94 per cent). These results agree with findings in people where a percentage of useful sECG of 87–99.6 per cent was reported,^{3 20–22} and in healthy horses with 96 per cent of diagnostic sECG.⁴ Based on the comparison between methods, artefacts were significantly higher on sECG than on stECG tracings; however, minor artefacts were negligible as they appeared as fine tremors of the baseline that did not preclude correct identification of ECG waves. Minor and major artefacts resulted to be independent of BCS both on tracings recorded in field and in hospital conditions. Major artefacts could be due to bad contact with the electrodes, interferences or movements of the patient. In order to minimise artefacts, it could be useful to set the highest filter (60 Hz) available in the app settings, and whenever possible recognise and eliminate possible causes of interference as well as improve contact between the electrodes and the patient.

When parameters of accuracy obtained using the device in field and in hospital conditions were compared, results were judged similar. Moreover, no significant differences were detected between artefacts recorded in hospital and in the field. These results indicate that AliveCor Veterinary Heart Monitor is a reliable diagnostic tool for veterinary practitioners in field as well as in hospital conditions.

According to the authors' experience on the usage of AliveCor in field conditions, only exceptional atmospheric conditions may prevent sECG recording. The first episode occurred in a stable during a storm. At the

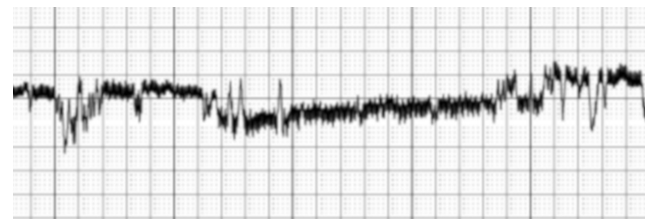


Figure 4 A smartphone ECG tracing with major artefacts during a storm.

beginning, the sECG recorded major artefacts (figure 4) and then a message 'electromagnetic interference too high' appeared on the smartphone screen and the tracing was interrupted; meanwhile, a good-quality stECG tracing was recorded. Therefore, electromagnetic fields generated during storms appeared to interfere with the smartphone functioning.

The second episode happened in a stable located at about 1000 m altitude during winter. In a sunny but cold day (about 4°C), it was not possible to record the sECG tracing. The reason is explained in the user manual, which certifies a correct temperature range of +10°C to +40°C for device usage.

Possible limitations of this study are the different numbers included in the two groups and the absence of ventricular arrhythmias.

In conclusion, AliveCor Veterinary Heart Monitor seems to be a practical, useful and feasible additional tool for electrocardiographic evaluation of horses. The results obtained during its use in field conditions demonstrated that AliveCor is a diagnostic instrument as accurate as in hospital conditions.

Contributors EA, VP and EZ contributed to the conception of the work, and acquisition and interpretation of data. LS contributed to the analysis of data. EA, LS, VP, GS, EF, FF and EZ contributed to drafting the work and revising it critically for important intellectual content. All authors approved the final version of the manuscript and agree to be accountable for all aspects of the work in ensuring that questions related to the accuracy or integrity of any part of the work are appropriately investigated and resolved.

Funding The research was performed with an AliveCor Veterinary Heart Monitor provided to the Department of Health, Animal Science and Food Safety of the Università degli Studi di Milano on loan to use agreement by Vétuquinol Italia, Bertinoro, Italy (agreement signed 01.15.2019).

Competing interests None declared.

Ethics approval Client-owned animals were used in the study. The research protocol was approved by the Institutional Animal Care and Use Committee of the University of Milan (OPBA_25_2019).

Provenance and peer review Not commissioned; externally peer reviewed.

Data availability statement Data sharing not applicable as no datasets generated and/or analysed for this study. All data relevant to the study are included in the article or uploaded as supplementary information.

Open access This is an open access article distributed in accordance with the Creative Commons Attribution Non Commercial (CC BY-NC 4.0) license, which permits others to distribute, remix, adapt, build upon this work non-commercially, and license their derivative works on different terms, provided the original work is properly cited, an indication of whether changes were made, and the use is non-commercial. See: <http://creativecommons.org/licenses/by-nc/4.0/>.

ORCID iD

Elena Alberti <http://orcid.org/0000-0001-7819-6267>

REFERENCES

- 1 Bowen MI. Ambulatory electrocardiography and heart rate variability. In: Marr CM, Bowen MI, eds. *Cardiology of the horse*. 2nd edn. London: Saunders Elsevier, 2010: 127–37.
- 2 Patteson M. Diagnostic aids in equine cardiology. In: Patteson M, ed. *Equine cardiology*. Oxford: Blackwell Science, 1996: 70–115.
- 3 Saxon LA. Ubiquitous wireless ECG recording: a powerful tool physicians should embrace. *J Cardiovasc Electrophysiol* 2013;24:480–3.
- 4 Vezzosi T, Sgorbini M, Bonelli F, et al. Evaluation of a smartphone electrocardiograph in healthy horses: comparison with standard base-apex electrocardiography. *J Equine Vet Sci* 2018;67:61–5.
- 5 Smith J, Ward J, Urbano T, et al. Use of AliveCor heart monitor for heart rate and rhythm evaluation in dairy water buffalo calves (*bubalis bubalis*). *JDVAR* 2016;4:2–5.
- 6 Bonelli F, Vezzosi T, Meylan M, et al. Comparison of smartphone-based and standard base-apex electrocardiography in healthy dairy cows. *J Vet Intern Med* 2019;33:981–6.
- 7 Vezzosi T, Buralli C, Marchesotti F, et al. Diagnostic accuracy of a smartphone electrocardiograph in dogs: comparison with standard 6-lead electrocardiography. *Vet J* 2016;216:33–7.
- 8 Kraus MS, Gelzer AR, Rishniw M. Detection of heart rate and rhythm with a smartphone-based electrocardiograph versus a reference standard electrocardiograph in dogs and cats. *J Am Vet Med Assoc* 2016;249:189–94.
- 9 Vezzosi T, Tognetti R, Buralli C, et al. Home monitoring of heart rate and heart rhythm with a smartphone-based ECG in dogs. *Vet Rec* 2019;184:96.
- 10 Gunther-Harrington CT, Arthur R, Estell K, et al. Prospective pre- and post-race evaluation of biochemical, electrophysiologic, and echocardiographic indices in 30 racing thoroughbred horses that received furosemide. *BMC Vet Res* 2018;14:1–10.
- 11 Gallant LR, Jacob SI, Tadros EM, et al. Rapid screening for cardiac arrhythmias in competition draft horses. *Comparative Exercise Physiology* 2019;15:291–8.
- 12 Brložnik M, Petric AD, Kos VK, et al. Wireless body sensor for electrocardiographic monitoring in equine medicine. In: *Proceedings of the 42nd International Convention on Information and Communication Technology, Electronics and Microelectronics (MIPRO); 20-24 May 2019*. Opatija, Croatia, 2019: 279–83.
- 13 Kraus MS, Rishniw M, Divers TJ, et al. Utility and accuracy of a smartphone-based electrocardiogram device as compared to a standard base-apex electrocardiogram in the horse. *Res Vet Sci* 2019;125:141–7.
- 14 Kronfeld DS. Clinical assessment of nutritional status of the horse. In: Watson TD, ed. *Metabolic and endocrine problems of the horse*. London: Saunders, 1998: 84–217.
- 15 Reef VB, Marr CM. Dysrhythmias: assessment and medical management. In: Marr CM, Bowen MI, eds. *Cardiology of the horse*. 2nd edn. Edinburgh: Saunders Elsevier, 2010: 159–78.
- 16 Patteson M. Cardiac arrhythmias. In: Patteson M, ed. *Equine cardiology*. 2nd edn. Iowa State: Blackwell Science, 1996: 172–205.
- 17 van Loon G. Cardiac arrhythmias in horses. *Vet Clin North Am Equine Pract* 2019;35:85–102.
- 18 Verheyen T, Decloedt A, De Clercq D, et al. Electrocardiography in horses – Part 2: how to read the equine ECG. *Vlaams Diergeneeskundig Tijdschrift* 2010;79:337–44.
- 19 Buhl R, Petersen EE, Lindholm M, et al. Cardiac arrhythmias in Standardbreds during and after racing – possible association between heart size, valvular regurgitations, and arrhythmias. *J Equine Vet Sci* 2013;33:590–6.
- 20 Nguyen HH, Van Hare GF, Rudokas M, et al. Spear trial: smartphone pediatric electrocardiogram trial. *PLoS One* 2015;10:1–9.
- 21 Tarakji KG, Wazni OM, Callahan T, et al. Using a novel wireless system for monitoring patients after the atrial fibrillation ablation procedure: the iTransmit study. *Heart Rhythm* 2015;12:554–9.
- 22 Chan N-Y, Choy C-C. Screening for atrial fibrillation in 13 122 Hong Kong citizens with smartphone electrocardiogram. *Heart* 2017;103:24–31.