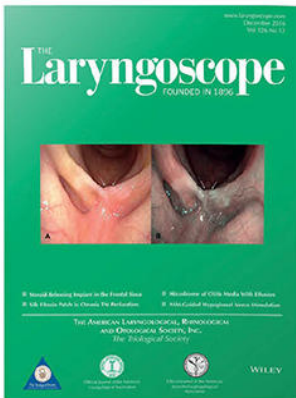



Premiere Publications from The Triological Society

Read all three of our prestigious publications, each offering high-quality content to keep you informed with the latest developments in the field.




THE Laryngoscope FOUNDED IN 1896

Editor-in-Chief: Samuel H. Selesnick, MD, FACS

The leading source for information in head and neck disorders.

Laryngoscope.com




Laryngoscope Investigative Otolaryngology

Open Access

Editor-in-Chief: D. Bradley Welling, MD, PhD, FACS

Rapid dissemination of the science and practice of otolaryngology-head and neck surgery.

InvestigativeOto.com



ENTtoday


A publication of the Triological Society

Editor-in-Chief: Alexander Chiu, MD

Must-have timely information that Otolaryngologist-head and neck surgeons can use in daily practice.

Enttoday.org

WILEY



Minimizing Contagion Risks of COVID-19 During Transoral Robotic Surgery

Giuseppe Meccariello MD ; Giovanni Cammaroto MD, PhD; Giannicola Iannella MD, PhD;
Pasquale Capaccio MD ; Stefano Pelucchi MD; Claudio Vicini MD

In this communication, we would like to share our experience in managing TORS patients during COVID-19 pandemic.

Key Words: Transoral robotic surgery, oropharyngeal, pandemic, tumour.

Laryngoscope, 130:2593–2594, 2020

A general consensus exists on the high risks of contagion by severe acute respiratory syndrome coronavirus 2 during otolaryngology procedures that may determine an aerosolization with nosocomial amplification of infection.^{1–3} Even asymptomatic carriers have a potential role in spreading the disease.² For those reasons, the use of particular personal protective equipment (PPE) is mandatory to protect healthworkers, especially otolaryngologists.¹

Taking a look at the current Italian situation, elective hospital activities have been remodulated and reduced as much as possible to essential emergency and oncologic procedures according to worldwide experiences. The Italian Society of Otolaryngology recently developed a couple of recommendations to address the routine and emergent activities during the coronavirus disease 2019 (COVID-19) pandemic.⁴

Although those recommendations also reflect how much is being implemented in the world, many logistical and technical problems still exist in supplying hospitals with suitable materials and performing active infection surveillance by reverse transcription-polymerase chain reaction test.

In particular, testing eligible patients for surgery is still inconsistent and haphazard in Italy.

Given this situation, our departmental policies are to consider all patients as infected. Thus, both in- and out-patient activity is modulated to minimally reduce contagion risks.

From the Department of Head-Neck Surgery, Otolaryngology, Head-Neck and Oral Surgery Unit (G.M., G.C., G.I., C.V.), Morgagni Pierantoni Hospital, Forlì, Italy; Department of biochemical, surgical and Dental sciences (P.C.), University of Milan, Fondazione IRCCS Ca' Granda Ospedale Maggiore Policlinico, Milan, Italy; and the Unit of Otolaryngology, University of Ferrara (S.P., C.V.), Ferrara, Italy.

Editor's Note: This Manuscript was accepted for publication on May 18, 2020.

The authors have no funding, financial relationships, or conflicts of interest to disclose.

Send correspondence to Giuseppe Meccariello, Department of Head-Neck Surgery, Otolaryngology, Head-Neck and Oral Surgery Unit, Morgagni Pierantoni Hospital, via Carlo Forlanini 34, 47100 Forlì, Italy. E-mail: giuseppemec@yahoo.it

DOI: 10.1002/lary.28847

Regarding surgery, we deferred all elective procedures, limiting the number of operations to oncological cases, similarly to protocol of other Institutions.^{1,5,6} A part of our cancer surgery consists of transoral robotic surgery (TORS) of oropharyngeal carcinoma. TORS may be considered a high-impact procedure on involving aerosolization similar to any other transoral surgery, in accordance with the statement of the Confederation of European Otorhinolaryngology–Head & Neck Surgery.⁵

Although high-risk operations in patients with known or suspected COVID-19 should be performed in a designated operating room with negative pressure, this is not possible in our hospital due to technical problems. A nasotracheal intubation is preferred,^{7,8} although the nasopharynx and nasal cavity are known to harbor significant viral loads.^{9,10} For those reasons, the eligible patient for TORS is prepared and intubated in another room side to operating room. Here, the anesthesia team may freely work with adequate PPE and all necessary instruments. Before transferring the patient to the operating room, the patient's nose and mouth are wrapped with transparent plastic dressing. A gauze soaked with povidone-iodine solution might be positioned in the mouth.¹¹ Surgeons and staff nurses are scrubbed while wearing suitable PPE. The operation usually begins with a neck dissection. This policy may allow the possibility of ligating lingual and/or the carotid arteries with consequent reduction of postoperative bleeding risks and the need for tracheotomy, reducing the transoral resection time due to a bloodless field without a significant risk of fistula formation.^{7,12} Moreover, this strategy avoids a second hospital admission that could be an additional risk of contagion and inadmissible due to the shortage of hospital beds. Once neck dissection is over, the patient is positioned in sniffing position and wrapped with surgical drapes. Before starting the exposure, a sterile transparent plastic bag is positioned with one inner part behind the patient's head. Then, the transparent plastic dressing on the mouth will be removed. Based on our experience,^{7,8} we strongly suggest the use of a Davis-Meyer mouth gag with aspirating blade, especially during the COVID-19 pandemic. The aspirating blade permits the

reduction of aerosolization toward the assistant surgeon's face generated by monopolar robotic cautery. Once a fine exposure is achieved, the remaining part of the transparent plastic bag is unrolled to cover the whole face, including the mouth gag. Using scissors, one hole is cut in the plastic covering the central part of the mouth and an additional hole is cut in the plastic covering each labial commissure in order to introduce the scope (central hole) and robotic arms with instruments (labial commissure holes). Two additional holes, one per side, can be made alongside and lateral to the inferior teeth to insert Lawton suction devices. These instruments are useful to help the robotic resection and also to give an extra aspiration of the aerosol. In case of bleeding control, an extra hole alongside the superior teeth can be made for inserting a MicroFrance Dessi forceps. Once the transoral resection is over, the specimen can be retrieved from the mouth by making a linear cut on the plastic covering. Then, the robotic arms and scope can be removed, and a wide transparent plastic dressing is applied to cover all holes waiting for the frozen sections, as needed. In case of remargination, holes can be cut once again in the same fashion as previous described. In our brief experience, no breakages or weakening of the plastic bag was reported.

Similarly, David et al.¹³ proposed an innovative system. However, this smart system appears to be expensive, especially in countries where the supply of devices is limited.

In a scenario with a scarcity of PPE, appropriate preoperative tests, and cumbersome Italian procedures for the acquisition of devices and equipments, our tricks

inevitably represent the minimum set for reducing aerosolization during TORS.

BIBLIOGRAPHY

1. Vukkadala Neelaysh, Qian Z. Jason, Holsinger F. Christopher, Patel Zara M., Rosenthal Eben. COVID-19 and the Otolaryngologist: Preliminary Evidence-Based Review. *The Laryngoscope*. 2020. <http://dx.doi.org/10.1002/lary.28672>.
2. Zou L, Ruan F, Huang M, et al. SARS-CoV-2 viral load in upper respiratory specimens of infected patients. *N Engl J Med* 2020;382:1177–1179.
3. Chan JYK., Wong EWY, Lam W. Practical Aspects of Otolaryngologic Clinical Services During the 2019 Novel Coronavirus Epidemic. *JAMA Otolaryngology-Head & Neck Surgery*. 2020;146 (6):519. <http://dx.doi.org/10.1001/jamaoto.2020.0488>.
4. Società Italiana di Otorinolaringoiatria e Chirurgia Cervico Facciale. COVID-19. Available at: <https://www.sioechcf.it/news-covid-19/>
5. Confederation of European Otorhinolaryngology-Head and Neck Surgery (CEORL-HNS). CEORL-HNS Statement to COVID-19. Available at: <https://www.ceorlhns.org/covid-19>.
6. Safety Recommendations for Evaluation and Surgery of the Head and Neck During the COVID-19 Pandemic. *JAMA Otolaryngology-Head & Neck Surgery*. 2020;146 (6):579. <http://dx.doi.org/10.1001/jamaoto.2020.0780>.
7. Meccariello G, Montevecchi F, D'Agostino G, et al. Trans-oral robotic surgery for the management of oropharyngeal carcinomas: a 9-year institutional experience. *Acta Otorhinolaryngol Ital* 2019;39:75–83.
8. Meccariello G, Montevecchi F, Sgarzani R, et al. The reconstructive options for oropharyngeal defects in the transoral robotic surgery framework. *Oral Oncol* 2017;66:108–111.
9. Chan JYK. Procedural precautions and personal protective equipment during head and neck instrumentation in the COVID-19 era. *Authorea* 2020. <https://doi.org/10.22541/au.158802355.53307782>
10. Meccariello G, Gallo O. What ENT doctors should know about COVID-19 contagion risks. *Head Neck* 2020. <https://doi.org/10.1002/hed.26190>
11. Parhar HS, Tasche K, Brody RM, et al. Topical preparations to reduce SARS-CoV-2 aerosolization in head and neck mucosal surgery. *Head Neck* 2020. <https://doi.org/10.1002/hed.26200>
12. Kucur C, Durmus K, Gun R, et al. Safety and efficacy of concurrent neck dissection and transoral robotic surgery. *Head Neck* 2016;38:E519–E523.
13. David AP, Jiam NT, Reither JM, Gurrola JG 2nd, Aghi MK, El-Sayed IH. Endoscopic skull base and transoral surgery during COVID-19 pandemic: Minimizing droplet spread with negative-pressure otolaryngology viral isolation drape. *Head Neck*. 2020 Jul;42:1577–1582. <https://doi.org/10.1002/hed.26239>