

# Immediate versus delayed implant placement after anterior single tooth extraction: the timing randomized controlled clinical trial

Maurizio S. Tonetti<sup>1,2</sup>,  
Pierpaolo Cortellini<sup>1</sup>,  
Filippo Graziani<sup>1</sup>, Francesco Cairo<sup>1</sup>,  
Niklaus P. Lang<sup>1</sup>, Roberto Abundo<sup>1</sup>,  
Gian Paolo Conforti<sup>1</sup>,  
Siegfried Marquardt<sup>1</sup>,  
Giulio Rasperini<sup>1</sup>,  
Maurizio Silvestri<sup>1</sup>, Beat Walkkamm<sup>1</sup>  
and Anton Wetzel<sup>1</sup>

<sup>1</sup>European Research Group on Periodontology, Genova, Italy; <sup>2</sup>Department of Periodontology, Hong Kong University, Hong Kong SAR, China

Tonetti MS, Cortellini P, Graziani F, Cairo F, Lang NP, Abundo R, Conforti GP, Marquardt S, Rasperini G, Silvestri M, Walkkamm B, Wetzel A. Immediate versus delayed implant placement after anterior single tooth extraction: the timing randomized controlled clinical trial. *J Clin Periodontol* 2017; 44: 215–224. doi: 10.1111/jcpe.12666.

## Abstract

**Aim:** To compare need for bone augmentation, surgical complications, periodontal, radiographic, aesthetic and patient reported outcomes in subjects receiving implant placement at the time of extraction (Immediate Implant) or 12 weeks thereafter.

**Methods:** Subjects requiring single tooth extraction in the anterior and premolar areas were recruited in seven private practices. Implant position and choice of platform were restoratively driven. Measurements were performed by calibrated and masked examiners.

**Results:** IMI was unfeasible in 7.5% of cases. One hundred and 24 subjects were randomized. One implant was lost in the IMI group. IMI required bone augmentation in 72% of cases compared with 43.9% for delayed ( $p = 0.01$ ), while wound failure occurred in 26.1% and 5.3% of cases, respectively ( $p = 0.02$ ). At 1 year, IMI had deeper probing depths ( $4.1 \pm 1.2$  mm versus  $3.3 \pm 1.1$  mm,  $p < 0.01$ ). A trend for greater radiographic bone loss was observed at IMI over the initial 3-year period ( $p$ -trend  $< 0.01$ ). Inadequate pink aesthetic scores were obtained in 19% of delayed and in 42% of IMI implant cases ( $p = 0.03$ ). No differences in patient reported outcomes were observed.

**Conclusions:** Immediate implant placement should not be recommended when aesthetics are important, IMI should be limited to selected cases. Longer follow-up is needed to assess differences in complication rates.

Key words: bone augmentation; dental implants; human; randomized controlled clinical trial; tooth extraction

Accepted for publication 1 December 2016

Tooth extractions requiring prosthetic replacement represent a major indication for dental implant placement. Immediate installation at the time of extraction offers potential advantages for both practitioners and patients. It allows a decrease in treatment time and may result in an increase in patient satisfaction. Some

## Conflict of interest and source of funding statement

The authors have stated explicitly that there are no conflicts of interest in connection with this article.

This study was sponsored by the European Research Group on Periodontology (ERGOPero). The study was financially supported in part by an unrestricted grant from Thommen Medical AG, Switzerland. The employed regenerative materials were provided at no cost by Geistlich AG, Switzerland. This research was initiated by the investigators who independently performed all phases of the study including protocol development, experimental procedures, data analysis and reporting. An early report of this trial received the 2010 clinical research award of the European Association of Osseointegration.

clinicians have argued that immediate implant installation may prevent alveolar bone resorption and thus decrease the need for bone augmentation procedures. Others have questioned such benefits and highlighted that immediate implant placement at the time of tooth extraction is associated with an increase in surgical complications and may result in sub-optimal aesthetic outcomes.

Case series have documented good survival rates for immediately placed implants. A multicenter trial comparing two different implant designs immediately placed following tooth extraction reported survival rates in excess of 98% (Lang et al. 2007). The 2010 update of the Cochrane systematic review has located only four randomized controlled clinical trials dealing with issues associated with implant placement timing (Esposito et al. 2010), among these only two with a total of 126 subjects directly compared immediate and delayed implant placement. The review concluded that there is insufficient evidence to assess the advantages and disadvantages of these timing options. Furthermore, the authors highlighted that the two studies were at high risk of bias. More recently a systematic review and meta-analysis of a total of 46 prospective studies with a mean follow-up period of 2 years reported an annual failure rate ranging from 0.5% to 1.4% (Lang et al. 2012). This evidence on implant survival provides an important argument in favour of immediate placement. It should be noted that also in this systematic review, an assessment of the risk of bias revealed significant potential for bias, in particular for allocation concealment. Importantly, evidence comparing implant success in immediate and delayed implant placement is still emerging.

In the absence of clear evidence to guide clinicians in the sequence of procedures, consensus reports have reached conflicting conclusions.

When implants are immediately placed at the time of tooth extraction, major issues relate to the discrepancy between the walls of the alveolus and the implant. This discrepancy is considered to have negative implications in terms of initial implant stability, amount of

osseointegration, and soft and hard tissue support. Bone augmentation procedures are frequently performed together with immediate implant installation to reduce and address such discrepancies (Lang et al. 2007). Another, frequently neglected aspect, is that tooth extraction is the result of either an important trauma or a disease process. In many cases therefore tooth extraction is accompanied by severe loss of alveolar bone and the presence of significant microbial contamination of the area. The external applicability of the results of several studies, therefore, is limited by stringent inclusion/exclusion criteria that frequently do not represent all clinical conditions of teeth that need to be extracted. For example, several trials have focused on intact or essentially intact residual alveoli, a condition observed when teeth are extracted for unresorable caries or some endodontic reasons but not for severe periodontitis or vertical fractures (Sanz et al. 2014). Such trials, designed essentially to learn about the healing pattern of alveoli after tooth extraction and implant placement, report only on immediate implant placement at sites with almost intact alveoli severely limiting the external applicability to the broader population requiring tooth extraction and implant replacement in the presence of severe damage to the alveolus.

The objective of this multicenter, multinational randomised clinical trial (RCT) RCT was to compare immediate and delayed implant placement following tooth extraction in terms of need for bone augmentation, surgical complications, patient based outcomes, aesthetics and costs. This article reports the surgical and 1-year outcomes in terms of clinical, aesthetics and patient reported outcomes as well as an initial assessment of 3-year radiographic parameters. An additional article reporting on full 3-year outcomes, relationship of surgical complications and clinical, radiographic and aesthetic outcomes and economic evaluation is planned.

#### Material and Methods

This was a randomized, controlled, parallel arm, single blind, multi-centre, multinational, practice-based

study designed to compare the clinical, radiographic and patient reported outcomes of immediate and delayed root shaped trans-mucosal implants placed into extraction sockets of anterior and premolar teeth. SPI Contact (Thommen Medical AG, Waldenburg, Switzerland) tapered, screw shaped implants of different length and diameters were placed either immediately after extraction or after 12-week healing of the extraction socket. Based in pre-specified criteria, dimensional discrepancies between the extraction socket and the implant surface were filled with bone replacement graft (Bio-Oss Geistlich AG, Lucerne, Switzerland) and covered with a collagen membrane (Bio-Gide Geistlich AG, Lucerne, Switzerland). The same regenerative approach was utilized in the delayed implant placement group. The study was primarily reviewed and approved by the Bern national ethics committee (Approval number 68/2005). The competent local authorities also approved the study. All study procedures were performed in accordance with the principles of the Declaration of Helsinki. Treatment was rendered in seven dental offices by experienced clinicians in both immediate and delayed implant placement as well as bone augmentation procedures.

#### Inclusion and exclusion criteria

Adult subjects in need of a single tooth extraction in the anterior region of the dentition (including premolars) for trauma, periodontitis, endodontic or unresorable caries were invited to participate in this study provided they (i) did not have relevant medical conditions or had not received head and neck radiation for cancer treatment; (ii) did not smoke more than 20 cigarettes per day or did not use more than 14 mg/day of nicotine replacement therapy; (iii) had completed periodontal treatment, if necessary; (iv) presented with full mouth plaque and bleeding scores  $\leq 25\%$  at study baseline; (v) did not have clinically symptomatic periapical radiolucencies, acute abscesses or chronic sinus tracts at the site of extraction; (vi) had adequate quantity of native bone to achieve primary stability; (vii) had an adequate mesio-distal

space for implant placement ( $\geq 6.5$  mm, i.e. 1.5 mm on each side of the 3.5 mm platform); (viii) had a sufficient band of keratinised mucosa to allow surgical manipulation and suturing according to the protocol; and (ix) were available for follow-up according to protocol for 42 months. Consecutive patients fulfilling the above criteria were offered participation into the study.

#### Randomization, allocation concealment, blinding, calibration

Patient registration, randomization and monitoring were performed by a central study registrar located at the ERGOPerio Clinical Research support infrastructure in Genova, Italy. Randomization was done using random permuted blocks with minimization of treatment unbalance in terms of cigarette smoking as previously described (Tonetti et al. 1998). Treatment assignment was concealed to the treating surgeon by opaque envelopes that were opened only after completion of tooth extraction and final assessment of the feasibility of immediate implant placement. Clinical and radiographic measures, aesthetic evaluations and statistical analyses were performed blind with respect to treatment assignment. Before study initiation, all study personnel participated in a 3-day calibration exercise.

#### Study interventions

Before surgery, all subjects were premedicated with 2 g of amoxicillin-clavulanic acid (or an appropriate alternative for patients with allergy; Lang et al. 2012) and 50 mg of diclofenac (or 500 mg of paracetamol). For both treatment groups, implant placement and implant diameter choice were restoratively driven to maximize aesthetics and function. The criteria for bone augmentation were similar in both groups: bone replacement graft and barrier membrane were positioned whenever (i) the sum of the buccal crest thickness and implant to bone gap (the total horizontal distance between the alveolar crest and the implant surface) was  $< 2$  mm; or (ii) the endosteal portion of the implant was exposed above the bone crest (Sanz et al. 2016). The membrane

was positioned around the transmucosal portion of the implant essentially as described (Bragger et al. 1996). Tooth extractions were performed in a standardized way: papilla preservation flaps with intra-sulcular incisions (Cortellini et al. 1999) were raised to expose 2–3 mm of alveolar bone, luxation was performed with fine periostomes attempting to avoid trauma to the alveolus. After extraction and before opening the randomization envelope, the surgeon was asked to verify the feasibility of immediate implant placement on the basis of absence of acute infection or purulence and presence of an adequate quantity of alveolar bone to allow immediate implant placement with primary stability. Control treatment (delayed implant placement) consisted of: (i) closure of the flap without any attempt to preserve the dimensions of the socket or to close the alveolus by coronal advancement of the flap; (ii) a minimum of 12 weeks of undisturbed healing; (iii) restoratively driven implant placement with or without bone augmentation on the basis of the pre-specified criteria; (iv) attempt to obtain primary intention healing around a healing cap in a transmucosal fashion. For control subjects presenting at 12 weeks with inadequate bone volumes for restoratively driven implant placement, rescue treatment consisting of guided bone regeneration before implant placement was available. Test treatment (immediate implant placement) consisted of: (i) restoratively driven implant placement at the time of tooth extraction with or without bone augmentation on the basis of the pre-specified criteria; (ii) attempt to obtain primary intention healing around a healing cap in a transmucosal fashion. Adhesive bridges were used as temporary restoration whenever feasible.

Post-operative medications included continuation of the antibiotic regimen for 5 days, a second dose of diclofenac or paracetamol, and twice daily chlorhexidine 0.12% rinsing for the first 2 weeks. Modified oral hygiene with an ultrasoft surgical toothbrush soaked in chlorhexidine was introduced on the third post-operative day in the treated area and continued for 6 weeks (Heitz et al. 2004). Sutures were removed 1 week

after the procedure. Patients were instructed to avoid chewing or trauma to the treated area for the first 6 weeks. Normal oral hygiene and chewing was resumed by Week 6. Post-surgical controls consisting of professional tooth cleaning and oral hygiene instructions were performed at Weeks 1, 2, 6 and 12. Prosthetic reconstruction was initiated 12 weeks after implant insertion.

#### Outcomes and study power

The primary outcome of the study was the comparison of the need for bone augmentation at the time of implant installation in the test and control groups. The choice of the primary outcome was due to the availability of robust preliminary data to size the study. Based on the need to augment 90% of immediate implant sites determined in a previous similarly designed study (Lang et al. 2007), a sample size of 54 subjects per treatment arm was required to have 90% power at  $\alpha = 0.05$  to detect a clinically important two sided difference of 10% in the proportion of cases requiring bone augmentation. To compensate for missing data and attrition a sample size of 120 was selected. Secondary outcomes included: (i) comparison of frequencies of implant survival; (ii) comparison of surgical complications including changes in local soft and hard tissue parameters: plaque scores, bleeding on probing, probing attachment levels, probing pocket depths, width of keratinized mucosa, radiographic bone level (RBL); (iii) comparison of implant aesthetic scores using the modified pink esthetic score and white esthetic score (PES/WES) PES/WES system (Belser et al. 2009); and (iv) comparison of patient experience with the surgical procedures, satisfaction with the results and impact on oral health and quality of life using a structured questionnaire (Tonetti et al. 2004). Due to uneven recruitment among study centres, this study does not report a formal analysis of the centre effect as such analysis will be under-powered and may be biased.

#### Clinical periodontal measures

Clinical periodontal parameters were assessed by a single, calibrated and

blind investigator at each centre using a UNC15 periodontal probe equipped with a pressure sensitive device (Brodontic®; Tonetti et al. 1998). Examiners were calibrated against each centre principal investigator. Their reproducibility was assessed measuring twice the clinical attachment levels in 10 subjects with at least one dental implant. Examiners achieved a reproducibility >98% within 1 mm.

#### Radiographic analysis

Exposure geometry standardized parallel long-cone radiographs were taken using a custom fabricated bite-block before tooth extraction, at the time of crown insertion and at 12, 24 and 36 months thereafter. Radiographs were evaluated in digital format by a single calibrated investigator who was unaware of the treatment assignment and of the time of follow-up. Changes in RBLs were evaluated at a 20× magnification using calibrated image analysis software for clinical radiographs (Sorriso® Image; Dentalrey, Fiumana di Predappio, Italy). The length of the implant was used to correct for vertical distortion. The margin between the rough, endosteal portion of the implants and the 1.5 mm polished collar was used as the reference to measure RBL changes. Mesial and distal averages were calculated as the best estimate of RBL for each implant. Duplicate readings of 20 radiographs showed >98% agreement within 0.2 mm.

#### Statistical analysis

Data were entered and proofed for errors. Analysis was performed using STATA version 11, College Station, Texas, USA. Characteristics of the test and control populations were described as means and standard deviations. Data were graphically displayed as box-plots with 95% confidence intervals. Inter-group differences were assessed by Student *t*-test or Chi-square test. RBL changes as a function of time were evaluated with the trend test. Significance was set at  $p < 0.05$  for primary and secondary outcome analysis. Bonferroni corrections for multiple testing were applied for control outcome analyses.

## Results

#### Study population and external validity

Figure 1 shows the CONSORT patient accountability. In 10 of the 134 (7.5%) subjects entered into the study, after completion of the tooth extraction, the surgeon deemed that it was not possible to proceed with immediate implant placement, these subjects were excluded before randomization. A total of 124 subjects were randomized and received the allocated treatment. Table 1 shows the patient characteristics. No statistically significant differences were present between test and control patients. Good levels of oral hygiene are demonstrated. Full mouth plaque scores and full mouth bleeding scores as well as the number of residual periodontal pockets remained stable throughout the study period (Fig. S1). All subjects completed the post-surgical follow-up, but nine subjects discontinued before the 12th month follow-up; one in the immediate implant group was exited after early implant loss before prosthetic reconstruction; the others failed to comply with follow-up.

#### Surgical outcomes

Table 2 shows the frequency of ridge augmentation in the test and control groups. Immediate implants required significantly more frequently a bone augmentation procedure ( $p = 0.01$ ). Optimal primary closure of the wound was obtained in 82% of delayed implants and 62% of immediate ones ( $p = 0.05$ ). A composite wound failure index comprising wound dehiscence, oedema, and suppuration over the first six post-operative weeks was calculated. Wound failure was five times more frequent at immediately placed implants. Patient post-operative complaints also had a tendency towards higher frequency at immediate implant sites.

One implant in the immediate implant group was lost due to an infection before completion of osseointegration. All other implants were reconstructed as planned and were present without symptoms 12 months after loading. In all delayed implant cases it was possible to place a restoratively driven implant without having to resort to

a preparatory bone augmentation procedure before implant placement.

The dimensions of bone defects present after completion of positioning of immediate and delayed implants are described in Fig. 2. On average, both immediate and delayed implant sites displayed inadequate bone diameters. In the immediate implant group, these were due to: (i) the resorption of the alveolar crest associated with the reason for tooth extraction; and/or (ii) the presence of a gap between the dimension of the alveolus and the restoratively driven choice of implant diameter and implant position in the immediate implant group. In the delayed implant group, these were due to the pattern of bone healing after the extraction. Figure 2b shows the distance of the residual alveolar crest from the margin of the endosteal part of the implant. This distance shows the presence of a significant degree of buccal and lingual resorption of the margin of the alveolus. Significant differences were observed comparing the two groups. Not unexpectedly, the more obvious differences related to the larger depth or width of defects associated with immediate implants.

Upon completion of the procedure, the surgeon was asked to rate the technical difficulty of the procedure using a visual analogue scale (VAS) with two anchors at the extremes: very easy and very difficult. Results are displayed in Fig. S2. Both procedures were rated in the easy to very easy portion of the scale. No differences were detected comparing immediate and delayed implants ( $p = 0.88$ ). No differences were observed in terms of the actual time needed for the procedure(s) (data not shown).

#### Patient reported outcomes

Patient reported outcomes were evaluated with questionnaires using VAS. Figure 3 reports VAS scores of test and control subjects. With regards to hardship and pain during the procedure, subjects responded immediately after the completion of the surgery, while post-operative pain and discomfort were scored at the 1-week post-operative appointment. Both procedures were well tolerated and no significant differences were observed comparing the two procedures.

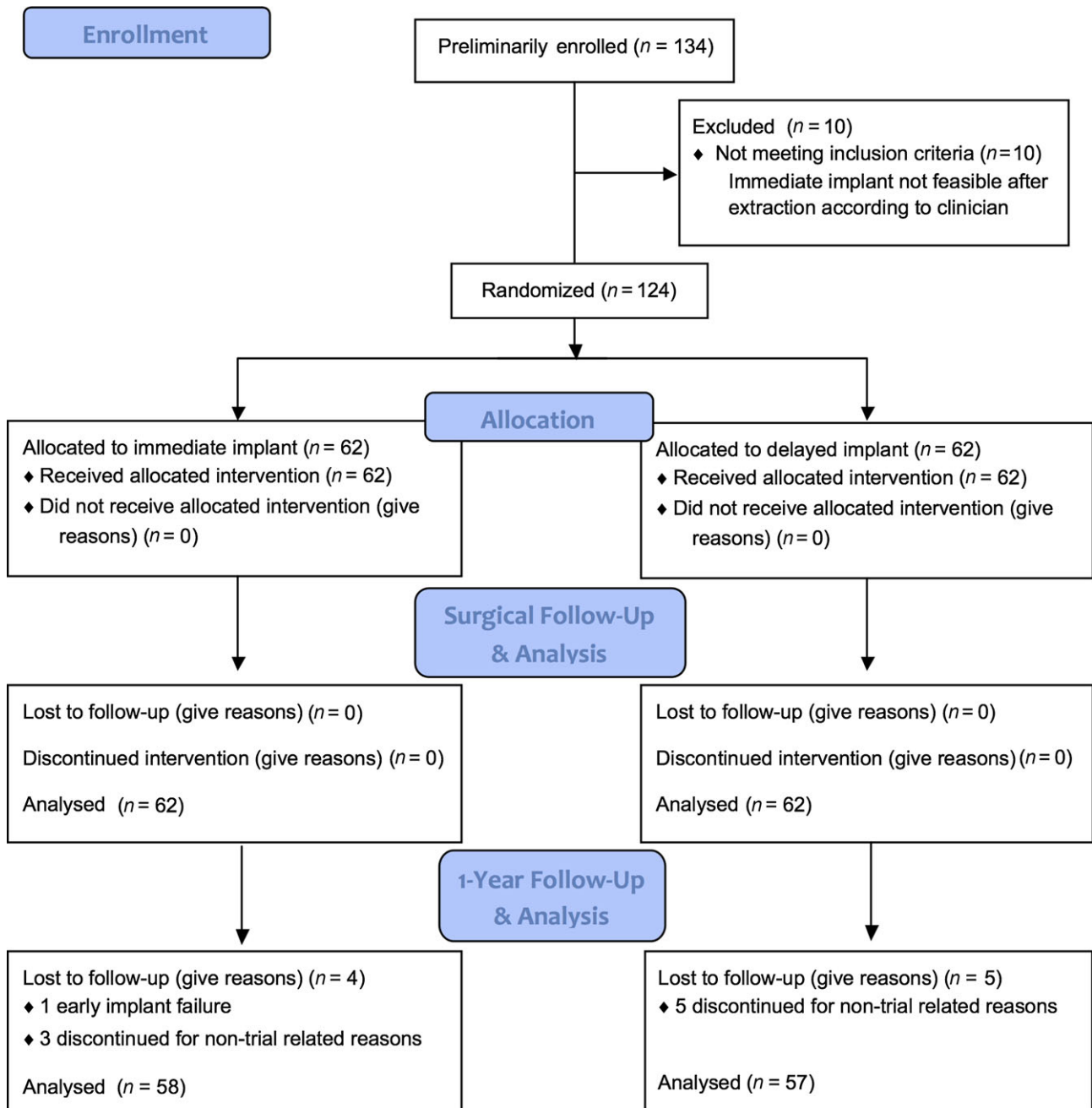


Fig. 1. Consort diagram.

Overall patient satisfaction with the procedures was very high (>85% in the VAS scale for both groups), and no significant differences were observed comparing test and control subjects.

**Clinical periodontal outcomes**

At the time of crown insertion, probing depths were significantly deeper in the immediate implant group than in the delayed implant group

( $3.7 \pm 1.4$  and  $3.1 \pm 1.1$  mm,  $p < 0.01$ ). Deeper probing depths were observed in the immediate implant group at the 12-month follow-up ( $4.1 \pm 1.2$  mm) compared with the delayed ( $3.3 \pm 1.1$  mm,  $p < 0.01$ ). No differences between the two groups were observed in the frequency of implants bleeding on probing at crown insertion or 12-month follow-up (data not shown).

**Radiographic outcomes**

Figure 4 reports RBLs at insertion of the crown and 12, 24 and 36-month follow-up. At crown insertion, RBL was coronal to the endosteal portion of the implant in the immediate implant group, while it was at the level of the endosteal portion of the implant in the delayed group. The difference between the two groups was  $0.8 \pm 0.4$  mm

Table 1. Study population

	Immediate	Delayed	Significance
Age (years)	50 ± 14	55 ± 13	<i>p</i> = 0.076
Females	63%	73%	<i>p</i> = 0.376
Smokers	15%	15%	<i>p</i> = 0.983
FMPS	20 ± 16	17 ± 14	<i>p</i> = 0.333
FMBS	11 ± 11	12 ± 16	<i>p</i> = 0.875

FMBS, full mouth bleeding score; FMPS, full mouth plaque score. Means ± SD.

Table 2. Comparison of surgical outcomes in the test and control groups

	Immediate (%)	Delayed (%)	Significance
Need for bone augmentation	72	43.9	<i>p</i> = 0.01
Primary wound closure	61.7	82.1	<i>p</i> = 0.05
Wound failure	26.1	5.3	<i>p</i> = 0.02
Patient post-op complaints	18.9	4.9	<i>p</i> = 0.06

(*p* < 0.01). Over the following 36 months, immediate implants showed a statistically significant trend for more RBL loss compared to delayed implants (*p* for trend = 0.03). No significant changes in RBL were observed comparing crown insertion with 12, 24 and 36 months in the delayed implant group.

**Aesthetic outcomes**

Figure S3 reports the dimensions of the keratinized tissue before the extraction, at the time of prosthetic reconstruction and 12 months later at the implant site (panel a) and at the neighbouring teeth (panel b). The band of keratinized tissue

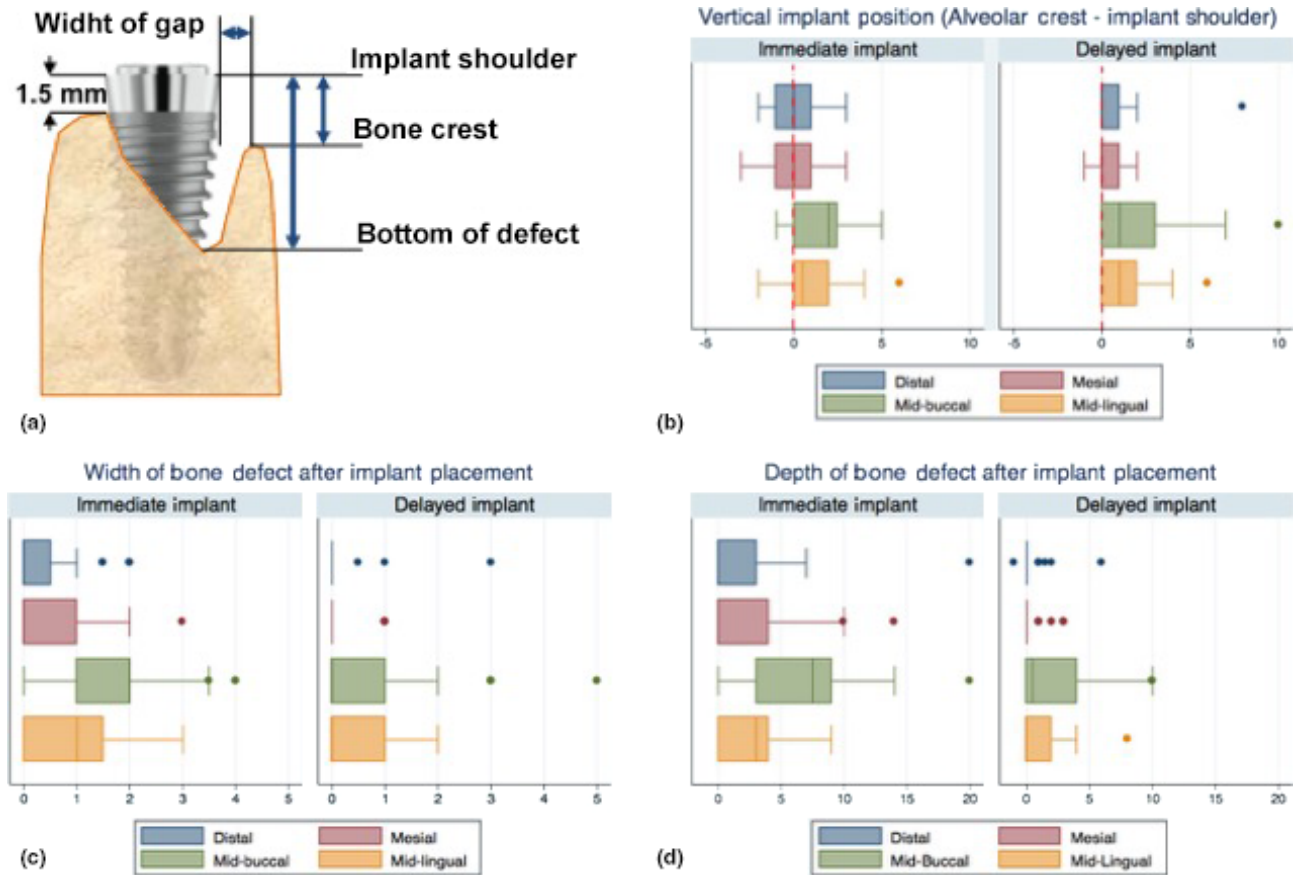


Fig. 2. Bone measurements after implant placement. All measurements were taken using the implant shoulder as the reference point to the nearest mm using a UNC-15 periodontal probe. Implant shoulder to bottom of the defect = depth of bone defect; Implant shoulder to bone crest – 1.5 mm = vertical implant position; implant shoulder to bone crest in a horizontal direction = width of bone gap. (Panel a) Measurement scheme. (Panel b) Vertical implant position with reference to the mesio-distal bone level of the two adjacent teeth. (Panel c) Horizontal width of the implant to alveolar bone crest defect. At immediate implants, this also includes the horizontal gap between the implant surface and the alveolar crest. At delayed implants it includes the buccal or lingual defect with respect to the ideal bone contour. (Panel d) Depth of the vertical component of the defect around the restoratively placed implant. In all panels the measurements are taken at four points around the implant: mesial, distal, mid-buccal and mid-lingual. All data displayed are box-plots. *p*-values are reported for test versus control treatments and *t*-test after Bonferroni correction for multiple testing.

remained stable and no significant differences were observed comparing immediate and delayed implants.

Changes in position of the gingival margin of the neighbouring teeth between the baseline situation and the 12-month post-loading one were

$0.3 \pm 0.8$  mm for immediate and  $0.5 \pm 0.9$  mm in the delayed implant group with no significant difference being detected ( $p = 0.78$ ).

Aesthetic scores for both the crown and the surrounding soft tissues were evaluated using the

PES/WES system and are displayed in Fig. 5. In accordance with the use of a restoratively guided choice of implant diameter and implant positioning, box-plots of WES scores were essentially identical in the test and control groups. Furthermore,

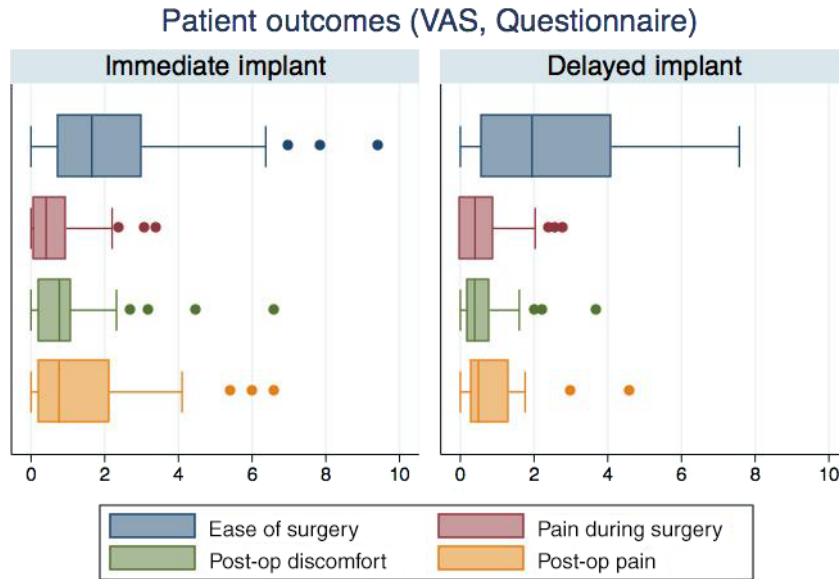


Fig. 3. Patient reported outcomes. Surgery and 1-week post-op period. Box-plots display visual analogue scale (VAS) scores (0–10 cm lines with anchors at 0 = no pain or discomfort at all and 10 = extreme pain or discomfort). Pain and discomfort was moderate for both procedures (VAS  $\leq 3$ ). No differences were observed between treatments ( $p > 0.13$ ). For control of post-op pain and discomfort patients received two 50 mg doses of diclofenac (one before and one 12 h after surgery).

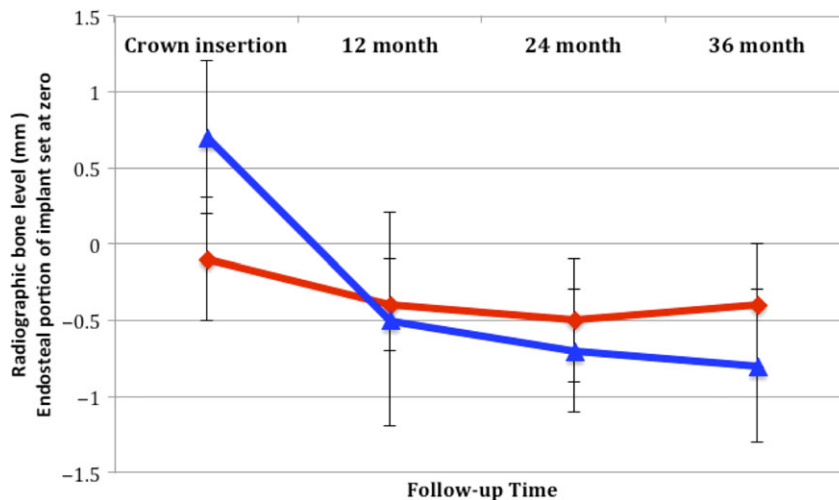


Fig. 4. Radiographic bone level (RBL) changes comparing immediate and delayed implant placement. Changes in RBL (expressed in mm and as mean  $\pm$  Stdev) from the time of crown insertion until the end of follow-up for immediate (blue line) and delayed (red line) implants. The margin of the endosteal portion of the implant is used as a reference point. Negative values represent a position apical to the reference point. No significant difference were observed at any time point with the exception of the time of crown insertion. At crown insertion the RBL was positioned 0.8 mm more coronal in the immediate implant placement group. Immediate implants were placed more apical than delayed implants (see Fig. 3). Immediate implants displayed significantly more RBL loss than delayed ones ( $p$  for trend = 0.04). No difference was observed between the time of crown insertion and the follow-up period for the delayed implant group.

the majority of cases had WES scores greater than the arbitrarily set clinical acceptability level in an aesthetic site. PES scores differed comparing immediate and delayed implants: arbitrarily set inadequate PES was obtained in 19% of delayed implant cases and in 42% of immediate implant cases. The difference was statistically significant (Chi-squared test,  $p = 0.03$ ).

## Discussion

This study shows the possibility to complete an ethically challenging trial on a controversial topic in implant dentistry with an appropriate control of potential sources of bias. These results contribute to clarification of the relative merits of immediate and delayed implant placement after single tooth extraction in the anterior portion of the dentition.

The results challenge a series of widely held paradigms. Undisturbed healing of extraction sockets without the application of any ridge preservation/augmentation approach allowed restoratively guided implant positioning in the control group. In some cases a total buccal bone thickness >1.5 mm was obtained with the addition of bone augmentation

materials at the time of implant placement, in others without it. An interesting result was that, comparing immediate implant placement at the time of extraction with delayed implant placement, bone augmentation was more frequently needed at immediate implant placement. This result may be partly due to the decision to choose the implant diameter based upon the cervical dimension of the tooth that needed to be replaced rather than selection based upon the size of the alveolus. The lower frequency of bone augmentation in the delayed implant seems to provide an important argument for selection of this approach as bone augmentation increases both the cost and the complexity of the procedure. Another important element related to the conditions of the alveoli after extraction. In this trial significant loss of both the buccal and palatal wall was present and this increased the need for bone augmentation at immediate implant sites. The observation that bone augmentation was less frequently needed in delayed placement challenges the current paradigms of the significance of spontaneous alveolar bone resorption during extraction socket healing (Van der Weijden et al. 2009). Recent research synthesis on interventions to preserve

extraction alveoli recognizes both the effectiveness of the preservation/reconstruction procedures (Avila-Ortiz et al. 2014) and questions their clinical relevance (Atieh et al. 2015). More high quality research is needed to convincingly answer these questions.

The issues related to timing of implant placement are complicated by the lack of consensus on effective and established procedures and by the wide array of confounders that have played a role in previous trials. In this study we decided to use a flap at the time of extraction and implant placement to be able to standardize surgery in the two groups. Raising a flap will undoubtedly affect the healing of the site. This has been shown in both preclinical (Blanco et al. 2008) and clinical studies (Cosyn et al. 2016, Stoupelet et al. 2016). The choice not to immediately place a temporary reconstruction may have further influenced the results (Slagter et al. 2015, Stoupelet et al. 2016).

Wound failure was observed at 26% of immediate implant placement sites and almost five times more frequently than in the delayed group. It mostly related to relatively minor complications that can be attributed to the challenge of achieving primary wound closure. This has

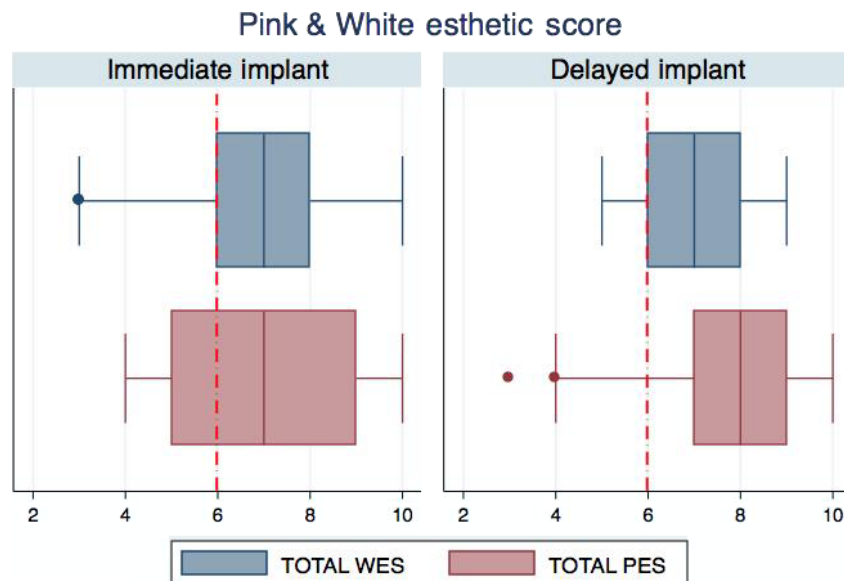


Fig. 5. Twelve-month post-crown insertion comparison of pink and white aesthetic scores at immediate and delayed implants. Twelve month soft tissue (pink) aesthetic score (PES, blue box plot) and crown (white) aesthetic score (WES, red box plot) were evaluated by two independent and calibrated examiners using photographs and study models as indicated by Belser et al. (2009). The red vertical dashed line highlights the level of clinical acceptability arbitrarily defined according to Belser et al. (2009). Outcomes above 6 have been considered clinically acceptable by a professional assessment.



been observed in our previous trial on immediate implants in spite of the attempt to use papilla preservation flaps to improve inter-dental tissue adaptation (Lang et al. 2007). Wound failure has been associated with suboptimal outcomes in periodontal surgical procedures (Tonetti et al. 1993) and attempts to limit this occurrence has been the underlying rationale for surgical flap developments over the last two decades. At implants, wound failure has been shown to negatively affect bone levels both at submerged and transmucosal healing. The fact that primary closure of the wound was obtained less frequently at immediate implant sites and that wound failure was more frequent in these cases reflects the inherent challenges of restoratively guided immediate implant installation: (i) the difficulty to obtain optimal primary closure of the palatal/lingual aspect; (ii) the challenge to maintain optimal papilla closure during the healing period in an environment whose blood supply has been limited by the obliteration of the periodontal ligament plexus after the placement of the dental implant; and (iii) the potential impact of the bone augmentation material on the wound healing. It seems that, in spite of careful soft tissue handling with microsurgical materials and the application of papilla preservation flaps, immediate implant placement carries a higher degree of surgical risk. This risk did not impact obvious areas like the facial aspect of the neighbouring teeth where no changes in recession of the gingival margin were observed, or the width of the facial band of keratinized tissue that remained stable after implant placement. Nevertheless, the 12-month post loading assessment of aesthetics showed greater variability in pink aesthetic scores and higher frequency of suboptimal pink aesthetic outcomes. This study showed that increased surgical risk might impact on the final soft tissue aesthetics.

Another important element relates to deeper implant positioning and deeper probing depths at the immediate implants. Preclinical studies have suggested that the dimensions of the junctional epithelium are increased at immediate implant sites with transmucosal healing (de

Sanctis et al. 2009, Vignoletti et al. 2009). Little is known about whether such different biological healing and clinical parameters impacts the local microbiome at dental implants and health and stability of the soft tissue seal. The initial analysis of radiographic bone changes reported in Fig. 4 shows a trend for additional bone loss in the immediate implant group, the observed differences, however, are confounded by the deeper placement of the immediate implants. Further analyses will explore the impact of these parameters on soft tissue health and RBL stability.

Another interesting finding was that, in spite of a careful pre-surgical diagnostic assessment that had verified the absence of a symptomatic peri-apical lesion, acute infection, sinus tract and the presence of adequate residual bone volumes to obtain primary stability of an immediately placed implant, 7.5% of extraction sockets were deemed unsuitable by the surgeon after completing the extraction. These were exited from the study before being randomized to treatment. In clinical practice these cases are of concern as they may be either inappropriately treated with an immediate implant or present the logistic and economic challenge of non-completing the planned procedure.

The evaluation of the surgical difficulty of the case provided by the surgeon at the end of the procedure showed that both surgical approaches were relatively easy but that both offered specific challenges. In terms of patient reported outcomes, no significant differences were observed in terms of pain and discomfort. Results are in line with reports from similar trials (Tan et al. 2014, Mei et al. 2016). A tendency towards greater incidence of post-op complaints during the early phases of healing was observed in the immediate implant group.

This study provides evidence to caution clinicians against the widespread application of immediate implants, which should be reserved for highly selected cases in areas of low aesthetic priority. Longer follow up is necessary to ascertain whether the deeper mucosal tunnel and the observed trend for greater marginal bone loss at immediate implants has

implications for biological complications and long term implant retention.

## Acknowledgements

Authors wish to recognize the clinical staff members of the participating centres for their excellent clinical work that made this study possible. The helpful discussions and external peer review of the protocol draft by Prof. Jan Lindhe and Prof. Urs Belser are gratefully acknowledged.

## References

- Atieh, M. A., Alsabeeha, N. H., Payne, A. G., Duncan, W., Faggion, C. M. & Esposito, M. (2015) Interventions for replacing missing teeth: alveolar ridge preservation techniques for dental implant site development. *Cochrane Database Systematic Review* **28**, CD010176. doi: 10.1002/14651858.CD010176.pub2.
- Avila-Ortiz, G., Elangovan, S., Kramer, K. W., Blanchette, D. & Dawson, D. V. (2014) Effect of alveolar ridge preservation after tooth extraction: a systematic review and meta-analysis. *Journal of Dental Research* **93**, 950–958.
- Belser, U. C., Grutter, L., Vailati, F., Bornstein, M. M., Weber, H. P. & Buser, D. (2009) Outcome evaluation of early placed maxillary anterior single-tooth implants using objective esthetic criteria: a cross-sectional, retrospective study in 45 patients with a 2- to 4-year follow-up using pink and white esthetic scores. *Journal of Periodontology* **80**, 140–151.
- Blanco, J., Nunez, V., Aracil, L., Munoz, F. & Ramos, I. (2008) Ridge alterations following immediate implant placement in the dog: flap versus flapless surgery. *Journal of Clinical Periodontology* **35**, 640–648.
- Bragger, U., Hämmerle, C. & Lang, N. P. (1996) Immediate transmucosal implants using the principle of guided tissue regeneration (II). A cross sectional study comparing clinical outcome 1 year after immediate to standard implant placement. *Clinical Oral Implants Research* **7**, 268–276.
- Cortellini, P., Prato, G. P. & Tonetti, M. S. (1999) The simplified papilla preservation flap. A novel surgical approach for the management of soft tissues in regenerative procedures. *The International Journal of Periodontics & Restorative Dentistry* **19**, 589–599.
- Cosyn, J., Eghbali, A., Hermans, A., Vervaeke, S., De Bruyn, H. & Cleymaet, R. (2016) A 5-year prospective study on single immediate implants in the aesthetic zone. *Journal of Clinical Periodontology* **43**, 702–709.
- Esposito, M., Grusovin, M. G., Polyzos, I. P., Felice, P. & Worthington, H. V. (2010) Interventions for replacing missing teeth: dental implants in fresh extraction sockets (immediate, immediate-delayed and delayed implants). *Cochrane Database Systematic Review* **8**, CD005968. doi: 10.1002/14651858.CD005968.pub3.
- Heitz, F., Heitz-Mayfield, L. J. & Lang, N. P. (2004) Effects of post-surgical cleansing protocols on early plaque control in periodontal and/or periimplant wound healing. *Journal of Clinical Periodontology* **31**, 1012–1018.

- Lang, N. P., Pun, L., Lau, K. Y., Li, K. Y. & Wong, M. C. M. (2012) A systematic review on survival and success rates of implants placed immediately into fresh extraction sockets after at least 1 year. *Clinical Oral Implants Research* **23**, 39–66.
- Lang, N. P., Tonetti, M. S., Suvan, J. E., Bernard, J. P., Botticelli, D., Fourmoussis, I., Hallund, M., Jung, R., Laurell, L., Salvi, G. E., Shafer, D. & Weber, H. P. (2007) Immediate implant placement with transmucosal healing in areas of aesthetic priority: a multicentre randomized-controlled clinical trial I. Surgical outcomes. *Clinical Oral Implants Research* **18**, 188–196.
- Mei, C. C., Lee, F. Y. & Yeh, H. C. (2016) Assessment of pain perception following periodontal and implant surgeries. *Journal of Clinical Periodontology* **43**, 1151–1159.
- de Sanctis, M., Vignoletti, F., Discepoli, N., Zucchelli, G. & Sanz, M. (2009) Immediate implants at fresh extraction sockets: bone healing in four different implant systems. *Journal of Clinical Periodontology* **36**, 705–711.
- Sanz, M., Cecchinato, D., Ferrus, J., Salvi, G. E., Ramseier, C., Lang, N. P. & Lindhe, J. (2014) Implants placed in fresh extraction sockets in the maxilla: clinical and radiographic outcomes from a 3-year follow-up examination. *Clinical Oral Implants Research* **25**, 321–327.
- Sanz, M., Lindhe, J., Alcaraz, J., Sanz-Sanchez, I. & Cecchinato, D. (2016) The effect of placing a bone replacement graft in the gap at immediately placed implants: a randomized clinical trial. *Clinical Oral Implants Research* in press. doi: 10.1111/clr.12896.
- Slagter, K. W., Meijer, H. J., Bakker, N. A., Vis-sink, A. & Raghoobar, G. M. (2015) Feasibility of immediate placement of single-tooth implants in the aesthetic zone: a 1-year randomized controlled trial. *Journal of Clinical Periodontology* **42**, 773–782.
- Stoupe, J., Lee, C. T., Glick, J., Sanz-Miralles, E., Chiuzan, C. & Papanou, P. N. (2016) Immediate implant placement and provisionalization in the esthetic zone using a flapless or a flap-involving approach: a randomized controlled trial. *Journal of Clinical Periodontology* **43**, 1171–1179.
- Tan, W. C., Krishnaswamy, G., Ong, M. M. & Lang, N. P. (2014) Patient-reported outcome measures after routine periodontal and implant surgical procedures. *Journal of Clinical Periodontology* **41**, 618–624.
- Tonetti, M. S., Cortellini, P., Suvan, J. E., Adriaens, P., Baldi, C., Dubravec, D., Fonzar, A., Fourmoussis, I., Magnani, C., Muller-Campañile, V., Patroni, S., Sanz, M., Vangsted, T., Zabalegui, I., Pini-Prato, G. & Lang, N. P. (1998) Generalizability of the added benefits of guided tissue regeneration in the treatment of deep intrabony defects. Evaluation in a multicenter randomized controlled clinical trial. *Journal of Periodontology* **69**, 1183–1192.
- Tonetti, M. S., Fourmoussis, I., Suvan, J., Cortellini, P., Bragger, U., Lang, N. P. & European Research Group on, P. (2004) Healing, post-operative morbidity and patient perception of outcomes following regenerative therapy of deep intrabony defects. *Journal of Clinical Periodontology* **31**, 1092–1098.
- Tonetti, M. S., Pini-Prato, G. & Cortellini, P. (1993) Periodontal regeneration of human intrabony defects. IV. Determinants of healing response. *Journal of Periodontology* **64**, 934–940.
- Van der Weijden, F., Dell'Acqua, F. & Slot, D. E. (2009) Alveolar bone dimensional changes of post-extraction sockets in humans: a systematic review. *Journal of Clinical Periodontology* **36**, 1048–1058.
- Vignoletti, F., de Sanctis, M., Berglundh, T., Abrahamsson, I. & Sanz, M. (2009) Early healing of implants placed into fresh extraction sockets: an experimental study in the beagle dog. III: soft tissue findings. *Journal of Clinical Periodontology* **36**, 1059–1066.

## Supporting Information

Additional Supporting Information may be found in the online version of this article:

**Figure S1.** Oral hygiene, bleeding on probing and number of residual periodontal pockets from baseline until 12-month after loading.

**Figure S2.** Surgeon's rating of the technical difficulty of the case.

**Figure S3.** Changes in keratinized tissue at implant site and neighbouring teeth.

Address:

Maurizio S. Tonetti  
European Research Group on Periodontology  
12th Floor WTC Tower Genoa  
Via De Marini 1  
16149 Genova, Italy  
E-mail: maurizio.tonetti@ergoperio.eu

## Clinical Relevance

*Scientific rationale for the study:* Timing of implant placement remains a controversial issue. Systematic reviews have identified both a gap in evidence and low quality of the available evidence for clinical decision-making. Consensus reports based on expert opinion have reached conflicting results.

*Principal findings:* Immediate implants are a feasible treatment modality but increase in wound failure, greater needs of bone augmentation, higher rates of suboptimal soft tissue aesthetics, deeper implant placement and probing pocket depth associated with a trend towards more radiographic bone loss are important unwanted effects. In spite of careful preoperative diagnosis,

immediate implant placement was not indicated, in 7.5% of cases.

*Practical implications:* The obvious benefits of immediate implant placement need to be carefully assessed against increased complexity and higher chance of suboptimal outcome, particularly in the aesthetically relevant area of the dentition. Immediate implants should be limited to highly selected cases.