

DERMOSCOPY OF THE MONTH

Azithromycin-Induced Longitudinal Melanonychia in a Child- a Case Report

Andrija JOVIĆ¹, Danica TIODOROVIĆ^{1,2}, Danijela POPOVIĆ¹, Hristina KOCIĆ¹,
Zorana ZLATANOVIĆ¹, Milan KOSTIĆ¹, Giovanni DAMIANI^{3,4,5}

¹Clinic of Skin and Venereal Diseases, Clinical Center of Niš, Serbia

²Faculty of Medicine, University of Niš, Serbia

³Young Dermatologists Italian Network (YDIN), Centro Studi GISED, Bergamo, Italy

⁴Clinical Dermatology, IRCCS Istituto Ortopedico Galeazzi, Department of Biomedical, Surgical and Dental Sciences, University of Milan, Milan, Italy

⁵Department of Dermatology, Case Western Reserve University, Cleveland, OH, USA

*Correspondence: Andrija Jović, E-mail: andrijajovic@rocketmail.com

UDC 616.596-003.829-07/-08

Abstract

Melanonychia refers to a brown or black coloration of the nail plate caused by numerous factors. Regarding the arrangement of pigmentation, we can differentiate between total melanonychia, when pigmentation involves the whole nail plate, or transverse or longitudinal melanonychia, when pigmentation involves the nail in a form of transverse or longitudinal band of pigmentation, respectively. Since longitudinal melanonychia can be a sign of numerous benign and malignant lesions, it often poses a diagnostic challenge for a dermatologist. Herein, we report a case of a 13-year-old girl who developed longitudinal melanonychia on multiple nails after receiving a therapy with azithromycin.

Key words: Azithromycin; Nail Diseases; Melanoma; Dermoscopy; Hyperpigmentation; Pigmentation Disorders; Adolescent

Introduction

Melanonychia refers to a brown or black coloration of the nail plate caused by numerous factors as a result of activation or proliferation of nail melanocytes as well as of direct production of melanin by pathogens (1-3). Regarding the arrangement of pigmentation, we can differentiate between total melanonychia,

when pigmentation involves the whole nail plate, or transverse or longitudinal melanonychia, when pigmentation involves the nail in a form of transverse or longitudinal band of pigmentation, respectively (1, 2). The vast majority of melanonychia belongs to longitudinal melanonychia, while other two forms are reported occasionally (1-3).

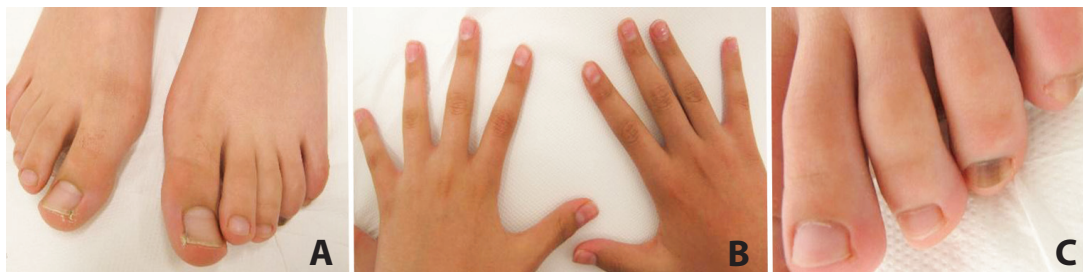

Figure 1. Pigmentation on the fourth right toenail and the fourth and the fifth left toenail without affecting the fingernails (A, B, C)

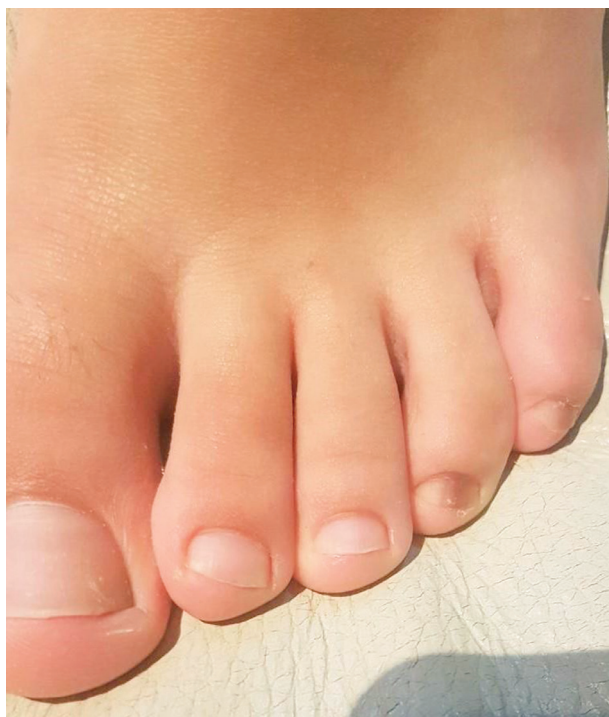

Figure 3. Partial regression of pigmentation after one-year follow-up

Longitudinal melanonychia, also known as melanonychia striata, is clinically manifested as a longitudinal streak of tan, brown or black pigmentation extending from the nail matrix along to the tip of the nail plate (1, 2). Depending on the number of nails involved, it can be presented in a form of single or multiple longitudinal melanonychia (1, 2).

The reported prevalence in white population is 1.4%, whereas it is reported more often in darkly pigmented population, with the prevalence ranging from 77% in African Americans in their twenties to approximately 100% in individuals older than 50 (4).

Longitudinal melanonychia can be a sign of numerous benign lesions including nail matrix melanocytic nevus, lentigo, drug-induced pigmentation, ethnic related pigmentation, trauma induced pigmentation, as well as subungual hemorrhages (1, 3). However, the possibility of subungual melanoma, although rare, should be considered.

Regarding the long list of differential diagnoses, the presence of longitudinal melanonychia in patients often poses a diagnostic challenge for a dermatologist. In addition, the fact that longitudinal melanonychia

can be an early sign of subungual melanoma which carries a poor prognosis, the diagnostic evaluation in the patients with those lesions should be crucial.

Herein, we report a pediatric patient who developed longitudinal melanonychia after receiving a therapy with azithromycin.

Case Report

A 13-year-old girl was referred to our Department for an evaluation of the nail pigmentation. Her personal history was uneventful. Also, there were no reported malignancies in personal or family history. Four weeks prior to the onset of the nail pigmentation, the patient was on therapy with azithromycin due to otitis media. Apart from azithromycin, she did not report use of any other medication in the recent past.

Clinical examination revealed some brown colored streaks along the nail plate on the fourth right toenail and the fourth and fifth left toenail (Figure 1 A, B, C). Hyperpigmentation was not observed on other nails, skin, mucous membranes, or sclerae. Dermoscopic examination showed a repetitive pattern of tan to brown regular longitudinal lines on the brown background extending from the proximal fold to the tip of the nails on fingers, which was visible through the cuticle (Figure 2 A,B). A routine hematological and biochemical examination was done along with the hormonal status (ACTH, T3, T4, TSH, and Cortisol), which did not reveal any abnormalities. The diagnosis of longitudinal melanonychia triggered by azithromycin was favored based on the history, clinical and dermoscopic findings.

We decided to do a regular follow-up every 6 months. After the one-year follow-up, the nail pigmentation partially disappeared (Figure 3).

Discussion

In pediatrics, the occurrence of longitudinal melanonychia is less commonly observed when compared to the elderly population. Furthermore, the underlying causes of this pigmentation significantly differ from the causes frequently reported in elderly patients (5, 6). Benign melanocytic nevi, lentiginous, and melanocyte activation due to various causes are most commonly reported in etiol-

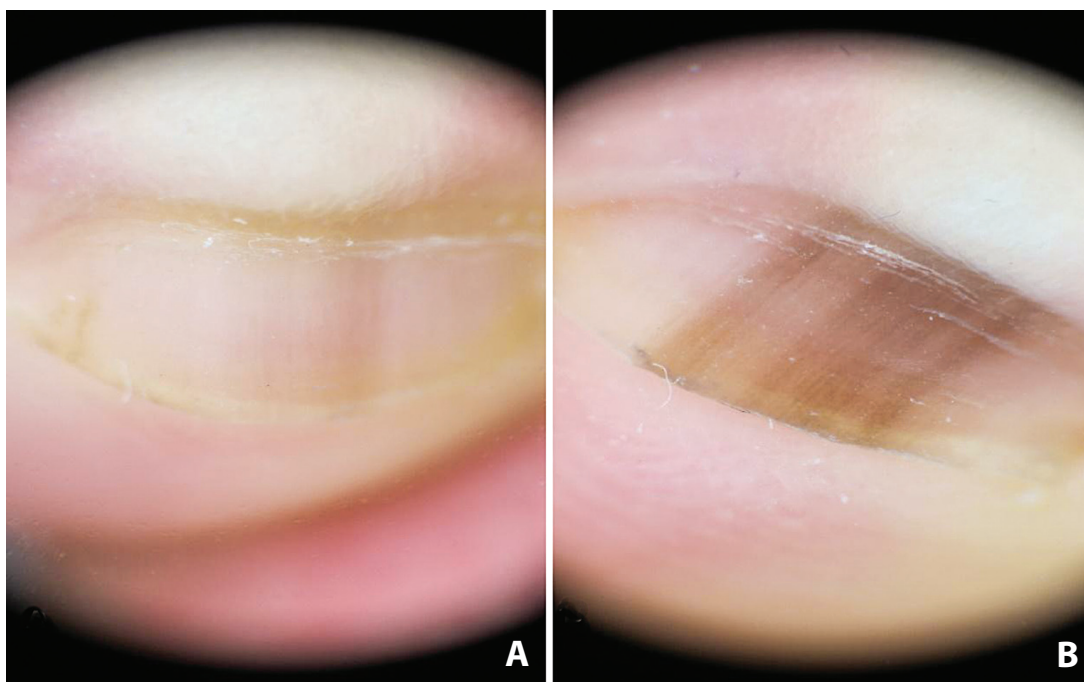


Figure 2. Regular tan to brown longitudinal lines on brown background observed by dermoscopy (A, B)

ogy of longitudinal melanonychia in childhood, whereas the presence of invasive subungual melanoma has not been reported in literature as far as we know, except for few cases of subungual melanoma in situ (5-7). However, approximately 6% of lesions presented as longitudinal melanonychia are melanomas in adult population (8). This implicates different clinical approach in the assessment of pigmented nail lesions between these two populations.

In most cases, the diagnostic assessment of nail pigmentation includes detailed personal history, clinical and dermoscopic examination (3). On the clinical ground, the onset during adulthood, monodactylic presentation, nail plate dystrophy, as well as rapidly evolving pigmentation with exclusion of other causes, should raise a clinical suspicion of subungual melanoma (1-3).

Proximal or lateral periungual skin involvement, also known as Hutchinson's sign, is highly related to subungual melanoma (3,9). However, it is not pathognomonic since it can be also found in nail melanocytic nevi (10). Moreover, hyperpigmentation that extends beneath the cuticle, without involving either cuticle or proximal nail fold, can simu-

late Hutchinson's sign. This is explained as a reflection of pigmentation due to the transparency of the cuticle and it is known as pseudo-Hutchinson's sign (1, 10, 11).

Dermoscopy has proven its efficiency in the diagnosis of melanocytic and non-melanocytic lesions. Dermoscopy also plays an important role in the evaluation of nail apparatus pigmentation since very subtle pigmentations not even visible to the naked eye can be observed. The term "micro" Hutchinson's sign is used for the pigmentation of cuticle only observed through dermoscopy and not clinically, and it is highly suggestive of subungual melanoma (11). In addition, irregularity of lines in color, thickness, and spacing should raise a suspicion of subungual melanoma. In this case, the longitudinal lines were regularly spaced out in parallel patterns in all involved nails (9, 11).

Drug-induced melanonychia most often occurs on several nail units, usually with multiple brown to black transverse or longitudinal streaks (1-3, 12). Interestingly, in the category of transverse melanonychia, drug-induced melanonychia accounts for the majority of the cases (3). Most commonly, chemotherapeutic drugs have been incriminated as the principal

cause, but other drugs including antiretrovirals, antimalarials and antibiotics are also known to have been the cause. Among the antibiotics, tetracyclines and sulfonamide are most often observed as drugs that cause this condition. After the cessation of therapy, the pigmentation disappears partially or completely in most cases (1-3). However, the process may take longer, as it was observed in this case.

Since other causes were excluded by performing the detailed clinical examination, insignificance in past medical and drug histories, the underlying cause of longitudinal melanonychia in this case was in favor of azithromycin therapy. To our knowledge, this is the first drug-induced longitudinal melanonychia related to azithromycin. In conclusion, clinical and dermoscopic examination of all nails, along with the detailed medical and drug history of the patient, provides sufficient information for the clinician when dealing with longitudinal melanonychia.

References

1. Jefferson J, Rich P. Melanonychia. *Dermatol Res Pract.* 2012;2012:952186.
2. Baran R, Kechijian P. Longitudinal melanonychia (melanonychia striata): diagnosis and management. *J Am Acad Dermatol.* 1989;21(6):1165-75.
3. Tosti A, Piraccini BM, de Farias DC. Dealing with melanonychia. *Semin Cutan Med Surg.* 2009;28(1):49-54.
4. André J, Lateur N. [Pigmented nail disorders.](#) *Dermatol Clin.* 2006;24(3):329-39.
5. Goettmann-Bonvallot S, André J, Belaich S. Longitudinal melanonychia in children: a clinical and histopathologic study of 40 cases. *J Am Acad Dermatol.* 1999;41(1):17-22.
6. Lam JM. Pediatric longitudinal melanonychia. *CMAJ.* 2017;189(34):1093.
7. Antonovich DD, Grin C, Grant-Kels JM. [Childhood subungual melanoma in situ in diffuse nail melanosis beginning as expanding longitudinal melanonychia.](#) *Pediatr Dermatol.* 2005;22(3):210-2.
8. Theunis A, Richert B, Sass U, Lateur N, Sales F, André J. Immunohistochemical study of 40 cases of longitudinal melanonychia. *Am J Dermatopathol.* 2011;33(1):27-34.
9. Thomas L, Dalle S. [Dermoscopy provides useful information for the management of melanonychia striata.](#) *Dermatol Ther.* 2007;20(1):3-10.
10. Kawabata Y, Ohara K, Hino H, Tamaki K. Two kinds of Hutchinson's sign, benign and malignant. *J Am Acad Dermatol.* 2001;44(2):305-7.
11. Ronger S, Touzet S, Ligeron C, Balme B, Viallard AM, Thomas L. Dermoscopic examination of nail pigmentation. *Arch Dermatol.* 2002;138(10):1327-33.
12. Piraccini BM, Alessandrini A. Drug-related nail disease. *Clin Dermatol.* 2013;31(5):618-26.

Longitudinalna melanonihija izazvana azitromicinom kod deteta – prikaz slučaja

Sažetak

Melanonihija predstavlja braon ili crnu prebojenost nokatnih ploča uzrokovanu brojnim faktorima. U odnosu na raspored pigmentacije, možemo razlikovati totalnu melanonihiju, kada pigmentacija zahvata čitavu nokatnu ploču, ili longitudinalnu i transferzalnu melanonihiju, kada je pigmentacija prisutna u vidu

uzdužne ili poprečne pigmentne trake. Zato što uzdužna melanonihija može biti znak brojnih benignih i malignih promena, ona često predstavlja dijagnostički izazov dermatolozima. Prikazujemo trinaestogodišnju pacijentkinju kojoj se pojavila uzdužna melanonihija na više nokatnih ploča, a nakon terapije azitromicinom.

Ključne reči: Azitromicin; Bolesti noktiju; Melanom; Dermoskopija; Hiperpigmentacija; Poremećaji pigmentacije; Adolescenti

Received 15 December, 2018

Accepted 20 December, 2018