

Trans-catheter valve-in-valve implantation with a novel balloon expandable device in patients with bioprosthetic heart valve failure: A case series.

Alfonso Ielasi, Andrea Buono, Massimo Medda, Francesco Casilli, Marta Bande, Mariano Pellicano, Mattia Glauber, Francesco Donatelli, Maurizio Tespili



PII: S1553-8389(20)30768-5

DOI: <https://doi.org/10.1016/j.carrev.2020.11.018>

Reference: CARREV 2187

To appear in: *Cardiovascular Revascularization Medicine*

Received date: 31 August 2020

Revised date: 14 November 2020

Accepted date: 16 November 2020

Please cite this article as: A. Ielasi, A. Buono, M. Medda, et al., Trans-catheter valve-in-valve implantation with a novel balloon expandable device in patients with bioprosthetic heart valve failure: A case series., *Cardiovascular Revascularization Medicine* (2020), <https://doi.org/10.1016/j.carrev.2020.11.018>

This is a PDF file of an article that has undergone enhancements after acceptance, such as the addition of a cover page and metadata, and formatting for readability, but it is not yet the definitive version of record. This version will undergo additional copyediting, typesetting and review before it is published in its final form, but we are providing this version to give early visibility of the article. Please note that, during the production process, errors may be discovered which could affect the content, and all legal disclaimers that apply to the journal pertain.

Trans-catheter Valve-in-Valve Implantation with a Novel Balloon Expandable Device in Patients with Bioprosthetic Heart Valve Failure: A Case Series.

Alfonso Ielasi^{1*}, MD; Andrea Buono^{1*}, MD; Massimo Medda¹, MD; Francesco Casilli¹, MD;
Marta Bande¹, MD; Mariano Pellicano¹, MD, PhD, MSc; Mattia Glauber², MD; Francesco
Donatelli³, MD, PhD; Maurizio Tespil¹, MD

¹Clinical and Interventional Cardiology Unit, Istituto Clinico Sant'Ambrogio, Milan, Italy

²Minimally Invasive Cardiac Surgery Department, Istituto Clinico Sant'Ambrogio, Milan, Italy

³Department of Cardiac Surgery, University of Milan, Istituto Clinico Sant'Ambrogio, Milan, Italy

**equally contributed to the manuscript and are joint first author*

Running Title: MyVal-in-Valve experience

Word count: 1705

Acknowledgements and Funding: None

Disclosures: Authors have no conflicts of interest to declare.

Keywords: valve-in-valve; bioprosthetic heart valve; balloon-expandable trans-catheter heart valve; trans-catheter aortic valve implantation; mitral bioprosthesis; aortic bioprosthesis.

Address for correspondence:

Alfonso Ielasi, MD FESC;

Clinical and Interventional Cardiology Unit, Istituto Clinico S. Ambrogio,

Via Faravelli 16, 20149, Milan, Italy.

Tel: +39 02-33127714.

Fax: +39 02-33127717

alielasi@hotmail.com

Abstract

Trans-catheter valve-in-valve (ViV) is a treatment option for patients affected by bioprosthetic heart valve (BHV) failure. Both aortic and mitral ViV procedures present several challenges compared to native valve replacement. To date, no data concerning the balloon-expandable MyVal (Meril, Vapi, India) trans-catheter heart valve (THV) use in ViV procedure have been provided. In this case series, we described for the first time its use in five different BHV failures.

Journal Pre-proof

Introduction

Bioprosthetic heart valves (BHVs) are used to replace severely diseased native valves both by conventional surgery or by trans-catheter interventions. Usually patients implanted with BHVs are older, presenting with more comorbidities and, in case of previous trans-catheter implantation, with a not negligible surgical risk. The use of BHVs has significantly increased over the last decades. Compared to mechanical prosthesis, BHVs are subjected to an unavoidable structural degeneration. Given the continuing increase of life expectancy, a rapidly growing number of BHVs will require re-intervention in the next years.

Trans-catheter heart valve (THV) implantation with the valve-in-valve (ViV) technique has become a viable option for treatment of BHVs' failure in patients deemed ineligible for redo valve surgery because of unacceptable high surgical risk scores, severe comorbidities, frailty or patient's preference. Since first available evidence, aortic and mitral ViV procedures have demonstrated to be safe and effective. Nowadays the most commonly used THVs for ViV technique are Medtronic self-expanding (SE) and Edwards balloon-expandable (BE) valves (1).

The MyVal (Meril Life Science, Varanasi, India) is a new commercially available BE-THV designed for transcatheter aortic valve implantation (TAVI) (2) and it has recently obtained CE mark. Briefly, MyVal THV consists of a tri-leaflet valve of bovine pericardium mounted on a cobalt alloy frame with an internal polyester sealing cuff and an external polyester skirt. Compare to the other BE-THVs on the market (Sapien XT/3 THVs, Edwards Lifesciences, Irvine, California), multiple (from 20 mm to 32 mm in diameter) and half (21.5, 24.5 and 27.5 mm) sizes of MyVal THV are available. Furthermore, MyVal THV is directly crimped on the delivery system balloon, whereas the counterparts are crimped in a dedicated section of the delivery system just above the balloon with a further positioning on it only before THV implantation. So far, no randomized head-to-head trial comparing MyVal THV to other commercially available THVs in patients indicated for TAVI are available, despite data are expected in the next future (3).

To date, no data have proved MyVal safety and efficacy in the subset of ViV procedure, and in this scenario its use is still off-label.

We here report our initial experience in aortic and mitral trans-catheter ViV implantation using MyVal THV, describing short-term patients' outcome.

Case Series

BHV failure was defined according to the European consensus statement (4). Reoperation for BHV was indicated based on the Heart Team decision in symptomatic patients with a significant increase in trans-prosthetic gradient or severe regurgitation. Post-procedural prosthesis-patient mismatch (PPM) was defined according to the indexed effective orifice area (EOA) value as: haemodynamically insignificant when the EOA resulted more than $0.85 \text{ cm}^2/\text{m}^2$, moderate between 0.65 and $0.85 \text{ cm}^2/\text{m}^2$, and severe less than $0.65 \text{ cm}^2/\text{m}^2$ (5).

Four patients underwent aortic and one mitral ViV implantation. Main patients' characteristics are reported in **Table 1**. Peri-procedural data and in-hospital outcomes are shown in **Table 2 and Table 3**. All patients were treated by trans-femoral access.

As general consideration, MyVal implantation's depth was reached positioning the middle part of the second dense band at the level of the BHV's "annular plane" (**Figure 1**).

Case 1 (Figure 2A and Online Video 1)

A 73-year-old female, suffering from exertional dyspnea (NYHA class III) due to a stenotic degeneration of a 23-mm aortic Toronto SPV (St. Jude Medical, St. Paul, MN) BHV, was referred for a ViV procedure. The stentless design of this BHV, associated with a predefined low left coronary height (6.3 mm), exposed the patient to a not negligible risk of coronary obstruction (CO) during the ViV procedure. For this reason, a 23-mm MyVal BE-THV (8.3 mm closed cells' height) was chosen. Before ViV implantation, a 4.0x28 mm drug-eluting stent (DES) was positioned in the left coronary artery through a 6F EBU 3.5 guiding catheter (Medtronic). ViV procedure was

effectively performed (no need for THV post-dilatation) and followed by unprotected left main stenting using a “mini-Chimney” technique (consisting of minimal DES struts protrusion just above the upper edge of the BE-THV) to prevent a subacute or delayed CO (6). Because of a haemoglobin drop of 3 g/dL, due to a procedural bleeding, administration of two units of blood was required. No major complications occurred during hospitalization and the patient was discharged after 6 days with 3-month dual antiplatelet therapy.

Case 2 (Figure 2B and Online Video 2)

A 80-year-old female with atrial fibrillation, reduced left ventricle ejection fraction (LVEF) and a degenerated 25-mm stentless Freestyle (Medtronic, Minneapolis, MN, USA) BHV was referred to our Institution for a ViV procedure. As in *Case 1*, the risk of CO was a main concern for the procedure together with a low LVEF. In order to favour a fast implant and a safe coronary access, a 23-mm MyVal BE-THV was chosen. Before ViV implantation a coronary guide wire and a DES were placed in the left coronary artery. ViV was successfully performed and, in contrast to *Case 1*, stent implantation was not needed, given both the wide distance between the left sinus of Valsalva and the MyVal THV frame and the relatively high left coronary ostium take-off (10 mm). No in-hospital complications occurred, and the patient was discharged on oral anticoagulation therapy (OAT).

Case 3 (Figure 2C and Online Video 3)

A 77-year-old female treated 4 years before with surgical (right anterior mini-thoracotomy approach) aortic valve replacement (AVR) with a Perceval sutureless M (Livanova, Milan, Italy) BHV, was referred for ViV evaluation because of heart failure and BHV calcific degeneration with significant paradoxical low-flow low-gradient stenosis. Due to a prohibitive surgical risk (STS mortality score 11.2%), a ViV procedure was planned. To reduce the potential risk of attrition between the THV and the metallic struts of the upper crown of the degenerated Perceval BHV, a

24.5-mm MyVal THV with a deflectable delivery system was chosen. ViV was effectively performed and no major complications occurred. The patient was discharged two weeks later on single antiplatelet therapy.

Case 4 (Figure 2D and Online Video 4)

A 87-year-old female with permanent atrial fibrillation and a failed 26-mm Sapien XT (Edward Life Science, Irvine, CA, USA) THV implanted percutaneously 8 years before was referred for ViV procedure. In this case, a 24.5-mm MyVal THV was chosen and successfully implanted. Post-procedural echocardiographic assessment confirmed the adequate new BHV's function. Only a minor vascular access site hematoma, requiring blood transfusion, occurred. The patient was discharged 9 days after the procedure on OAT.

Case 5 (Figure 2E and Online Video 5)

A 79-year-old female presented with symptomatic heart failure (NYHA class III) and severe mitral regurgitation, due to a failed 29-mm Biocor (St. Jude Medical, St. Paul, MN) BHV surgically implanted 10-year-before concomitantly with AVR. For this patient, a 27.5-mm MyVal THV was chosen. Through left trans-femoral venous access, trans-septal puncture was done. The degenerated BHV was crossed with a 0.035" wire supported by a steerable sheath (Agilis, St. Jude Medical, St. Paul, MN). To increase support, two Safari Guidewires (Boston Scientific, Boston, MA) were positioned in the left ventricle and atrial septum pre-dilation was performed to facilitate the THV's advancement. Identifying the proper implantation height was challenging, due to the very low Biocor BHV radiopacity. Final ViV implantation in the mitral valve's position was effective (trivial post-implantation paravalvular leak) but mini-invasive surgical repair of an apical left ventricle pseudoaneurysm was needed. The patient was discharged two weeks later.

Discussion

Trans-catheter ViV technique is now considered the first-line therapy for failed BHV in patients deemed unsuitable for conventional redo surgery. Despite being effective and safe, ViV procedure has been associated with more challenges compared to trans-catheter treatment of diseased native valves.

For instance in aortic ViV implantation the main potential adverse events are high post-procedural residual gradient and CO. Regarding the latter risk subset, upfront coronary protection and subsequent stenting might be required, especially in presence of a stented BHV with leaflets mounted externally or a stentless BHV, being both valve designs at higher risk of CO (7). Regarding the mitral ViV replacements, the key aspects for successful implantation are correct sizing and proper implantation height, aimed to reduce the risk of device's atrial migration or left ventricular outflow tract obstruction.

To the best of our knowledge, we described the first experience of ViV procedures using the MyVal BE-THV. In this context, the use of MyVal THV appeared to be feasible, and effective, with no device failure observed during in-hospital period. Moreover, the device has addressed a clinical need in different settings (aortic and mitral degeneration), occurred in patients affected by degenerated BHVs of different types and designs. Similarly to the other available BE-THVs (e.g. Edwards Sapien XT/3), an intuitive advantage of MyVal THV use (versus supra-annular SE THVs) in the ViV scenario might be the lower CO risk, given the short height of the closed cells in the ventricular end and the presence of open cells on the aortic end to ensure unjailing of coronary ostia. This feature is of paramount importance during ViV procedure of degenerated stentless or stented with leaflets mounted externally. In case of prohibitive CO risk, the use of MyVal THV with its shorter frame's height compare to SE-THVs, allows to perform a prophylactic coronary stenting with minimal struts protrusion immediately above the upper THV edge ("mini-Chimney"). This approach, feasible with a BE-THV, may minimize the risk of stent's struts compression/distortion due to the more extensive interaction between the SE-THV and the coronary

stent. Furthermore, the deflectable tip of the Navigator delivery system enhances fine control during MyVal THV navigation and positioning. This characteristic allowed us to minimize the potential attrition between MyVal THV and the upper crown of the degenerated Perceval BHV in *Case 3*, reaching a proper THV delivery. Lastly, the availability of MyVal THV half-sizes (namely 21.5, 24.5, 27.5 mm), may increase the therapeutic options to minimize the higher PPM risk associated with the use of intra-annular prosthesis in ViV scenario: in fact, in our case series we did not observe any haemodynamically significant PPM.

Our results using a novel BE-THV for ViV are encouraging, and in line with recent real-world evidences (8). Nevertheless, larger numbers and longer-term follow-up are strongly needed.

Conclusion

Transcatheter aortic and mitral ViV for failed PHV using MyVal THV appears to be technically feasible and safe, with device success achieved in all the presented five cases.

References

- 1) Ye J, Cheung A, Yamashita M, Wood D, Peng D, Gao M, et al. Transcatheter Aortic and Mitral Valve-in-Valve Implantation for Failed Surgical Bioprosthetic Valves: An 8-Year Single-Center Experience. *JACC Cardiovasc Interv.* 2015;8:1735-44.
- 2) Sharma SK, Rao RS, Chandra P, Goel PK, Bharadwaj P, Joseph G, et al. First-in-Human Evaluation of Balloon Expandable Transcatheter Heart Valve in the Treatment of Severe Symptomatic Native Aortic Stenosis: The MyVal-1 Study. *EuroIntervention.* 2020;16:421-429.
- 3) Kawashima H, Soliman O, Wang R, Ono M, Hara F, Gao C, et al. Rationale and design of a randomized clinical trial comparing safety and efficacy of Myval transcatheter heart valve versus contemporary transcatheter heart valves in patients with severe symptomatic aortic valve stenosis: the LANDMARK trial. *Am Heart J.* 2020:S0002-8703(20)30368-9.
- 4) Capodanno D, Petronio AS, Prendergast B, Eltchaninoff H, Vahanian A, Modine T, et al. Standardized definitions of structural deterioration and valve failure in assessing long-term durability of transcatheter and surgical aortic bioprosthetic valves: a consensus statement from the European Association of Percutaneous Cardiovascular Interventions (EAPCI) endorsed by the European Society of Cardiology (ESC) and the European Association for Cardio-Thoracic Surgery (EACTS). *Eur Heart J.* 2017;38:3382-3390.
- 5) Kappetein AP, Head SJ, Généreux P, Piazza N, van Mieghem NM, Blackstone EH, et al. Updated standardized endpoint definitions for transcatheter aortic valve implantation: the Valve Academic Research Consortium-2 consensus document. *EuroIntervention.* 2012;8:782-95.
- 6) Mangieri A, Gallo F, Popolo Rubbio A, Casenghi M, Ancona M, Regazzoli D, et al. Outcome of Coronary Ostial Stenting to Prevent Coronary Obstruction During Transcatheter Aortic Valve Replacement. *Circ Cardiovasc Interv.* 2020;13:e009017.

- 7) Mercanti F, Rosseel L, Neylon A, Bagur R, Sinning JM, Nickenig G, et al. Chimney Stenting for Coronary Occlusion During TAVR: Insights From the Chimney Registry. *JACC Cardiovasc Interv.* 2020;13:751-761.
- 8) Hirji SA, Percy ED, Zogg CK, Malarczyk A, Harloff MT, Yazdchi F, et al. Comparison of in-hospital outcomes and readmissions for valve-in-valve transcatheter aortic valve replacement vs. reoperative surgical aortic valve replacement: a contemporary assessment of real-world outcomes *Eur Heart J.* 2020;41:2747-2755.

Figures, Tables and Videos legends

Figure 1. MyVal implantation's depth in the 5 cases described. In the upper left box, a schematic configuration of MyVal THV, presenting with four angiographic dense and three angiographic light bands. In the upper right box, angiographic MyVal THV appearance (red arrow indicating the second dense band). MyVal THV has to be inflated when the middle part of the second dense band (represented by red box in the lower images' row) reaches the level of failed BHV's virtual basal ring (dashed lines in the 5 cases' angiograms). THV: trans-catheter heart valve; BHV: bioprosthetic heart valve.

Figure 2. Failed BHV, its CT appearance and angiographic frames of main ViV procedure phases of presented 5 cases (indicated by letter A to E). BHV: bioprosthetic heart valve; CT: computed tomography; ViV: Valve-in-valve.

Table 1. Patients' Baseline Characteristics

Case	Age (yrs)	Sex	BMI	STS-PROM (%)	Logistic Euro-SCORE II (%)	NYHA Class	LVEF (%)	Severe Pulmonary Hypertension	Diabetes Mellitus	Arterial Hypertension	CAD	Atrial Fibrillation	GFR (ml/min)
1	73	F	33,2	2,5	11	2	60	no	yes	yes	no	no	59
2	80	F	21,3	8,4	10,74	3	36	no	no	yes	yes	yes	93
3	77	F	27,7	11,19	26	4	60	no	no	yes	yes	no	24
4	87	F	20,1	2,93	3,25	2	56	yes	no	yes	yes	yes	53
5	79	F	31,6	4,98	11	3	55	yes	no	yes	no	yes	32

BMI: body mass index; STS-PROM: Society of Thoracic Surgeons Predicted Risk of Mortality; NYHA: New York Heart Association; LVEF: Left ventricle ejection fraction; CAD: coronary artery disease. GFR: glomerular filtration rate.

Table 2. Valve-in-Valve Peri-Procedural Data

Case	Failed prosthesis type	Size	Age (ys)	Failure mode	Leaflets Calcification Grade (0-3)	Internal mean diameter	CT annulus area (mm ²)	CT perimeter area (mm)	Access site	General anesthesia	ViV size (mm)	AVA (mm ²)	Transvalvular gradient mean		Valve regurgitation grade (0-4)		Pre-dilatation	Post-dilatation	CP
													Pre	Post	Pre	Post			
1	Toronto SPV	23	25	AS	3	23	415	72,9	TF	no	22	0,7	49	16	1	0	yes	no	yes
2	Freestyle	25	20	AS/AR	2	20,9	342	66,7	TF	no	23	0,9	38	12	3	2	yes	no	yes
3	Perceval	M	4	AS	2	18	241	56,6	TF	no	24,5	0,90	27	18	0	0	no	no	no
4	Sapien XT	26	8	AS/AR	3	22	376	69	TF	no	24,5	0,9	42	11	2	0	no	no	no
5	Biocor	29	10	MR	NA	NA	NA	NA	TF	yes	27,5	NA	8	2	4	1	no	no	na

CT: computed-tomography; ViV: Valve-in-Valve; AVA: aortic valve area; TF: trans-femoral; CP: coronary protection.

Table 3. In-Hospital Outcomes

Patient	Need of permanent PM	Bleeding (BARC)	VARC-2 Complications	PPM (indexed EOA, cm ² /m ²)	Stroke/TIA	Peri-procedural MI	Hospitalization length (days)	Discharge therapy
1	no	3a	no	no (1,13)	no	no	6	DAPT
2	no	no	no	no (1,36)	no	no	3	NOAC
3	no	3a	no	no (1,07)	no	no	15	SAPT
4	no	2	minor	no (1,32)	no	no	9	VKA
5	no	3a	major	na	no	no	15	VKA

PM: pacemaker; BARC: Bleeding academy research consortium; VARC: vascular academy research consortium; PPM: prosthesis-patient mismatch; EOA: effective orifice area; TIA: transient ischemic attack; DAPT: dual antiplatelet therapy; NOAC: non-vitamin K antagonist oral anticoagulant; SAPT: single antiplatelet therapy; VKA: Vitamin-K antagonist.

Online Video 1 – Case 1 ViV implantation video

Online Video 2 – Case 2 ViV implantation video

Online Video 3 – Case 3 ViV implantation video

Online Video 4 – Case 4 ViV implantation video

Online Video 5 – Case 5 ViV implantation video

Journal Pre-proof

Highlights

- To date, no data have been provided concerning the use of the novel commercially available balloon-expandable MyVal (Meril, Vapi, India) trans-catheter heart valve (THV) in the valve-in-valve (ViV) scenario
- In our preliminary experience, MyVal THV demonstrated to be feasible and effective to treat failure of different degenerated bioprosthetic heart valves.
- In ViV procedure, MyVal THV can be a valid treatment choice in order to reduce the risk of coronary obstruction.

Journal Pre-proof

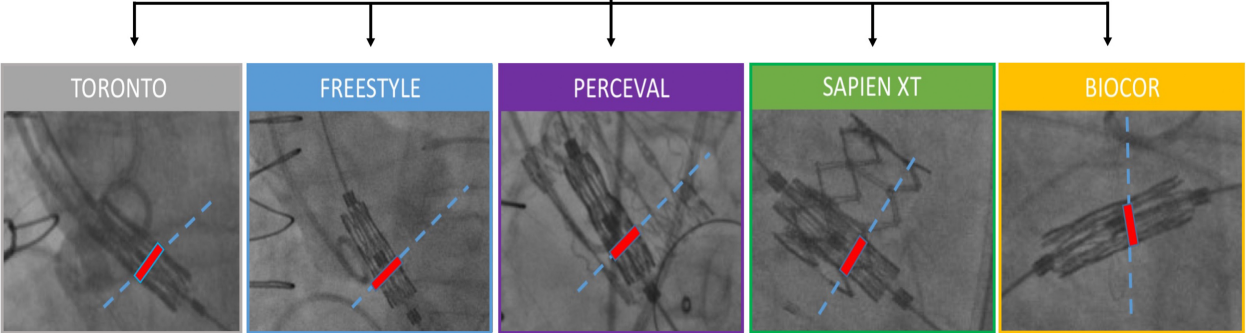
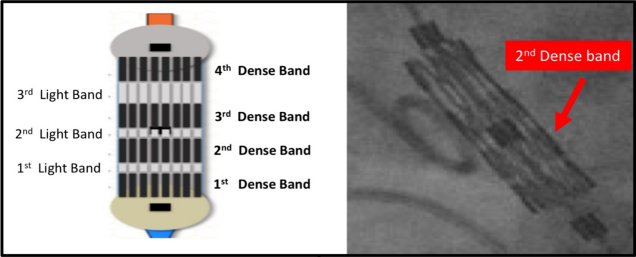


Figure 1

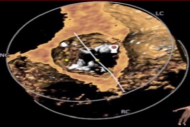
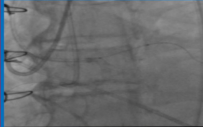
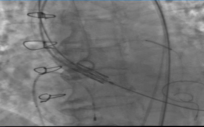
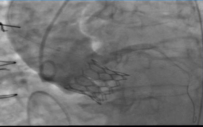
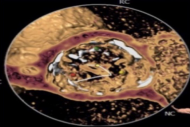
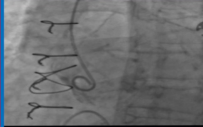

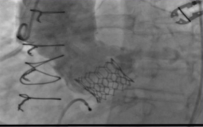
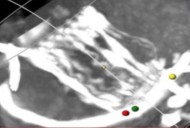
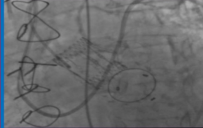
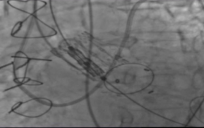
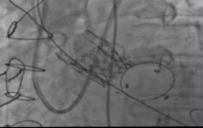
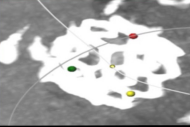
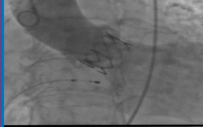
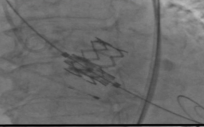
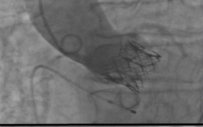

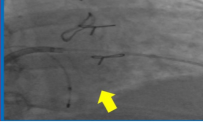
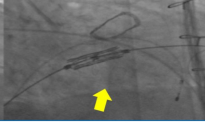

Prosthetic valve		CT assessment	Pre-implantation	Implantation	Post-implantation
A	Toronto SPV Stentless 23 (St. Jude Medical)				
B	Freestyle Stentless 25 (Medtronic)				
C	Perceval Sutureless M (Livanova)				
D	Sapien XT 26 (Edwards)				
E	Biocor Stented 29 (St. Jude Medical)				

Figure 2