



Considerations
for Pso and PsA
telemedicine
in the time of
COVID-19, and its
impact for clinicians
and patients

CONFRONTING CHALLENGES FOR THE **PEACE** WITHIN

Discover groundbreaking insights from leading experts, with videos, articles and more >



Furthermore, the present patient showed unique reticular hyperkeratotic eruptions on the forearms. In the literature, we were unable to find any reports of similar eruptions in DD patients. Although a nonsense mutation of the same amino acid, p.Tyr122X, has been reported,⁵ no substitution mutation of Tyr122 has been described previously. Thus, we cannot assess genotype/phenotype correlations concerning the clinical features of patients with substitution mutations of Tyr122. We hypothesize that some genetic and/or environmental modifying factors might have contributed to the development of the unique reticular arrangement of her DD lesions. The patient's hyperkeratotic DD lesions were itchy. The forearms are easily accessible regions, and the present patient with ADHD seemed to scratch the skin eruptions on the forearm frequently. We speculate that this intense scratching might have led to Köbner phenomenon, resulting in the unique reticular pattern of the hyperkeratotic lesions in the present DD case with ADHD.

Funding source: This work was supported by funding from Advanced Research and Development Programs for Medical Innovation (AMED-CREST) 19gm0910002 h0105 to M.A. from the Japan Agency for Medical Research and Development (AMED). This work was also supported by Grant-in-Aid for Scientific Research (B) 18H02832 to M.A., and by Grant-in-Aid for Young Scientists 18K16058 to T.T. from the Japan Society for the Promotion of Science (JSPS). This investigation was supported in part by The Mochida Memorial Foundation for Medical and Pharmaceutical Research and The Uehara Memorial Foundation.

T. Yoshikawa,¹ T. Takeichi,^{1,*} Y. Suga,² Y. Kitajima,³ M. Akiyama^{1,*}

¹Departments of Dermatology, Nagoya University Graduate School of Medicine, Nagoya, Japan, ²Department of Dermatology, Juntendo University Urayasu Hospital, Urayasu, Japan, ³Department of Dermatology, Kizawa Memorial Hospital, Minokamo, Japan

*Correspondence: T. Takeichi (TT) and M. Akiyama (MA). E-mails: takeichi@med.nagoya-u.ac.jp (TT); makiyama@med.nagoya-u.ac.jp (MA)

References

- 1 Sakuntabhai A, Ruiz-Perez V, Carter S *et al*. Mutations in ATP2A2, encoding a Ca²⁺ pump, cause Darier disease. *Nat Genet* 1999; **21**: 271–277.
- 2 Jacobsen NJ, Lyons I, Hoogendoorn B *et al*. ATP2A2 mutations in Darier's disease and their relationship to neuropsychiatric phenotypes. *Hum Mol Genet* 1999; **8**: 1631–1636.
- 3 Takeichi T, Sugiura K, Nakamura Y *et al*. Darier's disease complicated by schizophrenia caused by a novel ATP2A2 mutation. *Acta Derm Venereol* 2016; **96**: 993–994.
- 4 Cederlof M, Bergen SE, Langstrom N *et al*. The association between Darier disease, bipolar disorder, and schizophrenia revisited: a population-based family study. *Bipolar Disord* 2015; **17**: 340–344.
- 5 Sakuntabhai A, Burge S, Monk S *et al*. Spectrum of novel ATP2A2 mutations in patients with Darier's disease. *Hum Mol Genet* 1999; **8**: 1611–1619.

DOI: 10.1111/jdv.15892

Suspected eosinophilic pustular folliculitis presenting as rapidly evolving acneiform eruption

Editor

A 48-year-old African man presented to our Department of Dermatology, complaining of itchy papules and pustules rapidly spreading to cover the entire face (Fig. 1a and b). Dermatological assessment revealed several sterile follicular itchy papulo-pustules arranged in annular clusters and superimposed in plaques, with a tendency for central clearing and peripheral expansion, on an erythematous lacquered base mainly located on the face. Lesions healed without scarring leaving hyperpigmentation. There were no signs of lymphadenopathy, hepatosplenomegaly or petechiae. Preliminary laboratory tests demonstrated a mild leucocytosis (12.4×10^9 per L) and mild eosinophilia (804/ μ L); however, no haematological abnormalities were present on the peripheral smear. Serological testing for HIV, hepatitis B and C was negative. The patient was stable and immunocompetent. Histopathologic examination of a non-excoriated fresh papule revealed several mature eosinophils infiltrating the pilosebaceous unit with scattered neutrophils and monocytes. A diagnosis of eosinophilic pustular folliculitis (EPF) or papuloerythroderma (PEO) of Ofuji, classical type was established. Rapid improvement of lesions was noted within four weeks of systemic indometacin 75 mg/day combined with narrow band UVB (NB UVB). NB UVB phototherapy was administered thrice weekly on non-consecutive days, and the initial dose corresponded to 70% of the NB UVB MED. No recurrences were noted after 1 year of follow-up. Classic EPF is a rare dermatosis first described in Japanese population, characterized by coalescence of brownish papules developing the typical erythroderma not involving the skin folds and giving rise to the so-called deck-chair sign. Pruritus, lymphopenia and eosinophilia are commonly associated.¹ The aetiology of this disorder is still unknown but an association with acute lymphatic leukaemia, B and T lymphomas as well as visceral tumours have been reported.^{2,3} Reports of EPF occurring in Africans are even less common. The classical form affects immunocompetent patients and starts with papulo-pustules on the face rarely spreading to trunk. Immunosuppressed patients develop erythematous annular raised large follicular itchy pustules. The differential diagnosis includes conditions from banal acne to follicular mycosis fungoides.⁴ Several treatments have been proposed including topical/systemic steroids, PUVA, UVB, retinoids, cyclosporine and interferon alpha with different results.⁵ Considering the side-effects of PUVA and also the positive results obtained in the first report attesting the effectiveness of UVB in EPF in six patients with acquired immunodeficiency syndrome,⁶ we decided to treat our immunocompetent patient with NB UVB.

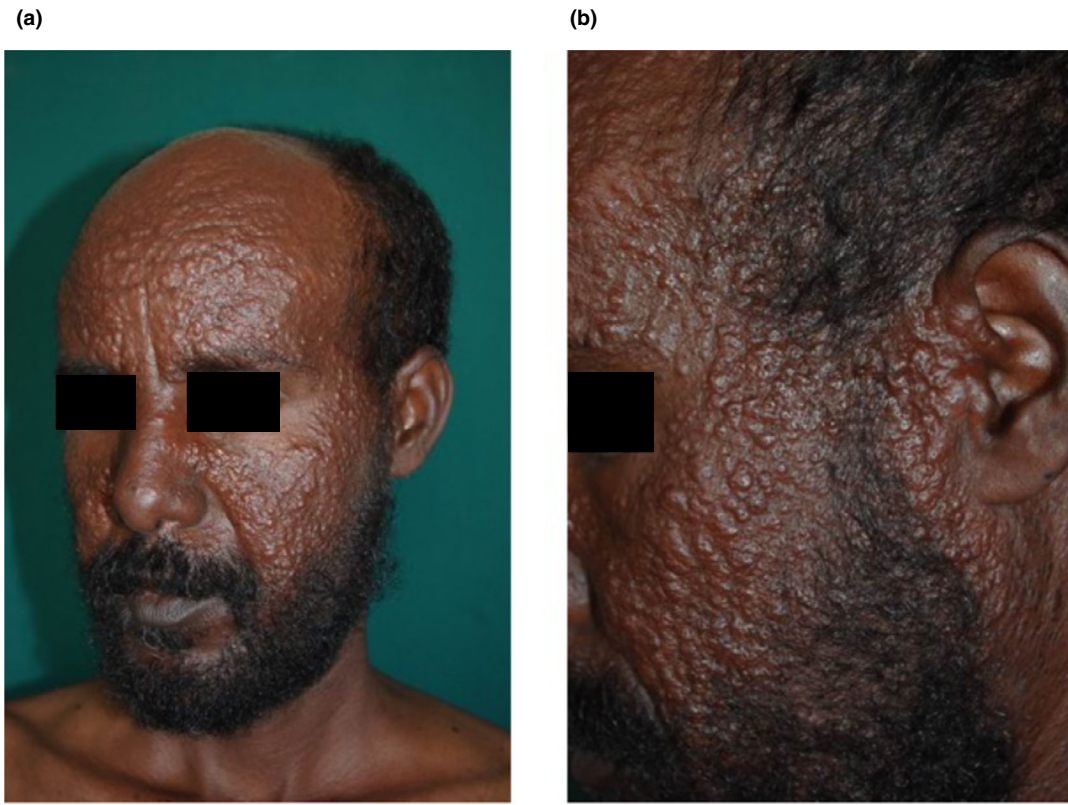




Figure 1 Papulopustular eruption limited to the face (a). The follicular lesions present an annular pattern with the tendency of central resolution (b).

Our case suggests that despite its rarity, EPF should be taken into account in case of a recurrent pustular itchy rash and that phototherapy with NB UVB could be a successfully and safe treatment option.

G. Damiani,^{1,2,3,†} A. Pacifico,^{4,*†}  A. Scarabello,⁴
P. Iacovelli,⁴ R.R.Z. Conic,³  A. Morrone⁴

¹Young Dermatologists Italian Network (YDIN), GISED, Bergamo, Italy,

²Clinical Dermatology, Department of Biomedical, Surgical and Dental Sciences, IRCCS Galeazzi Orthopaedic Institute, University of Milan,

Milan, Italy, ³Department of Dermatology, Case Western Reserve University, Cleveland, USA, ⁴San Gallicano Dermatological Institute, IRCCS, Rome, Italy

*Correspondence: A. Pacifico. E-mail: alessia.pacifico@gmail.com

[†]Equally contributed.

2 Wong CJ, Houghton JB, Andrew S, Griffiths CEM. Papuloerythroderma of Ofuji associated with acute myeloid leukaemia. *Clin Exp Dermatol* 2003; **28**: 277–279.

3 Nomura T, Kodama K, Moriuchi R *et al.* Papuloerythroderma of ofuji associated with early gastric cancer. *Int J Dermatol* 2008; **47**: 590–591.

4 Martinez-Barranca ML, Munoz-Perez MA, Morales-Garcia I, Fernandez-Crehuet JL, Sefura J, Camacho F. Ofuji papuloerythroderma evolving to cutaneous T-cell lymphoma. *J Eur Acad Dermatol Venereol* 2005; **19**: 104–106.

5 Mutluer S, Yerebakan O, Alpsoy E, Ciftcioglu MA, Yilmaz E. Treatment of papuloerythroderma of Ofuji with Re-PUVA: a case report and review of the therapy. *J Eur Acad Dermatol Venereol* 2004; **18**: 480–483.

6 Buchness MR, Lim HW, Hatcher VA, Sanchez M, Soter NA. Eosinophilic pustular folliculitis in the acquired immunodeficiency syndrome. Treatment with ultraviolet B phototherapy. *N Engl J Med* 1988; **318**: 1183–1186.

DOI: 10.1111/jdv.15893

References

1 Aste N, Fumo G, Conti B, Biggio P. Ofuji papuloerythroderma. *J Eur Acad Dermatol* 2000; **14**: 55–57.