

Injuries to the Collateral Ligaments of the Metacarpophalangeal and Interphalangeal Joints

Sonographic Appearance

Ferdinando Draghi, MD, Salvatore Gitto, MD , Stefano Bianchi, MD 

Injuries to the collateral ligaments of the metacarpophalangeal (MCP) and interphalangeal (IP) joints are commonly encountered in both athletes and nonathletes. They require prompt evaluation to ensure proper management and prevent loss of joint motion and permanent disability. Imaging is often required to confirm the diagnosis and assess injury severity. This review article aims to provide physicians with guidelines for sonographic assessment of the collateral ligaments of the MCP and IP and related injuries. Sonographic features of ligament injuries ranging from sprains and partial-thickness tears to full-thickness tears are described. Specific lesions of the ulnar collateral ligament of the thumb MCP joint, such as gamekeeper's thumb, skier's thumb, and Stener lesions, are also included. In conclusion, sonography is effective in evaluating the collateral ligaments of the MCP and IP joints and related injuries and represents a valuable tool for diagnosis.

Key Words—collateral ligament; finger; hand; musculoskeletal imaging; sonography; thumb

Received September 11, 2017, from the Radiology Institute, Fondazione Istituto di Ricovero e Cura a Carattere Scientifico Policlinico San Matteo, Università Degli Studi di Pavia, Pavia, Italy (F.D.); Postgraduate School in Radiodiagnosics, Università Degli Studi di Milano, Milan, Italy (S.G.); and Cabinet Imagerie Médicale, Geneva, Switzerland (S.B.). Manuscript accepted for publication December 9, 2017.

Address correspondence to Salvatore Gitto, MD, Postgraduate School in Radiodiagnosics, Università Degli Studi di Milano, Via Festa del Perdono 7, 20122 Milan, Italy.

E-mail: sal.gitto@gmail.com

Abbreviations

DIP, distal interphalangeal; IP, interphalangeal; MCP, metacarpophalangeal; PIP, proximal interphalangeal; RCL, radial collateral ligament; UCL, ulnar collateral ligament

doi:10.1002/jum.14575

Hand injuries are commonly encountered in both athletes, accounting for up to 15% of all sports injuries, and nonathletes.^{1,2} Ball handling and contact sports (eg, football, rugby, and basketball) as well as activities with a high risk of falling (eg, skiing, skating, biking, and gymnastics) represent risk factors for injury.^{3,4} The collateral ligaments of the metacarpophalangeal (MCP) and interphalangeal (IP) joints are frequently involved, and the number of chronic lesions reported in the literature highlights the large number of cases overlooked at the first visit.⁵⁻⁷

The diagnosis of collateral ligament injuries of the MCP and IP joints often relies on a physical examination. Imaging is of great help in challenging cases and in the assessment of injury severity, thus ensuring the appropriate management.⁸ The value of imaging is particularly important if joint stability is compromised, particularly in athletes, to prevent loss of joint motion and residual deformities.⁹ As a time-saving and cost-effective imaging modality that allows for a comparative, dynamic, and focused examination of small superficial structures with high resolution, sonography is valuable for assessing the collateral ligaments in the thumb and fingers.¹⁰⁻¹² This review article aims to provide physicians with simple and systematic guidelines for sonographic evaluations of the collateral ligaments of the MCP and IP joints and related injuries. These guidelines were

generated from our centers' experience in combination, as indicated by the references in the text, with a thorough analysis of the literature since 2000 to the present. A systematic search of the literature was conducted in PubMed using the key words "collateral ligament" combined with "hand", "thumb," and "finger" and with "ultrasound," "imaging," and "sonography." The references of the identified publications were also checked. Original studies and review articles in English dealing with the sonographic description of the collateral ligaments of the MCP and IP joints and related injuries were selected. Case reports and case series were included according to clinical relevance.

Normal Anatomy and Biomechanics

The MCP joints are synovial condyloid joints that allow movements in the sagittal and coronal planes: ie, flexion/extension and adduction/abduction, respectively, and circumduction.¹³⁻¹⁵ The range of motion at the MCP joint of the thumb is the most variable in the human body, and higher stability is required to resist lateral stress during grasping and pinching.^{16,17} The IP joints of the thumb and fingers are synovial, uniaxial hinge joints that allow motion only in the sagittal plane: ie, flexion and extension.¹⁴ Both static and dynamic structures stabilize the joints of the thumb and fingers. Static stabilizers include the collateral ligament–volar plate complex and the pulley system; the deep transverse metacarpal ligament and the extensor hoods also reinforce the MCP joint capsule. Intrinsic and extrinsic muscles and tendons act as dynamic stabilizers.¹⁴

The radial collateral ligament (RCL) and the ulnar collateral ligament (UCL) are the main stabilizers of the MCP and IP joints (Figure 1). They reinforce and thicken the fibrous capsule on both sides of each joint.¹⁸ Each collateral ligament consists of a proper and an accessory bundle. The proper collateral ligaments of the MCP joints insert proximally into the posterior tubercle and adjacent pit on the side of the metacarpal heads. Similarly, the proper collateral ligaments of the proximal interphalangeal (PIP) and distal interphalangeal (DIP) joints insert proximally into the lateral aspect of the heads of the proximal and middle phalanges, respectively. The proper collateral ligaments of the MCP, PIP, and DIP joints extend anterodistally in a slightly oblique course and insert into the volar aspect of the bases of the proximal, middle, and distal phalanges, respectively. The

distal insertion is slightly broader than the proximal one. The accessory collateral ligaments of the MCP, PIP, and DIP joints are close but more volarly located than the adjacent proper bundles. They run in a similar fashion as the proper collateral ligaments and attach distally to the volar plate.^{14,19,20} In the thumb, the UCL of the MCP joint (Figure 1B) is peculiar, as it is covered and strengthened by the adductor pollicis aponeurosis, which lies palmar on the ulnar side of the joint and inserts into the extensor hood.²¹ The proper and accessory collateral ligaments function antagonistically. Specifically, the proper bundles are taut in flexion and limit translational movements in the coronal plane. The accessory bundles are taut in extension and prevent frontal deviation.²²

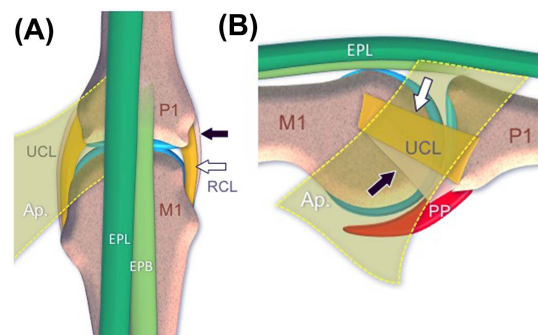
General Features of Collateral Ligament Injuries

Injuries to the collateral ligaments of the MCP and IP joints range from sprains and partial-thickness tears to complete or full-thickness tears. These lesions are complex and may be associated with joint effusion, avulsion fractures, bone dislocations, and various degrees of involvement of the volar plate and extensor tendons.²³

Metacarpophalangeal Joint of the Thumb

Among the collateral ligaments of the MCP joints in the hand, the UCL of the thumb is the most common site

Figure 1. Schemes of the thumb MCP joint. **A.** On a dorsal view, the RCL and UCL are depicted on the radial and ulnar joint sides, respectively, and consist of proper (shown in yellow and indicated by the white arrow) and accessory (shown in peach and indicated by the black arrow) bundles. Note their relationship with the adductor pollicis aponeurosis (Ap, shown as a semitransparent yellow layer) and the extensor pollicis brevis (EPB) and extensor pollicis longus (EPL) tendons. Articular cartilage is shown in light blue. **B.** On a sagittal view of the ulnar joint side, the volar plate (PP, shown in red) is also shown. M1 indicates metacarpal; and P1, proximal phalanx.



of lesions.²⁴ Injuries to the UCL occur when a forced abduction accompanied by varying degrees of hyperextension is applied to the thumb MCP joint.²⁵ They may be either acute or chronic. Chronic injuries result from repeated microtrauma with radial stress, which renders the UCL lax and nonfunctional. This condition is known as “gamekeeper’s thumb,” as it was originally described in Scottish gamekeepers who strangled rabbits by stretching their necks between the thumb and the index finger.²⁶ More frequently nowadays, UCL injuries present in the acute setting and result from a sudden hyperabduction of the thumb MCP joint. This condition is termed “skier’s thumb,” as it is typically encountered in skiers, and it is related to the grip and restraint strap position while holding the ski poles during a fall.²⁷ Contact sports such as football and rugby can also be implicated.²⁸ Distal injuries account for 90% of cases.²⁹ Three types of lesions are recognized (Figure 2): (1) an avulsion injury at the distal ligament attachment, which may result in a displaced or nondisplaced fracture of the proximal phalanx base; (2) a midsubstance partial- or full-thickness tear, in which the ligament stumps remain in their anatomic position, deep to the adductor pollicis aponeurosis; and (3) Stener lesions.²⁹ In a Stener lesion, the UCL ruptures, and its proximal stump is trapped superficial or proximal to the proximal edge of the intact adductor pollicis aponeurosis. The interposition of this aponeurosis between the ligament stumps prevents primary healing and thus represents an indication for surgical repair.³⁰ Stener lesions are found in 64% to 87% of full-thickness tears.²⁷

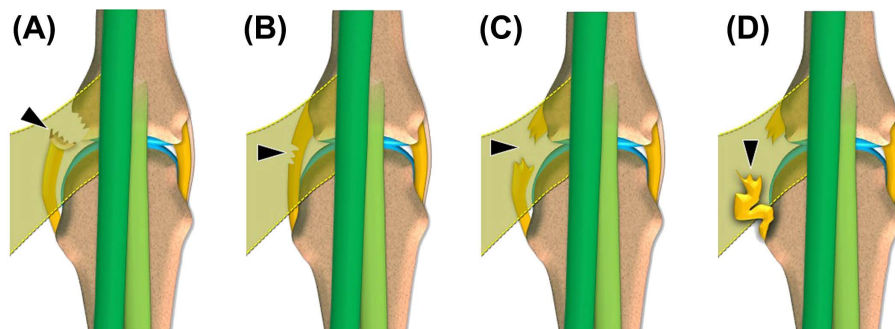
Radial collateral ligament injuries represent 10% to 40% of collateral ligament injuries of the thumb MCP joint.³¹ Simultaneous tears of the RCL and UCL have also been described.³² Radial collateral ligament injuries typically result from a forced and sudden adduction of the thumb MCP joint due to a sports-related trauma, mostly in ball-handling sports, or falls.^{33,34} Based on their location, they are proximal in 55% of cases, midsubstance in 16% of cases, and distal in 29% of cases.³¹ Unlike on the ulnar side, the aponeurosis of the abductor pollicis brevis covers the RCL entirely, thus precluding any proximal and superficial displacement in the case of rupture.²⁹

In the acute setting, traumatic injuries of the collateral ligaments present with pain and swelling over the affected side of the thumb MCP joint. Chronically, patients have weakness while grasping an object, writing, or turning a key. The physical examination may reveal a radiovolar or ulnovolar dislocation of the proximal phalanx in the case of disruption of the UCL and RCL, respectively. Such joint incongruity is a risk factor for degenerative arthritis.^{33,35} Treatment is usually conservative in the case of nondisplaced injuries and surgical in displaced ones.²⁵

Metacarpophalangeal Joints of the Fingers

Injuries to the collateral ligaments of the MCP joints are less common in the fingers than in the thumb. Specifically, these injuries account for 39% of cases, considering the fingers as a whole.³⁶ A radially or ulnarly directed palmar-to-dorsal force typically represents the

Figure 2. Schemes of the types of UCL injuries in the thumb MCP joint. **A.** Avulsion injury at the distal ligament attachment resulting in a fracture (arrowhead) of the proximal phalanx base. **B.** Midsubstance partial-thickness tear (arrowhead). **C.** Midsubstance full-thickness tear (arrowhead). In these 3 cases, the ulnar collateral ligament remains in its anatomic position, deep to the adductor pollicis aponeurosis. **D.** Stener lesion: ie, UCL rupture in which the proximal ligament stump (arrowhead) is displaced proximal to and superficial to the proximal edge of the adductor pollicis aponeurosis.



mechanism of trauma.³⁷ The UCL is most frequently affected in the index finger, reflecting the protective role against ulnar stress that the middle finger exerts. Conversely, RCL injuries occur most commonly in the ring and little fingers. No side predominance exists in the middle finger.^{36,37} Incidentally, a Stener-like lesion may occur in the finger MCP joints. In these cases, the collateral ligament ruptures, and its stump is trapped superficially by an open window of the injured sagittal band.^{38,39}

Clinical findings include swelling and local pain in the acute setting and instability while grasping objects. Misalignment in the coronal plane during finger extension is usually suggestive of a full-thickness tear.⁴⁰ Even though conservative treatment is successful in most cases, severe joint instability or displacement of the torn ligament may require surgical repair.^{38,41}

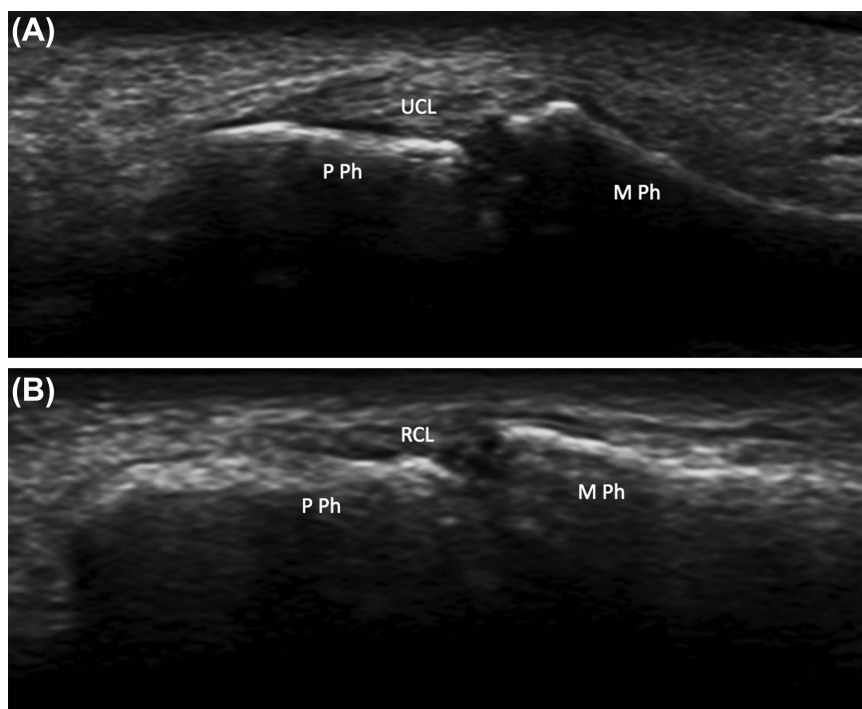
Interphalangeal Joints

The PIP joints represent the most common sites of ligament injuries in the fingers.^{19,42} Conversely, DIP joint dislocations and ligament injuries are relatively

uncommon because of the great anatomic stability of these joints.⁴³ The collateral ligaments of the thumb IP joint are also injured infrequently.^{44,45}

Proximal IP joint injuries can be classified in terms of instability in the coronal plane and instability in the sagittal plane.⁴⁶ Instability in the coronal plane is related to a forced adduction or abduction while the finger is extended. In this case, collateral ligament injuries range from sprains and partial-thickness tears with no or minimal loss of articular stability to complete tears with major joint instability.^{47,48} Instability in the sagittal plane is caused by a hyperextension or compression trauma. A forced hyperextension of the PIP joint results in a dorsal dislocation of the middle phalanx and occurs most commonly in ball-handling sports.^{48–50} There is no side predominance in terms of collateral ligament involvement.²⁹ Based on the Eaton classification, 3 types of lesion are recognized: (1) hyperextension injury to the volar plate–collateral ligament complex with no dislocation or fracture; (2) dorsal subluxation or luxation that is associated with major trauma to the volar plate–collateral ligament

Figure 3. Collateral ligaments of the PIP of the fingers. **A**, A longitudinal sonogram over the ulnar joint side depicts the healthy UCL appearing as an echoic structure. **B**, The healthy RCL shows similar features on the radial joint side. M Ph indicates middle phalanx; and P Ph, proximal phalanx.

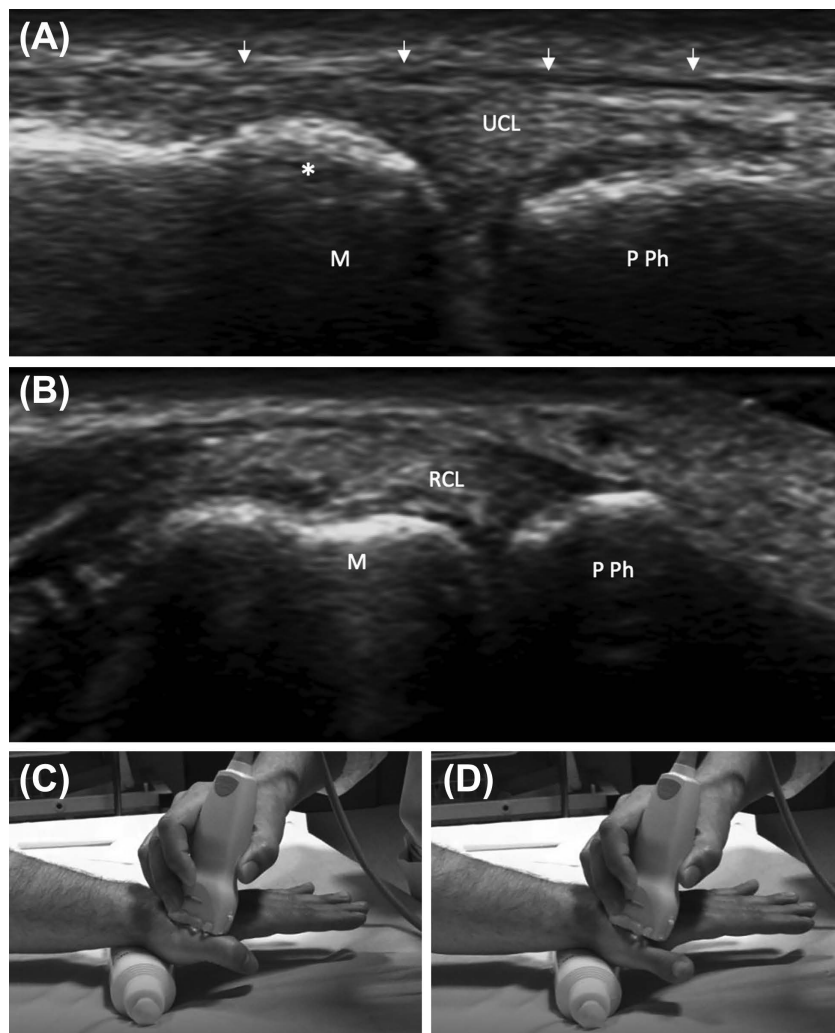


complex; and (3) fracture-dislocation of the base of the middle phalanx. The latter is stable if it involves less than 40% of the articular surface and leaves the collateral ligaments attached to the middle phalanx or unstable if it involves more than 40% of the articular surface while leaving the collateral ligaments and the volar plate attached to the fractured fragment.²³ Less frequently, PIP joint instability is due to the longitudinal compression of a semiflexed joint and results in

volar dislocation of the middle phalanx with unilateral injury to the collateral ligament system.⁴⁸

Many injuries result in partial disruption of the collateral ligaments and present with local pain, swelling, and a limited range of motion. Joint stability is maintained in these cases. In severe cases, an unstable fracture-dislocation as well as full-thickness tears of the ligamentous structures may result in joint instability and deformities, thus requiring surgical treatment.^{51,52}

Figure 4. Collateral ligaments of the thumb metacarpophalangeal joint. **A**, On the ulnar joint side, the healthy UCL appears as an echoic structure that lies underneath the adductor pollicis aponeurosis (arrows). **B**, The healthy RCL shows a similar echo structure on the radial joint side. **C** and **D**, Dynamic maneuvers and transducer orientation for evaluating the UCL are shown during joint flexion (**C**) and extension (**D**). A gel tube is placed under the wrist to allow free motion of the thumb MCP joint. Asterisk indicates metacarpal lateral tubercle; M, metacarpal; and P Ph, proximal phalanx.



Sonographic Examination

Sonographic Technique and Normal Findings

The collateral ligaments of the MCP and IP joints can be assessed with high-frequency linear array transducers, typically 12 to 24 MHz. The use of a small transducer, such as a “hockey stick” type, can solve problems over access for the ultrasonic beam and improve visualization of the collateral ligaments of the MCP joints in the fingers. The patient sits opposite the operator with the hand lying on the examination table. Large amounts of gel or a water bath can be useful for evaluating the collateral ligaments. Bone landmarks are crucial for correct positioning of the transducer and include the proximal and distal ligament insertion sites. A comparative examination of the unaffected contralateral side can serve as a control.^{53,54}

Collateral ligaments appear as thick fibrillar or echoic bands (Figures 3 and 4). They are primarily visualized along their longitudinal axis, in the coronal plane, whereas a short-axis examination is helpful to confirm imaging findings.⁵⁵ The ultrasonic beam should be directed as perpendicular as possible to the examined structure to minimize anisotropy, an artifactual decrease in echogenicity that may mimic a pathologic change.⁵⁶ The slightly hypoechoic appearance of the normal collateral ligaments may be due to this artifact and may be related to the oblique course of their fibers.⁵⁷ Differentiation between the proper and accessory collateral ligaments is not feasible with sonography, as they merge with each other.²⁹

Dynamic maneuvers can be applied to stress the MCP and IP joints (Figure 4). This action enables the collateral ligaments to be straightened, and it is helpful for distinguishing between partial-thickness and complete tears in doubtful cases. At the level of the MCP joints, the collateral ligaments can be depicted under different degrees of tensioning during flexion and extension movements. Radial (ie, valgus) and ulnar (ie, varus) stresses allow for the best depiction of UCL and RCL injuries, respectively, by causing joint space widening and increasing the gap between the ligament stumps.²⁹ These maneuvers should, however, be performed gently and under sonographic control, thus exerting minimal stress on the joint and avoiding conversion of a nondisplaced injury into a displaced one.⁴⁵ The dynamic assessment of displaced ruptures of the UCL of the thumb MCP joint is described later in the text. The collateral

ligaments of the IP joints are examined by asking the patient to keep the involved digit in extension while flexing the other digits.^{53,58}

Sonographic Features of Collateral Ligament Injuries

Sonography is valuable for detecting the injured collateral ligament as well as associated findings, such as joint effusion, bone misalignment, and any avulsion fracture at the insertion sites.⁵⁹ Table 1 summarizes the main sonographic features of collateral ligament injuries of the MCP and IP joints. Specific lesions of the UCL of the thumb MCP joint are described in Table 2.

In the acute setting, sonographic features of collateral ligament injuries of the MCP and IP joints may vary according to severity. In the case of a sprain (Figures 5 and 6), the involved ligament is focally enlarged and hypoechoic because of hemorrhage and edema, with

Table 1. Sonographic Features of Injuries to the Collateral Ligaments of the MCP and Interphalangeal Joints

Injury	Sonographic Features
Acute sprain	Focal hypoechoic thickening No loss of ligament continuity
Acute partial-thickness tear	Focal hypoechoic thickening Partial disruption of ligament continuity Hematoma between the torn fibers Surrounding soft tissue hyperemia on Doppler imaging
Acute full-thickness tear	Complete disruption of ligament continuity Retraction of the ligament stumps Hematoma between the torn fibers Joint space widening under dynamic stress Surrounding soft tissue hyperemia on Doppler imaging
Chronic sprain	Thickening Elongation Calcifications Absence of hyperemia on Doppler imaging

Table 2. Sonographic Features of Specific Lesions of the UCL of the Thumb MCP Joint

Lesion	Sonographic Features
Skier's thumb	Full-thickness tear
Stener lesion	Full-thickness tear Proximal or superficial displacement in relation to the adductor pollicis aponeurosis
Gamekeeper's thumb	Thickening and elongation due to chronic overuse No loss of ligament continuity

loss of the fibrillar echo texture. Ligament continuity is maintained in the presence of a sprain.^{60,61} In the case of a partial-thickness tear (Figures 7–9), there is a focal hypoechoic thickening of the involved ligament with partial disruption of ligament continuity. Sonographic features of full-thickness tears (Figures 10–18) include complete disruption of ligament continuity and various degrees of retraction of the ligament stumps. In both partial-thickness and complete tears, additional findings include a hematoma between the torn fibers and surrounding soft tissue hyperemia reflecting local inflammation on Doppler imaging.⁵³ An avulsion fracture (Figures 6, 17, 19, and 20) may coexist with a ligament injury and appears as a hyperechoic fragment detached

from the cortical bone.⁶² Fractures may also involve the sesamoid bones (Figure 21).⁶³

In chronic lesions (Figure 22), the ligament appears thickened because of fibrosis.⁶⁴ This appearance constitutes a gamekeeper’s thumb (Figure 23), in which the UCL is enlarged and elongated with no discontinuity of its fibers.⁶⁰ Ligament calcifications may occur as a result of previous trauma and appear hyperechoic with posterior acoustic shadowing over the joint line.⁵³

Nondisplaced Versus Displaced Injury of the Ulnar Collateral Ligament of the Thumb MCP Joint

In the case of a complete nondisplaced tear (Figures 12–14), the UCL may be retracted, but it remains underneath the adductor pollicis aponeurosis, which appears as a very thin echoic band (Figure 4A).⁶¹ In a Stener lesion (Figures 15–18), the UCL of the thumb MCP joint is completely torn and displaced. Specifically, the proximal ligament stump is dislocated proximal to or superficial to the adductor pollicis aponeurosis and appears as a round-to-oval heterogeneously hypoechoic mass proximal to the MCP joint.^{57,65} The adductor pollicis aponeurosis points directly to the bulk of the retracted stump. This appearance is defined as the “yo-yo on a string” sign. The distal ligament stump is smaller than the proximal one and usually negligible.^{66–71} The normal adductor pollicis aponeurosis can be best appreciated under dynamic examination. Specifically, flexion and extension movements of the IP joint of the thumb induce passive gliding of the extensor pollicis longus tendon and, as a consequence, proximal or distal gliding of the aponeurosis that inserts into the extensor

Figure 5. Acute sprain of the RCL of the proximal IP joint of the ring finger. On a longitudinal sonogram, the RCL is characterized by interstitial hypoechoic defects with no fiber disruption, suggestive of a sprain. M Ph indicates middle phalanx; and P Ph, proximal phalanx.

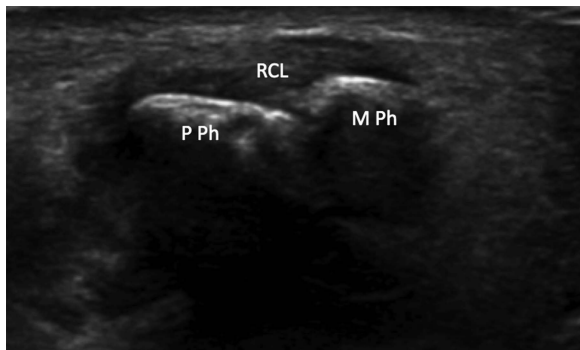
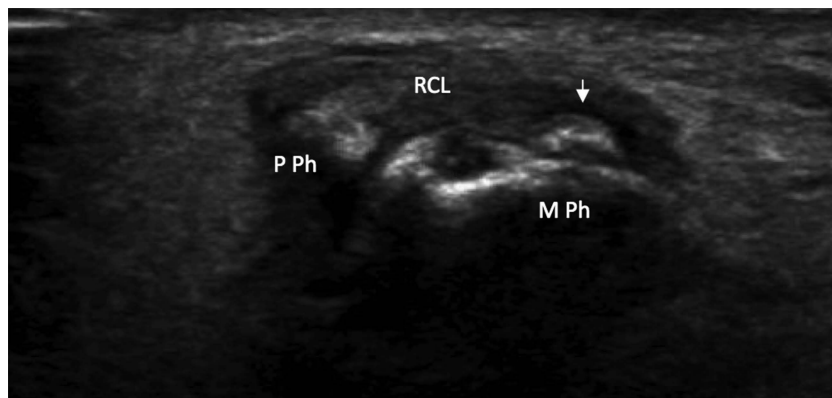


Figure 6. Acute sprain of the RCL of the proximal IP joint of the ring finger. A longitudinal sonogram shows a sprain of the RCL, which appears thickened and hypoechoic. An avulsion fracture (arrow) is shown at the distal ligament attachment. M Ph indicates middle phalanx; and P Ph, proximal phalanx.



hood. If a Stener lesion occurs, the adductor pollicis aponeurosis clashes with the proximal ligament stump or folds within its fibers under dynamic evaluation (Figure 18).^{29,72}

Discussion

Based on a systematic review of the literature from 2000 to the present and taking advantage of our centers'

experience, this study sheds light on key sonographic features of injuries to the collateral ligaments of the MCP and IP joints, thus representing a valuable guide for diagnosis and treatment planning. Table 1 summarizes the main findings suggestive of collateral ligament injuries that can be identified on sonography. Table 2 specifies some specific lesions of the UCL of the thumb MCP joint. Clarification is needed regarding the latter lesions. Although some authors currently use the term

Figure 7. Partial-thickness tear of the RCL of the proximal IP joint of the index finger. A longitudinal sonogram shows the focally hypoechoic appearance of the RCL with partial disruption of ligament continuity (arrow). The superficial fibers of the ligament are swollen but intact, indicating a partial-thickness tear. M Ph indicates middle phalanx; and P Ph, proximal phalanx.

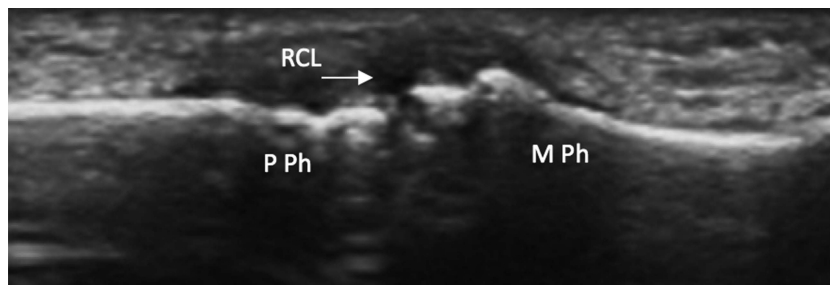


Figure 8. Partial-thickness tear of the UCL of the thumb MCP joint. **A.** On a longitudinal sonogram, the UCL is focally hypoechoic with partial fiber disruption close to its distal insertion, indicating a partial-thickness tear (arrowhead). **B.** On Doppler imaging, hyperemia is shown close to the site of tearing. M indicates metacarpal; and P Ph, proximal phalanx.

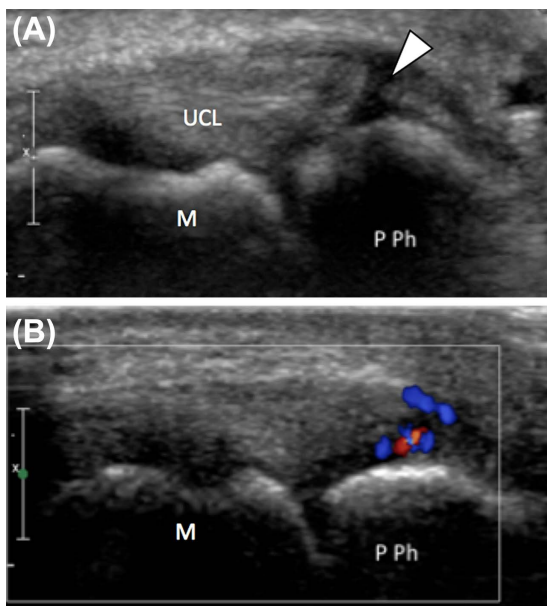


Figure 9. Partial-thickness tear of the UCL of the thumb MCP joint. **A.** A longitudinal sonogram depicts a focal hypoechoic defect (asterisk) of the UCL with partial disruption of its fibers, indicating a partial-thickness tear. **B.** On Doppler imaging, hyperemia is shown close to the site of tearing. M indicates metacarpal; and P Ph, proximal phalanx.

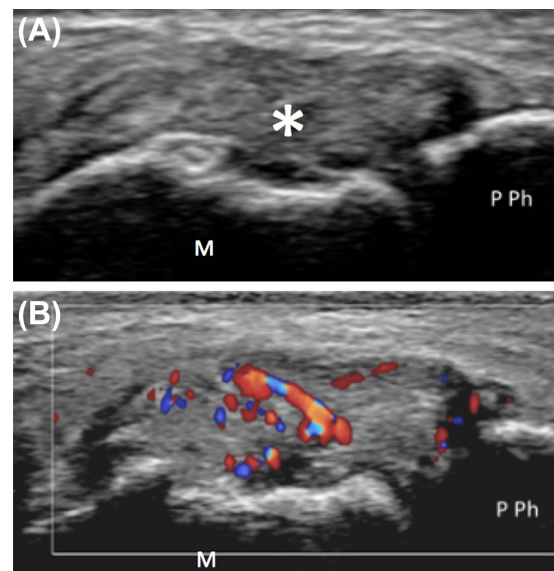


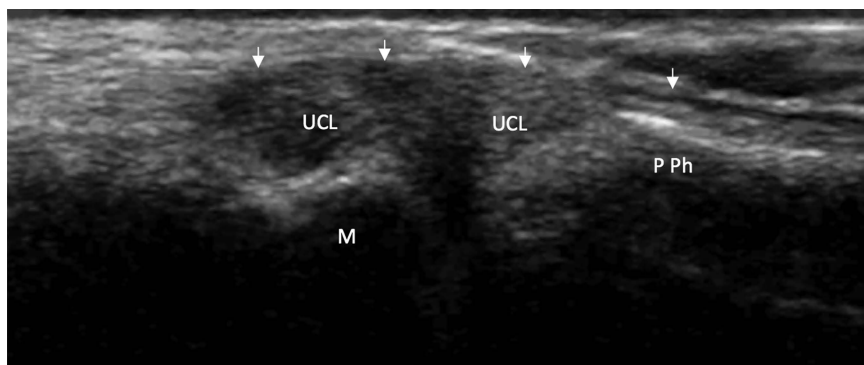
Figure 10. Full-thickness tear of the UCL of the proximal IP joint of the middle finger. On a longitudinal sonogram, the UCL is swollen and retracted and appears as a hypoechoic pseudomass, indicating a full-thickness tear. M Ph indicates middle phalanx; and P Ph, proximal phalanx.

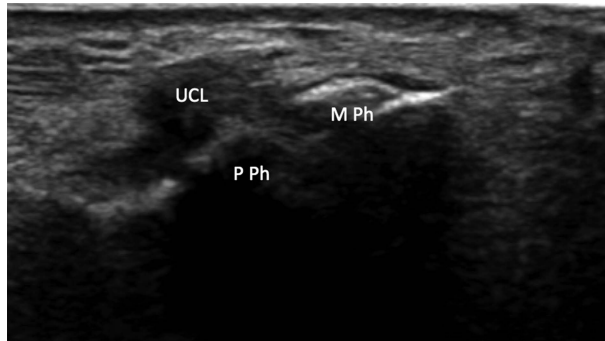

Figure 11. Full-thickness tear of the RCL of the thumb MCP joint. On a longitudinal sonogram, the RCL is swollen and retracted and appears as a hypoechoic pseudomass, indicating a full-thickness tear. M indicates metacarpal; and P Ph, proximal phalanx.

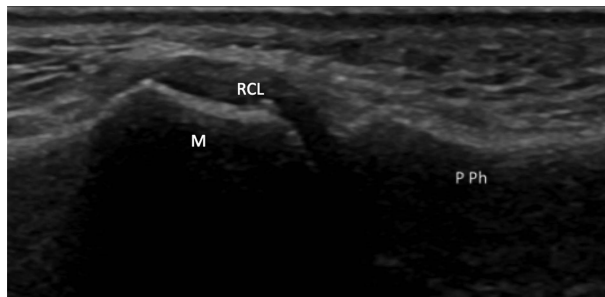

Figure 12. Full-thickness tear of the UCL of the thumb MCP joint. On a longitudinal sonogram, the UCL is swollen and retracted and appears as a hypoechoic pseudomass, indicating a full-thickness tear. This tear is a nondisplaced rupture, as the ligament remains underneath the adductor pollicis aponeurosis (arrows). M indicates metacarpal; and P Ph, proximal phalanx.



“gamekeeper’s thumb” to describe both acute and chronic injuries to the UCL,⁶⁴ throughout this article, we have advocated the original description provided by Campbell²⁶ and reserved this term for chronic lesions while referring to acute injuries as “skier’s thumb”.

Treatment of collateral ligament injuries of the MCP and IP joints can be either conservative or surgical depending on a series of factors. These include patient-related factors, eg, occupational demands, as well as injury-related factors such as the location, grade, concomitant bone or soft tissue abnormalities, and timing of presentation.²⁵ The key information for establishing injury severity is the degree of displacement. Since the collateral ligaments are capsular ligaments, sprains and partial-thickness tears as well as minimally displaced full-thickness tears are often treated conservatively with favorable results.⁶⁷ Ligament displacement occurs in Stener lesions and Stener-like lesions at the level of the thumb and finger MCP joints, respectively. It is related to soft tissue interposition between two stumps of a ruptured ligament or between an avulsed ligament and its attachment site. In a Stener lesion, the UCL is dislocated superficial or proximal to the proximal edge of the intact adductor pollicis aponeurosis.³⁰ In Stener-like lesions, a torn sagittal band creates a window for the injured collateral ligament to herniate and become trapped superficially.³⁸ These complications prevent primary healing and require surgical repair.^{30,38} Extensive injuries involving not only the collateral ligament system but also the dorsal capsule, the extensor hood, or the volar plate may also require surgical

Figure 13. Full-thickness tear of the UCL of the thumb MCP joint (long-standing). **A**, At rest, a longitudinal sonogram shows complete fiber interruption of the UCL with moderate retraction of the ligament stumps, indicating a full-thickness tear. **B**, During valgus stress, substantial joint space widening (dashed double-headed arrow) and radial subluxation (curved arrow) of the proximal phalanx are shown. M indicates metacarpal; and P Ph, proximal phalanx.

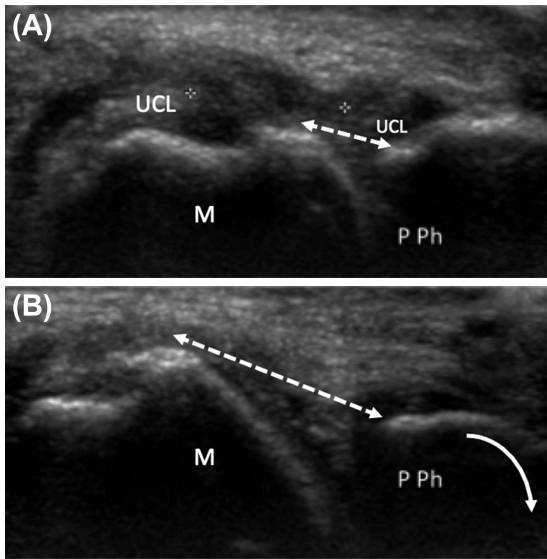


Figure 14. Rerupture of the UCL of the thumb MCP joint. **A**, At rest, a longitudinal sonogram shows a midsubstance full-thickness tear of the UCL with moderate retraction (dashed double-headed arrow) of the ligament stumps. Suture threads (arrowheads) at the distal ligament insertion indicate previous surgery. **B**, During valgus stress, an increase in the distance between the ligament stumps and radial subluxation (curved arrow) of the proximal phalanx is shown. M indicates metacarpal; and P Ph, proximal phalanx.

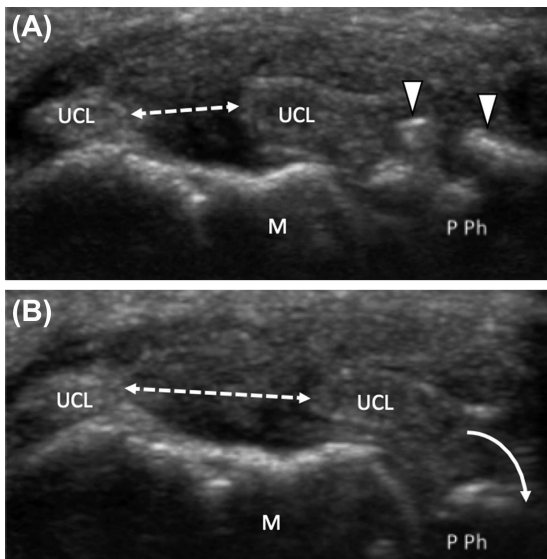


Figure 15. Stener lesion. On a longitudinal sonogram over the ulnar aspect of the thumb MCP joint, the UCL appears ruptured and retracted, and its proximal stump is displaced proximal to and superficial to the adductor pollicis aponeurosis (arrowheads). M indicates metacarpal; and P Ph, proximal phalanx.

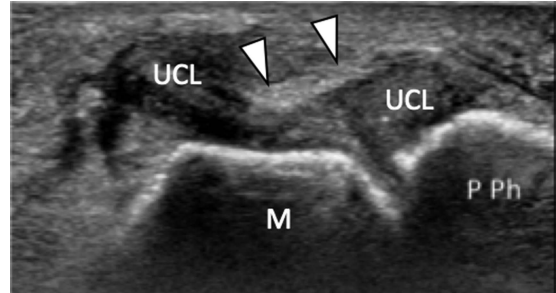


Figure 16. Stener lesion. On a longitudinal sonogram over the ulnar aspect of the thumb MCP joint, the UCL appears ruptured and retracted, and its proximal stump is displaced proximal to and superficial to the adductor pollicis aponeurosis (arrowheads). M indicates metacarpal; and P Ph, proximal phalanx.

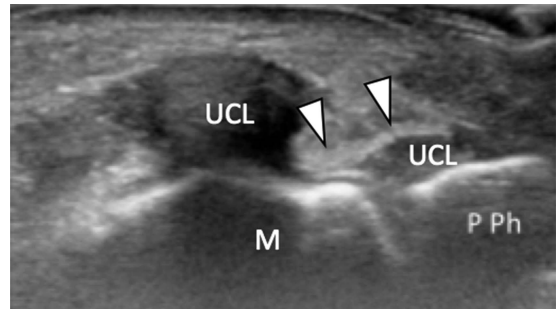
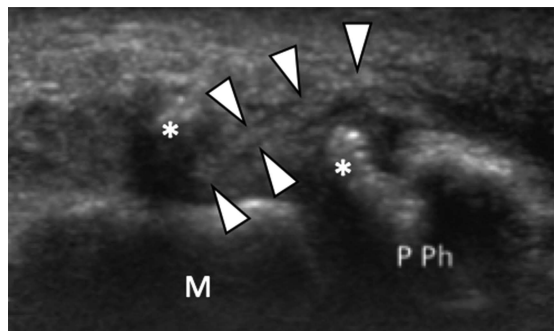


Figure 17. Stener lesion concomitant with an avulsion fracture of the thumb proximal phalanx. A longitudinal sonogram over the ulnar aspect of the thumb MCP joint shows two bone fragments (asterisks) avulsed from the proximal phalanx base with interposition of the adductor pollicis aponeurosis (arrowheads). This case was surgically confirmed. M indicates metacarpal; and P Ph, proximal phalanx.



management.⁷³ In chronic lesions, surgical treatment may be considered in symptomatic patients in the absence of joint arthritis.¹⁶

Figure 18. Dynamic sonographic assessment of a Stener lesion. **A.** At rest, on a longitudinal sonogram over the ulnar aspect of the thumb MCP joint, the UCL appears retracted and hypoechoic, and its proximal stump is displaced superficial to the adductor pollicis aponeurosis (arrows). **B.** During thumb flexion, the adductor pollicis aponeurosis glides and impacts with the proximal stump of the ulnar collateral ligament, indicating a Stener lesion. M indicates metacarpal; and P Ph, proximal phalanx.

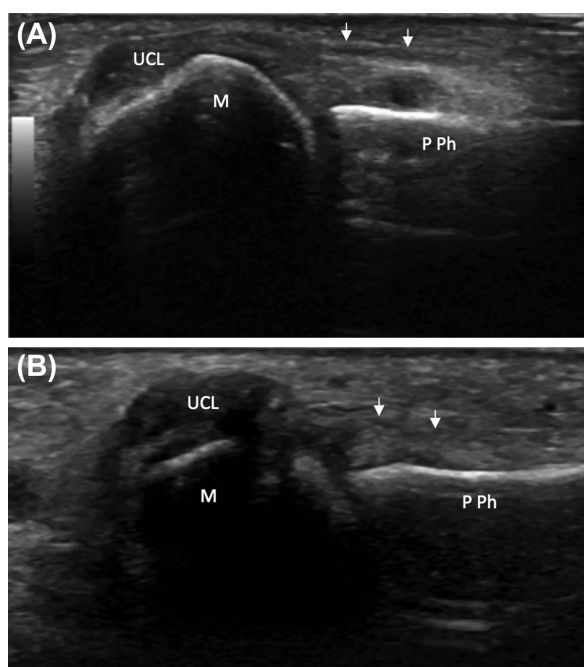
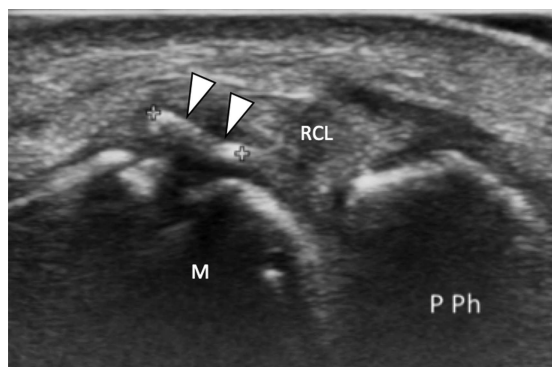


Figure 19. Avulsion fracture of the thumb metacarpal head. A longitudinal sonogram over the radial aspect of the thumb MCP joint depicts an avulsion fracture (arrowheads) of the metacarpal head at the proximal insertion of the RCL. M indicates metacarpal; and P Ph, proximal phalanx.



Most collateral ligament injuries after trauma can be correctly diagnosed on the basis of anamnesis and a physical examination.⁷⁴ The clinical examination, however, may be inaccurate in the assessment of injury severity, specifically in the identification of displaced tears and concomitant abnormalities.²⁹ Thus, imaging serves as a valuable adjunct for appropriate diagnosis and treatment planning. In clinical practice, plain radiography is routinely used in the evaluation of hand injuries to rule out bone abnormalities, such as fractures and joint misalignment. Stress radiographs may reveal joint instability, even though some controversy exists regarding the risk of converting a nonsurgical injury into a surgical one.⁷⁵ Sonography and magnetic resonance imaging are much better suited than radiography to assessing soft tissue lesions. Several studies evaluating the use of sonography and magnetic resonance imaging have supported an improvement in the diagnosis of displaced ruptures of the collateral ligaments, but a consensus for one superior

Figure 20. Avulsion fracture of the thumb proximal phalanx. **A.** At rest, a longitudinal sonogram over the ulnar aspect of the thumb MCP joint depicts an avulsion fracture (asterisk) of the proximal phalanx base at the distal attachment of the UCL. **B.** During valgus stress, the distance (dashed double-headed arrow) between the proximal phalanx and the avulsed bone fragment increases as this fragment is attached to the UCL. Radial subluxation (curved arrow) of the proximal phalanx is also shown. M indicates metacarpal; and P Ph, proximal phalanx.

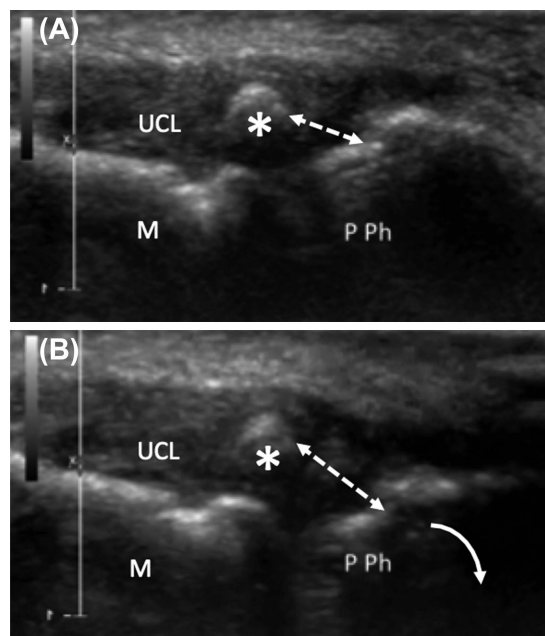


Figure 21. Fracture of the thumb radial sesamoid with a concomitant UCL tear of the MCP joint (not shown). **A**, A longitudinal sonogram over the palmar aspect of the metacarpal head (M) depicts a cortical avulsion from the sesamoid bones (asterisks). **B**, On Doppler imaging, surrounding soft tissue hyperemia is shown. **C**, Axial CT confirms the fracture of the radial sesamoid (asterisks). A normal ulnar sesamoid (USes) is also shown.

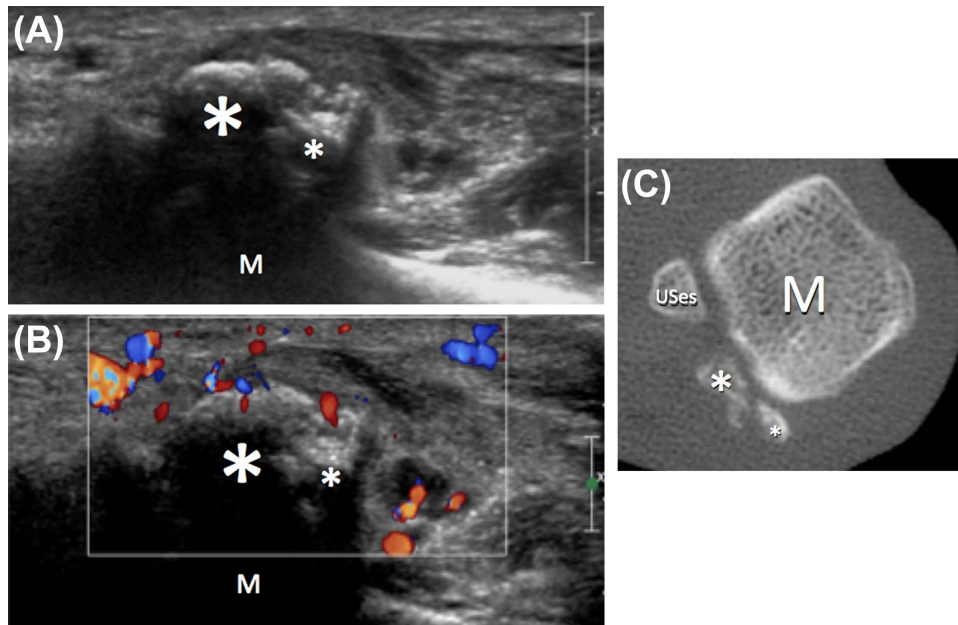


Figure 22. Chronic sprain of the UCL of the proximal IP joint of the index finger. A longitudinal sonogram shows the UCL, which is thickened and elongated with microcalcifications, indicating a chronic lesion. A nondisplaced fracture (arrows) of the proximal phalanx (P Ph) head is also shown.

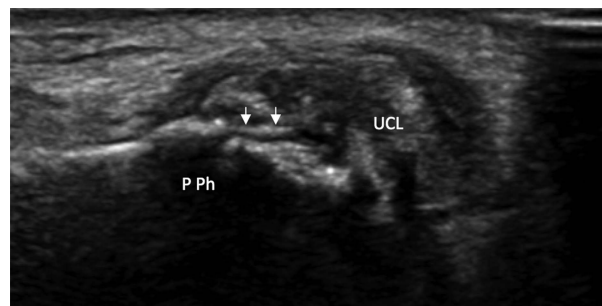
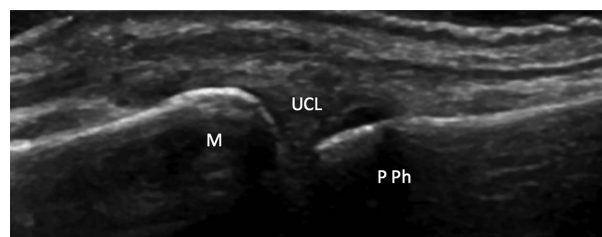


Figure 23. Gamekeeper's thumb. A longitudinal sonogram over the ulnar aspect of the thumb MCP joint shows diffuse thickening of the UCL with no tear. M indicates metacarpal; and P Ph, proximal phalanx.



diagnostic tool does not currently exist.⁷⁶ Several authors have focused their attention on sonographic evaluation of UCL injuries of the thumb MCP joint.^{66–70} High accuracy values have been reported in the differentiation of displaced and nondisplaced tears, with some variability that at least partially reflects the different equipment

Figure 24. Operated adductor pollicis aponeurosis with normal collateral ligaments. On a longitudinal sonogram obtained over the ulnar aspect of the thumb MCP joint, the adductor pollicis aponeurosis (arrows) appears thickened and inhomogeneously hypoechoic because of previous surgery. Some suture threads (arrowheads) are shown in the context of the aponeurosis. The underlying UCL is healthy and shows a normal fibrillar pattern. M indicates metacarpal; and P Ph, proximal phalanx.

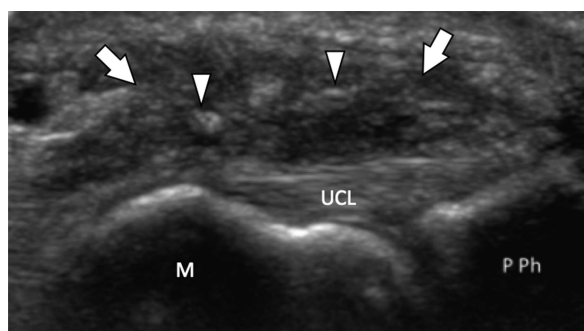
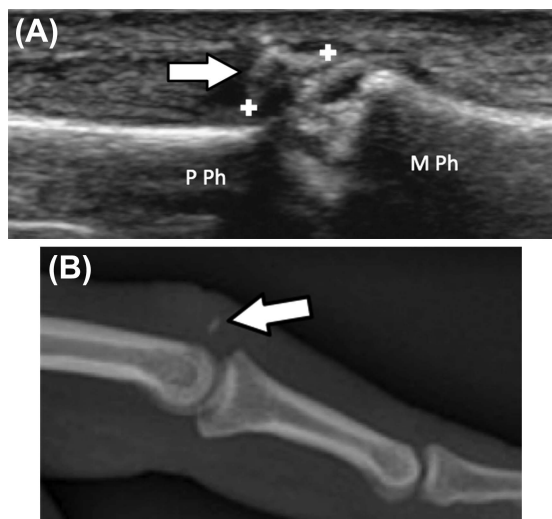


Figure 25. Avulsion fracture of the middle phalanx of the middle finger with normal collateral ligaments (not shown). **A**, A longitudinal sonogram shows an avulsion fracture (arrow) of the middle phalanx base, at the insertion site of the central terminal slip of the extensor tendon. **B**, Plain radiography confirms the presence of a bone fragment (arrow) avulsed from the middle phalanx base. M Ph indicates middle phalanx; and P Ph, proximal phalanx.



technologies available over the years. This factor finds support in a recent retrospective assessment of cases confirmed at surgery, which demonstrated excellent diagnostic performance of sonography in the differentiation of displaced and nondisplaced ruptures with 100% sensitivity, specificity, positive predictive value, negative predictive value, and accuracy.⁵⁷ In this respect, some pitfalls need to be addressed. First, the transducer position and anatomic plane must be properly identified to image the collateral ligaments correctly. Specifically, the smooth concavities at the proximal and distal ligament insertion sites can be used as anatomic landmarks. The second pitfall relates to the site of displacement of the UCL. Specifically, its proximal stump may be located either proximal to or superficial to the proximal edge of the adductor pollicis aponeurosis.⁵⁷ The third pitfall concerns a concomitant injury of the adductor pollicis aponeurosis (Figure 24), which appears thickened and hypoechoic on sonography and can be mistaken as some intact fibers of the UCL.⁷⁷ Dynamic assessment of

Figure 26. Avulsion injury of the volar plate of the proximal IP joint of the middle finger. **A**, A longitudinal sonogram over the palmar joint aspect reveals an avulsion and proximal migration (dashed curved arrow) of the volar plate (white arrow). This condition results in a reduction in the distance between the flexor tendons (arrowheads) and the proximal phalanx head (asterisk) and dorsal subluxation (dashed straight arrow) of the middle phalanx. **B**, Normal volar plate of the contralateral side for comparison. The normal volar plate appears as an echoic structure lying palmar to the proximal phalanx head, underneath the flexor tendons. M Ph indicates middle phalanx; and P Ph, proximal phalanx.

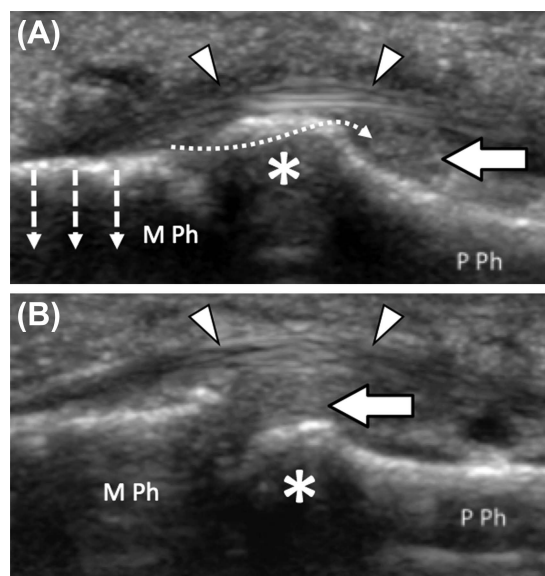
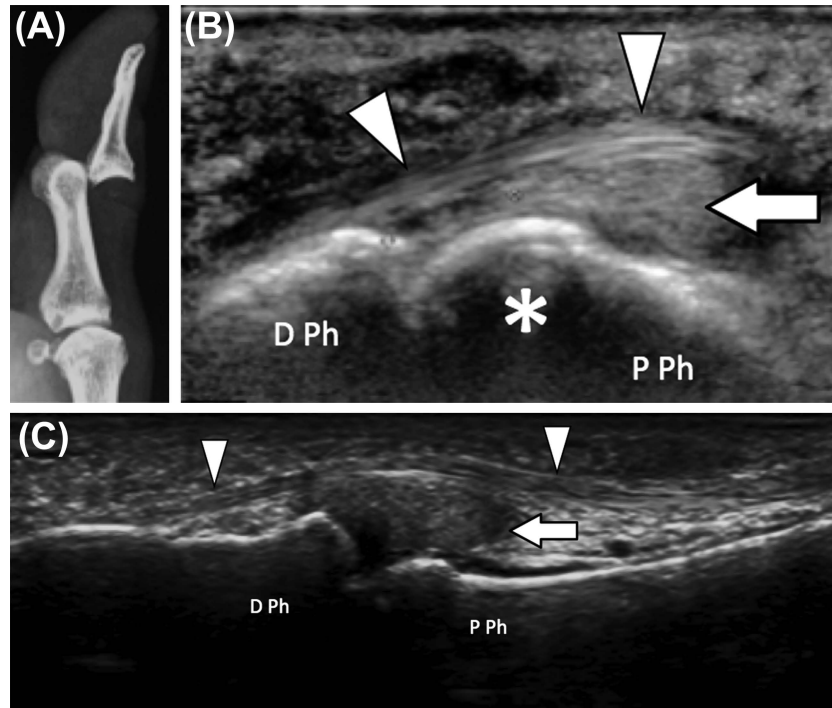


Figure 27. Avulsion injury of the volar plate of the thumb IP joint. **A**, Plain radiography reveals dorsal luxation of the distal phalanx. **B**, After a reduction maneuver, sonography performed for persistent pain shows an avulsion and proximal migration of the volar plate (arrow). This condition results in a reduction in the distance between the proximal phalanx head (asterisk) and the flexor pollicis longus tendon (arrowheads). **C**, Normal volar plate for comparison. The normal volar plate appears as an echoic structure lying palmar to the proximal phalanx head, underneath the flexor pollicis longus tendon. D Ph indicates distal phalanx; and P Ph, proximal phalanx.



the adductor pollicis aponeurosis under sonographic guidance may help clarify the situation in this case.

Sonography may reveal a series of concomitant findings as well as disorders in the vicinity of the MCP and IP joints that may clinically resemble injuries to the collateral ligaments. Bone fractures and joint effusion may be associated with collateral ligament lesions or exist as isolated entities (Figure 25). A bone fracture can be identified on plain radiography, but its location does not predict joint stability.⁷⁸ Thus, stress testing is mandatory for defining proper management, and sonography may safely guide dynamic assessment of joint stability. Sonography may depict a joint effusion that is not obvious on clinical grounds. Specifically, it has been shown to be more accurate than both a physical examination and radiographs in identifying intrasynovial fluid.^{79,80} In complex lesions, volar plate ruptures (Figures 26 and 27) may coexist with collateral ligament injuries and can be detectable on sonography.⁵³ Finally, several pathologic conditions of the thumb and fingers should be considered in the differential

diagnosis of collateral ligament injuries. They mainly include tendon and muscle disorders,^{81,82} vascular injuries,⁸³ and arthropathies.^{84,85}

In conclusion, injuries to the collateral ligaments of the MCP and IP joints require prompt evaluation to ensure proper management and prevent loss of joint motion and permanent disability. Sonography is an efficient and effective imaging modality that aids physicians in the diagnosis and assessment of injury severity, specifically allowing for differentiation of surgical and nonsurgical lesions. A series of concomitant findings as well as several disorders resembling a collateral ligament injury may also be shown.

References

1. Owings FP, Calandruccio JH, Mauck BM. Thumb ligament injuries in the athlete. *Orthop Clin North Am* 2016; 47:799–807.
2. Rettig AC. Athletic injuries of the wrist and hand, part I: traumatic injuries of the wrist. *Am J Sports Med* 2003; 31:1038–1048.

3. Peterson JJ, Bancroft LW. Injuries of the fingers and thumb in the athlete. *Clin Sports Med* 2006; 25:527–542, vii–viii.
4. Rettig AC. Epidemiology of hand and wrist injuries in sports. *Clin Sports Med* 1998; 17:401–406.
5. Gaston RG, Lourie GM. Radial collateral ligament injury of the index metacarpophalangeal joint: an underreported but important injury. *J Hand Surg Am* 2006; 31:1355–1361.
6. Ishizuki M. Injury to collateral ligament of the metacarpophalangeal joint of a finger. *J Hand Surg Am* 1988; 13:444–448.
7. Wong JC, Lutsky KF, Beredjikian PK. Outcomes after repair of subacute-to-chronic grade III metacarpophalangeal joint collateral ligament injuries in fingers are suboptimal. *Hand* 2014; 9:322–328.
8. Mahajan M, Rhemrev SJ. Rupture of the ulnar collateral ligament of the thumb: a review. *Int J Emerg Med* 2013; 6:31.
9. Samora JB, Harris JD, Griesser MJ, Ruff ME, Awan HM. Outcomes after injury to the thumb ulnar collateral ligament: a systematic review. *Clin J Sport Med* 2013; 23:247–254.
10. Draghi F, Robotti G, Jacob D, Bianchi S. Interventional musculoskeletal ultrasonography: precautions and contraindications. *J Ultrasound* 2010; 13:126–133.
11. Lee SA, Kim BH, Kim SJ, Kim JN, Park SY, Choi K. Current status of ultrasonography of the finger. *Ultrasonography* 2016; 35:110–123.
12. Robotti G, Canepa MG, Bortolotto C, Draghi F. Interventional musculoskeletal US: an update on materials and methods. *J Ultrasound* 2013; 16:45–55.
13. Masson JA, Golimbu CN, Grossman JA. MR imaging of the metacarpophalangeal joints. *Magn Reson Imaging Clin North Am* 1995; 3:313–325.
14. Standing S. Wrist and Hand. In: Standing S (ed). *Gray's Anatomy: The Anatomical Basis of Clinical Practice*. 40th ed. London, England: Churchill Livingstone; 2008:857–898.
15. Theumann NH, Pfirrmann CW, Drape JL, Trudell DJ, Resnick D. MR imaging of the metacarpophalangeal joints of the fingers, part I: conventional MR imaging and MR arthrographic findings in cadavers. *Radiology* 2002; 222:437–445.
16. Carlsen BT, Moran SL. Thumb trauma: Bennett fractures, Rolando fractures, and ulnar collateral ligament injuries. *J Hand Surg Am* 2009; 34:945–952.
17. Posner MA, Retillaud JL. Metacarpophalangeal joint injuries of the thumb. *Hand Clin* 1992; 8:713–732.
18. Gupta P, Lenchik L, Wuertzer SD, Pacholke DA. High-resolution 3-T MRI of the fingers: review of anatomy and common tendon and ligament injuries. *AJR Am J Roentgenol* 2015; 204:W314–W323.
19. Allison DM. Anatomy of the collateral ligaments of the proximal interphalangeal joint. *J Hand Surg Am* 2005; 30:1026–1031.
20. Carlson MG, Warner KK, Meyers KN, Hearn KA, Kok PL. Anatomy of the thumb metacarpophalangeal ulnar and radial collateral ligaments. *J Hand Surg Am* 2012; 37:2021–2026.
21. Hirschmann A, Sutter R, Schweizer A, Pfirrmann CW. MRI of the thumb: anatomy and spectrum of findings in asymptomatic volunteers. *AJR Am J Roentgenol* 2014; 202:819–827.
22. Prucz RB, Friedrich JB. Finger joint injuries. *Clin Sports Med* 2015; 34:99–116.
23. Green DP, Wolfe SW. *Green's Operative Hand Surgery*. 6th ed. Philadelphia, PA: Elsevier Churchill Livingstone; 2011.
24. Peterson JJ, Bancroft LW, Kransdorf MJ, Berquist TH, Magee TH, Murray PM. Evaluation of collateral ligament injuries of the metacarpophalangeal joints with magnetic resonance imaging and magnetic resonance arthrography. *Curr Probl Diagn Radiol* 2007; 36:11–20.
25. Madan SS, Pai DR, Kaur A, Dixit R. Injury to ulnar collateral ligament of thumb. *Orthop Surg* 2014; 6:1–7.
26. Campbell CS. Gamekeeper's thumb. *J Bone Joint Surg Br* 1955; 37-B:148–149.
27. Ritting AW, Baldwin PC, Rodner CM. Ulnar collateral ligament injury of the thumb metacarpophalangeal joint. *Clin J Sport Med* 2010; 20:106–112.
28. Smith RJ. Post-traumatic instability of the metacarpophalangeal joint of the thumb. *J Bone Joint Surgery Am* 1977; 59:14–21.
29. Martinoli C, Perez MM, Bignotti B, et al. Imaging finger joint instability with ultrasound. *Semin Musculoskelet Radiol* 2013; 17:466–476.
30. Stener B. Displacement of the ruptured ulnar collateral ligament of the metacarpophalangeal joint of the thumb: a clinical and anatomical study. *J Bone Joint Surg Br* 1962; 44B:869–879.
31. Coyle MP Jr. Grade III radial collateral ligament injuries of the thumb metacarpophalangeal joint: treatment by soft tissue advancement and bony reattachment. *J Hand Surg Am* 2003; 28:14–20.
32. Werner BC, Belkin NS, Kennelly S, et al. Injuries to the collateral ligaments of the metacarpophalangeal joint of the thumb, including simultaneous combined thumb ulnar and radial collateral ligament injuries, in National Football League Athletes. *Am J Sports Med* 2017; 45:195–200.
33. Edelstein DM, Kardashian G, Lee SK. Radial collateral ligament injuries of the thumb. *J Hand Surg Am* 2008; 33:760–770.
34. Kottstorfer J, Hofbauer M, Krusche-Mandl I, Kaiser G, Erhart J, Platzer P. Avulsion fracture and complete rupture of the thumb radial collateral ligament. *Arch Orthop Trauma Surg* 2013; 133:583–588.
35. Melone CP Jr, Beldner S, Basuk RS. Thumb collateral ligament injuries: an anatomic basis for treatment. *Hand Clin* 2000; 16:345–357.
36. Delaere OP, Suttor PM, Degolla R, Leach R, Pieret PJ. Early surgical treatment for collateral ligament rupture of metacarpophalangeal joints of the fingers. *J Hand Surg Am* 2003; 28:309–315.
37. Kang L, Rosen A, Potter HG, Weiland AJ. Rupture of the radial collateral ligament of the index metacarpophalangeal joint: diagnosis and surgical treatment. *J Hand Surg Am* 2007; 32:789–794.
38. Ishizuki M, Sugihara T, Wakabayashi Y, Shirasaka R, Aoyama H. Stener-like lesions of collateral ligament ruptures of the metacarpophalangeal joint of the finger. *J Orthop Sci* 2009; 14:150–154.
39. Toffoli A, Chammas M. Stener-like lesions due to radial collateral ligament rupture in the metacarpophalangeal joints of two adjacent fingers: a case report and review of literature. *Hand Surg Rehabil* 2017; 36:141–145.

40. Lourie GM, Gaston RG, Freeland AE. Collateral ligament injuries of the metacarpophalangeal joints of the fingers. *Hand Clin* 2006; 22:357–364, viii.
41. Wheatley MJ, Layman C, Burke JB. Closed rupture of the deep transverse metacarpal ligament: diagnosis and management. *J Hand Surg Am* 1998; 23:524–528.
42. Cheung JP, Tse WL, Ho PC. Irreducible volar subluxation of the proximal interphalangeal joint due to radial collateral ligament interposition: case report and review of literature. *Hand Surg* 2015; 20:153–157.
43. Itadera E, Muramatsu Y, Hiwatari R, Moriya H. Chronic recurrent dislocation of the distal interphalangeal joint of the finger: case report. *J Hand Surg Am* 2009; 34:1091–1093.
44. Ankarath S, Cohen AP. An uncommon injury of the thumb. *Acta Orthop Belg* 2001; 67:84–85.
45. Rawat U, Pierce JL, Evans S, Chhabra AB, Nacey NC. High-resolution MR imaging and US anatomy of the thumb. *Radiographics* 2016; 36:1701–1716.
46. Clavero JA, Alomar X, Monill JM, et al. MR imaging of ligament and tendon injuries of the fingers. *Radiographics* 2002; 22:237–256.
47. Kahler DM, McCue FC III. Metacarpophalangeal and proximal interphalangeal joint injuries of the hand, including the thumb. *Clin Sports Med* 1992; 11:57–76.
48. Palmer RE. Joint injuries of the hand in athletes. *Clin Sports Med* 1998; 17:513–531.
49. Geissler WB, Burkett JL. Ligamentous sports injuries of the hand and wrist. *Sports Med Arthrosc Rev* 2014; 22:39–44.
50. Sprague BL. Proximal interphalangeal joint injuries and their initial treatment. *J Trauma* 1975; 15:380–385.
51. Bowers WH. Sprains and joint injuries in the hand. *Hand Clin* 1986; 2:93–98.
52. Carlo J, Dell PC, Matthias R, Wright TW. Collateral ligament reconstruction of the proximal interphalangeal joint. *J Hand Surg Am* 2016; 41:129–132.
53. Bianchi S, Martinoli C. Hand. In: *Ultrasound of the Musculoskeletal System*. Berlin, Germany: Springer; 2007:495–548.
54. Le Coroller T, Piro N, Champsaur P. Hand distal interphalangeal joints: sonographic anatomy [in French]. *Morphologie* 2008; 92:188–194.
55. Gitto S, Messina C, Mauri G, Aliprandi A, Sardanelli F, Sconfienza LM. Dynamic high-resolution ultrasound of intrinsic and extrinsic ligaments of the wrist: how to make it simple. *Eur J Radiol* 2017; 87:20–35.
56. Gitto S, Draghi F. Normal sonographic anatomy of the wrist with emphasis on assessment of tendons, nerves, and ligaments. *J Ultrasound Med* 2016; 35:1081–1094.
57. Melville D, Jacobson JA, Haase S, Brandon C, Brigido MK, Fessell D. Ultrasound of displaced ulnar collateral ligament tears of the thumb: the Stener lesion revisited. *Skeletal Radiol* 2013; 42:667–673.
58. Schmitt R. Ligament injuries of fingers and thumbs [in German]. *Radiologe* 2017; 57:43–56.
59. Draghi F, Bianchi S, Gervasio A, Fachinetti C, Gaignot C, de Gautard R. Ultrasound of traumatic disorders of wrist and hand. *J Ultrasound* 2006; 9:218–226.
60. Draghi F. *Ultrasonography of the Upper Extremity: Hand and Wrist*. Cham, Switzerland: Springer; 2014.
61. Melville DM, Jacobson JA, Fessell DP. Ultrasound of the thumb ulnar collateral ligament: technique and pathology. *AJR Am J Roentgenol* 2014; 202:W168.
62. Chotai NC, Tham SC, Wansaicheong G, Tandon AA. Imaging in index finger radial collateral ligament injury: attention to detail really pays. *JBR-BTR* 2011; 94:202–203.
63. Bianchi S, Abdelwahab IF, Zwass A, Molini L. Fractures of the sesamoid bone of the thumb. *Bull Hosp Jt Dis* 1993; 53:7–10.
64. Scalcione LR, Pathria MN, Chung CB. The athlete's hand: ligament and tendon injury. *Semin Musculoskelet Radiol* 2012; 16:338–349.
65. Mattox R, Welk AB, Battaglia PJ, Scali F, Nunez M, Kettner NW. Sonographic diagnosis of an acute Stener lesion: a case report. *J Ultrasound* 2016; 19:149–152.
66. Arend CF, da Silva TR. The role of US in the evaluation of clinically suspected ulnar collateral ligament injuries of the thumb: spectrum of findings and differential diagnosis. *Acta Radiol* 2014; 55:814–823.
67. Ebrahim FS, De Maeseneer M, Jager T, Marcelis S, Jamadar DA, Jacobson JA. US diagnosis of UCL tears of the thumb and Stener lesions: technique, pattern-based approach, and differential diagnosis. *Radiographics* 2006; 26:1007–1020.
68. Jones MH, England SJ, Muwanga CL, Hildreth T. The use of ultrasound in the diagnosis of injuries of the ulnar collateral ligament of the thumb. *J Hand Surg Br* 2000; 25:29–32.
69. Schnur DP, DeLone FX, McClellan RM, Bonavita J, Witham RS. Ultrasound: a powerful tool in the diagnosis of ulnar collateral ligament injuries of the thumb. *Ann Plast Surg* 2002; 49:19–23.
70. Shinohara T, Horii E, Majima M, et al. Sonographic diagnosis of acute injuries of the ulnar collateral ligament of the metacarpophalangeal joint of the thumb. *J Clin Ultrasound* 2007; 35:73–77.
71. Tresley J, Singer AD, Ouellette EA, Blachman J, Clifford PD. Multimodality approach to a Stener lesion: radiographic, ultrasound, magnetic resonance imaging, and surgical correlation. *Am J Orthop* 2017; 46:E195–E199.
72. Bordet B, Borne J, Fantino O, Pialat JB. US of the ulnar collateral ligament (UCL) at the first metacarpophalangeal (MCP) joint: a new dynamic maneuver to detect Stener lesions [in French]. *J Radiol* 2009; 90:217–220.
73. Theumann NH, Pessis E, Lecompte M, et al. MR imaging of the metacarpophalangeal joints of the fingers: evaluation of 38 patients with chronic joint disability. *Skeletal Radiol* 2005; 34:210–216.
74. Mahajan M, Tolman C, Wurth B, Rhemrev SJ. Clinical evaluation vs magnetic resonance imaging of the skier's thumb: a prospective cohort of 30 patients. *Eur J Radiol* 2016; 85:1750–1756.
75. Noszian IM, Dinkhauser LM, Straub GM, Orthner E. Ulnar collateral ligament injuries of the thumb: dislocation caused by stress radiography in two cases. *Acta Orthop Scand* 1995; 66:156–157.

76. Lark ME, Maroukis BL, Chung KC. The Stener lesion: historical perspective and evolution of diagnostic criteria. *Hand* 2017; 12:283–289.
77. Chiavaras MM, Jacobson JA, Yablon CM, Brigido MK, Girish G. Pitfalls in wrist and hand ultrasound. *AJR Am J Roentgenol* 2014; 203: 531–540.
78. Hintermann B, Holzach PJ, Schutz M, Matter P. Skier's thumb: the significance of bony injuries. *Am J Sports Med* 1993; 21:800–804.
79. Chau CL, Griffith JF. Musculoskeletal infections: ultrasound appearances. *Clin Radiol* 2005; 60:149–159.
80. Valley VT, Stahmer SA. Targeted musculoarticular sonography in the detection of joint effusions. *Acad Emerg Med* 2001; 8:361–367.
81. Gitto S, Draghi AG, Draghi F. Sonography of non-neoplastic disorders of the hand and wrist tendons. *J Ultrasound Med* 2018; 37:51–68.
82. Wieschhoff GG, Sheehan SE, Wortman JR, et al. Traumatic finger injuries: what the orthopedic surgeon wants to know. *Radiographics* 2016; 36:1106–1128.
83. Bianchi S, Martinoli C, Abdelwahab IF. High-frequency ultrasound examination of the wrist and hand. *Skeletal Radiol* 1999; 28:121–129.
84. Orlandi D, Gitto S, Perugin Bernardi S, et al. Advanced power Doppler technique increases synovial vascularity detection in patients with rheumatoid arthritis. *Ultrasound Med Biol* 2017; 43:1880–1887.
85. Taljanovic MS, Melville DM, Gimber LH, et al. High-resolution US of rheumatologic diseases. *Radiographics* 2015; 35:2026–2048.