

Original Research Paper

Efficacy of the Administration of a Natural Feed Supplement in the Management of Equine Gastric Ulcer Syndrome in 7 Sport Horses: A Field Trial

¹Stucchi Luca, ¹Zucca Enrica, ²Serra Alessia, ¹Stancari Giovanni, ¹Ceriotti Serena, ³Conturba Bianca, ¹Ferro Elisabetta and ¹Ferrucci Francesco

¹Department of Health, Animal Science and Food Safety (VESPA), Università degli Studi di Milano, Italy

²Private Practitioner, Alessandria, Italy

³Centro Clinico-Veterinario e Zootecnico Sperimentale, Università degli Studi di Milano, Italy

Article history

Received: 31-03-2017

Revised: 15-05-2017

Accepted: 15-06-2017

Corresponding Author:

Ferrucci Francesco
Department of Health, Animal
Science and Food Safety
(VESPA), Università degli
Studi di Milano, Italy
Phone: +39 02 503.31112
Fax: + 39 02 503.31115
E-mail: francesco.ferrucci@unimi.it

Abstract: Equine Gastric Ulcer Syndrome (EGUS) is one of the most common causes of poor performance in the equine patient and affects more than 90% of Standardbred and Thoroughbred racehorses in training. Nowadays, the principal therapeutic options for EGUS treatment include antiacids such as histamine receptor antagonists and proton pump inhibitors. Recently, many studies concerning feed supplements to treat and prevent EGUS were carried out. The aim of the present study was to evaluate the efficacy of a natural feed supplement, administered for 30 days, as the only treatment for gastric ulcerations in sport horses in training. Seven horses were selected for the study on the basis of their gastroscopic evidence of erosive and ulcerative lesions of the gastric mucosa. Each horse received a natural feed supplement (Gastrocure, Institute Farmaceutico Candioli, Italy) registered for use in horses for 30 days. Gastroscopy was performed on day 0 (T₁), day 15 (T₂) and at the end of the treatment (day 30, T₃). Scores were assigned according to MacAllister method (score 0,1,2,3,4 for number of lesions and score 0,1,2,3,4,5 for lesion severity). Statistical analysis showed a strong evidence (p<0.01) of lower scores occurring at T₃ when compared to T₁ for both number and severity of gastric lesions. In conclusion, the administration of Gastrocure was effective in reducing the number and severity of ulcerative lesions in horses affected by EGUS.

Keywords: Horse, EGUS, Gastroscopy, Feed Supplement

Introduction

Equine Gastric Ulcer Syndrome (EGUS) is one of the most common causes of poor performance in the equine patient and affects more than 90% of Standardbred and Thoroughbred racehorses in training (Ferrucci *et al.*, 2003a; Roy *et al.*, 2005; Bell *et al.*, 2007). EGUS also affects horses involved in others disciplines such as endurance (Tamzali *et al.*, 2011), show horses (White *et al.*, 2007) and horses not involved in competition, such as broodmares (Le Jeune *et al.*, 2009). EGUS is associated with several risk factors, i.e., stress (Malmkvist *et al.*, 2012), intense training and competition (Roy *et al.*, 2005; Jonsson and Egenvall, 2006) and diet (Nadeau *et al.*, 2003; Andrews *et al.*, 2008). EGUS has a negative impact on horse's health and performance. The most common clinical signs are weight loss (Murray *et al.*, 1989; Dionne *et al.*, 2003), poor performance (Nieto *et al.*, 2009)

and gastrointestinal symptoms (Andrews and Nadeau, 1999; Dionne *et al.*, 2003). EGUS treatment aims to promote ulcers healing, eliminate clinical signs and prevent the onset of recurrences (Buchanan and Andrews, 2003). The therapeutic approach includes management strategies and drugs administration (Hepburn, 2001; Sykes and Jokisalo, 2015). The first aim of pharmacological therapy is to suppress acid secretion. Nowadays, the principal therapeutic options for EGUS treatment include antiacids such as histamine receptor antagonists and proton pump inhibitors. All these products are effective although a "rebound effect" is frequently reported and this could exacerbate the syndrome (Hunfeld *et al.*, 2007) furthermore, they are expensive and should be administered for long periods of time. Besides, in sport horses, most treatments during the competition periods are not permitted. These considerations led to an increased interest in research for less expensive

natural alternatives to prevent the deleterious effects of increased acidity and recurrence of gastric ulcers after discontinuing omeprazole administration. For these reasons, many studies concerning feed supplements to treat and prevent gastric ulceration in horses were carried out (Venner *et al.*, 1999; Ferrucci *et al.*, 2003b; Huff *et al.*, 2012; Hellings and Larsen 2014).

The aim of the present study was to evaluate the efficacy of a natural feed supplement, administered for 30 days, as the only treatment for gastric ulcerations in sport horses in training.

Materials and Methods

Horses

All procedures performed on horses were approved by the University of Milan Ethics Committee (Protocol Number 72/14) and included informed owner consent.

Seven sport horses were selected for the study on the basis of their gastroscopic evidence of erosive and ulcerative lesions of the gastric mucosa. The study population consisted in four Thoroughbreds (three mares and one gelding), two Standardbreds (one mare and one gelding) and one Arabian gelding. All horses were in full training either for flat (thoroughbreds and standardbreds) or endurance (ara bian gelding) racing. All horses ranged in age from three to fifteen years old (mean age: 6.6 ± 5.5 years) and had a mean weight of 440 ± 34.5 kg. All the horses were stabled in individual boxes and bedded on woods having. Racehorses (thoroughbreds and standardbreds) were fed approximately 8 kg hay and 7 kg commercial pelleted feed per day with free access to drinking water and engaged in race once monthly. Endurance horse was fed 10 kg hay and 5 kg commercial pelleted and raced once every two month. Feeding was not changed in the competition period.

Physical Examination

A physical examination was performed on all horses before the beginning of the study in order to rule out the presence of any clinical disease. Behaviour and physical parameters (rectal temperature, pulse, respiratory rate, gut motility) were monitored at weekly intervals throughout the study.

Gastroscopic Examination

Gastroscopy was performed on day 0 (T_1), day 15 (T_2) and at the end of the treatment (day 30, T_3). Before gastroscopic examination, feed was withheld for 24 h. All horses were examined with a video gastro scope (PV-G 34-325; Storz, Germany) connected to an aspirator pump (208-ACH; Faset, Italy). Horses were restrained with a twitch and sedated with 0.01 mg/kg i.v. hydrochloride detomidine (Detogesic; Zoetis, USA). To enable observation of the squamous mucosa, *margoplicatus* and glandular mucosa, the stomach was

insufflate with air. Recordings of gastroscopic examinations were reviewed independently by three examiners with different level of experience. Scores were assigned according to MacAllister method (score 0,1,2,3,4 for number of lesions and score 0,1,2,3,4,5 for lesion severity, MacAllister *et al.*, 1997).

Treatment

Each horse received natural feed supplement (Gastrocure, Institute Farmaceutico Candioli, Italy) registered for use in horses (Table 1) according to the producer indications: 85 grams orally twice daily for ten days and then 85 grams once daily for twenty days were administered. During this period, the management factors, such as feeding and training regimen, were not changed.

Statistical Analysis

Data were analyzed by a categorical response linear regression, considering the ulcer number and severity scores as dependent variables. The probability for each score was estimated both for number and for severity. Moreover, in the regression model it was kept into account that each subject was repeatedly scored on three occasions (times) by three evaluators for each occasion.

Time, with three increasing levels (1, 2 and 3), was considered as the regression independent variable.

Both for number and severity of lesions, the hypothesis of higher probability of lower scores (cut off: ≤ 2), comparing T_3 with T_1 , was tested at $p < 0.05$ level of significance.

Statistical analysis was performed with SAS STAT© software (SAS Institute Inc., Cary, NC, USA).

Results

Throughout the study, the horses did not show any signs of discomfort and all the monitored parameters remained within normal limits. The product was well accepted by all of the horses and no side effects were observed.

Gastroscopy at T_1 showed that all horses had gastric lesions localised to the squamous mucosa close to the *margoplicatus*. Four horses had ulcers active bleeding. Only three horses showed lesions of the glandular mucosa. The average scores regarding number and severity of lesions of the three operators at T_1 , T_2 and T_3 are showed in Fig. 1.

Statistical analysis showed a strong evidence ($p < 0.01$) of lower scores occurring at T_3 when compared to T_1 (Fig. 2 and 3).

When the cut off was considered, for the number of lesions probability of ≤ 2 score increased from 0.04 to 0.35 between time 1 and time 3 (0.31 increment) (Fig. 4). For the severity of lesions, probability of ≤ 2 score increased from 0.36 to 0.76 between time 1 and time 3 (0.40 increment) (Fig. 5).

Table 1. Composition and analytical constituents of feed supplement

Composition	
Alfalfa hay, Soybean kernel, Saccharose, Calcium Carbonate, Oils and Vegetable Fats (Soybean Oil), Magnesium Hydroxide, Methyl-Sulphonil-Methane.	
Additives for kg: Vitamins and Pro-vitamins (Vitamin E/alpha-tocopheryl-acetate g 2,5).	
Emulsifiers and Stabilizing Agents: Guar Gum g 75.	
Natural products: <i>Plantago ovate</i> (Fleawort extract) g 19; <i>Trigonellafoenum-graecum</i> (Fenugreek extract CoE 460) g 13; <i>Aloe Vera</i> (Aloe extract CoE 28) g 6; <i>Glycyrrhizaglabra</i> (Licorice extract CoE 218) g 10;	
Aminoacid: L-threonine g 63;	
Preservatives: Methyl-4-hydroxibenzoate E218 g 0,23; Propile-4-hydroxibenzoate E216 g 0,12;Potassium sorbate E202 g 0,35; Butil-hydroxi-toluene E321 g 0,20	
Analytical constituents	
Water content	9%
Crude protein	12%
Crude oils and fats	7%
Crude ashes	13%
AshInsoluble in HCl	1%
Crude fiber	12%
Calcium	2%
Magnesium	1,6%

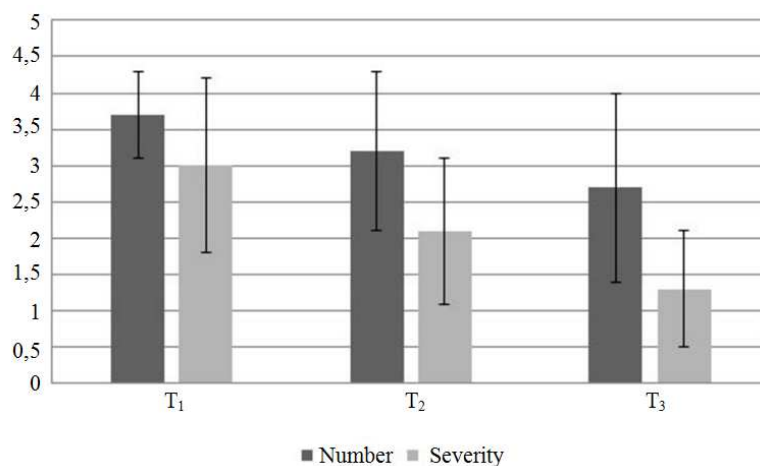


Fig. 1. Average score regarding number and severity of lesions of the three operators

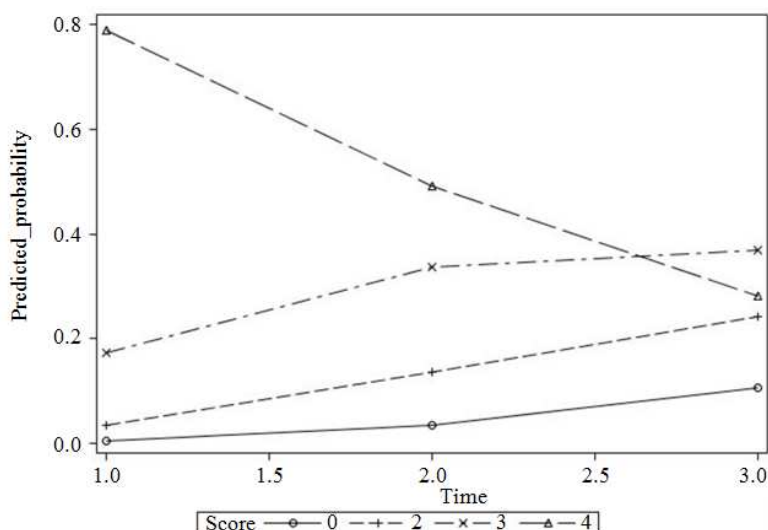


Fig. 2. Predicted probabilities of scores for lesion number

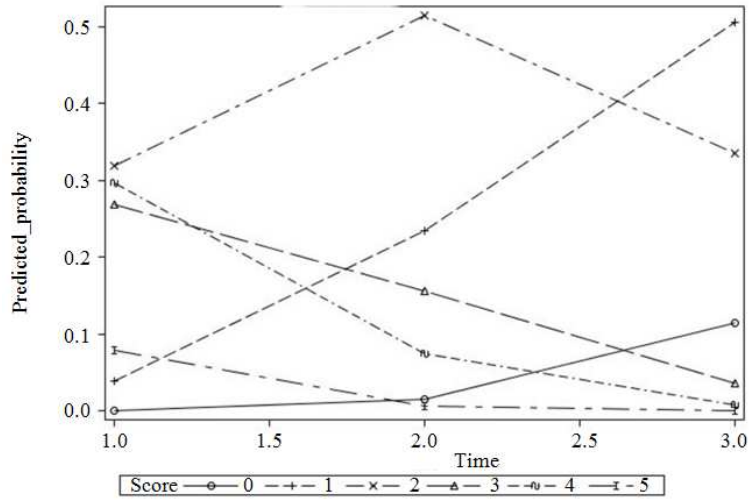


Fig. 3. Predicted probabilities of scores for lesion severity

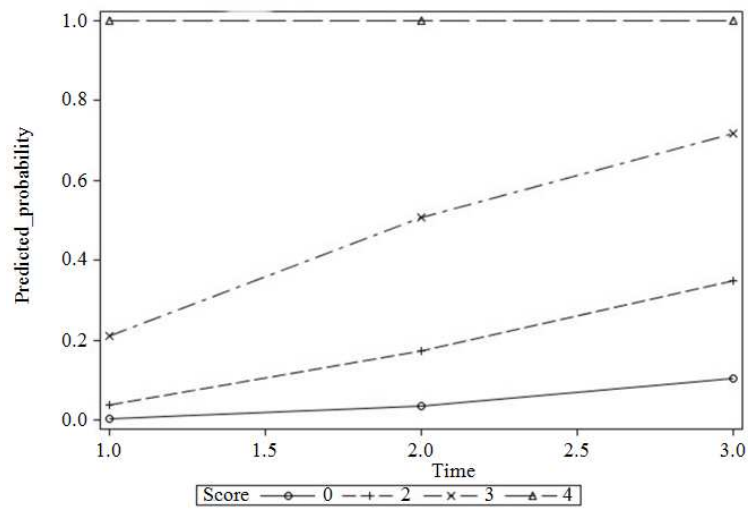


Fig. 4. Predicted cumulative probabilities of scores for lesion number

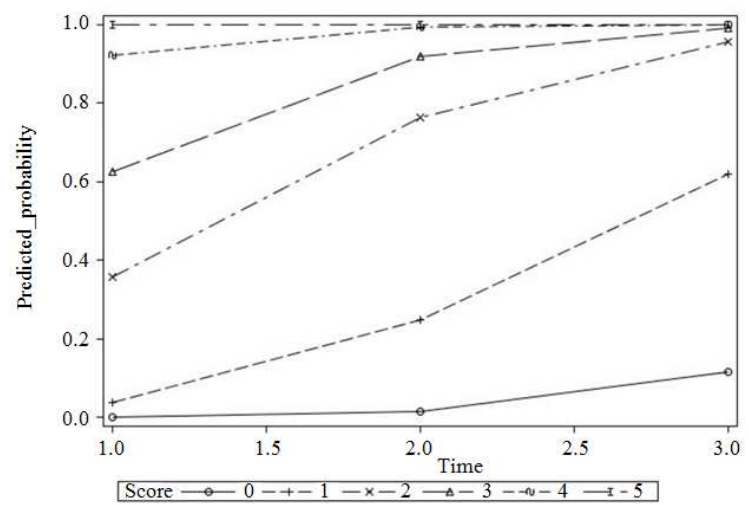


Fig. 5. Predicted cumulative probabilities of scores for lesion severity

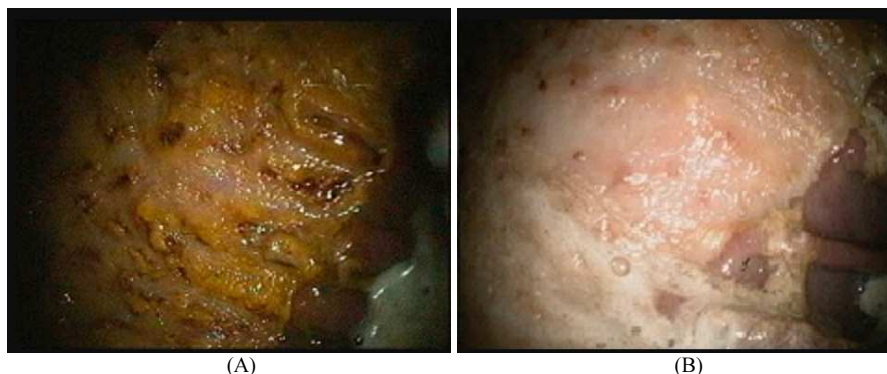

Fig. 6. Gastroscopic view at T1 (A) and T3 (B) of one of the horses of the study

Discussion

To date, no data reporting the efficacy of a feed supplement similar to the one administered in this study are available. The horses selected for the study were representative of the typical population affected by EGUS, i.e., high concentrates fed horses in training. Localisation, number and severity of the gastric lesions observed were consistent with previous studies (Ferrucci *et al.*, 2003a; Roy *et al.*, 2005; Bell *et al.*, 2007; Tamzali *et al.*, 2011).

Statistical analysis showed that administration of the supplement reduces significantly ($p < 0.01$) the scores for both number and severity of gastric lesions (Fig. 6). Scores improvement could be explained with the buffering effect of those components such as alfalfa hay (Husted *et al.*, 2008), magnesium hydroxide and calcium carbonate (Clark *et al.*, 1996). Besides, there are also other nutrients, such as threonine, *Glycyrrhiza glabra* (liquorice), *Aloe vera*, antioxidant factors and mucilages, that may have a protective effect on the gastric mucosa. Threonine is an amino acid involved in the production of protective mucus at the gastro-enteric level. Studies on piglets (Law *et al.*, 2007) report that a lack in threonine represents a limiting factor for mucus production. Liquorice is included in the feed supplement in form of deglycyrrhizinated root extract, to prevent the occurrence of the systemic hypertension effects of liquorice. A study conducted in 1985 on 190 human patients, concluded that the substance is as effective as anti-acids and cimetidine in the treatment of duodenal chronic ulcers (Kassir, 1985). Several studies in human medicine and on other species proved the efficacy of liquorice as anti-ulcerogenic and gastro-protective factor (Guslandi, 1985; Aslam *et al.*, 2015). The anti-ulcerogenic activity of liquorice extract results in the suppression of acid secretion and in an increase of mucine secretion. Liquorice also promotes the release of PGE₂. Antioxidant action is due to its flavonoid content (Khayyal *et al.*, 2001). Besides, it was reported that flavonoid could inhibit protonic-pump in the glandular mucosa of the stomach (Beil *et al.*, 1995). Studies conducted on human patients (Langmead *et al.*, 2006)

and on rats (Eamlamnam *et al.*, 2006) hypothesize an anti-ulcerogenic activity of *Aloe vera*, due to its anti-inflammatory, cytoprotective and mucus-stimulating effects. Anti-inflammatory effects of *Aloe vera* were demonstrated in horses as well (Lans *et al.*, 2006). *Aloe* could act increasing the perfusion of gastric mucosa, reducing vasoconstriction and promoting angiogenesis, facilitating the healing of ulcers. Finally, mucilages (Pectin, Guar, Psyllium and fenugreek), when in an acid environment, form a viscous gel that protects the mucosa from the effects of acidity (Murray and Grady, 2002; Ferrucci *et al.*, 2003b; Lans *et al.*, 2006).

One possible limit of the present study is that it was conducted as a field trial, in the absence of a control group. This condition doesn't allow to rule out the possibility that the lesions could have improved spontaneously (Murray *et al.*, 1997). However, the management of the horses was not changed throughout the study. Therefore, EGUS predisposing factors, such as training and competition, feeding a diet high in concentrates and low in fibre and box stabling were maintained during the whole period of treatment, suggesting that the administration of the supplement may have had a positive effect on ulcers healing.

Conclusion

In conclusion, the administration of Gastrocure was effective in reducing the number and severity of ulcerative lesions in horses affected by EGUS. These results suggest that this product could be included in the treatment protocol of EGUS, according to each individual case, either alone or as an adjuvant in anti acid treatment or during the period when anti acids are discontinued, in order to prevent the "rebound effect".

Acknowledgement

The Authors wish to acknowledge Dr. Fabio Maria Colombo (Department of Health, Animal Science and Food Safety, Università degli Studi di Milano) for helping with statistical evaluation and Dr. Armida

Barelli (Istituto Farmaceutico Candioli, Italy), for technical support during the trial.

Funding Information

The project has been funded by Istituto Farmaceutico Candioli which is the company that has patent on Gastrocure.

Author Contributions

All authors were actively involved in all stage of the work. The manuscript it has been read and approved by all authors.

Conflict of Interest

The authors have no personal financial or non-financial competing interest in the product.

References

- Andrews, F.M. and J.A. Nadeau, 1999. Clinical syndromes of gastric ulceration in foals and mature horses. *Equine Vet. J. Supp.*, 29: 30-33.
- Andrews, F.M., B.R. Buchanan, S.B. Elliott, R.A.M. Al Jassim and C.M. McGowan *et al.*, 2008. In Vitro effects of hydrochloric and lactic acids on bioelectric properties of equine gastric squamous mucosa. *Equine Vet. J.*, 40: 301-305.
- Aslam, B., T. Awan, I. Javed, T. Khaliq and J.A. Khan *et al.*, 2015. Gastroprotective and antioxidant potential of Glycyrrhizaglabra on experimentally induced gastric ulcer in albino mice. *Int. J. Curr. Microbiol. Applied. Sci.*, 4: 451-460.
- Beil, W., C. Birkholz and K.F. Sewing, 1995. Effects of flavonoids on parietal cell acid secretion, gastric mucosal prostaglandin production and helicobacter pylori growth. *Arzneimittel-Forschung*, 45: 697-700.
- Bell, R.J.W., J.K. Kingston, T.D. Mogg and N.R. Perkins, 2007. The prevalence of gastric ulceration in racehorses in New Zealand. *New Zeal Vet. J.*, 55: 13-18.
- Buchanan, B.R. and F.M. Andrews, 2003. Treatment and prevention of equine gastric ulcer syndrome. *Vet. Clin. Equine Pract.*, 19: 575-597.
- Clark, C.K., A.M. Merritt, J.A. Burrow and C.K. Steible, 1996. Effect of aluminum hydroxide/magnesium hydroxide antacid and bismuth subsalicylate on gastric pH in horses. *J. Am. Vet. Med. Assoc.*, 208: 1687-1691.
- Dionne, R.M., A. Vrins, M.Y. Doucet and J. Parè, 2003. Gastric ulcers in standardbred racehorses: Prevalence, lesion description and risk factors. *J. Vet. Intern. Med.*, 17: 218-222.
- Eamlamnam, K., S. Patmuraj, N. Visedopas and D. Thong-Ngam, 2006. Effects of Aloe vera and sucralfate on gastric microcirculatory changes, cytokine levels and gastric ulcer healing in rats. *World J. Gastroentero.*, 12: 2034-2039.
- Ferrucci, F., E. Zucca, V. Di Fabio, C. Croci and F. Tradati, 2003a. Gastroscopic findings in 63 standardbred racehorses in training. *Vet. Res. Commun.*, 27: 759-762. PMID: 14535515
- Ferrucci, F., E. Zucca, C. Croci, V. Di Fabio and E. Ferro, 2003b. Treatment of gastric ulceration in 10 standardbred racehorses with a pectin-lecithin complex. *Vet. Rec.*, 152: 679-681.
- Guslandi, M., 1985. Ulcer-healing drugs and endogenous prostaglandins. *Int. J. Clin. Pharm. Therapy Toxicol.*, 23: 398-402. PMID: 2864318
- Hellings, I.R. and S. Larsen, 2014. ImproWin® in the treatment of gastric ulceration of the squamous mucosa in trotting racehorses. *Acta. Vet. Scand*, 56: 13-13. DOI: 10.1186/1751-0147-56-13
- Hepburn, R.J., 2001. Gastric ulceration in horse. *Practice*, 33: 116-124.
- Huff, N.K., A.D. Auer, F. Garza, M.L. Keowen and M.T. Kearney *et al.*, 2012. Effect of sea buckthorn berries and pulp in a liquid emulsion on gastric ulcer scores and gastric juice pH in horses. *J. Vet. Intern Med.*, 26: 1186-1191. DOI: 10.1111/j.1939-1676.2012.00975.x
- Hunfeld, N.G.M., W.P. Geus and E.J. Kuipers, 2007. Systematic review: Rebound acid hypersecretion after therapy with proton pump inhibitors. *Aliment Pharm. Therap.*, 25: 39-46. PMID: 17229219
- Husted, L., L.C. Sanchez, S.N. Olsen, K.E. Baptiste and A.M. Merrit, 2008. Effect of paddock vs. stall housing on 24 hour gastric pH within the proximal and ventral equine stomach. *Equine Vet. J.*, 40: 337-341.
- Jonsson, H. and A. Egenvall, 2006. Prevalence of gastric ulceration in Swedishst and ardbreds in race training. *Equine Vet. J.*, 38: 209-213. PMID: 16706273
- Kassir, Z.A., 1985. Endoscopic controlled trial of four drug regimens in the treatment of chronic duodenal ulceration. *Ir. Med. J.*, 78: 153-6. PMID: 3891678
- Khayyal, M.T., M.T. El-Ghazaly, S.A. Kenawy, M. Seif-Al Naser and L.G. Mahranet *al.*, 2001. Antiulcerogenic effect of some gastro intestinally acting plant extracts and their combination. *Arzneimittel-forsch*, 51: 545-553.
- Langmead, L., R.M. Feakins, S. Goldthorpe, H. Holt and E. Tsironi *et al.*, 2006. Randomized, double-blind, placebo-controlled trial of oral aloe vera gel for active ulcerative colitis. *Aliment Pharm. Therap.*, 19: 341-349. DOI: 10.1111/j.1365-2036.2004.01902.x
- Lans, C., N. Turner, G. Brauer, G. Lourenco and K. Georges, 2006. Ethno veterinary medicines used for horses in trinidad and in British Columbia, Canada. *J. Ethnobiol. Ethnomed.*

- Law, G.K., R.F. Bertolo, A. Adjiri-Awere, P.B. Pencharz and R.O. Ball, 2007. Adequate oral threonine is critical for mucin production and gut function in neonatal piglets. *Am. J. Physiol. Gastrointest Liver Physiol.*, 292: 1293-1301.
- Le Jeune, S., J. Nieto, J. Dechant and J. Snyder, 2009. Prevalence of gastric ulcers in thoroughbred broodmares in pasture. *Vet J.*, 181: 251-255.
- MacAllister, C.G., F.M. Andrews, E. Deegan, W. Ruoff and S.G. Olovson, 1997. A scoring system for gastric ulcers in the horse. *Equi. Vet. J.*, 29: 403-433.
- Malmkvist, J., J.M. Poulsen, N. Luthersson, R. Palme and J.W. Chistensen *et al.*, 2012. Behavior and stress responses in horses with gastric ulceration. *Applied Anim. Behav. Sci.*, 142: 160-167.
- Murray, M.J., C. Grodinsky, C.W. Anderson, P.F. Radue and R. Schmidt, 1989. Gastric ulcers in horses: A comparison of endoscopic findings in horses with and without clinical signs. *Equine Vet. J.*, 21: 68-72. DOI: 10.1111/j.2042-3306.1989.tb05659.x
- Murray, M.J., M.L. Haven, E.S. Eichorn, G.J. Hickey and J. Eagleson, 1997. The effects of omeprazole on healing of natural-occurring gastric ulcers in thoroughbred race horses. *Equine. Vet. J.*, 28: 368-374.
- Murray, M.J. and T.C. Grady, 2002. The effect of a pectin-lecithin complex on prevention of gastric mucosal lesions induced by feed deprivation in ponies. *Equine. Vet. J.*, 34: 195-198.
- Nadeau, J.A., F.M. Andrews, C.S. Patton, R.A. Argenzio and A.G. Mathew *et al.*, 2003. Effects of hydrochloric, acetic, butyric and propionic acids on pathogenesis of ulcers in the nonglandular portion of the stomach of horses. *Am. J. Vet. Res.*, 64: 404-412.
- Nieto, J.E., J.R. Snyder, N.J. Vatistas and J.H. Jones, 2009. Effect of gastric ulceration on physiologic responses to exercise in horses. *Am. J. Vet. Res.*, 70: 787-795. DOI: 10.2460/ajvr.70.6.787
- Roy, M.A., A. Vrins, G. Beauchamp and M.Y. Doucet, 2005. Prevalence of ulcers of the squamous gastric mucosa in Standardbred horses. *J. Vet. Intern. Med.*, 19: 744-750
- Sykes, B.W., M. Hewetson, R.J. Hepburn, N. Luthersson and Y. Tamzali, 2015. European college of equine internal medicine-equine gastric ulcer syndrome in adult horses. *J. Vet. Intern. Med.*, 201: 1288-1299.
- Tamzali, Y., C. Marguet, N. Priymenko and F. Lyazrhi, 2011. Prevalence of gastric ulcer syndrome in high-level endurance horses. *Equin. Vet. J.*, 43: 141-144. DOI: 10.1111/j.2042-3306.2010.00129.x
- Venner, M., S. Lauffs and E. Deegen, 1999. Treatment of gastric lesions in horses with pectin-lecithin complex. *Equine Vet. J. Supp.*, 29: 91-96.
- White, G., S.R. McClure, R. Sifferman, J.E. Holste and C. Fleishman *et al.*, 2007. Effects of short-term light to heavy exercise on gastric ulcer development in horses and efficacy of omeprazole paste in preventing gastric ulceration. *J. Am. Vet. Med. Assoc.*, 230: 1680-1682.