



J Indian Soc Periodontol. 2020 Jul-Aug; 24(4): 301–308.

PMCID: PMC7418544

Published online 2020 Jun 5.

PMID: [32831501](https://pubmed.ncbi.nlm.nih.gov/32831501/)

doi: 10.4103/jisp.jisp_528_19: 10.4103/jisp.jisp_528_19

Reproducibility and validity of anterior implant esthetic indices: A review

[Gunjan Srivastava](#), [Swagatika Panda](#),¹ [Saurav Panda](#),^{2,3} [Subrat Kumar Padhiary](#),⁴ [Sitansu Sekhar Das](#), and [Massimo Del Fabbro](#)³

Department of Prosthodontics, Institute of Dental Sciences, Siksha 'O' Anusandhan Deemed to be University, Bhubaneswar, Odisha, India

¹*Department of Oral and Maxillofacial Pathology, Institute of Dental Sciences, Siksha 'O' Anusandhan Deemed to be University, Bhubaneswar, Odisha, India*

²*Department of Periodontics and Oral Implantology, Institute of Dental Sciences, Siksha 'O' Anusandhan Deemed to be University, Bhubaneswar, Odisha, India*

³*Department of Biomedical, Surgical and Dental Sciences, University of Milan, Milan, Italy*

⁴*Department of Oral and Maxillofacial Surgery, Institute of Dental Sciences, Siksha 'O' Anusandhan Deemed to be University, Bhubaneswar, Odisha, India*

Address for corresponding: Prof. Gunjan Srivastava, Department of Prosthodontics, Institute of Dental Sciences, Siksha 'O' Anusandhan Deemed to be University, Bhubaneswar - 751 003, Odisha, India. E-mail:

gunjansrivastava@soa.ac.in

The work belongs to the Department of Prosthodontics, Institute of Dental Sciences, Siksha 'O' Anusandhan Deemed to be University, Bhubaneswar, Odisha, India

Received 2019 Oct 15; Revised 2020 Mar 1; Accepted 2020 Mar 18.

[Copyright](#) : © 2020 Indian Society of Periodontology

This is an open access journal, and articles are distributed under the terms of the Creative Commons Attribution-NonCommercial-ShareAlike 4.0 License, which allows others to remix, tweak, and build upon the work non-commercially, as long as appropriate credit is given and the new creations are licensed under the identical terms.

Abstract

Background:

The purpose of this review was to narrate about the reproducibility and validity of different indices evaluating esthetic aspects in anterior single implant-supported restorations.

Materials and Methods:

An electronic search of Medline, Scopus, Embase, Cochrane Central, and Web of Science databases was performed using the keywords “dental implants,” “anterior esthetics,” “esthetic score,” and “esthetic index.” Besides, a manual search of dental implant journals was carried out.

Results:

The electronic search revealed 932 titles. After further review, 14 articles fulfilled the eligibility criteria and were included in this review. Because of the heterogeneity of the study designs, interventions, and parameters used for assessment of esthetics, no meta-analysis could be performed.

Conclusion:

Many indices have been proposed for the evaluation of the esthetic aspects of single implant-supported reconstructions in the anterior maxilla. All of them have some advantages and drawbacks that this review pointed out. The evidence level of studies used for the validation of these indices is poor. It is necessary to achieve a consensus on the tools for assessment of the esthetic aspect and perform evidence-based studies to validate an appropriate index.

Keywords: Dental implants, esthetic index, esthetic score, reproducibility, success criteria

INTRODUCTION

Replacement of single or multiple missing teeth with implant-supported prosthesis is a dependable treatment modality with success rates as high as 95%.[\[1,2,3\]](#) With changing times, success criteria for anterior implants have changed from mere survival and function to esthetics.[\[4\]](#) A combination of a visually pleasing prosthesis and healthy, harmoniously scalloped peri-implant soft tissues is the key to achieve adequate esthetics in anterior implant restorations.[\[5\]](#) Objective assessment done by professionals and by patients minimizes the subjective nature of esthetics. Esthetic indices not only give insight about the esthetic outcome but also evaluate the outcomes as a function of time regarding the stability of implant-supported restoration.

Jemt's papilla index (PI)[\[6\]](#) was the first to assess the papilla fill of the anterior implant restoration objectively though it considered only one factor for esthetic assessment. Annibali *et al.*,[\[7\]](#) in their review, had found that this index was the most commonly reported until 2009 for evaluation of esthetics in anterior single implant crowns. The Implant Esthetic Score (IAS) proposed by Testori *et al.*[\[8\]](#) comprised five variables: presence and stability of the mesiodistal papilla, ridge stability buccopalatally, texture and color of the peri-implant soft tissue as well as gingival contour. Taking into account seven different variables (height of mesial and distal papilla, level, contour, color, and texture of soft tissue and alveolar process deficiency) to objectively assess the peri-implant soft tissue, Furhauser *et al.*[\[9\]](#) proposed the Pink Esthetic Score (PES). Mesiodistal width, incisal edge position, labial surface convexity, color, translucency and surface characteristics of the crown along with labial margin, interproximal embrasures, surface contour, and color and texture of the labial mucosa are the nine variables considered by Meijer *et al.*[\[10\]](#) in the "Implant Crown Esthetic Index" (ICAI). The major drawback of this index is its scoring pattern providing five points for gross deviation; hence, the single gross deviation can result in poor esthetic results. Belser *et al.*[\[11\]](#) developed a new complete esthetic index that combines the PES with White Esthetic Score (PES/WES), which objectively assessed the peri-implant soft tissues and featured inherent to the restoration. The five PES parameters are mesial papilla, distal papilla, the curvature of the facial mucosa, level of the facial mucosa, and root convexity/soft-tissue color and texture. The WES parameters are tooth form, outline, and volume of the crown, the color of the crown, surface texture, and translucency, and characterization. In 2010, Juodzbaly and Wang[\[12\]](#) developed and validated a Complex Esthetic Index (CEI) for evaluating esthetics of implant-supported restorations and peri-implant soft and hard tissues. This comprehensive index is composed of Soft-tissue index (S), Predictive index (P), and Restoration index (R). Hosseini and Gotfredsen[\[13\]](#) established the Copenhagen Index Score (CIS), which was composed of six scores: crown morphology, color match, symmetry/harmony, mucosal discoloration, and PI mesially and distally. Encompassing three subjective and six objective criteria, Tettamanti *et al.*[\[14\]](#) proposed the Peri-Implant and Crown Index and further compared that with PES/WES and ICAI. The Implant Restoration Esthetic Index, a novel index developed by Li *et al.*,[\[15\]](#) included six soft-tissue parameters and six crown-related parameters. The authors compared it with another widely used index (PES/WES).

Reproducibility is the degree of concordance of multiple measurements of the same subject, carried out under different conditions. Intra-observer and inter-observer agreement values are considered to predict the reproducibility of an index. Different studies exist concerning esthetic assessment;[\[14,16,17,18,19,20\]](#) however, there is no uniform consensus among clinicians on this topic. As far as we know, this is the first review specifically aiming at comparing the reproducibility and validity of several esthetic indices of anterior single implant-supported restorations. A secondary aim was the identification of the strength and the most common drawbacks of existing indices, to help in designing specific tools, validated by specific evidence-based studies.

MATERIALS AND METHODS

An electronic search in Medline, Scopus, Embase, Cochrane Central, and Web of Science databases was conducted using the keywords “dental implants,” “anterior esthetics,” “esthetic score,” and “esthetic index” in combination to one another. The search was done for studies reporting on single-tooth implant-supported restorations in the maxillary esthetic zone for which esthetic evaluation was done in the form of esthetic index or esthetic score.

Inclusion criteria

Studies with a minimum sample size of ten patients that have proposed a new esthetic index and validated the reproducibility of the same or studies that have checked the reproducibility and validity of esthetic indices already present in the literature were included.

Exclusion criteria

Studies with lack of reproducibility assessment, lack of esthetic assessment by the clinician, lack of explicit mention of anterior single-tooth implant, case series with less than ten patients, lack of adjacent natural tooth, and no index being used for esthetic assessment were excluded [Table 1]. No limitation was set regarding the study design and the language.

In addition, implant dentistry-related journals were manually searched to include all pertinent publications: *Clinical Oral Implants Research*, *Journal of Prosthetic Dentistry*, *International Journal of Oral and Maxillofacial Implants*, *Journal of Prosthodontics*, *International Journal of Prosthodontics*, *Journal of Periodontology*, *Clinical Implant Dentistry and Related Research*, *The International Journal of Periodontics and Restorative Dentistry*, and *European Journal of Oral Implantology*.

The search was performed independently by two reviewers (GS and SP). All titles obtained by the electronic search were screened for meeting the inclusion criteria. The titles containing insufficient information for inclusion were selected for the abstract evaluation. Articles were selected for evaluation of full text when synonyms related to esthetic evaluation were present in the abstract. Full texts of carefully chosen articles were appraised entirely before the final inclusion. Any disagreement about inclusion was resolved after discussion with a third reviewer (SWP).

RESULTS

Searches of PubMed, Scopus, Embase, Cochrane Central, and Web of Science databases generated 932 articles. The last electronic search was performed on February 20, 2019. After removing the duplicates, 740 titles were retrieved. Of which, 263 abstracts were selected for further evaluation. After a meticulous screening of abstracts, 37 articles were subjected to full-text assessment. Finally, 14 studies that validated or compared the reproducibility of the esthetic index in a single anterior implant-supported crown were selected for inclusion [Figure 1]. A total of 23 studies were excluded with proper reasons for exclusion [Table 1]. Standardized descriptive tables were prepared to present the relevant data, which was extracted by two reviewers independently (GS and SKP).

All characteristics of included studies are presented in Table 2. This review included 14 studies evaluating 641 implants in 597 patients with a minimum follow-up duration of 1 year. The details of the studies, including the nature of the assessor, assessment interval, mode of assessment, and the criterion of the rating scale for each index are recorded for included studies.

The number of examiners and assessment intervals were different in all studies. The mode of assessment was heterogeneous and varied. Ten of 14 studies had used photographs alone [6,9,10,13,15,16,17,19,20,42] as the mode of assessment, whereas photographs in combination with the diagnostic cast were used in other three studies [11,14,18]. Only one study [12] had used periapical radiographs as well as direct visualization on a patient's mouth. The PES/WES was the most repeatedly used index in the included studies ($n = 6$), followed by ICAI used by five studies. Objective evaluation of esthetic indices has been done using either a numerical scale (NS) or a Visual Analog Scale (VAS).

The summary of findings of all the included studies is presented in [Table 3](#). The mean values of the esthetic score, intra-observer agreement, and inter-observer agreement were tabulated for a comprehensive interpretation. No statistical analysis could be carried out across the indices for measuring the variation in inter- and intra-observer agreement because of heterogeneous nature of indices in terms of assessment, assessor's expertise, and evaluation criteria.

DISCUSSION

With an increased demand for esthetics, the perspective for the success of implant-supported restorations has changed from mere osseointegration to natural appearance of crowns. The International Team for Implantology (ITI) consensus statement of 2014 has suggested the use of esthetic indices for objective assessment of factors that contribute to esthetic outcomes.[\[43\]](#) The esthetic index serves as a checklist to confirm the vital parameters of esthetic implant restorations. There have been multiple studies suggesting novel indices. On critical evaluation of those studies, this review has attempted to summarize the reproducibility and validity of those indices. Reproducibility of the esthetic index is influenced by intra- and inter-observer variations, the interval between the first and second assessments, observer's specialization, methods of evaluation, and scoring parameters.

Cohen's kappa is an accepted statistical measure to assess intra-observer and inter-observer reliability,[\[44\]](#) which was used by most of the included studies.[\[10,12,13,14,17,18,19,20\]](#) The interval between the first and second assessments of esthetic index ranged from 7 to 28 days. A uniform interval between the first and second evaluations would have increased the homogeneity and reduced bias of included studies. Retained memory of the observer after the first assessment may negatively influence the judgment of the second evaluation when the interval is very short.

Multiple authors showed the influence of the observer's specialization on an objective assessment of index reproducibility.[\[9,10,16,17,18,20\]](#) It has been observed that orthodontists were more critical in rating the esthetics for implant restoration likely due to their inclination toward natural esthetics than the restorative esthetics.[\[9,17,18\]](#) We may opine that an unbiased assessor who is unaware of difficulties in achieving peri-implant esthetics is required for assessment of the esthetic index.

The esthetic indices reported so far have evaluated the esthetics either by photographs alone or in combination with dental casts. CEI[\[12\]](#) is the only index that used direct visualization on the patient and intraoral periapical radiographs. Before CEI, none of the esthetic indexes had taken into consideration the underlying hard tissue upon which the soft-tissue appearance is mainly dependent. Horizontal bone level and interproximal bone height are strongly correlated to the stability and appearance of the peri-implant soft tissue.[\[45,46\]](#) Chen *et al.*[\[47\]](#) showed that the thin tissue biotype had more implant soft-tissue recession than the thick tissue biotype. They also found that buccally placed implants had shown three-folds more recession than lingually placed implants. Assessment on photographs runs the risk of a different angle of exposure and difference in brightness and contrast. Again, some anatomical features are more discernible in three-dimensional structures such as alveolar process convexity, which are difficult to interpret in photographs. While most authors used a NS, few authors[\[14,15\]](#) used VAS, which has added to the random nature of the data.

Tettamanti *et al.*[\[14\]](#) rated PES/WES as the fastest and easiest index. They compared three objective indices and found the highest intra-observer agreement with PES/WES and lowest with ICAI; therefore, they conclude that the use of ICAI was questionable. Gehrke *et al.*[\[17\]](#) also concluded the same about ICAI. Vilhjálmsón *et al.*[\[19\]](#) also compared three objective indices and found the highest intra-observer reproducibility with modified ICAI. The modified ICAI gives fewer penalty points for gross deviation, thus overcoming the demerit of ICAI. Hof *et al.*,[\[42\]](#) in a recent study, had compared eight objective indices and discovered the highest intra-rater reproducibility for the PI, PES, and CEI while the lowest intra-rater reproducibility was recorded for ICAI.

Most of the included studies have evaluated esthetics from the clinician's perspective except few, [\[11,13,14,15,19,42\]](#) which have included the patient's as well as clinician's perspective. In general, it can be noted that clinicians tend to evaluate the esthetic outcomes of restoration more critically than patients.[\[48\]](#)

As included, articles have used different indices, and the heterogeneous nature of parameters being taken any suggestive comparison between data was not possible. The retrospective nature of all included studies excludes a higher level of evidence, which further encourages to conduct prospective randomized controlled trials with adequately explained inclusion and exclusion criteria.

Clinical significance

This study compares the esthetic indices used for anterior single implant-supported restorations and gives an insight to the readers for using indices in their implant dentistry practice to judge the level of esthetics achieved at the end of the treatment procedure. Evaluation of esthetic outcomes adds as a success criterion for the restoration of anterior implants.

CONCLUSION

Many indices have been proposed for the evaluation of the esthetic aspects of single implant-supported reconstructions in the anterior maxilla. All of them have some advantages and drawbacks that this review pointed out. The evidence level of studies used for the validation of these indices is poor. It is necessary to achieve a consensus on the tools for assessment of the esthetic aspect and perform evidence-based studies to validate an appropriate index.

By comprehensively reviewing several indices, the authors believe that PES/WES index proposed by Belser *et al.*[11] is the most user-friendly index with scoring criteria straightforward and easy to use. This index was used in most of the clinical trials on anterior implant esthetics the authors came across during the review process.

Financial support and sponsorship

Nil.

Conflicts of interest

There are no conflicts of interest.

REFERENCES

1. Buser D, Janner SF, Wittneben JG, Brägger U, Ramseier CA, Salvi GE. 10-year survival and success rates of 511 titanium implants with a sandblasted and acid-etched surface: a retrospective study in 303 partially edentulous patients. *Clin Implant Dent Relat Res.* 2012;14:839–51. [PubMed: 22897683]
2. Fuentealba R, Jofré J. Esthetic failure in implant dentistry. *Dent Clin North Am.* 2015;59:227–46. [PubMed: 25434568]
3. Pjetursson BE, Asgeirsson AG, Zwahlen M, Sailer I. Improvements in implant dentistry over the last decade: Comparison of survival and complication rates in older and newer publications. *Int J Oral Maxillofac Implants.* 2014;29:308–24. [PubMed: 24660206]
4. Gotfredsen K. A 10-year prospective study of single tooth implants placed in the anterior maxilla. *Clin Implant Dent Relat Res.* 2012;14:80–7. [PubMed: 19673954]
5. Wittneben JG, Buser D, Belser UC, Brägger U. Peri-implant soft tissue conditioning with provisional restorations in the esthetic zone: The dynamic compression technique. *Int J Period Res Dent.* 2013;33:447–55. [PubMed: 23820704]
6. Jemt T. Regeneration of gingival papillae after single-implant treatment. *Int J Period Res Dent.* 1997;17:326–33. [PubMed: 9497723]
7. Annibaldi S, Bignozzi I, La Monaca G, Cristalli MP. Usefulness of the aesthetic result as a success criterion for implant therapy: A review. *Clin Implant Dent Relat Res.* 2012;14:3–40. [PubMed: 19673953]
8. Testori T, Bianchi F, Del Fabbro M, Capelli M, Zuffetti F, Berlucchi I, et al. Implant aesthetic score for evaluating the outcome: Immediate loading in the aesthetic zone. *Pract Proced Aesthetic Dent PPAD.* 2005;17:123–30. [PubMed: 15918307]

9. Fürhauser R, Florescu D, Benesch T, Haas R, Mailath G, Watzek G. Evaluation of soft tissue around single-tooth implant crowns: The pink esthetic score. *Clin Oral Implants Res.* 2005;16:639–44. [PubMed: 16307569]
10. Meijer HJ, Stellingsma K, Meijndert L, Raghoobar GM. A new index for rating aesthetics of implant-supported single crowns and adjacent soft tissues-the Implant Crown Aesthetic Index. *Clin Oral Implants Res.* 2005;16:645–9. [PubMed: 16307570]
11. Belser UC, Grütter L, Vailati F, Bornstein MM, Weber HP, Buser D. Outcome evaluation of early placed maxillary anterior single-tooth implants using objective esthetic criteria: A cross-sectional, retrospective study in 45 patients with a 2-to 4-year follow-up using pink and white esthetic scores. *J Periodontol.* 2009;80:140–51. [PubMed: 19228100]
12. Juodzbaly G, Wang HL. Esthetic index for anterior maxillary implant-supported restorations. *J Periodontol.* 2010;81:34–42. [PubMed: 20059415]
13. Hosseini M, Gotfredsen K. A feasible, aesthetic quality evaluation of implant-supported single crowns: An analysis of validity and reliability. *Clin Oral Implants Res.* 2012;23:453–8. [PubMed: 21443589]
14. Tettamanti S, Millen C, Gavric J, Buser D, Belser UC, Brägger U, et al. Esthetic evaluation of implant crowns and peri-implant soft tissue in the anterior maxilla: Comparison and reproducibility of three different indices. *Clin Implant Dent Relat Res.* 2016;18:517–26. [PubMed: 25727214]
15. Li X, Wu B, Cheng X, Li Y, Xie X, Deng F. Esthetic evaluation of implant-supported single crowns: The implant restoration esthetic index and patient perception. *J Prosthodont.* 2019;28:e51–8. [PubMed: 29148207]
16. Gehrke P, Lobert M, Dhom G. Reproducibility of the pink esthetic score-rating soft tissue esthetics around single-implant restorations with regard to dental observer specialization. *J Esthet Restor Dent.* 2008;20:375–84. [PubMed: 19120783]
17. Gehrke P, Degidi M, Lulay-Saad Z, Dhom G. Reproducibility of the implant crown aesthetic index-rating aesthetics of single-implant crowns and adjacent soft tissues with regard to observer dental specialization. *Clin Implant Dent Relat Res.* 2009;11:201–13. [PubMed: 18657148]
18. Cho HL, Lee JK, Um HS, Chang BS. Esthetic evaluation of maxillary single-tooth implants in the esthetic zone. *J Periodontal Implant Sci.* 2010;40:188–93. [PMCID: PMC2931307] [PubMed: 20827328]
19. Vilhjálmsdóttir VH, Klock KS, Størksen K, Bårdsen A. Aesthetics of implant-supported single anterior maxillary crowns evaluated by objective indices and participants' perceptions. *Clin Oral Implants Res.* 2011;22:1399–403. [PubMed: 21443608]
20. Vaidya S, Ho YLE, Hao J, Lang NP, Mattheos N. Evaluation of the influence exerted by different dental speciality backgrounds and measuring instrument reproducibility on esthetic aspects of a maxillary implant-supported single crown. *Clin Oral Implants Res.* 2015;26:250–6. [PubMed: 25496129]
21. Al-Dosari A, Al-Rowis R, Moslem F, Alshehri F, Ballo AM. The esthetic outcome for maxillary anterior single implants assessed by different dental specialists. *J Adv Prosthodont.* 2016;8:345–53. [PMCID: PMC5099126] [PubMed: 27826384]
22. Altay MA, Sindel A, Tezerişener HA, Yıldırım N, Özarslan MM. Esthetic evaluation of implant-supported single crowns: A comparison of objective and patient-reported outcomes. *Int J Implant Dent.* 2019;5:2. [PMCID: PMC6321832] [PubMed: 30613918]
23. Chang M, Odman PA, Wennström JL, Andersson B. Esthetic outcome of implant-supported single-tooth replacements assessed by the patient and by prosthodontists. *Int J Prosthodont.* 1999;12:335–41. [PubMed: 10635203]
24. Chang M, Wennström JL, Odman P, Andersson B. Implant-supported single-tooth replacements compared to contralateral natural teeth. Crown and soft tissue dimensions. *Clin Oral Implants Res.* 1999;10:185–94. [PubMed: 10522178]

25. Cosyn J, De Rouck T. Aesthetic outcome of single-tooth implant restorations following early implant placement and guided bone regeneration: Crown and soft tissue dimensions compared with contralateral teeth. *Clin Oral Implants Res.* 2009;20:1063–9. [PubMed: 19519788]
26. Cosyn J, Eghbali A, de Bruyn H, Collys K, Cleymaet R, de Rouck T. Immediate single-tooth implants in the anterior maxilla: 3-year results of a case series on hard and soft tissue response and aesthetics. *J Clin Periodontol.* 2011;38:746–53. [PubMed: 21752044]
27. Cosyn J, Eghbali A, de Bruyn H, Dierens M, de Rouck T. Single implant treatment in healing versus healed sites of the anterior maxilla: An aesthetic evaluation. *Clin Implant Dent Relat Res.* 2012;14:517–26. [PubMed: 20662859]
28. den Hartog L, Raghoobar GM, Slater JJ, Stellingsma K, Vissink A, Meijer HJ. Single-tooth implants with different neck designs: A randomized clinical trial evaluating the aesthetic outcome. *Clin Implant Dent Relat Res.* 2013;15:311–21. [PubMed: 21815991]
29. Dueled E, Gotfredsen K, Trab Damsgaard M, Hede B. Professional and patient-based evaluation of oral rehabilitation in patients with tooth agenesis. *Clin Oral Implants Res.* 2009;20:729–36. [PubMed: 19515060]
30. Evans CD, Chen ST. Esthetic outcomes of immediate implant placements. *Clin Oral Implants Res.* 2008;19:73–80. [PubMed: 17956569]
31. Fava J, Lin M, Zahran M, Jokstad A. Single implant-supported crowns in the aesthetic zone: Patient satisfaction with aesthetic appearance compared with appraisals by laypeople and dentists. *Clin Oral Implants Res.* 2015;26:1113–20. [PubMed: 24863466]
32. Hall JA, Payne AG, Purton DG, Torr B, Duncan WJ, De Silva RK. Immediately restored, single-tapered implants in the anterior maxilla: Prosthodontic and aesthetic outcomes after 1 year. *Clin Implant Dent Relat Res.* 2007;9:34–45. [PubMed: 17362495]
33. Hartlev J, Kohberg P, Ahlmann S, Andersen NT, Schou S, Isidor F. Patient satisfaction and esthetic outcome after immediate placement and provisionalization of single-tooth implants involving a definitive individual abutment. *Clin Oral Implants Res.* 2014;25:1245–50. [PubMed: 24024479]
34. Jones AR, Martin W. Comparing pink and white esthetic scores to layperson perception in the single-tooth implant patient. *Int J Oral Maxillofac Implants.* 2014;29:1348–53. [PubMed: 25397797]
35. Lai HC, Zhang ZY, Wang F, Zhuang LF, Liu X, Pu YP. Evaluation of soft-tissue alteration around implant-supported single-tooth restoration in the anterior maxilla: The pink esthetic score. *Clin Oral Implants Res.* 2008;19:560–4. [PubMed: 18474062]
36. Luo Z, Zeng R, Luo Z, Chen Z. Single implants in the esthetic zone: Analysis of recent peri-implant soft tissue alterations and patient satisfaction. A photographic study. *Int J Oral Maxillofac Implants.* 2011;26:578–86. [PubMed: 21691605]
37. Meijndert L, Meijer HJ, Stellingsma K, Stegenga B, Raghoobar GM. Evaluation of aesthetics of implant-supported single-tooth replacements using different bone augmentation procedures: A prospective randomized clinical study. *Clin Oral Implants Res.* 2007;18:715–9. [PubMed: 17888016]
38. Misje K, Bjørnland T, Saxegaard E, Jensen JL. Treatment outcome of dental implants in the esthetic zone: A 12-to 15-year retrospective study. *Int J Prosthodont.* 2013;26:365–9. [PubMed: 23837168]
39. Petsos H, Trimpou G, Eickholz P, Lauer HC, Weigl P. The influence of professional competence on the inter-and intra-individual esthetic evaluation of implant-supported crowns in the anterior maxilla. *Clin Oral Implants Res.* 2017;28:453–60. [PubMed: 27009805]
40. Suphanantachai S, Thovanich K, Nisapakulorn K. The influence of peri-implant mucosal level on the satisfaction with anterior maxillary implants. *Clin Oral Implants Res.* 2012;23:1075–81. [PubMed: 22892063]

41. Vanlıoğlu BA, Kahramanoğlu E, Yıldız C, Ozkan Y, Kulak-Özkan Y. Esthetic outcome evaluation of maxillary anterior single-tooth bone-level implants with metal or ceramic abutments and ceramic crowns. *Int J Oral Maxillofac Implants*. 2014;29:1130–6. [PubMed: 25216139]
42. Hof M, Umar N, Budas N, Seemann R, Pommer B, Zechner W. Evaluation of implant esthetics using eight objectives indices-Comparative analysis of reliability and validity. *Clin Oral Implants Res*. 2018;29:697–706. [PubMed: 29926991]
43. Morton D, Chen ST, Martin WC, Levine RA, Buser D. Consensus statements and recommended clinical procedures regarding optimizing esthetic outcomes in implant dentistry. *Int J Oral Maxillofac Implants*. 2014;29:216–20. [PubMed: 24660199]
44. Landis JR, Koch GG. The measurement of observer agreement for categorical data. *Biometrics*. 1977;33:159–74. [PubMed: 843571]
45. Buser D, Martin W, Belser UC. Optimizing esthetics for implant restorations in the anterior maxilla: anatomic and surgical considerations. *Int J Oral Maxillofac Implants*. 2004;19:43–61. [PubMed: 15635945]
46. Bianchi AE, Sanfilippo F. Single-tooth replacement by immediate implant and connective tissue graft: A 1-9-year clinical evaluation. *Clin Oral Implants Res*. 2004;15:269–77. [PubMed: 15142088]
47. Chen ST, Darby IB, Reynolds EC. A prospective clinical study of non-submerged immediate implants: Clinical outcomes and esthetic results. *Clin Oral Implants Res*. 2007;18:552–62. [PubMed: 17608739]
48. Arunyanak SP, Pollini A, Ntounis A, Morton D. Clinician assessments and patient perspectives of single-tooth implant restorations in the esthetic zone of the maxilla: A systematic review. *J Prosthet Dent*. 2017;118:10–7. [PubMed: 28385430]

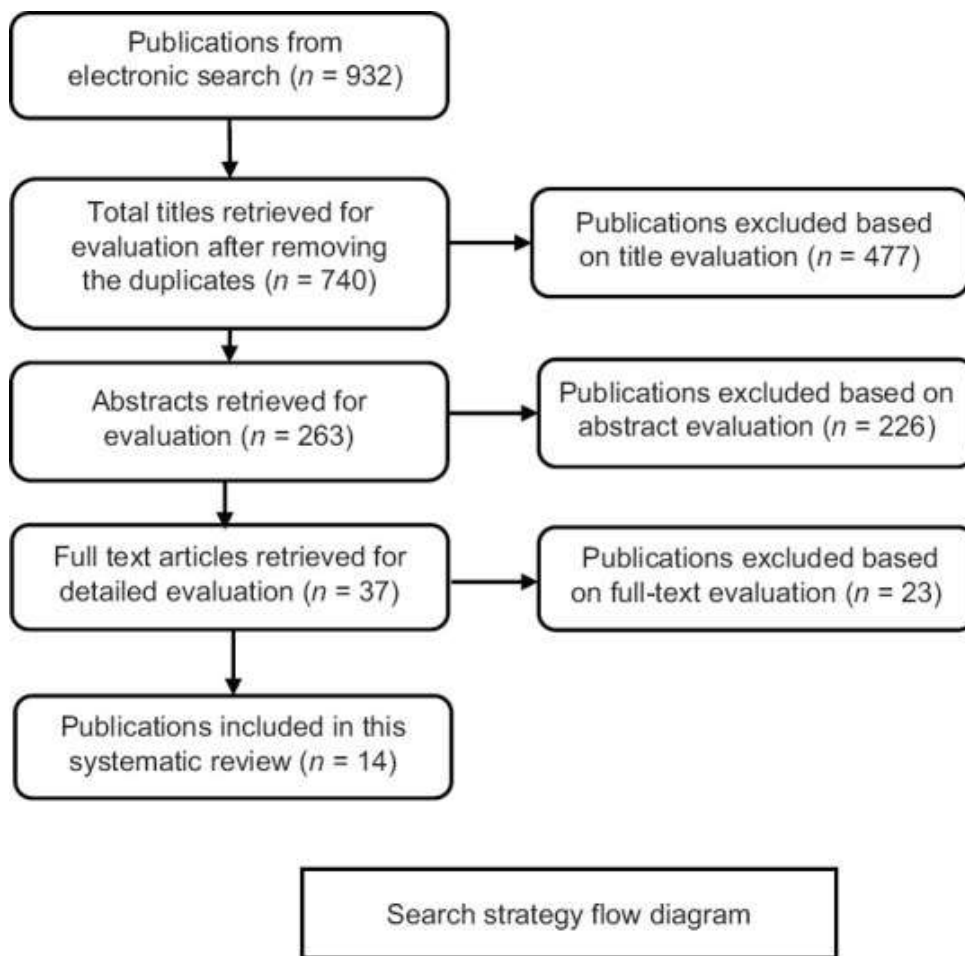
Figures and Tables

Table 1

Exclusion criteria

Study	Reasons for exclusion
Al-Dosari <i>et al.</i> [21]	Lack of reproducibility assessment
Altay[22]	Lack of reproducibility assessment
Chang <i>et al.</i> [23]	Lack of reproducibility assessment
Chang <i>et al.</i> [24]	Esthetic index was not used for assessment
Cosyn and De Rouck 2009[25]	Esthetic index was not used for assessment
Cosyn <i>et al.</i> [26]	Lack of reproducibility assessment
Cosyn <i>et al.</i> [27]	Lack of reproducibility assessment
den Hartog <i>et al.</i> [28]	Lack of reproducibility assessment
Dueled <i>et al.</i> [29]	No natural contralateral tooth, no esthetic index was used
Evans and Chen[30]	Lack of reproducibility assessment
Fava[31]	Lack of reproducibility assessment
Gotfredsen[4]	None of the esthetic indexes was used for assessment
Hall <i>et al.</i> [32]	Lack of reproducibility assessment
Hartlev <i>et al.</i> [33]	Lack of reproducibility assessment
Jones and Martin[34]	Assessment was not done by clinician
Lai <i>et al.</i> [35]	Lack of reproducibility assessment
Luo <i>et al.</i> [36]	Lack of reproducibility assessment
Meijndert <i>et al.</i> [37]	Lack of reproducibility assessment
Misje <i>et al.</i> [38]	None of the esthetic indexes was used for assessment
Petsos[39]	Lack of reproducibility assessment
Suphanantachat <i>et al.</i> [40]	None of the esthetic indexes was used for assessment
Testori <i>et al.</i> [8]	Case report
Vanhoğlu[41]	Lack of reproducibility assessment

Figure 1



Search strategy flow diagram. *n* – Number of articles

Table 2

Characteristics of the studies



Study and year	Number of patients/implants	Follow up period (in months)	Assessor	Assessment interval (in days)	Method	Esthetic index	Rating
Jemt 1997[6]	21/25	18	NR	11	Photographs	PI	5-point scale 0 papilla <half o height : or more comple papilla hyperp papilla
Fürhauser <i>et al.</i> , 2005[9]	30/30	15-143	20 assessors (5 oral surgeons, 5 prosthodontists, 5 orthodontists, 5 dental students)	28	Photographs	PES	0-1-2 s system maxim PES=1
Meijer <i>et al.</i> , 2005[10]	24/24	NR	4 assessors (2 oral surgeons, 2 prosthodontists)	14	Photographs	ICAI	No dev score 0 deviat score 1 deviat score 5
Gehrke <i>et al.</i> , 2008[16]	30/30	NR	15 assessors (3 general dentists, 3 oral surgeons, 3 orthodontists, 3 postgraduate students in implant dentistry, 3 lay people)	28	Photographs	PES	0-1-2 s system
Gehrke <i>et al.</i> , 2009[17]	23/23	NR	10 assessors (2 general dentists, 2	28	Photographs	ICAI	No dev - score Slight

[Open in a separate window](#)

PI – Papilla index; PES – Pink Esthetic Score; ICAI – Implant Crown Esthetic Index; PES/WES – Pink Esthetic Score/White Esthetic Score; mod-ICAI – Modified Implant Crown Esthetic Index; CEI – Complex Esthetic Index; CIS – Copenhagen Index Score; PICI – Peri-Implant and Crown Index; IREI – Implant Restoration Esthetic Index; IAS – Implant Esthetic Score; SES – Subjective Esthetic Score; NR – Not reported

Table 3

Summary of findings



Study and year	Esthetic score	Intra-observer agreement	Inter-observer agreement	Statistical analysis	Repro
Jemt 1997[6]	PI 1, PI 2 Mesial 1.44 2.48 Distal 1.52 2.46	Mean difference between values was 0.11 (SD=0.53)	NR	Sign test $P<0.001$	
Fürhauser <i>et al.</i> , 2005[9]	Mean PES 1=9.46 Mean PES 2=9.24	No statistically significant difference ($P=0.6379$)	NR	Chi-square test ANOVA and Tukey's test ($P<0.05$)	Good
Meijer <i>et al.</i> , 2005[10]	NR	Surgeons=67.1-84.7% Prosthodontists=86.1-86.6%	Surgeons=74.1% Prosthodontists=81.5% between different examiners=70.4%-82.4%	Cohen's κ	High
Gehrke <i>et al.</i> , 2008[16]	Mean PES 1=9.28 Mean PES 2=9.57	All specialty group=70.5% Orthodontists=73.5% lay people=65.9%	Spearman's $R=0.58$, $P=0$; $Z=3.383599$, $P=0.000716$	Spearman's rank correlation coefficient Wilcoxon signed-rank test	Good
Gehrke <i>et al.</i> , 2009[17]	Mean ICAI 1=10.4 Mean ICAI 2=9.73	Cohen's $\kappa=0.49$ ($P<0.001$).	A minimum agreement (Cohen's $K=0.11-0.37$, observer agreement: 40.2-66.3%).	Cohen's κ	Questio
Belser <i>et al.</i> , 2009[11]	Mean total PES/WES=14.7 \pm 1.18 Mean PES=7.8 \pm 0.88 Mean WES=6.9 \pm 1.47	NR	NR	Linear regression analysis was conducted	Suitabl
Cho <i>et al.</i> , 2010[18]	Mean total PES/WES=11.19 \pm 3.59 Mean PES=5.17 \pm 2.29 Mean WES=6.02 \pm 1.96	Very good and moderate agreements, Cohen's $\kappa=0.526-0.941$	NR	Weighted Cohen's κ Kruskal-Wallis analysis	Suitabl
Juodzbaly and Wang 2010[12]	NR	Cohen's Soft tissue: Predictive: Restoration κ	Examiner1: Examiner 2 Soft tissue 86% - 78% Predictive 82% - 66%	Weighted Cohen's kappa (k)	Reproc

[Open in a separate window](#)

PI – Papilla index; PES – Pink Esthetic Score; ICAI – Implant Crown Esthetic Index; PES/WES – Pink Esthetic Score/White Esthetic Score; mod-ICAI – Modified Implant Crown Esthetic Index; CEI – Complex Esthetic Index; CIS – Copenhagen Index Score; PICI – Peri-Implant and Crown Index; IREI – Implant Restoration Esthetic Index; IAS – Implant Esthetic Score; SES – Subjective Esthetic Score; NR – Not reported; ICC – Interclass correlation coefficients; P – Probability value

Articles from Journal of Indian Society of Periodontology are provided here courtesy of **Wolters Kluwer -- Medknow Publications**