

Erdheim–Chester disease: from palliative care to targeted treatment

Giorgio Graziani, Manuel A. Podestà, David Cucchiari, Francesco Reggiani and Claudio Ponticelli

Nephrology and Dialysis Unit, Humanitas Clinical and Research Center, Rozzano, Milano, Italy

Correspondence and offprint requests to: Giorgio Graziani; E-mail: giorgio.graziani@humanitas.it

Abstract

Erdheim–Chester disease (ECD) is a life-threatening multi-systemic non-Langerhans histiocytosis with cardiovascular complications as the leading cause of death. ECD affects the kidneys in up to 30% of cases, with fibrotic tissue deposition in the perirenal fat and renal hilum. Diagnosis is usually based on histological analysis of the pathologic tissue, which typically shows xanthogranulomatous infiltrates of foamy CD68+/CD1a- histiocytes surrounded by fibrosis. A consistent percentage of patients affected by ECD develop renal failure and hypertension as a consequence of renal artery stenosis and hydronephrosis. These conditions have been generally treated with the placement of stents and nephrostomies that frequently led to disappointing outcomes. Before the introduction of interferon-alpha (IFN α) treatment, the mortality rate was as high as 57% in the long term. Recent studies have granted new insights into the pathogenesis of ECD, which seems to bear a dual component of clonal and inflammatory disease. These advances led to use specific therapies targeting either the oncogenes (BRAF^{V600E}) or the effectors of the immune response implicated in ECD (IL-1, TNF α). Drugs such as anakinra (recombinant human IL-1 receptor antagonist), infliximab (monoclonal antibody against TNF α) and vemurafenib (inhibitor of mutant BRAF) showed promising results in small single-centre series. Although larger trials will be needed to address the impact of these drugs on ECD prognosis and to select the most effective treatment, targeted therapies hold the premises to drastically change the outcome of this condition.

Keywords: anakinra; Erdheim–Chester disease; infliximab; renal failure; vemurafenib

Introduction

Erdheim–Chester disease (ECD) is a non-Langerhans histiocytosis that affects multiple organs and systems. Since the first description by Erdheim and Chester in 1930, ~450 cases have been reported in international literature [1, 2]. The pathological hallmark of the disease is represented by xanthogranulomatous infiltrates of foamy CD68+/CD1a- histiocytes surrounded by fibrosis [3] (Figure 1). The clinical features are highly dependent on the degree and severity of organ involvement, leading to a multifaceted presentation and to a challenging diagnosis. The aetiology and pathogenesis of this condition remain poorly understood and also its classification as a tumoral or inflammatory disease is controversial [2, 4]. However, recent advances have allowed a better understanding of the pathogenesis of ECD and to the development of promising therapeutic strategies.

Clinical features and diagnosis

ECD is a multifaceted disorder, with various possible combinations of symptoms, which depend on the distribution and severity of organ involvement. Mean age at presentation is 55 years (range 16–80 years), and men are usually

affected more frequently than women [5]. Clinical features usually include constitutional symptoms, such as weight loss, fever, night sweats, muscle and joint pain, weakness and fatigue. Long bone involvement is almost universal, with bilateral symmetrical and diffuse osteosclerosis of knees and ankles, which causes juxta-articular pain in ~50% of cases [3, 6]. Another peculiar sign of ECD is the circumferential sheathing of the thoracic and abdominal aorta, which is complete in a minority of cases, giving the appearance of a ‘coated’ aorta at computed tomography (CT). Heart involvement is frequent and represents the leading cause of death. Cardiac symptoms are mainly due to pericardial effusion, with a high risk of cardiac tamponade. Myocardial infiltration may also cause a pattern described as ‘pseudotumour’ in the right heart. Myocardial infarction and valvular heart disease have also been reported. Indeed, heart failure induced by progressive myocardial fibrosis and/or pericardial effusion is the major cause of mortality [7]. Involvement of the brain and pituitary gland results in manifestations ranging from diabetes insipidus to cerebellar or pyramidal syndromes (ataxia, dysarthria and nistagmus), cognitive impairment and cranial nerve paralysis. The retro-orbital soft tissue is frequently invaded, leading to exophthalmus and vision impairment. Infiltration of liver, lungs, spleen, thyroid, skin, conjunctiva and false vocal cord may also occur [3, 8].

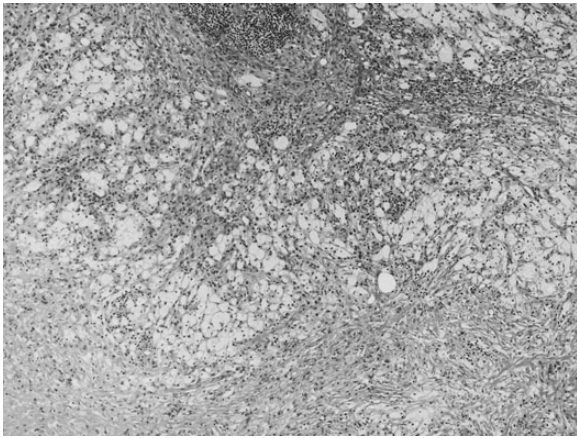


Fig. 1. Histological analysis of the perirenal fat in a patient with ECD, showing fibromuscular and adipose tissue with infiltrates of foamy histiocytes surrounded by fibrosis.

Kidneys may be involved in up to 30% of cases, with hypodense fibrotic tissue deposition in the perirenal fat and hilum. This fibrotic tissue usually encases both kidneys, conferring them a 'hairy' appearance on CT scans [8]. The progressive infiltration of the hilum often leads to renal artery compression, which is responsible for renovascular hypertension, ischaemic injury and renal failure. In addition, the long-standing compression of renal parenchyma may result in renin-angiotensin-aldosterone system activation, leading to renovascular hypertension, even in the absence of a significant renal artery obstruction (Page kidney phenomenon) [9]. In some cases, the fibrotic tissue deposition may also cause extrinsic obstruction of the pelvis and the proximal ureteral segments, inducing bilateral hydronephrosis and post-renal kidney injury. Kidney involvement is rarely symptomatic, but disease progression leads to end-stage renal disease in a rather high percentage of cases [10, 11].

Histological analysis of the perirenal infiltrates is the gold standard for the diagnosis. ECD needs to be distinguished from immune-mediated or secondary (radio-induced) retroperitoneal fibrosis (RPF), a rare disease that often causes hydronephrosis and urinary tract obstruction. In ECD both the vena cava and pelvic ureters are usually unaffected, while in RPF a more extensive involvement may be demonstrated by imaging techniques. In addition, histological analysis in RPF cases usually shows diffuse inflammatory infiltrates, typically with a central core of CD20+ cells and a mantle of CD3+ cells, with plasma cells positive for the IgG4 isotype [12].

Pathogenesis

ECD pathogenesis is still incompletely understood, with contrasting evidence supporting the theory of either a reactive or a malignant disorder. Assessment of clonality using different strategies has been inconclusive, with studies favouring either monoclonality or polyclonality [13, 14].

Consistent efforts have been directed towards the elucidation of the mechanism by which histiocytes are recruited and accumulate in ECD. In a study by Stoppacciaro *et al.* [15], the low expression of the proliferation marker Ki-67 on ECD histiocytes, coupled with the absence of mitosis, led the authors to conclude that the pathogenetic

contribution of proliferation to the disease is limited. The same investigators also demonstrated a high expression on foamy histiocytes of chemokine/chemokine receptor pairs implied in monocyte migration activity (i.e. CCR1, CCR2, CCR3, CCR5 and the ligands CCL4, CCL2, CCL20 and CCL5). The interaction of these molecules may generate an autocrine loop, leading to histiocytes recruitment and accumulation. In addition, they described a prominent T-helper lymphocyte infiltration with intense IFN γ staining and the expression on histiocytes of IP-10, which is an IFN γ -induced chemokine. These findings were consistent with a Th1-oriented inflammatory response. Histiocyte-secreted chemokines such as CCL5, IP-10, CCL19 and CCL2 may be responsible for the recruitment of these lymphocytes, which in turn may determine histiocyte activation and chemokine production, in a self-renewing loop.

Aouba *et al.* [16] measured the serum levels of different cytokines and the expression of IL-1 α on the surface of monocyte cell from two ECD patients. The authors found that the levels of pyrogenic cytokines such as IL-6, TNF α and IL-1 β , as well as the expression of IL-1 α on monocytes, were significantly higher in these patients compared with the controls. The authors also demonstrated an abrupt decrease of IL-1 α expression following the administration of Anakinra, a recombinant non-glycosylated form of human IL-1 receptor antagonist (IL-1Ra). This study suggested a pivotal role for IL-1 cytokine family as a main actor in ECD pathogenesis.

Other investigators advocated a central role of tumour necrosis factor alpha (TNF α) in ECD patients. In addition to increased levels of IL-1 β , IL-6, CCL2 and CCL5, Dagna *et al.* [17] also found high levels of plasma soluble TNF receptor I (sTNFRI) and II (sTNFRII), which are considered as markers of TNF α activity. This hypothesis was supported by the decrease of these markers during anti-TNF α therapy with infliximab.

Arnaud *et al.* [18] further elucidated the cytokine pattern underlying ECD pathophysiology. In a large series of 37 patients they demonstrated that a 5 cytokine signature (IFN α , IL-12, MCP-1, IL-4 and IL-7) could be used to identify ECD patients.

Taken together, all these data seem to tip the scale towards an inflammatory origin of the disease, specifically a Th1-oriented disorder. Nevertheless, recent findings led to disprove this one-sided view. Haroche *et al.* [19] reported that in 13 of 24 ECD patients histiocytes harboured an activating mutation of the proto-oncogene BRAF (BRAF^{V600E}), which is involved in the mitogen-activated protein kinase (MAPK) pathway. Recent studies indicated that the percentage of ECD patients carrying a BRAF mutation might have been initially underestimated. Cangi *et al.* [20] detected BRAF^{V600E} exploiting an ultrasensitive technique in all of their 18 patients, but they were able to identify the mutation only in 12 patients when using conventional techniques. The same mutation was also detected on peripheral blood mononuclear cells from all of the patients and in none of the serum from controls. Other authors also described single cases of ECD with somatic activating mutations of NRAS, a proto-oncogene upstream of BRAF in the MAPK pathway [21, 22]. This further emphasizes the relevance of activating mutations in the pathogenesis of ECD.

Interestingly, activating mutations of the MAPK pathway have been linked to oncogene-induced senescence, a protective mechanism against neoplastic transformation characterized by the expression of high levels of oncosuppressor proteins (i.e. p16^{Ink4a}), which can induce a

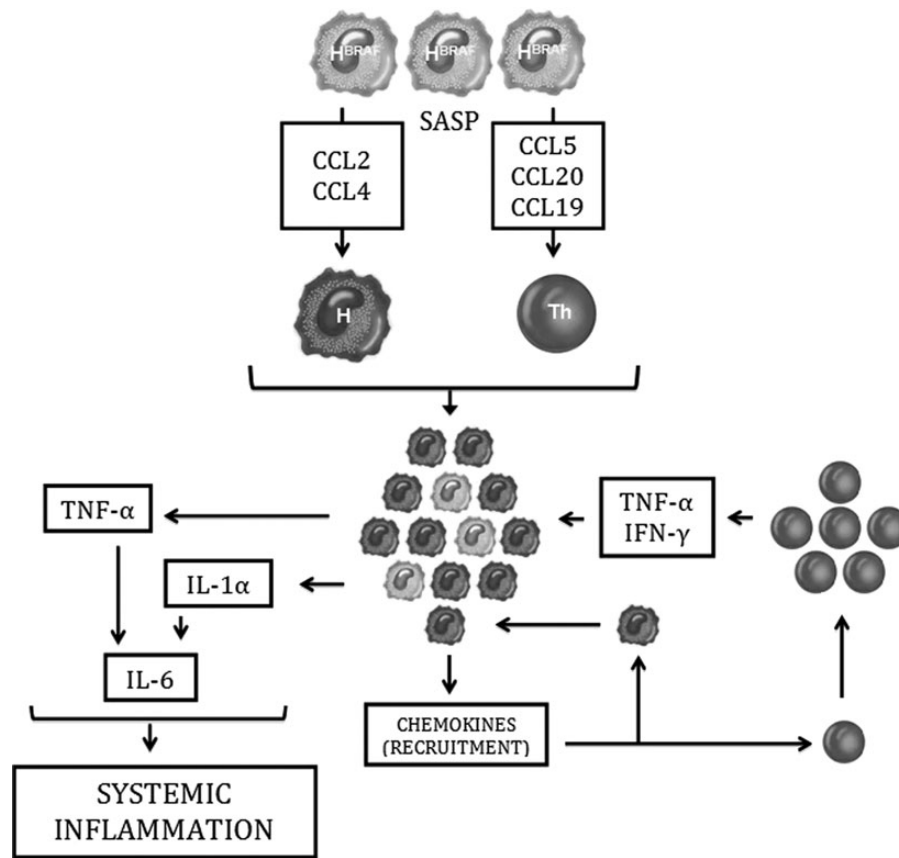


Fig. 2. Hypothesis on the pathogenesis of ECD (see text for explanation). H^{BRAF}: BRAF^{V600E} mutated histiocytes; SASP: senescence-associated secretory phenotype; H: wild-type histiocytes; Th: T-helper lymphocytes.

senescence-associated secretory phenotype [23, 24]. This inflammatory response is characterized by the expression of cytokines/chemokines that resembles the cytokine pattern of ECD histiocytes, and which could lead to the recruitment of non-mutated histiocytes at the lesion site [20]. This may represent the link between the two pathogenetic hypotheses regarding ECD: an oncogenic mutation responsible for a limited clonal proliferation that leads to a senescence-associated secretory phenotype and a Th1-oriented inflammatory response capable of worsening the initial lesion (Figure 2). Further work is needed to clarify the contribution of each of these components to ECD pathogenesis.

Treatment

There is currently no consensus on the best treatment for ECD. This is largely due to the lack of clinical trials, which are difficult to be realized owing to the rarity of this condition. Before the introduction of targeted therapies, the therapeutical approach to kidney involvement was mainly based on palliative treatments such as renal artery or ureteral stenting, the latter being often complicated by bladder irritation, dislocation, infection and blockage by encrustation.

Steroids were initially the most commonly employed systemic therapy, along with other cytotoxic drugs. In a series of 17 of 59 patients presented with retroperitoneal involvement that led to hydronephrosis and renal

Table 1. Therapeutic approaches to ECD

| Treatment | Target | Author (first reported) | Year | Largest series |
|--------------------------------|-------------------------|----------------------------------|------|----------------|
| Steroids | Glucocorticoid receptor | Veyssier-Belot <i>et al.</i> [3] | 1996 | 20 patients |
| Cladribine | Adenosine deaminase | Myra <i>et al.</i> [25] | 2004 | 1 patient |
| IFN α /PEG-IFN α | CD40L | Braiteh <i>et al.</i> [27] | 2005 | 46 patients |
| Anakinra | IL-1 | Aouba <i>et al.</i> [16] | 2010 | 2 patients |
| Infliximab | TNF α | Dagna <i>et al.</i> [17] | 2012 | 2 patients |
| Vemurafenib | BRAF ^{V600E} | Haroche <i>et al.</i> [34] | 2013 | 3 patients |

impairment in less than a half of cases. However, the reported mortality rate was 57%, with respiratory distress and heart failure as the most common cause of death [3]. Cladribine, a purine analogue that causes monocyte and T-lymphocyte depletion, obtained partial regression of ocular or cerebral symptoms in few cases, but the evidence supporting this therapy is anecdotal [25, 26], and no data on the efficacy on kidney involvement are available (Table 1).

ECD prognosis improved after Braiteh *et al.* introduced IFN α therapy in three patients with advanced systemic involvement: in a subsequent survival analysis, treatment with IFN α was an independent predictor of survival [27, 28]. Indeed, IFN α may activate CD40-ligand, a member of the TNF superfamily which binds to CD40 on dendritic cells. CD40-ligand accelerates the maturation of dendritic

cells and favours immune-mediated destruction of histiocytes. Moreover, IFN α not only exerts immunomodulatory effects but can also inhibit the inflammatory response by reducing lesional histiocyte recruitment. Single-centre experiences provided proof of the efficacy of IFN α on renal involvement [29]. Nevertheless, the beneficial effect of IFN α therapy seems to depend on individual response and on organs involved. Moreover, only high doses of the drug could obtain a significant improvement of symptoms in $\sim 2/3$ of patients, but half of them complained of severe side effects [16].

In the last few years, new insights on ECD pathogenesis led to test targeted therapies, which showed promising results. Anakinra is a recombinant, non-glycosylated form of human IL-1Ra which binds to IL-1 membrane receptor and down-regulates the biologic activities of IL-1, including inflammation [30]. This effect is somewhat similar to that exerted by IFN α , which, in fact, increases the expression of IL-1Ra. Aouba et al. [16] first reported a significant reduction of IL-1 α (a form expressed at the monocytes membrane surface after cell stimulation) following treatment with Anakinra in two ECD patients. One of the patients presented with a history of retroperitoneal and periureteral fibrosis associated to bilateral hydronephrosis, which was unresponsive to corticosteroids and required bilateral ureteral stenting. Another patient had right ureteral stenosis and periarterial lesions with renal artery stenosis and renovascular hypertension, which were partially responsive to IFN α . Both patients showed a good response to the administration of 100 mg/day of anakinra, with reversal of hydronephrosis and total/partial recovery of renal function. Anakinra also showed relevant beneficial effects in ECD patients with extensive skeletal lesions [31] or with severe cardiac involvement [32]. In all cases the treatment induced a reduction of inflammatory markers, fever and other ECD-related systemic symptoms. In addition, the treatment was generally well tolerated, especially when compared with the high occurrence of side effects during IFN α therapy.

Infliximab, a chimeric monoclonal antibody against TNF α , at a dose of 5 mg/kg every 6 weeks has been successfully employed in two cases of ECD with cardiovascular involvement [17]. This therapy induced a marked improvement of symptoms and cardiac function, mainly due to the reduction of pericardial effusion and infiltrating tissue. TNF α was recently linked to endothelial barrier disruption in ECD patients, which was prevented *in vitro* by the administration of infliximab: this may explain the marked activity of the drug on cardiac involvement [33]. However, only one patient from this study presented with bilateral renal artery stenosis-induced renal failure, and the follow-up was too short to show any difference in kidney infiltrates.

Finally, the inhibitor of mutant BRAF vemurafenib at a dose of 1920 mg/day has shown dramatic efficacy in three BRAF^{V600E} mutated cases of ECD. The treatment had a rapid effect on cardiovascular, skin and ocular involvement. In one of the patients, vemurafenib induced a complete resolution of hydronephrosis and pyelocaliceal dilation, which allowed the removal of nephrostomies and ureteral stents [34].

Although anecdotal, these reports may pave the way to a therapy targeted to different pathogenic mechanisms. This may lead to a deeper understanding of ECD pathogenesis and may contribute to lower the mortality associated to this systemic condition. Larger trials are required to assess the efficacy of each treatment and determine the best approach to ECD.

Acknowledgement. The authors thank Dr Fiamengo for taking the histologic pictures.

Conflict of interest statement. None declared.

(See related article by Rademacher et al. Erdheim-Chester disease and knee pain in a dialysis patient. *Clin Kidney J* 2014; 7: 402–405)

References

- Chester W. Über Lipoidgranulomatose. *Virchows Arch Pathol Anat* 1930; 279: 561–602
- Dagna L, Giralda S, Langheim S et al. Erdheim-Chester disease: report on a case and new insights on its immunopathogenesis. *Rheumatology (Oxford)* 2010; 49: 1203–1206
- Veyssier-Belot C, Cacoub P, Caparros-Lefebvre D et al. Erdheim-Chester disease. Clinical and radiologic characteristics of 59 cases. *Medicine (Baltimore)* 1996; 75: 157–169
- Wilejto M, Abla O. Langerhans cell histiocytosis and Erdheim-Chester disease. *Curr Opin Rheumatol* 2012; 24: 90–96
- Haroche J, Arnaud L, Cohen-Aubart F et al. Erdheim-Chester disease. *Curr Rheumatol Rep* 2014; 16: 412
- Rademacher S, Anagnostopoulos J, Luft FC et al. Erdheim-Chester disease and knee pain in a dialysis patient. *Clin Kidney J* 2014; 7: 402–405
- Haroche J, Cluzel P, Toledano D et al. Images in cardiovascular medicine. Cardiac involvement in Erdheim-Chester disease: magnetic resonance and computed tomographic scan imaging in a monocentric series of 37 patients. *Circulation* 2009; 119: e597–e598
- Haroche J, Arnaud L, Amoura Z. Erdheim-Chester disease. *Curr Opin Rheumatol* 2012; 24: 53–59
- Samson M, Rossi C, Soltani Z et al. Perirenal fibrosis: make your diagnosis. *Clin Kidney J* 2013; 6: 543–544
- Verdalles U, Goicoechea M, Garcia de Vinuesa S et al. Erdheim-Chester disease: a rare cause of renal failure. *Nephrol Dial Transplant* 2007; 22: 1776–1777
- Sandal S, Zand M. Page kidney phenomenon secondary to an atypical presentation of Erdheim-Chester disease. *Clin Kidney J* 2013; 6: 547–548
- Corradi D, Maestri R, Palmisano A et al. Idiopathic retroperitoneal fibrosis: clinicopathologic features and differential diagnosis. *Kidney Int* 2007; 72: 742–753
- Dickson BC, Pethe V, Chung CT et al. Systemic Erdheim-Chester disease. *Virchows Arch* 2008; 452: 221–227
- Gong L, He XL, Li YH et al. Clonal status and clinicopathological feature of Erdheim-Chester disease. *Pathol Res Pract* 2009; 205: 601–607
- Stoppacciaro A, Ferrarini M, Salmaggi C et al. Immunohistochemical evidence of a cytokine and chemokine network in three patients with Erdheim-Chester disease: implications for pathogenesis. *Arthritis Rheum* 2006; 54: 4018–4022
- Aouba A, Georgin-Lavialle S, Pagnoux C et al. Rationale and efficacy of interleukin-1 targeting in Erdheim-Chester disease. *Blood* 2010; 116: 4070–4076
- Dagna L, Corti A, Langheim S et al. Tumor necrosis factor alpha as a master regulator of inflammation in Erdheim-Chester disease: rationale for the treatment of patients with infliximab. *J Clin Oncol* 2012; 30: e286–e290
- Arnaud L, Gorochov G, Charlotte F et al. Systemic perturbation of cytokine and chemokine networks in Erdheim-Chester disease: a single-center series of 37 patients. *Blood* 2011; 117: 2783–2790
- Haroche J, Charlotte F, Arnaud L et al. High prevalence of BRAF V600E mutations in Erdheim-Chester disease but not in other non-Langerhans cell histiocytoses. *Blood* 2012; 120: 2700–2703
- Cangi MG, Biavasco R, Cavalli G et al. BRAFV600E-mutation is invariably present and associated to oncogene-induced senescence in Erdheim-Chester disease. *Ann Rheum Dis* 2014; doi: 10.1136/annrheumdis-2013-204924 [Epub ahead of print]

21. Diamond EL, Abdel-Wahab O, Pentsova E *et al.* Detection of an NRAS mutation in Erdheim-Chester disease. *Blood* 2013; 122: 1089–1091
22. Aitken SJ, Presneau N, Tirabosco R *et al.* An NRAS mutation in a case of Erdheim Chester disease. *Histopathology* 2014; doi: 10.1111/his.12443 [Epub ahead of print]
23. Michaloglou C, Vredeveld LC, Soengas MS *et al.* BRAFE600-associated senescence-like cell cycle arrest of human naevi. *Nature* 2005; 436: 720–724
24. Acosta JC, Banito A, Wuestefeld T *et al.* A complex secretory program orchestrated by the inflammasome controls paracrine senescence. *Nat Cell Biol* 2013; 15: 978–990
25. Myra C, Sloper L, Tighe PJ *et al.* Treatment of Erdheim-Chester disease with cladribine: a rational approach. *Br J Ophthalmol* 2004; 88: 844–847
26. Adam Z, Sprlakova A, Rehak Z *et al.* Partial regression of CNS lesions of Erdheim-Chester disease after treatment with 2-chlorodeoxyadenosine and their full remission following treatment with lenalidomide. *Klin Onkol* 2011; 24: 367–381
27. Braiteh F, Boxrud C, Esmaeli B *et al.* Successful treatment of Erdheim-Chester disease, a non-Langerhans-cell histiocytosis, with interferon-alpha. *Blood* 2005; 106: 2992–2994
28. Arnaud L, Hervier B, Neel A *et al.* CNS involvement and treatment with interferon-alpha are independent prognostic factors in Erdheim-Chester disease: a multicenter survival analysis of 53 patients. *Blood* 2011; 117: 2778–2782
29. Loddenkemper K, Hoyer B, Loddenkemper C *et al.* A case of Erdheim-Chester disease initially mistaken for Ormond's disease. *Nat Clin Pract Rheumatol* 2008; 4: 50–55
30. Stewart RJ, Marsden PA. Biologic control of the tumor necrosis factor and interleukin-1 signaling cascade. *Am J Kidney Dis* 1995; 25: 954–966
31. Aubert O, Aouba A, Deshayes S *et al.* Favorable radiological outcome of skeletal Erdheim-Chester disease involvement with anakinra. *Joint Bone Spine* 2013; 80: 206–207
32. Killu AM, Liang JJ, Jaffe AS. Erdheim-Chester disease with cardiac involvement successfully treated with anakinra. *Int J Cardiol* 2013; 167: e115–e117
33. Ferrero E, Belloni D, Corti A *et al.* TNF-alpha in Erdheim-Chester disease pericardial effusion promotes endothelial leakage in vitro and is neutralized by infliximab. *Rheumatology (Oxford)* 2014; 53: 198–200
34. Haroche J, Cohen-Aubart F, Emile JF *et al.* Dramatic efficacy of vemurafenib in both multisystemic and refractory Erdheim-Chester disease and Langerhans cell histiocytosis harboring the BRAF V600E mutation. *Blood* 2013; 121: 1495–1500

Received for publication: 7.3.14; Accepted in revised form: 10.6.14