

Thrombotic thrombocytopenic purpura and defective apoptosis due to CASP8/10 mutations: the role of mycophenolate mofetil

F. Fioredda,¹ E. Cappelli,¹ A. Mariani,¹ A. Beccaria,¹ E. Palmisani,¹ A. Grossi,² I. Ceccherini,² R. Venè,³ C. Micalizzi,¹ M. Calvillo,¹ F. Pierri,¹ I. Mancini,⁴ F. Peyvandi,^{5,6} F. Corsolini,⁷ C. Dufour,¹ and M. Miano¹

¹Unit of Haematology and ²Medical Genetics Unit, IRCCS Istituto Giannina Gaslini, Genoa, Italy; ³Molecular Oncology and Angiogenesis Unit, IRCCS AOU San Martino-IST, Genoa, Italy; ⁴Fondazione IRCCS Ca' Granda Ospedale Maggiore Policlinico, Angelo Bianchi Bonomi Hemophilia and Thrombosis Center, Università degli Studi di Milano, Department of Pathophysiology and Transplantation and Fondazione Luigi Villa, Milan, Italy; ⁵Department of Pathophysiology and Transplantation, Università degli Studi di Milano and Fondazione Luigi Villa, Milan, Italy; ⁶Fondazione IRCCS Ca' Granda Ospedale Maggiore Policlinico, Angelo Bianchi Bonomi Hemophilia and Thrombosis Center, Milan, Italy; and ⁷Laboratory of Molecular Genetics and Biobanks, IRCCS Istituto Giannina Gaslini, Genoa, Italy

Key Points

- Immunological dysregulation may underlie unusual autoimmune diseases, which also deserve to be investigated from a genetic point of view.

Introduction

Thrombotic thrombocytopenic purpura (TTP) is a rare, life-threatening disorder characterized by microvascular platelet clumping and microangiopathic hemolytic anemia, often accompanied by renal dysfunction and neurological symptoms.¹ The underlying pathophysiological mechanism is due to a defective ADAMTS13 protein, either congenital or secondary to the anti-ADAMTS antibodies that switch off its function. Acquired TTP occurs mainly in women, rarely in children, and has also been described in association with known autoimmune disorders (ie, systemic lupus erythematosus).^{1,2}

The gold standard therapy for TTP is plasma exchange together with high-dose steroids or immunoglobulins. Drugs such as rituximab are indicated in cases of failure/relapse. Vincristine, cyclophosphamide, azathioprine, and cyclosporine have also been used with a certain efficacy,³⁻⁵ and splenectomy has been performed with a positive outcome in patients with refractory or relapsing disease.⁶ To the best of our knowledge, correlation between acquired TTP and immune dysregulation due to a defect in components of the apoptosis pathway have never previously been described.

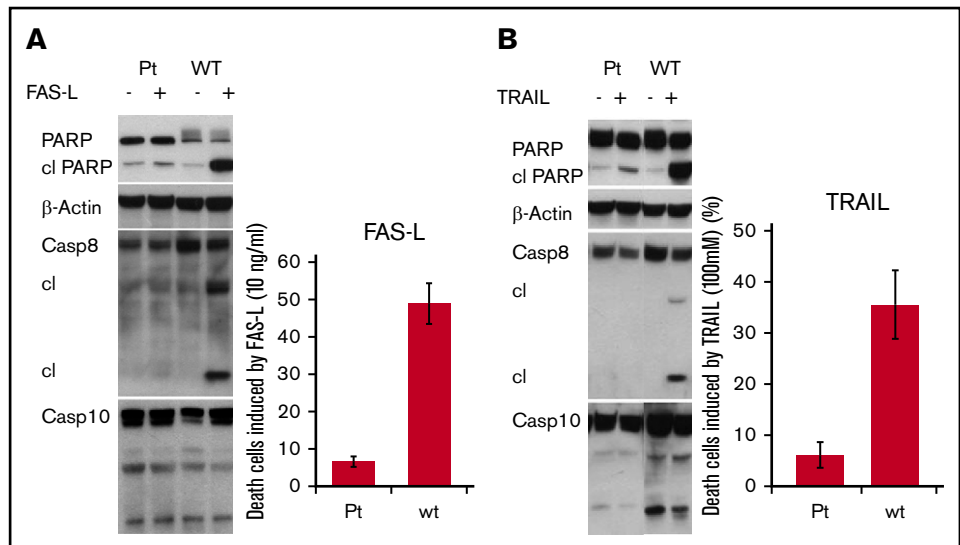
Case description

An Ecuador-born female patient came to us for the first time for observation at 18 years of age due to easy bruising and hematuria. Her platelet count was $4 \times 10^9/L$, and acute non-autoimmune hemolytic anemia was indicated (hemoglobin, 6 g/dL; lactate dehydrogenase, 2964 IU/L; reticulocyte count, $200 \times 10^9/L$; haptoglobin, <2 mg/dL; schistocytes on the blood smear; and negative results on direct and indirect antiglobulin tests). The patient carried antithyroglobulin antibodies; in addition, antinuclear antibodies, antibodies against double-stranded DNA, extractable nuclear antigens, antiphospholipid antibodies, and complement components (C3 and C4) were negative. Previously in Ecuador, the patient had had 2 similar episodes at the age of 10 and 15 years, successfully treated with transfusions and immunoglobulins. A long remission occurred between the 2 events without any therapy.

The differential diagnosis initially considered between relapsing Evans syndrome treated with high-dose steroids and immunoglobulins and atypical hemolytic uremic syndrome/TTP. The patient was empirically treated with plasma infusions, with substantial improvement in clinical status.

Following steroid suspension, the patient's platelet count dropped again below $10 \times 10^9/L$, and hemolysis relapsed. This oriented treatment toward a plasma exchange procedure. Unfortunately, the patient could not tolerate the procedure because of a severe reaction characterized by malaise, hypotension, and hives. Rescue therapy with a second cycle with immunoglobulin was administered, and mycophenolate mofetil (MMF) at a dose of 600 mg/mq twice a day was started as "maintenance" treatment.

Figure 1. Lower cell death after stimulation of apoptosis by FAS-L/TRAIL and reduction of CASP8 and PARP cleavage due to reduced activity of CASP10 protein in our patient (pt) compared to the control. (A) Apoptosis proteins cleavage and cell death induced by FAS-L (10 ng/mL); values given as percentage. (B) Apoptosis proteins cleavage and cell death stimulated by TRAIL (100 mM); values given as percentage. cl, cleaved; wt, wild type.



The choice of MMF was based on our recent encouraging results in refractory cytopenias.⁷ Given the stability of the hematological values, after 2 weeks of MMF, the therapeutic strategy was not shifted to rituximab. We preferred MMF to rituximab, even after confirmation of the TTP diagnosis, because the good initial response reported in autoimmune cytopenias is outbalanced by rarely maintained long-term remission and by the risk of iatrogenic, deep and prolonged hypogammaglobulinemia.^{8,9} Indeed, rituximab therapy, mainly in the pre-“low-dose” era, had a stronger impact on B cells and immunoglobulin G concentrations, which remain below the threshold for many months (requiring, in some cases, immunoglobulin replacement therapy).¹⁰

Methods and results

Despite normal platelet values and resolution of hemolysis, low levels of ADAMTS13 (<3% activity as measured by using the FRET-S-VWF73 assay; normal range, 45%-138%) and positivity for antibodies against ADAMTS13 (62 U/mL as measured by using the Technozym ADAMTS-13 Inhibitor assay [Technoclone GmbH]) were shown.¹¹ The patient continued MMF, and remission lasted >12 months. After that time span, another relapse occurred that was attributed to poor MMF compliance. A new plasma exchange cycle (plus steroids) was performed, and this time it was well tolerated. After 2 months, stable remission was again achieved; the patient has been motivated to adequately comply with the MMF regimen. To date, 19 months later, the patient is again in remission (steroid free), and the trough MMF plasma levels are in the therapeutic range (1-4 mg/mL).¹²

ADAMTS13 activity remained below the threshold, and antibodies against ADAMTS13 persisted as positive both in the “active” periods and during the remission phases of the disease. An expanded immunological evaluation was normal (even the CD3⁺ T-cell receptor αβ⁺ CD4⁻ CD8⁻ double-negative T cells), lymphoproliferation was absent, and the *in vitro* FAS-mediated apoptosis test result was normal. Molecular studies were performed by using an enlarged next-generation sequencing panel, which surprisingly showed a homozygous variant in CASP8 and a heterozygous variant in CASP10. The caspase-8 gene showed a homozygous mutation, c.2T>C (RefSeq NM_001080125.1), which led to

a p.Met1Thr change, affecting the start codon. This variant, although rare in different populations, is relatively common in South America, with an allelic frequency of 12% and with ~1% to 2% of the population being homozygote-CC (ExAC Browser, <http://exac.broadinstitute.org/>).

In fact, western blotting of the extract of lymphoblast cells obtained from the patient showed normal expression of procaspase-8 (Figure 1A), probably a “different” protein with uncertain functionality. (Informed consent had been obtained from the patient, and all experiments were performed in accordance with the approved guidelines.) Treatment with FAS-L aimed to induce apoptosis generated a cleavage activation of caspase-8 only in the wild-type cell line and not in the patient’s lymphoblasts, suggesting that the mutation altered protein function and maintained an impaired apoptotic pathway. The heterozygous CASP10 variant (NM_032977.3: c.1564T>A) leading to a Leu522Ile missense change did not substantially alter the expression of the protein (Figure 1A-B). This variant is generally classified as a high-frequency polymorphism (EXAC DATABASE, <http://exac.broadinstitute.org/>) even if it was reported with a probably damaging role in most prediction tools; it has also been shown to be associated with an impaired apoptotic capacity.^{13,14}

The additional weak cleavage inactivation of the PARP protein, along with FAS-L treatment that did not induce any apoptotic death (Figure 1A), suggests an overall reduction in apoptotic activity in the patient’s lymphoid cells.

The same experimental setting adopted for FAS-L was repeated with TRAIL, the other apoptosis inducer, thus confirming the impairment of the CASP pathway in the patient’s lymphoid cells (Figure 1B).¹⁵

Discussion

The current report contains 2 main peculiarities: the association between acquired TTP and mutations in the CASP8/10 genes, usually responsible for different disorders, and its management with a “nonconventional” immunosuppressive drug. Caspases are cysteine proteases that play a central role in apoptosis. Caspase-8 and caspase-10 may be the first enzymes in the

proteolytic cascade that are activated by FAS ligand and tumor necrosis factor. The absence of an immunomodulatory function of CASP8, enhanced by its lack of negative regulation by CASP10, interrupts the cleavage of CASP3, increases PARP pathway signaling, and causes hyperactivation of Akt—mammalian target of rapamycin.^{16,17} According to the literature, mutations in either CASP8 or CASP10 (being implicated in programming life and death of immune cells) influence immune surveillance of malignancies and cause lymphoproliferation (autoimmune lymphoproliferative syndrome type IIA and B).^{13,18-21} In addition, the interplay between caspase-8 and caspase-10 proteins, which share substrates and functions, is crucial for the maintenance of regular apoptosis.²¹ The hypothesis, recently addressed in an article from our group, is that the association of 2 variants on genes involved in the same pathway, even if polymorphic, might contribute to the development of immune dysregulation.¹⁴ Indeed, we speculate that the mutations found in our patient do not affect lymphocyte accumulation but generate a negative synergy expressed as autoimmunity against the ADAMTS13 protein. Even if direct causality between the hyperactivation of Akt—mammalian target of rapamycin and autoimmune TTP cannot be proved, an immune dysregulation was at the basis of the phenomenon affecting the patient. It is worth noting that our patient was also studied for 315 adjunctive genes involved in hematological disorders, immune deficiencies, and immune dysregulations, with negative results. Nevertheless, we cannot exclude that other genetic lesions in genes not covered by our panel might have contributed to the clinical phenotype of the study patient, but the knowledge of the impaired apoptosis pathway represents a suggestion for a tailored treatment.

Regarding the response to treatment, MMF, on account of the inhibition of B, T, and natural killer cells, has been shown to be effective in autoimmune cytopenia and in a number of other autoimmune diseases.²²⁻²⁴ In this patient, MMF seemed to have had a certain efficacy in the maintenance of autoimmunity suppression against ADAMTS13 with no undesirable effects. Moreover, according to a recent article, persistent low ADAMTS13 activity, as observed in our patient, seems to be a predictor of relapse

and thus indicates a possible role for a preemptive immunosuppression regimen.²⁵

The very last “lesson” of this experience is that patients presenting with refractory autoimmune cytopenia and/or unusual autoimmune targets should be studied by using an extended genetic panel directed to identify “disimmunity.” The aim is to better understand the mechanism and identify possible targeted drugs.

Acknowledgment

This work was supported by the Italian Ministry of Health (Ricerca corrente 2019).

Authorship

Contribution: F.F., C.D., and M.M. conceived and designed the research and wrote the paper; E.C., A.G., I.C., R.V., I.M., F.P., and F.C. performed the laboratory investigations; A.M. and A.B. collected data and drafted the paper; and E.P., C.M., M.C., and F.P. collected the materials and cared for the patient.

Conflict-of-interest disclosure: I.M. has received honoraria for participating as a speaker at an educational meeting organized by Instrumentation Laboratory and for participating at a Sanofi advisory board meeting. F.P. is a member of the scientific advisory board of Bioerativ, Roche, Sanofi, and Takeda. The remaining authors declare no competing financial interests.

ORCID profiles: F.F., 0000-0003-1504-5511; E.C., 0000-0001-5910-9260; A.B., 0000-0002-1712-6529; E.P., 0000-0003-2812-653X; A.G., 0000-0002-4570-3485; I.C., 0000-0001-8732-1955; R.V., 0000-0002-2522-3716; C.M., 0000-0002-7371-1431; M.C., 0000-0002-5925-4318; F. Pierri, 0000-0002-0005-4127; I.M., 0000-0002-5059-5212; F. Peyvandi, 0000-0001-7423-9864; F.C., 0000-0003-0016-3400; C.D., 0000-0002-5980-5474; M.M., 0000-0002-9816-1704.

Correspondence: F. Fioredda, Unit of Haematology, IRCCS Istituto Giannina Gaslini, Largo G Gaslini 5, 16147 Genoa, Italy; e-mail: francescafioredda@gaslini.org.

References

1. Joly BS, Coppo P, Veyradier A. Thrombotic thrombocytopenic purpura. *Blood*. 2017;129(21):2836-2846.
2. Joly BS, Stepanian A, Leblanc T, et al; French Reference Center for Thrombotic Microangiopathies. Child-onset and adolescent-onset acquired thrombotic thrombocytopenic purpura with severe ADAMTS13 deficiency: a cohort study of the French national registry for thrombotic microangiopathy. *Lancet Haematol*. 2016;3(11):e537-e546.
3. Rock GA, Shumak KH, Buskard NA, et al; Canadian Apheresis Study Group. Comparison of plasma exchange with plasma infusion in the treatment of thrombotic thrombocytopenic purpura. *N Engl J Med*. 1991;325(6):393-397.
4. Lim W, Vesely SK, George JN. The role of rituximab in the management of patients with acquired thrombotic thrombocytopenic purpura. *Blood*. 2015;125(10):1526-1531.
5. Scully M, Goodship T, How I. How I treat thrombotic thrombocytopenic purpura and atypical haemolytic uraemic syndrome. *Br J Haematol*. 2014;164(6):759-766.
6. Kappers-Klunne MC, Wijermans P, Fijnheer R, et al. Splenectomy for the treatment of thrombotic thrombocytopenic purpura. *Br J Haematol*. 2005;130(5):768-776.
7. Miano M, How I. How I manage Evans syndrome and AIHA cases in children. *Br J Haematol*. 2016;172(4):524-534.
8. Svahn J, Fioredda F, Calvillo M, et al. Rituximab-based immunosuppression for autoimmune haemolytic anaemia in infants. *Br J Haematol*. 2009;145(1):96-100.

9. Patel VL, Mahévas M, Lee SY, et al. Outcomes 5 years after response to rituximab therapy in children and adults with immune thrombocytopenia. *Blood*. 2012;119(25):5989-5995.
10. Sacco KA, Abraham RS. Consequences of B-cell-depleting therapy: hypogammaglobulinemia and impaired B-cell reconstitution. *Immunotherapy*. 2018; 10(8):713-728.
11. Lotta LA, Valsecchi C, Pontiggia S, et al. Measurement and prevalence of circulating ADAMTS13-specific immune complexes in autoimmune thrombotic thrombocytopenic purpura. *J Thromb Haemost*. 2014;12(3):329-336.
12. Gellermann J, Weber L, Pape L, Tönshoff B, Hoyer P, Querfeld U; Gesellschaft für Pädiatrische Nephrologie (GPN). Mycophenolate mofetil versus cyclosporin A in children with frequently relapsing nephrotic syndrome. *J Am Soc Nephrol*. 2013;24(10):1689-1697.
13. Hu Z, Li C, Chen K, et al. Single nucleotide polymorphisms in selected apoptotic genes and BPDE-induced apoptotic capacity in apparently normal primary lymphocytes: a genotype-phenotype correlation analysis. *J Cancer Epidemiol*. 2008;2008:147905.
14. Miano M, Cappelli E, Pezzulla A, et al. FAS-mediated apoptosis impairment in patients with ALPS/ALPS-like phenotype carrying variants on CASP10 gene [published online ahead of print July 15, 2019]. *Br J Haematol*. doi: 10.1111/bjh.16098.
15. Sedger LM, Katewa A, Pettersen AK, et al. Extreme lymphoproliferative disease and fatal autoimmune thrombocytopenia in FasL and TRAIL double-deficient mice. *Blood*. 2010;115(16):3258-3268.
16. Horn S, Hughes MA, Schilling R, et al. Caspase-10 negatively regulates caspase-8-mediated cell death, switching the response to CD95L in favor of NF- κ B activation and cell survival. *Cell Reports*. 2017;19(4):785-797.
17. Tapodi A, Debreceni B, Hanto K, et al. Pivotal role of Akt activation in mitochondrial protection and cell survival by poly(ADP-ribose)polymerase-1 inhibition in oxidative stress. *J Biol Chem*. 2005;280(42):35767-35775.
18. Völkl S, Rensing-Ehl A, Allgäuer A, et al. Hyperactive mTOR pathway promotes lymphoproliferation and abnormal differentiation in autoimmune lymphoproliferative syndrome. *Blood*. 2016;128(2):227-238.
19. Zhu S, Hsu AP, Vacek MM, et al. Genetic alterations in caspase-10 may be causative or protective in autoimmune lymphoproliferative syndrome. *Hum Genet*. 2006;119(3):284-294.
20. Chun HJ, Zheng L, Ahmad M, et al. Pleiotropic defects in lymphocyte activation caused by caspase-8 mutations lead to human immunodeficiency. *Nature*. 2002;419(6905):395-399.
21. Fischer U, Stroth C, Schulze-Osthoff K. Unique and overlapping substrate specificities of caspase-8 and caspase-10. *Oncogene*. 2006;25(1):152-159.
22. Miano M, Scalzone M, Perri K, et al. Mycophenolate mofetil and sirolimus as second or further line treatment in children with chronic refractory primitive or secondary autoimmune cytopenias: a single centre experience. *Br J Haematol*. 2015;171(2):247-253.
23. Davis LS, Reimold AM. Research and therapeutics-traditional and emerging therapies in systemic lupus erythematosus. *Rheumatology*. 2017;56: i100-i113.
24. Cropley A, Weltman M. The use of immunosuppression in autoimmune hepatitis: a current literature review. *Clin Mol Hepatol*. 2017;23(1):22-26.
25. Mazepa MA, Masias C, Chaturvedi S. How targeted therapy disrupts the treatment paradigm for acquired TTP: the risks, benefits, and unknowns. *Blood*. 2019;134(5):415-420.